

# Asymmetry in mesial root number and morphology in mandibular second molars: a case report

**Gurudutt Nayak\*,  
Shashit Shetty, Rhitu  
Shekhar**

Department of Conservative  
Dentistry and Endodontics, Kanti  
Devi Dental College and Hospital,  
Mathura, Uttar Pradesh, India

Ambiguity in the root morphology of the mandibular second molars is quite common. The most common root canal configuration is 2 roots and 3 canals, nonetheless other possibilities may still exist. The presence of accessory roots is an interesting example of anatomic root variation. While the presence of radix entomolaris or radix paramolaris is regarded as a typical clinical finding of a three-rooted mandibular second permanent molar, the occurrence of an additional mesial root is rather uncommon and represents a possibility of deviation from the regular norms. This case report describes successful endodontic management of a three-rooted mandibular second molar presenting with an unusual accessory mesial root, which was identified with the aid of multiangled radiographs and cone-beam computed tomography imaging. This article also discusses the prevalence, etiology, morphological variations, clinical approach to diagnosis, and significance of supernumerary roots in contemporary clinical dentistry. (*Restor Dent Endod* 2014;39(1):45-50)

**Key words:** Accessory root; Accessory root canal; Additional root; Mandibular second molars; Mesial root; Supernumerary root

## Introduction

Human molars show considerable anatomic variation and abnormalities with respect to number of roots and root canals. A thorough knowledge of anatomical variations in multirouted teeth is an essential prerequisite for successful endodontic treatment. In dental literature, the mandibular second molar is typically described as a two rooted tooth with a mesial and a distal root. This form has an overall incidence of 76%.<sup>1</sup> The mesial and the distal roots are usually closer together or have a longer root trunk and are more frequently fused. Root fusion that becomes a single-rooted, conical, or 'C-shaped' form has an incidence of approximately 21.8%.<sup>1</sup> The incidence of a third root, usually the distolingual root (radix entomolaris), in mandibular second molars is approximately 2.2%.<sup>1</sup> While as an additional root located mesiobuccally (radix paramolaris) has an incidence of 0.5%.<sup>2</sup> The existence of an extra root in permanent mandibular second molar is associated with certain ethnic and racial groups. The 'three-rooted molar' trait has a high degree of genetic penetrance as its dominance is reflected in the fact that the prevalence of this trait is more common in Mongoloids than Negros and Caucasians.<sup>3</sup> The mandibular second molar typically has two mesial canals and one distal canal. The mesial root has an incidence of two canals 86% of time and one canal 14% of the time.<sup>1</sup> Mesial root canals may have a single foramen

Received August 14, 2013;  
Accepted September 26, 2013.

Nayak G; Shetty S; Shekhar R,  
Department of Conservative  
Dentistry and Endodontics, Kanti  
Devi Dental College and Hospital,  
Mathura, Uttar Pradesh, India

### \*Correspondence to

Gurudutt Nayak, BDS, MDS.  
Professor, Department of  
Conservative Dentistry and  
Endodontics, Kanti Devi Dental  
College and Hospital, Mathura,  
Uttar Pradesh, India 281006  
TEL, +91-9997259742; FAX, +91-  
565-2825050; E-mail, gurudutt\_  
nayak@hotmail.com

or may exit separately as two or more foramina, but the joining of the two canals is the most common form.<sup>4</sup> Other variations reported in mandibular second molars include taurodontism, fused or single roots, two canals, and additional canals in one or more of the roots.<sup>5-7</sup> Apart from these anatomical aberrations, in extremely rare case, a three-rooted mandibular second molar may present with two separate roots on the mesial side and one on the distal side.<sup>8-11</sup>

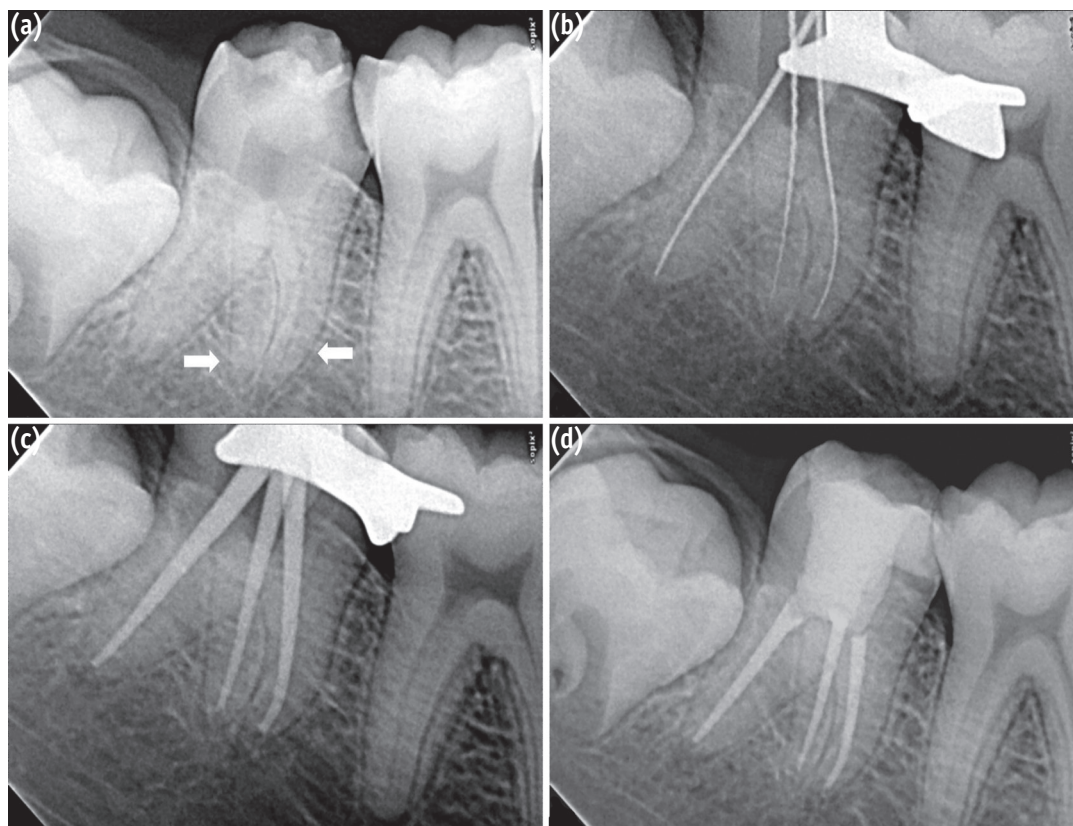
To the best of our knowledge, only four cases of mandibular second molars with two mesial roots have been reported in the literature to date. While earlier description were based on endodontic treatment using conventional radiographs and on examination of extracted teeth, no clinical reports have attempted to identify or define the degree and level of separation of the two mesial roots using cone-beam computed tomography (CBCT) imaging.<sup>8-11</sup> This case report describes a successful endodontic management of a three-rooted mandibular second molar presenting with an unusual accessory mesial root, identified with the aid of multiangled radiographs and CBCT. This article also discusses the prevalence, etiology, morphological variations, clinical approach to diagnosis, and significance of supernumerary roots in contemporary clinical dentistry.

## Case report

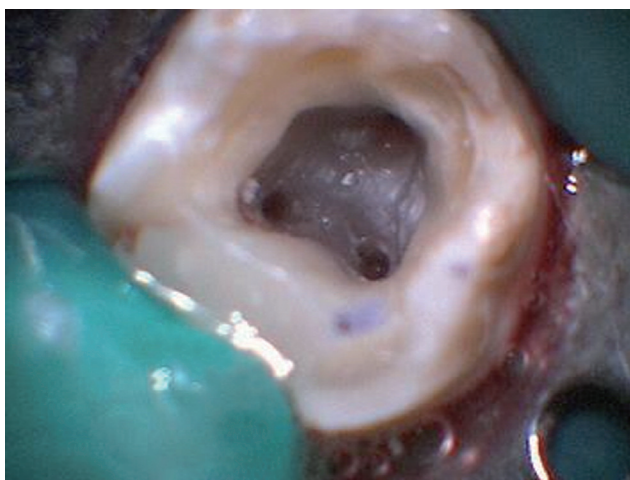
A 16-year old male patient presented to the Department of Conservative Dentistry and Endodontics with a chief complaint of pain in his lower right posterior region of mouth for one week. The patient revealed a history of mild intermittent pain for the past 2 months, which had increased in intensity since one week ago. The patient reported subjective symptoms of prolonged sensitivity to hot and cold food and drinks. The pain was spontaneous and aggravated particularly at night and required analgesic to get relief from pain. The medical history contained no abnormal data. Clinical examination revealed a deep carious lesion on the proximal surface of right mandibular second molar (tooth #47). Palpation and percussion test of the involved tooth did not reveal any tenderness. The tooth was not mobile and periodontal probing around the tooth was within physiological limits. Thermal testing of the involved tooth with heated gutta-percha (Dentsply Maillefer, Ballaigues, Switzerland) and cold spray (Roeko Endo-Frost, Coltène-Whaledent, Langenau, Germany) caused an intense lingering pain, whereas electronic pulp stimulation (Parkell Electronics Division, Farmingdale, NY, USA) caused an early response. The preoperative diagnostic radiograph showed carious lesion closely approximating the pulp with no signs of periapical changes (Figure 1a). From the clinical tests and radiographic findings, a diagnosis of symptomatic irreversible pulpitis was made and endodontic treatment was initiated.

Radiographic evaluation of the involved tooth revealed an unusual anatomical configuration suggesting the possibility of the presence of two mesial roots (Figure 1a). The mesial surface of the tooth was restored with composite resin (P60, 3M ESPE, St. Paul, MN, USA) after caries excavation to enable optimal isolation. The tooth was anesthetized using 1.8 mL 2% lidocaine with 1 : 200,000 epinephrine (Xylocaine, AstraZeneca Pharma India Ltd., Bangalore, India). Following rubber dam isolation, an endodontic access cavity was established. On inspection with a DG-16 endodontic explorer (Hu-Friedy, Chicago, IL, USA) under an operating microscope (Roslane Meditech, Haryana, India), the pulp chamber floor revealed three canal openings corresponding to the two mesial and one distal roots (Figure 2). The mesiobuccal, mesiolingual, and distal canal orifices were located in their regular locations at the angles in the floor-wall junction. Further inspection of the pulpal floor was done for search of other orifices that were absent. Coronal enlargement was done with a nickel-titanium (NiTi) ProTaper SX rotary file (Dentsply Maillefer) to improve the straight-line access. The pulp tissue was extirpated using barbed broaches (Dentsply Tulsa, Tulsa, OK, USA). The working length was initially determined with the help of an apex locator (Raypex5, VDW, Munich, Germany) and confirmed using radiographs taken at different horizontal angulations. The working length radiographs showed three independent root canals in three separated roots (Figure 1b). Cleaning and shaping was done using ProTaper NiTi rotary instruments (Dentsply Maillefer) along with ethylenediaminetetraacetic acid (Glyde File Prep, Dentsply Tulsa) using a crown-down technique. Irrigation was performed using 3% sodium hypochlorite solution (Cmident, Cmident, New Delhi, India). Afterwards, a closed dressing was given with a sterilized cotton pellet in the pulp chamber with access cavity restored with Cavit G (3M ESPE).

To confirm this rare and unusual morphology, dental imaging of the tooth with the help of CBCT (Carestream CS 9300, Carestream Dental LLC, Atlanta, GA, USA) was planned. An informed consent was obtained from the patient, and a multi-slice scans of the mandible was performed with a tube voltage of 90 kV and a tube current of 15 mA. All measures were taken to protect the patient from radiation. The involved tooth was focused, and the cross-sectional images were obtained in transverse, axial, and sagittal planes (Figures 3a - 3d). All images were analyzed with the help of CS 3D Imaging software (Carestream Dental LLC). Horizontal slices of the molar were obtained at 0.5-mm thickness, and were studied at different levels (coronal, middle, and apical third of the roots) to determine the level of root bifurcation and degree of root separation (Figures 3b - 3d). The images confirmed that the right mandibular second molar had 2 mesial roots and 1 distal root with independent canal in each. The



**Figure 1.** (a) Preoperative radiograph showing the external outlines of the two mesial roots (white arrows); (b) Working length radiograph showing three separate roots and root canals; (c) Master cone radiograph; (d) Post-obturation radiograph.

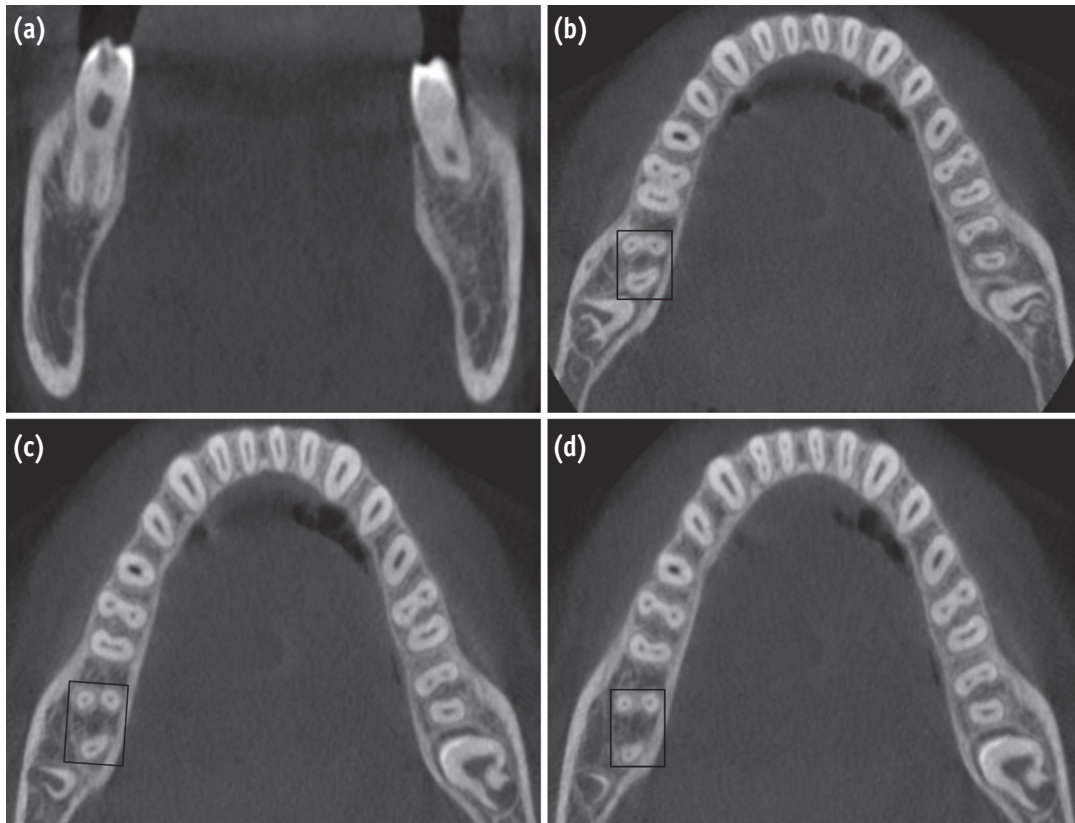


**Figure 2.** An intraoral photograph showing the wide buccolingual dimension of the mesial orifices.

mesial roots were well separated and were bifurcated at the level of coronal one third. In contrast, the contralateral mandibular second molar was asymmetrical. It had 2 roots, 1 mesial, and 1 distal with 2 canals in the mesial root and 1 canal in the distal root (Figures 3a - 3d).

At the second appointment, the patient was asymptomatic. Temporary restoration was removed and irrigation was done with copious amounts of 3% sodium hypochlorite and 17% ethylenediaminetetraacetic acid (EDTA, Prevest Denpro Ltd., Jammu, India). The canals were finally flushed with sterile saline. Master cones were selected by placing cones corresponding to the size of the last finishing file used to the working length and was confirmed radiographically (Figure 1c). The canals were dried with absorbent points (ProTaper, Dentsply Maillefer) and obturation was carried out with ProTaper gutta-percha cones (Dentsply Maillefer) using AH Plus resin sealer (Dentsply Detrey GmbH, Konstanz, Germany). The tooth was then restored with a posterior composite resin core (P60, 3M ESPE). Final radiograph was taken to establish the quality of the obturation (Figure 1d). The patient remained asymptomatic during 1 year follow-up period.





**Figure 3.** (a) Transverse section cone-beam computed tomography (CBCT) scan image of tooth #47 clearly showing two separate mesial roots. Axial section of CBCT scan image (b) at the coronal third; (c) at the middle third; (d) at the apical third.

## Discussion

An accessory root, also known as an extra root, supernumerary root, supplementary root or additional root, refers to the development of an increased number of roots in teeth compared with that classically described in dental anatomy.<sup>12</sup> The exact etiology behind the formation of accessory root is unclear. Various etiological factors have been suggested. Supernumerary roots may result secondary to metabolic dysfunction during root development after birth.<sup>13</sup> Its formation could be related to the disturbances in the Hertwig's epithelial root sheath (HERS) forming the root. Splitting of the HERS results in formation of two similar roots where it is difficult to differentiate which one is the accessory. Whereas folding of the HERS results in formation of an independent root which may present with various morphological features.<sup>14</sup> Midtbø and Halse reported an association of supernumerary roots with Turner syndrome, which is a sex chromosomal disorder associated with a female phenotype. The interactions between the mesenchyme and epithelium can be influenced by the

reduced amount of X-chromosome material, thereby modifying the sequence of events in tooth formation, including the formation of accessory roots.<sup>15</sup>

Accessory roots may be fully developed or rudimentary. They may sometimes be fused to other roots or be bifid and broadly separated. Generally, an accessory root which usually represents an autonomous outgrowth at the level of the crown is considered as an entity on its own. Controversy does exist whether bifurcation of root, the level of root bifurcation and degree of root separation should be considered in defining any root component as an accessory root. De Souza-Freitas *et al.* studied the anatomical variations of mandibular first molar roots in two ethnic groups, and commented that distolingual roots are the real supplementary roots, and they did not consider the mesial root bifurcation as a third root.<sup>16</sup> Onda *et al.* examined the shape and number of roots in mandibular molar teeth extracted from Indian skulls. Molars with an additional distolingual root, accessory lingual root, and bifurcation of the mesial root were categorized as teeth with increased number of roots. The level of mesial root

bifurcation were classified as apical, middle or cervical depending whether more or less than one third of the root length was involved. Accordingly, all root bifurcations that have their own root canals were defined as extra roots, whether they are separated or fused.<sup>17</sup>

Conventional intra-oral periapical radiographs has been the standard method for ascertaining varying morphology of the root and root canal system. If the outlines of the roots are unclear, the root canal shows sharp density changes or the apices cannot be well defined, then extra roots can be suspected.<sup>8</sup> The use of a preoperative radiograph and an additional radiographic view from a 20-degree mesial or distal projection aids in the accurate detection of the periodontal ligament outlines, thus facilitating the interpretation of external root anatomy. Two periodontal ligament spaces on one side of a root and the periodontal ligament space crossing over roots are important observations that can indicate either the presence of 2 mesial roots, bifurcation of the mesial root, or a very broad faciolingually oriented mesial root.<sup>17</sup> In our case, a 20-degree mesial angulation periapical radiograph of the right mandibular second molars revealed double periodontal ligament spaces in the mesial roots indicating the presence of an accessory mesial root (Figure 1a). CBCT investigations confirmed the existence 2 well separated mesial roots in which the level of bifurcation is at the coronal third (Figures 3a - 3d).

A literature search was done in the PubMed and Google Scholar search engines to ascertain the existence of such an unusual morphology. Most of the anatomical studies pertaining to accessory roots in mandibular molars described the additional root to be either radix entomolaris or radix paramolaris while clinical case reports of this anomaly are relatively few.<sup>8-11</sup> Ravanshad and Nabavizade reported endodontic treatment of a mandibular second molar with 3 separate roots, two located mesially and one distally.<sup>10</sup> The identification of the additional mesial root was done through careful examination of the diagnostic radiograph. Ahmed and Luddin reinforced the importance of knowing the anatomical variations of mandibular second molar when they demonstrated successful identification and endodontic management of a three-rooted mandibular second molar with an accessory mesial root.<sup>11</sup> In addition, they conducted a scanning electron microscope (SEM) and radiographic evaluation of an extracted mandibular second molar with an apically bifurcated mesial root. The SEM analysis revealed the presence of furcation, lateral canals and multiple foramina at both apices. The radiographic examination showed three mesial canals, in which the mesiobuccal and middle mesial root canals were connected at the middle third of the root. Peiris *et al.* examined an extracted mandibular second molar with four distinct roots: two mesial and two distal. Mesial roots were separated in the cervical one-third near the cervical margin, while

distal roots were divided at a lower level in the middle one-third of the root. Internal canal morphology of the mesial root displayed two separate canals leaving from the pulp chamber all the way through to the apex. While as in the distal root, a single canal was seen leaving the pulp chamber and dividing into two at the cervical one-third of the root.<sup>9</sup>

During diagnosis, it is also important to differentiate and rule out an additional mesial root from other supernumerary roots that are associated with mandibular molars such as radix entomolaris or radix paramolaris. The radix entomolaris is located distolingually, with its coronal third completely or partially fixed to the distal root. The dimensions can vary from a short conical extension to a 'mature' root with normal length and root canal. In most cases the pulpal extension is radiographically visible. In general, the radix entomolaris is smaller than the distobuccal and mesial roots. The root can be straight or curved to the lingual, and can be separate from, or partially fused with, the other roots. Whereas, the radix paramolaris is located mesiobuccally, with its cervical part either located on the mesial root complex (Type A) or centrally between the mesial and distal root complexes (Type B). This additional root can be separate or fused with the mesial root. The dimensions of the radix paramolaris can vary from a 'mature' root with a root canal, to a short conical extension.<sup>18</sup>

Unusual occurrence of an extra mesial root has significant implications in clinical dentistry. During the endodontic treatment, modification in the access cavity design is usually a common landmark for teeth having accessory roots, especially when they are well separated with a coronal bifurcation.<sup>11,18</sup> The orifice of the additional mesial root is located along the same horizontal line as that of the orifice of the main mesial root. The mesial wall of the access cavity needs to be extended more in a buccolingual direction to locate and gain access to the well separated canal orifices (Figure 2).<sup>11</sup> Before initiating the mechanical instrumentation of the root canal, it is important to evaluate the dentine wall thickness and curvature of accessory roots.<sup>10,18</sup> This is because the accessory roots are relatively thin and the root canal instrumentation should be performed with caution to avoid perforation or stripping caused by over-enlargement of the encased root canals. Additionally, accessory mesial roots may also present with severe curvatures and narrow canals.<sup>10</sup> Therefore, after relocation and enlargement of the canal orifice, initial exploration of the root canal must be done with small files (size 10 or less) followed by creation of a glide path before shaping the canal using flexible nickel titanium hand and rotary files of suitable taper with lubrication. This helps in preserving the normal root canal geometry, and also prevents the incidence of shaping aberrations such as instrument separation, ledge formation, root canal

transportation, straightening of the root canal, and loss of working length.<sup>18</sup> Furthermore, the presence of third root poses a significant challenge in case of endodontic surgical procedures.<sup>19</sup>

However, the occurrence of accessory roots in some teeth might contribute to the development of localized periodontitis. Complex furcation associated with teeth with accessory roots leads to the formation of a well-protected environment for microorganisms and their toxins to evoke localized periodontal destruction. This problem may also lead to earlier involvement of the pulp as a result of the communication between the pulp and the periodontal ligament through the apical foramen especially in teeth with short accessory root.<sup>20</sup>

## Conclusions

The root anatomy is highly complex and unpredictable. The knowledge of the normal and its frequent variations dictates the parameters for execution of root canal therapy and can directly affect the probability of success. The present case report describes the endodontic treatment of an unusual mandibular second molar with 2 separate mesial roots with 2 root canals. This article also puts impetus on careful examination of multiangled preoperative radiographs and use of advanced diagnostic aids, such as CBCT in identification and better understanding of such complex developmental abnormalities.

Conflict of Interest: No potential conflict of interest relevant to this article was reported.

## References

- Ingle JJ, Backland LK, Baumgarthner JC. Endodontics, 6th ed. Hamilton: BC Decker Inc.; 2008. Cleghorn BM, Goodacre CJ, Christie WH. Morphology of teeth and their root canal system. p151-220.
- Visser JB. Beitrag zur Kenntnis der menschlichen Zahnwurzelformen. Hilversum: Rotting; 1948. p49-72.
- Ferraz JA, Pécora JD. Three-rooted mandibular molars in patients of Mongolian, Caucasian and Negro origin. *Braz Dent J* 1993;3:113-117.
- Slowey RR. Root canal anatomy. Road map to successful endodontics. *Dent Clin North Am* 1979;23:555-573.
- Sert S, Bayrl G. Taurodontism in six molars: a case report. *J Endod* 2004;30:601-602.
- Fava LR, Weinfeld I, Fabri FP, Pais CR. Four second molars with single roots and single canals in the same patient. *Int Endod J* 2000;33:138-142.
- Bond JL, Hartwell GR, Donnelly JC, Portell FR. Clinical management of middle mesial root canals in mandibular molars. *J Endod* 1988;14:312-314.
- Kannan SK, Suganya, Santharam H. Supernumerary roots. *Indian J Dent Res* 2002;13:116-119.
- Peiris R, Pitakotuwage N, Takahashi M, Ohzeki S, Nakayama M, Sakurai S, Igarashi Y, Matsuno M, Sasaki K, Satake T, Kanazawa E. Mandibular permanent second molar with four roots and root canals: a case report. *Odontology* 2009;97:51-53.
- Ravanshad S, Nabavizade MR. Endodontic treatment of a mandibular second molar with two mesial roots: report of a case. *Iran Endod J* 2008;3:137-140.
- Ahmed HMA, Luddin N. Accessory mesial roots and root canals in mandibular molar teeth: case reports, SEM analysis and literature review. *Endod Pract Today* 2012;6:195-205.
- Neville BW, Damm DD, Allen CM, Bouquot JE, eds. Oral & Maxillofacial Pathology, 2nd ed. Philadelphia: Saunders; 2002. Neville BW, Damm DD, Allen CM, Bouquot JE. Abnormalities of teeth. p88.
- Baert AL. Encyclopedia of diagnostic imaging. Volume 1. Seoul: Springer; 2008. p427.
- Alt KW, Rösing FW, Teschler-Nicola M. Dental Anthropology. Fundamentals, Limits and Prospects, Austria: Springer; 1998. Türp JC, Alt KW. Chapter 3.1. Anatomy and morphology of human teeth. p71-94.
- Midtbø M, Halse A. Root length, crown height, and root morphology in Turner syndrome. *Acta Odontol Scand* 1994;52:303-314.
- de Souza-Freitas JA, Lopes ES, Casati-Alvares L. Anatomic variations of lower first permanent molar roots in two ethnic groups. *Oral Surg Oral Med Oral Pathol* 1971;31:274-278.
- Onda S, Minemura R, Masaki T, Funatsu S. Shape and number of the roots of the permanent molar teeth. *Bull Tokyo Dent Coll* 1989;30:221-231.
- Calberson FL, De Moor RJ, Deroose CA. The radix entomolaris and paramolaris: clinical approach in endodontics. *J Endod* 2007;33:58-63.
- Jerome CE, Hanlon RJ Jr. Dental anatomical anomalies in Asians and Pacific Islanders. *J Calif Dent Assoc* 2007;35:631-636.
- Huang RY, Lin CD, Lee MS, Yeh CL, Shen EC, Chiang CY, Chiu HC, Fu E. Mandibular disto-lingual root: a consideration in periodontal therapy. *J Periodontol* 2007;78:1485-1490.