

Imaging-Based Diagnosis of Wernicke Encephalopathy: A Case Report

Hosein Delavar Kasmaei¹; Alireza Baratloo²; Maryam Soleymani^{1*}; Zahra Nasiri¹

¹Department of Neurology, Shohada Tajrish Hospital, Shahid Beheshti University of Medical Sciences, Tehran, IR Iran

²Department of Emergency Medicine, Shohada Tajrish Hospital, Shahid Beheshti University of Medical Sciences, Tehran, IR Iran

*Corresponding author: Maryam Soleymani, Department of Neurology, Shohada Tajrish Hospital, Shahid Beheshti University of Medical Sciences, Tehran, IR Iran. Tel.: +98-917042319, Fax: +98-2122721155, E-mail: dr_maya_s@yahoo.com

Received: January 5, 2014; **Revised:** January 30, 2014; **Accepted:** February 10, 2014

Introduction: Wernicke encephalopathy (WE) is a medical emergency characterized by ataxia, confusion, nystagmus and ophthalmoplegia resulting from thiamin deficiency. Alcoholism is the common cause for this disease.

Case Presentation: A 41-year-old man was brought to our emergency department (ED) complaining of confusion. One week earlier he had started to experience severe nausea and vomiting followed by diplopia, dysarthria and also dysphagia. One day later he had experienced gait disturbance and progressive ataxia accompanied with confusion, apathy and disorientation. He had no history of alcoholism, drug abuse or previous surgery but had history of untreated Crohn disease. Just before arrival to our emergency department, he had been hospitalized in another center for about a week but all investigations had failed to provide a conclusive diagnosis. Upon admission to our ED, he was dysarthric and replied with inappropriate answers. On physical examination, bilateral horizontal nystagmus in lateral gaze, left abducens nerve palsy and upward gaze palsy were seen. Gag reflex was absent and plantar reflexes were upwards bilaterally. After reviewing all the previously performed management measures, MRI was performed and was consistent with the diagnosis of WE. Treatment with thiamine led to partial resolution of his upward gaze palsy and nystagmus on the first day. At the end of the third day of treatment, except for gait ataxia, all other symptoms completely resolved and he was fully conscious. After the fifth day his gait became normal and after one week he was discharged in good general condition.

Discussion: After reviewing the current literature, it seems that brain MRI can be helpful in the diagnosis of WE in patients with the classic clinical trial in the absence of clear risk factors.

Keywords: Wernicke Encephalopathy; Magnetic Resonance Imaging; Thiamine Deficiency; Diagnosis

1. Introduction

Wernicke encephalopathy (WE) is a medical emergency characterized by ataxia, confusion, nystagmus and ophthalmoplegia which is related to an initially reversible biochemical brain damage resulting from the depletion of intracellular thiamine stores. Left untreated, it may lead to Korsakoff syndrome or even death (1, 2).

Alcoholism is the most common cause of thiamine deficiency around the world (3). Poor diet associated with unhealthy lifestyle, impaired thiamine storage, chronically compromised thiamine absorption from the gastrointestinal tract and reduced thiamine metabolism are some of the known etiologies of this condition (3-6).

2. Case Presentation

A 41-year-old man was brought to our ED complaining of confusion. One week earlier he had started to experience severe nausea and vomiting. These symptoms were followed by diplopia, dysarthria and also dysphasia. One day later he had experienced gait disturbances and progressive ataxia accompanied with confusion, apathy and disorientation. He had no history of alcoholism, drug abuse or previous surgery but had a history of untreated Crohn disease. Just before the arrival in our ED, he was

hospitalized in another center for about one week but all investigations had failed to reveal the diagnosis. When he was admitted to our ED, he was confused and disoriented to time and place. He was dysarthric and replied with inappropriate answers. Cranial nerve examination showed bilateral horizontal nystagmus in lateral gaze, left abducens nerve palsy and upward gaze palsy. Pupils had normal size and normal light reaction. Gag reflex was absent. In motor examination, tone and force of muscles were normal, DTRs were +2 in all limbs. Plantar reflexes were upwards bilaterally. Sensory examination was normal. Bilaterally, finger to nose exam was abnormal and dysmetria was seen. After reviewing all previously performed investigations, MRI was performed which was consistent with the diagnosis of WE (Figures 1 and 2). Treatment with thiamine led to partial resolution of his upward gaze palsy and nystagmus on the first day. At the end of the third day of treatment, except for gait ataxia, all other symptoms were fully corrected and he was totally conscious. After the fifth day his gait became normal and after one week he was discharged in good general condition.

It should be mentioned that after recovery he denied any alcohol consumption but mentioned occasional use of Clonazepam. All other clinical settings related to WE described in previous reports were thoroughly ruled out,

including malnutrition, history of gastrointestinal surgical procedures, unbalanced nutrition including staple diet of polished rice, chronic diarrhea, cancer, systemic diseases such as renal disease, hyperthyroidism, and chronic infectious febrile diseases, magnesium depletion, and use of drugs known for causing WE.

3. Discussion

Classically, thiamine deficiency causes lesions in tectal plate, thalamus, hypothalamic nuclei and periventricular nuclei which may result in WE's cardinal signs of ataxia, nystagmus, ophthalmoplegia and confusion (7). Although alcoholism is the most common cause, other disorders may affect thiamine bioavailability or metabolism (Box 1) (1, 7, 8).

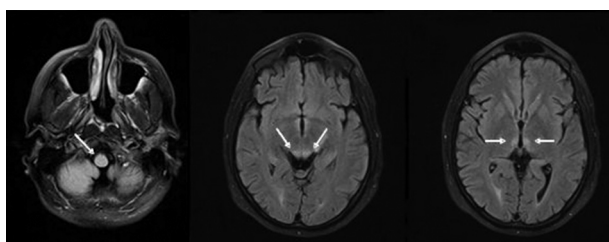


Figure 1. MRI (FLAIR Sequences) Consistent With the Diagnosis of WE

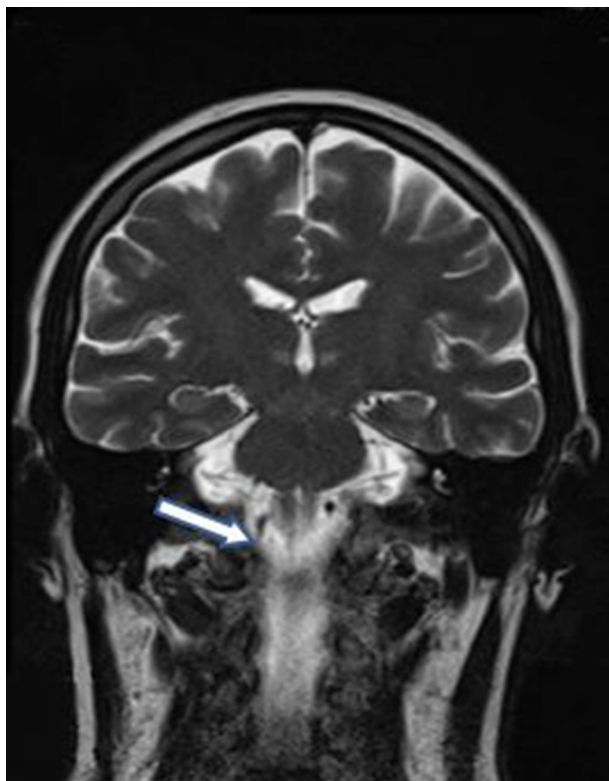


Figure 2. MRI (Coronal T2 Weighted Sequence) Consistent With the Diagnosis of WE

In spite of the fact that thiamine deficiency is possible in the context of inflammatory bowel disease (IBD) and has been reported with various manifestation in some case reports, IBD and WE do not have a clear association with each other (9, 10). Whenever WE is suspected based on the physical exam and history, high-dose parenteral thiamine should be administered as soon as possible to reduce the risk of progression to Korsakoff Syndrome (KS) or death (2). Neuroimaging has been used for many years by emergency physicians in various trauma, ischemic and hemorrhagic brain insults and cerebral venous thrombosis. So it may be helpful to review some special aspects of this (11, 12). Imaging with the aim of diagnosing WE has been used from 1970s. Ventricular enlargement, especially in the third ventricle, has been reported in previous studies using computed tomography (CT) scanning but could not detect any focal damage or edema (7). Magnetic resonance imaging (MRI), with its high

Box 1. Clinically Relevant Causes of Thiamine Deficiency

Clinically Relevant Thiamine Deficiency

Alcoholism

AIDS

Malnutrition

Hunger strike

Hepatic disease

Orofacial cancers

Pyloric obstruction

Multiple organ failure

Magnesium deficiency

Gastric bypass surgery

Long term hemodialysis

Hyperemesis gravidarum

Gastrointestinal carcinoma

Prolonged parenteral therapy

Prolonged furosemide therapy

Anorexia and Anorexia nervosa

Inflammatory bowel disease (IBD)

Rapid parenteral carbohydrate loading

Chronic diarrhea or persistent vomiting

Infarction of the Mammillothalamic tracts

sensitivity for water contenting tissues, have revolutionized the diagnosis of neurologic lesions not visible on CT. Tissues with high water content which are shown as hyperintense abnormal structures in T2-weighted late-echo sequences of brain MRI, can be a sign of edematous lesion of WE in alcoholics (7, 13). Reviewing the literature, show the most obvious imaging sign of acute WE is bilateral hyperintensity on late-echo MRI, generally happening in gray matter tissues of the mammillary bodies, anterior and medial nuclei of the thalamus, inferior and superior

colliculi, periventricular gray matter and occasionally cerebellum; bilateral distribution of these findings may correlate with the clinical severity of the disease (14-18). Although the pons is rarely affected in WE, but there is some evidence regarding excessive fluid accumulation in the central pons of patients with alcoholic WE-KS, revealed by MR study examination of T2 relaxation time (19).

Introduction of the MRI fluid attenuated inversion recovery (FLAIR) sequence has significantly advanced diagnosis. FLAIR sequences have special ability to enhance the signal in edematous lesions (7). In one study, by evaluating six nonalcoholic cases of WE with FLAIR, hyperintense signals were seen in the tissues around the medial thalami, third ventricle, aqueduct, anterior ventricular caps and floor of the fourth ventricle; follow-up examination noted recovery in the four cases without cortical damage but not in the two cases with such damage (16). Magnetic resonance diffusion-weighted imaging (DWI) is another proven MRI technique for detection of WE brain lesions. The bright signal, representing high diffusivity abnormalities, in the periventricular and thalamic tissues typically is compatible with WE diagnosis; despite this fact, one case study concluded that bright signal on DWI was caused by abnormally low diffusion in the cerebellum, so further studies are still needed (15, 20, 21). DWI-increased signal intensity in the affected brain regions, confirmed as decreased diffusivity with apparent diffusion coefficient (ADC) images, has been reported in two studies of acute WE (21, 22). Interpretation of DWI accompanied by ADC imaging for assessment of the water diffusion, has allowed characterization of a spectrum of WE lesions from early edematous high diffusivity through later atrophic low diffusivity (7). The presented patient was diagnosed as having WE based on typical brain MRI findings and response of neurological signs and symptoms to thiamine administration. Thus, it seems that brain MRI can be helpful in diagnosis of WE in patients with classic clinical triad of WE but in the absence of clear risk factors. This case report can be useful in designing future retrospective and prospective studies in this disease.

Acknowledgements

We would like to thank all ED personnel who helped in diagnosis and management of this patient.

Authors' Contributions

Study supervision: Hosein Delavar Kasmaei; study concept, design and critical revision of the manuscript for important intellectual content: Alireza Baratloo; acquisition of data: Maryam Soleymani; drafting of the manuscript: Zahra Nasiri.

References

1. Thomson AD, Cook CC, Touquet R, Henry JA, Royal College of Physicians L. The Royal College of Physicians report on alcohol: guidelines for managing Wernicke's encephalopathy in the accident and Emergency Department. *Alcohol Alcohol*. 2002;**37**(6):513-21.
2. Kopelman MD, Thomson AD, Guerrini I, Marshall EJ. The Korsakoff syndrome: clinical aspects, psychology and treatment. *Alcohol Alcohol*. 2009;**44**(2):148-54.
3. Thomson AD. Mechanisms of vitamin deficiency in chronic alcohol misusers and the development of the Wernicke-Korsakoff syndrome. *Alcohol Alcohol*. 2000;**35**(Supplement 1):1-2.
4. Lieber CS. Relationships between nutrition, alcohol use, and liver disease. *Alcohol Res Health*. 2003;**27**(3):220-31.
5. Martin PR, Singleton CK, Hiller-Sturmhofel S. The role of thiamine deficiency in alcoholic brain disease. *Alcohol Res Health*. 2003;**27**(2):134-42.
6. Thomson AD, Marshall EJ. The natural history and pathophysiology of Wernicke's Encephalopathy and Korsakoff's Psychosis. *Alcohol Alcohol*. 2006;**41**(2):151-8.
7. Sullivan EV, Pfefferbaum A. Neuroimaging of the Wernicke-Korsakoff syndrome. *Alcohol Alcohol*. 2009;**44**(2):155-65.
8. Cirignotta F, Manconi M, Mondini S, Buzzi G, Ambrosetto P. Wernicke-korsakoff encephalopathy and polyneuropathy after gastroplasty for morbid obesity: report of a case. *Arch Neurol*. 2000;**57**(9):1356-9.
9. Costantini A, Pala MI. Thiamine and fatigue in inflammatory bowel diseases: an open-label pilot study. *J Altern Complement Med*. 2013;**19**(8):704-8.
10. Larnaout A, El-Euch G, Kchir N, Filali A, Hamida MB, Hentati F. Wernicke's encephalopathy in a patient with Crohn's disease: a pathological study. *J Neurol*. 2001;**248**(1):57-60.
11. Arhami Dolatabadi A, Baratloo A, Rouhipour A, Abdalvand A, Hatamabadi H, Forouzanfar M, et al. Interpretation of Computed Tomography of the Head: Emergency Physicians versus Radiologists. *Trauma Mon*. 2013;**18**(2):86-9.
12. Delavar Kasmaei H, Baratloo A, Soleimani M. A 33-year-old woman with severe postpartum headache. *Emerge*. 2013;**1**(1).
13. Sullivan EV, Pfefferbaum A. Neurocircuitry in alcoholism: a substrate of disruption and repair. *Psychopharmacology (Berl)*. 2005;**180**(4):583-94.
14. Chu K, Kang DW, Kim HJ, Lee YS, Park SH. Diffusion-weighted imaging abnormalities in wernicke encephalopathy: reversible cytotoxic edema? *Arch Neurol*. 2002;**59**(1):123-7.
15. Unlu E, Cakir B, Asil T. MRI findings of Wernicke encephalopathy revisited due to hunger strike. *Eur J Radiol*. 2006;**57**(1):43-53.
16. Zhong C, Jin L, Fei G. MR Imaging of nonalcoholic Wernicke encephalopathy: a follow-up study. *AJNR Am J Neuroradiol*. 2005;**26**(9):2301-5.
17. Nicolas JM, Fernandez-Sola J, Robert J, Antunez E, Cofan M, Cardenal C, et al. High ethanol intake and malnutrition in alcoholic cerebellar shrinkage. *QJM*. 2000;**93**(7):449-56.
18. Bae SJ, Lee HK, Lee JH, Choi CG, Suh DC. Wernicke's encephalopathy: atypical manifestation at MR imaging. *AJNR Am J Neuroradiol*. 2001;**22**(8):1480-2.
19. Sullivan EV, Pfefferbaum A. Magnetic resonance relaxometry reveals central pontine abnormalities in clinically asymptomatic alcoholic men. *Alcohol Clin Exp Res*. 2001;**25**(8):1206-12.
20. Le Bihan D, Poupon C, Amadon A, Lethimonnier F. Artifacts and pitfalls in diffusion MRI. *J Magn Reson Imaging*. 2006;**24**(3):478-88.
21. Halavaara J, Brander A, Lyytinen J, Setälä K, Kallela M. Wernicke's encephalopathy: is diffusion-weighted MRI useful? *Neuroradiology*. 2003;**45**(8):519-23.
22. Lapergue B, Klein I, Olivot JM, Amarenco P. Diffusion weighted imaging of cerebellar lesions in Wernicke's encephalopathy. *J Neuroradiol*. 2006;**33**(2):126-8.