

## CASE REPORT

# Unexpected foreign body induced refractory maxillary sinusitis

Bassel Hallak<sup>1</sup>  | Pedro Teiga<sup>1</sup> | Jean-Pierre Bühler<sup>2</sup> | Salim Bouayed<sup>1</sup>

<sup>1</sup>Department of Otorhinolaryngology- Head and Neck Surgery, Sion Hospital, Sion, Switzerland

<sup>2</sup>Department of Dental and Maxillofacial Surgery, Sion Hospital, Sion, Switzerland

**Correspondence**

Bassel Hallak, Department of Otorhinolaryngology, Sion Hospital, Avenue du Grand-Champsec 80, 1950 Sion, Switzerland.

Emails: [bassel2004@hotmail.com](mailto:bassel2004@hotmail.com); [bassel.hallak@hopitalvs.ch](mailto:bassel.hallak@hopitalvs.ch)

**Abstract**

Maxillary sinusitis induced by ipsilateral dental manipulation often carries the risk of sinus foreign body impaction. Adequate evaluation mandates radiological exploration of the sinus. Management requires complete foreign body removal, surgical drainage of the sinus, and closure of any oroantral communication or fistula.

**KEYWORDS**

dental implant, foreign body, maxillary sinusitis, oroantral fistula

## 1 | INTRODUCTION

Foreign bodies' impaction in paranasal sinuses is an unusual clinical condition. The majority of impacted foreign bodies are found in the maxillary sinus and come from an odontogenic source. Of these, only approximately 10% will cause a maxillary sinusitis. Oroantral fistulas secondary to dental manipulations are the most common entry point for foreign bodies into the maxillary sinus. Adequate management requires complete surgical removal of the foreign body and oroantral communication closure.

Unilateral maxillary sinusitis is usually related to specific underlying causes, such as facial trauma with maxillary injury, tumors, fungal infections, dental affections, or foreign bodies.<sup>1</sup>

The anatomical proximity between the maxillary sinus and teeth make the odontogenic origin the most common source of maxillary sinusitis.

Throughout the literature, the majority of maxillary sinus foreign bodies are in relation to iatrogenic dental manipulation<sup>2</sup> and only a few cases with nondental origin are reported. These odontogenic maxillary sinus foreign bodies differ in their nature from teeth roots, root-filling materials, broken teeth fragments, dental implants, and dental impression materials. Foreign bodies may penetrate the maxillary sinus

by different mechanisms, such as apical migration of filling fragments, accidental rough handling, or through an oroantral fistula.<sup>3</sup>

We report an unusual and unexpected case of foreign body in the maxillary sinus after removal of a displaced dental implant of the upper first molar (tooth 26). Our patient presented a refractory ipsilateral maxillary sinusitis despite several medical treatments. Radiological imaging showed a full drill (steel round bur) on the floor of the maxillary sinus. Surgical removal of the foreign body was done by transnasal endoscopic approach associated with total drainage of the maxillary sinus and followed by medical management. The outcome is presented.

## 2 | CASE REPORT

We report the case of 60-year-old male presenting a refractory left maxillary sinusitis. His medical background did not show any medical history or known diseases. Three months prior he undergone insertion of two dental implants at the level of the upper first premolar and first molar on the left side by his dentist. The procedure report did not mention any problem, technical difficulties, or complications during the placement of both implants. What is more, no mention was made of any oroantral communication.

This is an open access article under the terms of the Creative Commons Attribution-NonCommercial-NoDerivs License, which permits use and distribution in any medium, provided the original work is properly cited, the use is non-commercial and no modifications or adaptations are made.

© 2021 The Authors. *Clinical Case Reports* published by John Wiley & Sons Ltd.

A few days after the insertion of both dental implants, the patient presented a unilateral facial and dental pain on the left side, more important at the level of tooth 26. Despite initial pain managed by different analgesics, the outcome was unfavorable. At 3 weeks after the intervention, the dentist noticed an implant displacement, probably in relation with a lack of bony integration. He then decided to remove the crown and keep the implant in place, introducing an antibiotic treatment (Amoxicillin 750 mg) thrice daily for a week. Later on, at 6 weeks after implantation, the pain had not subsided and the dentist decided to remove the whole implant with a second cure of antibiotic (Amoxicillin 1 gr, twice daily for a week). No radiographic imaging was made at this stage.

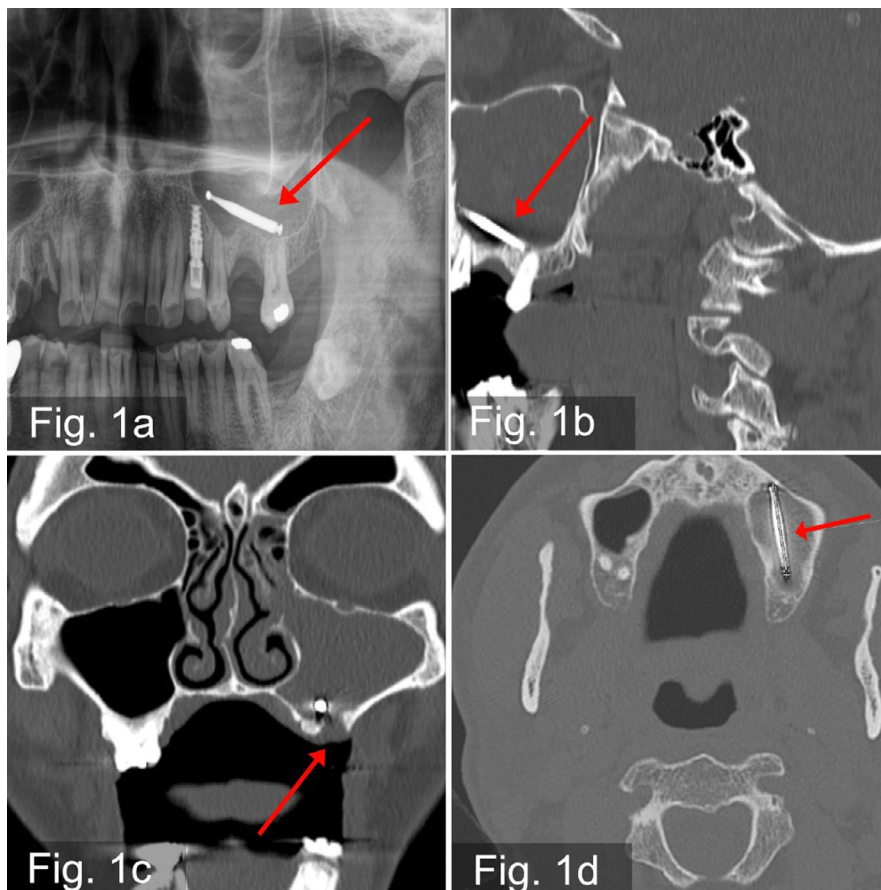
The worsening of the facial pain on the left side, especially regarding the maxillary sinus, lead the patient to consult another dentist. An orthopantomography (OPT) (Figure 1A) was performed and showed a metallic foreign body (steel round bur) inside the left maxillary sinus.

The patient was then referred to the department of Otorhinolaryngology for further investigations and management. Clinical evaluation showed a persistent left-sided facial and maxillary pain and mild swelling regarding the maxillary area. There was neither nasal obstruction nor purulent nasal discharge. On clinical examination of the oral cavity showed a defect at the level of the upper first left molar without signs of fistula. Nasal endoscopic examination of the nasal cavity

showed hyperemia of the nasal mucosa on both sides, without purulent discharge on both sides. The remaining clinical examination was normal. Radiological evaluation by computed tomography (CT-Scan) of the head showed total opacification of the left maxillary sinus. Inside it and on its floor, a metallic foreign body of 2.5 cm in length was visible together with signs of bony defect where the implant had been removed (Figure 1B-D). No other radiological complications were found. The biological examination showed a mild inflammatory syndrome.

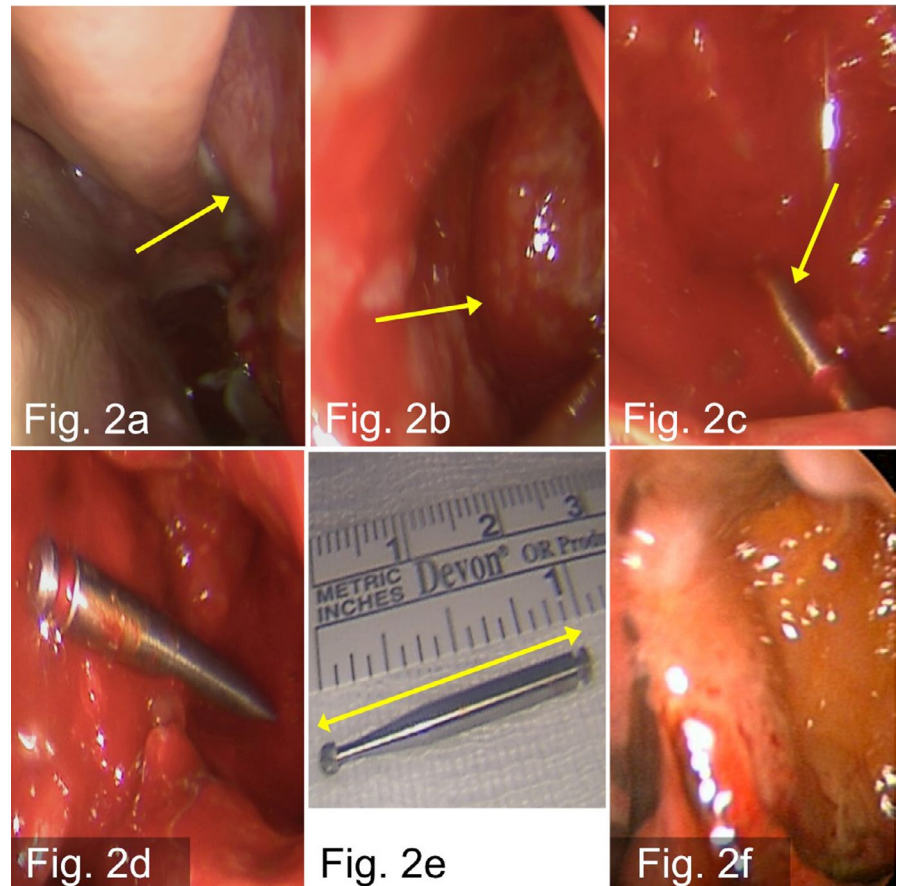
The patient underwent surgical management under general anesthesia via transnasal endoscopic approach with a middle meatotomy on the left side and total drainage of the purulent collection inside the maxillary sinus (Figure 2A,B). The foreign body in the maxillary sinus was located using the “image-guided navigation system” with optics 0° and 30° (Figure 2C,D). The foreign body was then completely removed (Figure 2E,F). No excessive intraoperative bleeding nor any other complications were recorded. Due to the spontaneous closure of the defect regarding the upper left molar by soft tissue and absence of residual fistula, no additional procedure was performed at this level. The left nostril was packed using a nonabsorbable packing.

After surgery, the patient was kept on observation at the ward for 2 days with an intravenous antibiotic of Amoxicillin 1.2 g thrice daily. There were no surgery-related



**FIGURE 1** A, OPT panoramic view shows a metallic foreign body at the floor of the left maxillary sinus. B, CT-Scan image, sagittal view shows total opacification with metallic foreign body in the left maxillary sinus. C, CT-Scan image, coronal view shows the bony defect between the maxillary sinus and the oral cavity at the level of the first upper molar on the left side. D, CT-Scan image, axial view shows the position and extension of the metallic foreign body in the maxillary sinus

**FIGURE 2** A, intraoperative endoscopic view of the nasal cavity in the left side, shows discharge of purulent secretions from the ostium of the maxillary sinus. B, intraoperative endoscopic view of the left-sided maxillary sinus after performing middle meatotomy with total drainage of the sinus. C, Intraoperative endoscopic view showing the location of the metallic foreign body in the maxillary sinus. D, intraoperative endoscopic view showing complete removal of the foreign body from the maxillary sinus. E, intraoperative image shows the size of the metallic foreign body. F, postoperative endoscopic view shows the healing of the maxillary sinus mucosa



complications. The nasal packing was removed 2 days after surgery, and the patient was discharged with oral antibiotic for an additional 7 days with nasal saline irrigations.

On follow-up, the patient showed complete pain remission and good healing of the maxillary sinus mucosa.

### 3 | DISCUSSION

Presence of foreign bodies into paranasal sinuses remains rare, most often related to iatrogenic causes (60%) or accidents (25%). The maxillary sinus is the most commonly affected site (75%), followed by the frontal sinus (18%).<sup>4</sup>

Maxillary molar or premolar tooth extractions are considered the most common causes of oroantral communications.<sup>5</sup> This is the reason why a careful inspection for an eventual oroantral communication, using the Valsalva maneuver, especially after maxillary molar and premolar tooth extractions or endodontic surgery performed on maxillary teeth, is recommended.

It is known that the presence of foreign bodies in a sinus induces chronic physical and chemical irritation of the mucosa; promotes some degree of ciliary insufficiency and leads to secondary infections,<sup>6</sup> reason why, the removal of all foreign bodies in the paranasal sinus is widely recommended. Regarding the maxillary sinus, small foreign bodies can be

expelled spontaneously.<sup>7</sup> Several surgical techniques have been reported for the removal of foreign bodies in the maxillary sinus such as transnasal endoscopic approach, oral anastomy via the anterior maxillary wall, mainly by means of the Caldwell-Luc procedure or a combined approach in some cases.<sup>8</sup> The choice of the appropriate approach depends on multiple factors, such as size and location of the foreign bodies in the sinus.

A transoral approach to the maxillary sinus may be indicated in cases of small foreign bodies without sinusitis because of the limited field of vision and accessibility.<sup>9</sup> The transnasal endoscopic approach is minimally invasive and carries more advantages such as allowing for simultaneous treatment of sinusitis involving the maxillary, ethmoidal, or frontal sinuses.<sup>10</sup>

Accurate management of odontogenic foreign body-induced maxillary sinusitis requires not only total removal of the foreign body, but also closure of any oroantral communications by establishing a physical barrier between the oral cavity and the maxillary sinus. Small defects less than 5 mm usually heal spontaneously, defects larger than 5 mm need to be closed and several surgical techniques have been described.<sup>11</sup>

Simuntis et al,<sup>11</sup> report an incidence of oroantral communications as a complication of dental extractions in the posterior maxillary area of up to 80% of cases. In a study of 121

cases of odontogenic maxillary sinusitis reported by Mattias et al,<sup>12</sup> bone substitutes and root canal filling were the most frequently detected foreign bodies in the maxillary sinus.

In our case reported above, the nature of the foreign material identified in the maxillary sinus after the dental surgery was totally unexpected. And to the extent of our knowledge, a similar odontogenic foreign body impaction into the maxillary sinus has yet to be reported in the literature. We do believe that the transnasal endoscopic approach provides a better exposure of the maxillary sinus, is minimally invasive and allows simultaneous conservative treatment of the sinus mucosa.

## 4 | CONCLUSION

Foreign bodies' impaction into paranasal sinus remains a rare entity and most often affects the maxillary and frontal sinus.

Odontogenic substances are the most common foreign bodies into the maxillary sinus.

Dental manipulation of the first upper molar teeth carries a higher risk of oroantral fistula and required careful inspection using the Valsalva maneuver.

Refractory facial pain after dental manipulation of the upper maxillary teeth warrants imaging by OPT or CT-scan.

Foreign body-induced maxillary sinusitis requires appropriate surgical management.

## ACKNOWLEDGMENT

The authors declare no acknowledgment.

## CONFLICT OF INTEREST

The authors declare no conflict of interest.

## AUTHOR CONTRIBUTIONS

BH: involved in corresponding author, reporting, and design. PT: involved in draft and revision. J-PB: involved in data acquisition. SB: involved in reporting.

## PATIENT CONSENT

The patient consent is obtained.

## DATA AVAILABILITY STATEMENT

The authors declare the availability of data.

## ORCID

Bassel Hallak  <https://orcid.org/0000-0002-1359-4325>

## REFERENCES

1. Kapila BK, Lata J. A rare foreign body impaction: a case report. *Quintessence Int.* 1998;29(9):583.
2. Liston PN, Walters RF. Foreign bodies in the maxillary antrum: a case report. *Aust Dent J.* 2002;47(4):344.
3. Lima MM, Moreira CA, Da Silva VC, De Freitas MR. 34 Self-inflicted foreign bodies in the maxillary sinus. *Braz J Otorhinolaryngol.* 2008;74(6):948.
4. Krause HR, Rustemeyer J, Grunert RR. Foreign body in paranasal sinuses. *Mund Kiefer Gesichtschir.* 2002;6(40):4.
5. Scattarella A, Ballini A, Grassi FR, et al. Treatment of oroantral fistula with autologous bone graft and application of a non-resorbable membrane. *Int J Med Sci.* 2010;7(267):71.
6. Pagella F, Emanuelli E, Castelnuovo P. Endoscopic extraction of a metal foreign body from the maxillary sinus. *Laryngoscope.* 1999;109(2):339.
7. Dimitrakopoulos I, Papadaki M. Foreign body in the maxillary sinus. Report of an unusual case. *Quintessence Int.* 2008;39(8):698.
8. Chiapasco M, Felisati G, Maccari A, Borloni R, Gatti F, Di Leo F. The management of complications following displacement of oral implants in the paranasal sinuses: a multicenter clinical report and proposed protocols. *Int J Oral Maxillofac Surg.* 2009;38(12):1273.
9. Gonzalez-Gracia A, Gonzalez-Garcia J, Diniz-Freitas M, Garcia-Garcia A, Bullon P. Accidental displacement and migration of endosseous implants into adjacent craniofacial structures: a review and update. *Med Oral Patol Oral Cir Bucal.* 2012;17(5):769.
10. Felisati G, Lozza P, Chiapasco M, Borloni R. Endoscopic removal of an unusual foreign body in the sphenoid sinus: an oral implant. *Clin Oral Implants Res.* 2007;18(6):776.
11. Simuntis R, Kubilius R, Vaitkus S. Odontogenic maxillary sinusitis: a review. *Stomatologija.* 2014;16(2):39.
12. Matthias Z, Timo D, Matthias P, et al. Odontogenic sinusitis maxillaries: a retrospective study of 121 cases with surgical intervention. *J Craniomaxillofac Surg.* 2017;45(4):520.

**How to cite this article:** Hallak B, Teiga P, Bühler J-P, Bouayed S. Unexpected foreign body induced refractory maxillary sinusitis. *Clin Case Rep.* 2021;9:2185–2188. <https://doi.org/10.1002/ccr3.3976>