



Contents lists available at ScienceDirect

International Journal of Surgery Case Reports

journal homepage: www.casereports.com

Isolated comminuted trapezium fracture: A case report and literature review

Aidin Arabzadeh, Farzad Vosoughi *

Orthopedic Surgery Department, Imam Khomeini Hospital, Tehran University of Medical Sciences, Tehran, Iran

ARTICLE INFO

Article history:

Received 6 December 2020
 Received in revised form
 21 December 2020
 Accepted 21 December 2020
 Available online 24 December 2020

Keywords:

Trapezium bone
 Carpometacarpal joints
 Range of motion
 Case report

ABSTRACT

INTRODUCTION AND IMPORTANCE: Trapezium, as a carpal bone positioned at the distal row, is often associated with other wrist injuries such as distal radius fracture. Isolated trapezium fracture, especially in a comminuted form, rarely occurs. There are only six reports of isolated comminuted trapezium fractures in the literature to the best of our knowledge.

CASE PRESENTATION: We present a case with an isolated comminuted trapezium fracture presenting pain in his thenar eminence and thumb motion limitation. He was treated by Open Reduction and Internal Fixation (ORIF) with the K wire pin.

CLINICAL DISCUSSION: We searched the published related studies and summarized the signs and symptoms of patients presented with trapezium fracture. The most common presentation of trapezium fracture include pain/tenderness at the base of the first metacarpal bone, pain/tenderness at the snuffbox area and 1st digit motion limitation. The treatment options described in the literature for isolated comminuted trapezium fracture are also presented. Open reduction and fixation with pin is the most common treatment mentioned in the literature. The priority is restoring the scaphotrapezium and trapeziometacarpal joint congruency to save the 1st digit range of motion.

CONCLUSION: Comminuted trapezium fracture may happen following either low energy (like our patient) or high energy trauma. This paper highlights the fact that even a comminuted trapezium fracture can be easily missed. Regardless of the trauma mechanism (high energy versus low energy trauma), a high index of suspicion and delicate work up would be necessary in order not to miss this type of fracture.

© 2020 The Authors. Published by Elsevier Ltd on behalf of IJS Publishing Group Ltd. This is an open access article under the CC BY-NC-ND license (<http://creativecommons.org/licenses/by-nc-nd/4.0/>).

1. Introduction

Among different carpal bones, those placed at the proximal row, especially scaphoid, are more prone to fracture. As part of the carpal bones seated in the distal row, trapezium fracture accounts for 4% of carpal fractures [1]. It occurs following either a high-energy trauma like a motor vehicle accident or a low-energy trauma like falling on an outstretched hand. Trapezium fracture is accompanied with other simultaneous upper extremity injuries (i.e., distal radial fracture, Bennett's, or Rolando fracture) in 80% of cases [2,3]. Isolated trapezium fracture, especially in comminuted form, is a rare clinical entity. Due to the low prevalence and difficulty in diagnosing the isolated trapezium fracture by routine imaging, high clinical suspicion, careful history taking, physical examination, and imaging interpretation are needed to avoid missing a trapezium fracture. Delay in the diagnosis may result in degeneration at trapeziometacarpal joint, thumb weakness, and limitation in

pinching or grasping [4]. This paper reports a young patient with an isolated comminuted trapezium fracture. It then further delineates the features of this rare type of injury, our management, and its clinical and radiologic outcomes. This report is presented according to the SCARE guideline [5].

2. Presentation of case

Our patient was a thirty-three-year-old right-handed military man complaining of pain in the thenar eminence and snuff box area of his left hand. His symptoms started following a fall on an outstretched hand five days before visiting our clinic. His past medical and family history, surgical and social history were unremarkable. He did not take any medication. At first, he assumed that the trauma is insignificant. However, as the symptoms persisted, he visited our clinic for further workup. Upon examination, he had limited left thumb range of motion and a local tenderness and swelling at the base of his left first metacarpal bone. Active and passive thumb opposition, abduction, adduction, and flexion were painful. We considered first metacarpal fracture (e.g. Bennett's fracture) and carpal fracture (mainly scaphoid and trapezium fracture) as the differential diagnosis. On plain X ray imaging and Computed Tomography (CT) scan, comminuted trapezium fracture, and first

* Corresponding author at: Joint Reconstruction Research Center, Orthopedic surgery department, Imam Khomeini Hospital, End of Keshavarz Blvd, Tehran 1419733141, Iran.

E-mail addresses: aidin.medico@gmail.com (A. Arabzadeh), Farzadvosoughi@gmail.com (F. Vosoughi).

<https://doi.org/10.1016/j.ijscr.2020.12.072>

2210-2612/© 2020 The Authors. Published by Elsevier Ltd on behalf of IJS Publishing Group Ltd. This is an open access article under the CC BY-NC-ND license (<http://creativecommons.org/licenses/by-nc-nd/4.0/>).

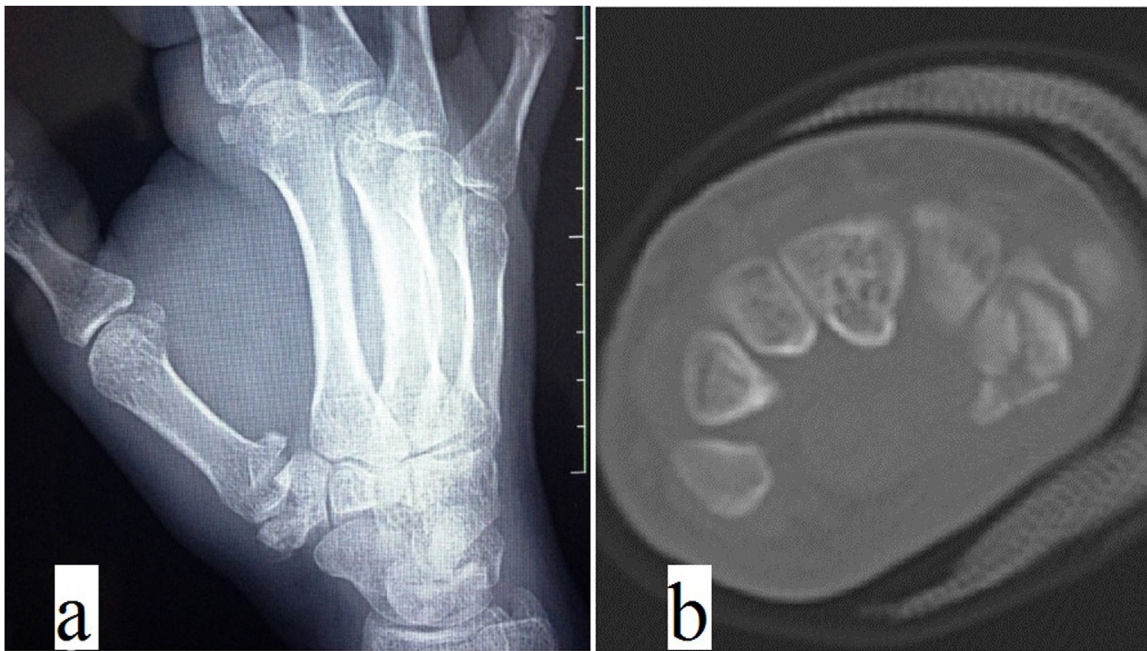


Fig. 1. Preoperative radiograph and CT scan images show the comminution of trapezium fracture.

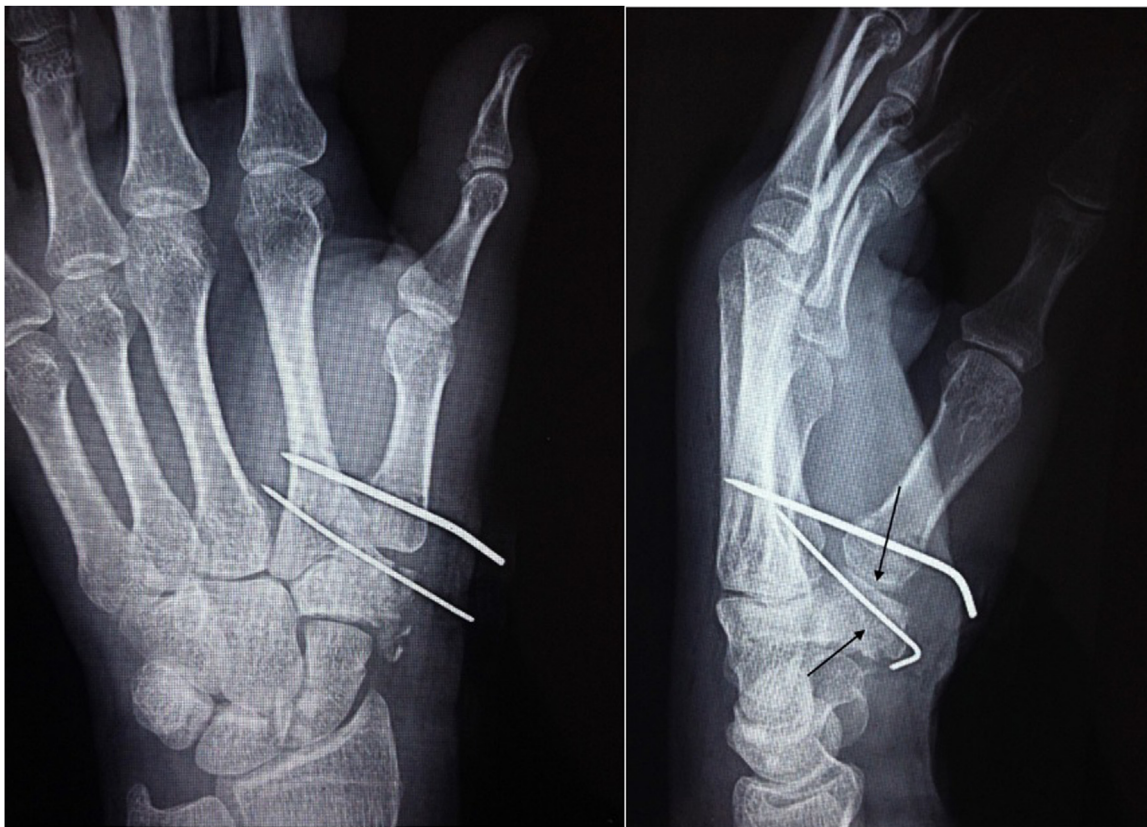


Fig. 2. Postoperative radiographs show a suitable reduction of the 1st carpometacarpal articular surface. Black arrows display the fracture line.

carpometacarpal joint incongruence were evident [Fig. 1]. All other carpal bones were intact.

The patient was hospitalized at our center (tertiary trauma center) and scheduled for surgery. The patient underwent general anesthesia and the procedure was conducted while he was placed in supine position. Tourniquet was applied during the surgi-

cal procedure. The surgical operator was orthopedic hand surgeon performing of at least 20 hand surgeries per month during the previous 2 years. As the close reduction under C-Arm imaging was not successful, the patient underwent Open Reduction and Internal Fixation (ORIF) surgery through the Wagner approach. First, only the largest fractured segment was fixed with a 1 mm K wire pin so that

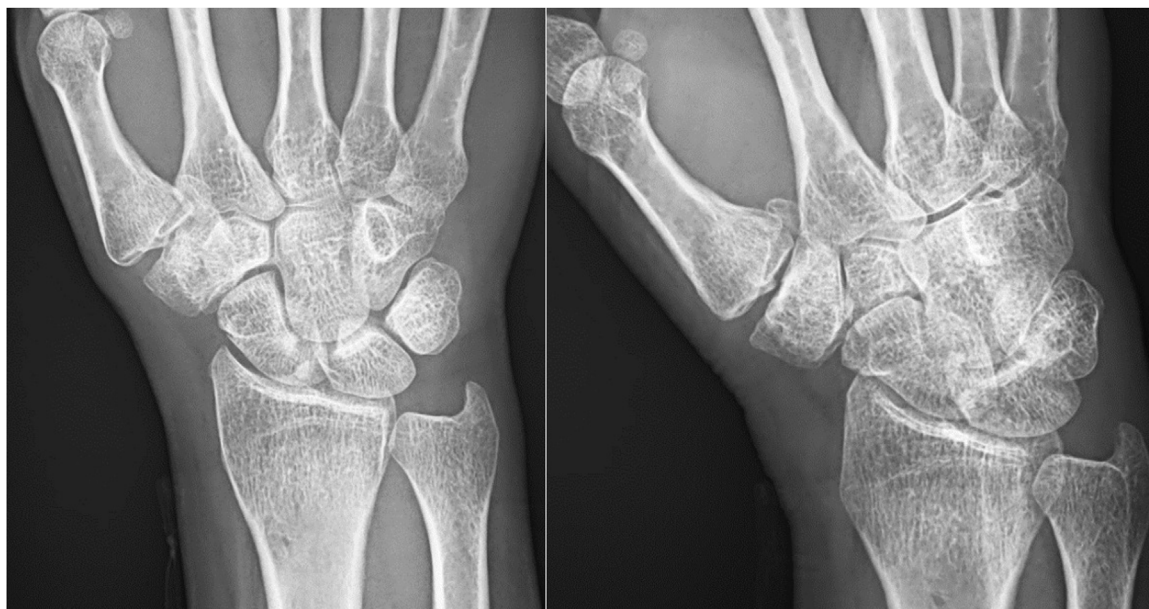

Fig. 3. Postoperative radiographs after sixty-six months. Note the excellent congruency of the carpometacarpal joint without considerable degenerative changes.

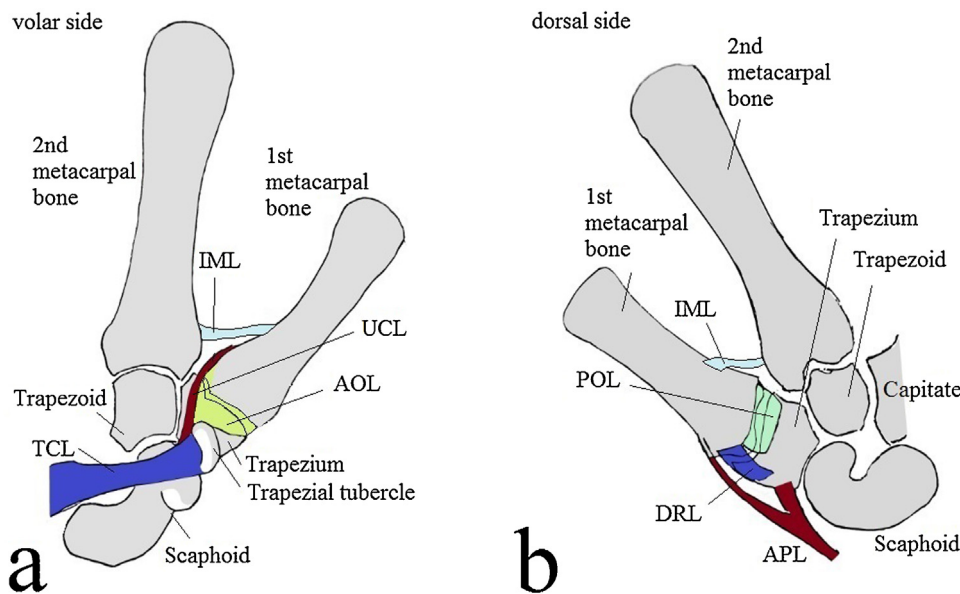


Fig. 4. Stabilizing Ligaments of the trapeziometacarpal joint. a: Anterior view, b: Posterior view. Abbreviations: IML, intermetacarpal ligament; UCL, ulnar collateral ligament; AOL, anterior oblique ligament; TCL, transverse carpal ligament; POL, posterior oblique ligament; DRL, dorsoradial ligament; APL, abductor pollicis longus.

the 1st carpometacarpal (CMC) surface was anatomically restored. Since the bone defect was insignificant, we preferred to use small fractured segments instead of the bone graft as a void filler. Then the first metacarpal to the second metacarpal fixation was done using a 1.5 mm K wire pin. Finally, a short thumb spica cast was applied to immobilize the first CMC joint.

The operation time was 70 min and blood loss was insignificant. Post-operative radiographs showed satisfactory fracture reduction and CMC joint [Fig. 2]. His recovery was uneventful and no post-operative complication was noticed. He was discharged after 2 days. At six-week post-surgery, the cast was discontinued, the pins were removed, and movement exercises were started. Follow-ups were done every three months afterwards. At the end of the 12th month, our patient regained full range of wrist and thumb motion with sufficient power. At the last visit 66 months after

surgery, He was satisfied (quick Disabilities of the Arm, Shoulder and Hand (quick DASH) questionnaire, score of zero), and radiographs showed complete fracture union with inconsiderable adjacent articular degenerative changes [Fig. 3].

3. Discussion

The thumb has a unique role in the hand function, including grasping an object, writing, and drawing. The saddle shape of the trapeziometacarpal joint and its stabilizing ligaments, including the anterior oblique ligament, posterior oblique ligament, intermetacarpal ligament, and dorsoradial ligament, have a role in providing the first ray with adequate mobility and stability needed for performing activities of everyday life delicately [Fig. 4] [6,7].

Table 1
Signs and symptoms of the trapezium fractures reported in the literature.

	Literature reporting the mentioned sign/symptom
Symptoms	
Pain and swelling of the first metacarpal base	Horch et al. [13], Ramoutar et al. [7], Roger et al. [8], Beekhuizen et al. [2]
Persistent pain in the anatomical snuffbox	Beekhuizen et al. [2]
Diffuse pain and swelling in the thumb	Kohyama et al. [6]
Pain exacerbated by opposition	Cordrey et al. [4], Horch et al. [13]
Signs	
Tenderness of the first metacarpal base	Horch et al. [13], Ramoutar et al. [7], Roger et al. [8]
Diffuse tenderness of the thumb	Kohyama et al. [6]
Subcutaneous prominence at dorsoradial area	Kose et al. [10]
Deformity in thenar area	Alonso et al. [15]
Tenderness at thenar area	Kose et al. [10]
Tenderness over the anatomical snuffbox	Cordrey et al. [4], Beekhuizen et al. [2]
Multidirectional limitation in thumb motion	Kose et al. [10], Kohyama et al. [6]
Inability to sustain a pinch	Cordrey et al. [4]

The isolated trapezium fracture may be difficult to diagnose as the adjacent carpal bones' shadow obscure the fracture line in routine wrist X rays. Meanwhile, a neglected trapezium fracture may lead to degenerative joint disease in the adjacent first CMC joint, causing inevitable thumb motion limitation. Therefore, a high index of suspicion should be considered in any patient with pain in the thenar and snuffbox area [Table 1] [1,8]. Complimentary imaging, including Bett's view (true lateral view of the Trapeziometacarpal joint), Robert's view (true AP view of the Trapeziometacarpal joint), and CT scan help physician to rule out possible Trapezium fracture [9,10].

According to Walker et al., trapezium fracture can be classified based on its pattern and involvement of either the trapeziometacarpal or scaphotrapezial joints [Fig. 5] [11]. Type 1 affects neither of the mentioned joints and can be managed non-operatively with a thumb spica cast for six weeks [2]. Type 4 and 5 involve both joints and have a worse prognosis. Most reported cases belong to type 2a,2b, and 4 [6,12]. However, our patient had a comminuted fracture (type 5).

Regarding type 2–4, displaced fractures (>2 mm articular step off) or those with trapeziometacarpal joint subluxation need to be reduced and fixed with K wires (for small fracture fragments) or headless screws (for fixation of larger fracture fragments) [3,11,13].

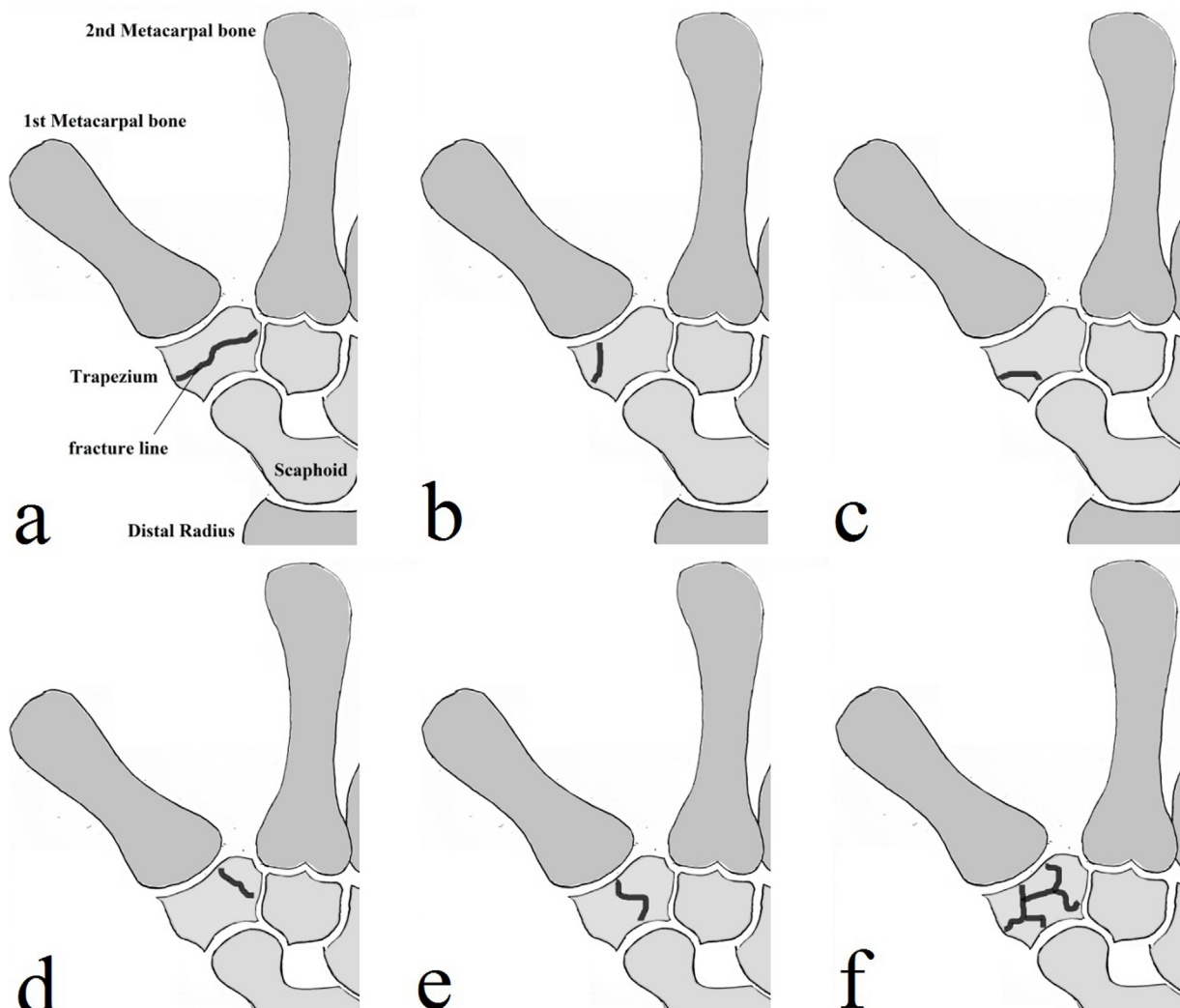


Fig. 5. Walker classification for Trapezium fracture. a: Horizontal fracture (type I), b: Radial tuberosity fracture through the CMC joint (type IIa), c: Radial tuberosity fracture through the Scaphotrapezial joint (type IIb), d: Ulnar tuberosity fracture (type III), e: Vertical fracture (type IV), d: Comminuted fracture (type V).

Table 2
Reported cases of comminuted trapezium fracture in the literature.

Study	Age of patient (Y/O)	Mechanism of injury	Management	Follow up (months)	Reported results
Walker et al. [11]	17	MVA	ORIF with fat interpositional arthroplasty	6	Full painless ROM
Gelberman et al. [14]	Not reported	Not reported	Oblique traction + Banjo outrigger splint	2	Useful, painless ROM
McGuigan et al. [3]	58	Falling	ORIF with K wire	48	Painless, Very satisfied
Alonso et al. [15]	23	MVA	ORIF with K wire + bone graft	70	Painless, Very satisfied
	67	Falling	CRIF with K wire	6	Painless, completely satisfied
Kohyama et al. [6]	20	Direct trauma	ORIF with K wire + β tricalcium phosphate	24	Full painless ROM

Abbreviations: MVA, Motor vehicle accident; ORIF, Open reduction and internal fixation; CRIF, Close reduction and internal fixation; ROM, Range of motion.

In contrast to scaphoid fracture, the risk of non-union in trapezium fracture is low due to its rich vascular supply [2].

Only a few reports exist in the literature about managing the isolated comminuted trapezium fracture [Table 2]. Traction, close reduction, or open reduction with K wire fixation are suggested for stabilizing this type of fracture, all with satisfactory results. Gelberman et al. proposed a traction system for the trapezium fracture introduced previously for Bennett's fracture. They applied an oblique K wire pin and rubber band to exert traction [14]. Alonso et al. reported a case with comminuted trapezium fracture and first CMC dislocation [15]. They managed the fracture with close reduction and fixation with two k wires. The first pin connected the first and second metacarpals base, and the second pin traversed through the first metacarpal base and larger fractured Trapezial segment. McGuigan et al. reported 5 cases of comminuted trapezium fracture, two of which were isolated. They advocated ORIF with or without graft to restore articular surface [3]. Kohyama et al. also used ORIF (via a lateral approach) for treating comminuted trapezium fractures [6].

One of the main issues about our case was his delayed referral highlighting that a localized pain in the snuffbox should never be underestimated. Since our patient had little compliance to follow the medical orders, we decided not to manage him with a traction-only technique described by Gelberman. The fragment displacement in our case failed to be reduced closely. Thus we had to open the fracture site for reducing the fracture and restoring the first CMC joint congruence. Due to the fragments' small size, we selected the K wire fixation technique to stabilize the reduction. We believed that the use of bone graft was not necessary for filling the little bone defects. Fortunately, our patient was satisfied and regained his normal thumb function at the final follow up (66 months postoperatively). There are few reports about isolated comminuted trapezium fracture. Therefore, we think this case report with its relative long-term follow-up and review of the literature to be beneficial in correctly diagnosing and managing Trapezium fracture. However, higher level of evidence with larger sample size pave the way to a better understanding of Trapezium fracture treatment.

4. Conclusion

Trapezium fracture is usually accompanied by other upper extremity and wrist injuries; however, it may also occur as an isolated entity. Persistent pain in the anatomical snuffbox or thenar eminence following a hand trauma should alert the physician to consider soft tissue injury diagnosis only after excluding the diagnosis of scaphoid or trapezium fracture. Based on the review of published literature and our experience, ORIF even without using graft seems to be a plausible choice for managing comminuted trapezium fracture. Further studies, however, are needed to obtain more concrete evidence about the mentioned treatment.

Declaration of Competing Interest

The authors report no declarations of interest.

Sources of funding

The authors had no source of funding or study sponsor in the collection, analysis and interpretation of data; in the writing of the manuscript; and in the decision to submit the manuscript for publication.

Ethical approval

This case report was exempted from ethical approval from the institution.

Consent

Written informed consent was obtained from the patient for publication of this case report and accompanying images. A copy of the written consent is available for review by the Editor-in-Chief of this journal on request.

Author contribution

A.A supervised the study, revised the manuscript and performed the procedure. F.V prepared the manuscript, reviewed the literature and drew the schematic figures. All authors approved the manuscript to be published, and agree to be accountable for all aspects of the work in ensuring that questions related to the accuracy or integrity of any part of the work are appropriately investigated and resolved.

Registration of research studies

Not applicable.

Guarantor

Aidin Arabzade was the guarantor of the study.

Provenance and peer review

Not commissioned, externally peer-reviewed.

Acknowledgement

This report was approved by the ethical committee of our institution. Written informed consent was obtained from the patient, and patient anonymity was preserved.

References

- [1] L.W. Catalano 3rd, S.V. Minhas, D.J. Kirby, Evaluation and management of carpal fractures other than the scaphoid, *J. Am. Acad. Orthop. Surg.* (June) (2020), Epub 2020/06/06.
- [2] S.R. Beekhuizen, C.R. Quispel, J. Jasper, R.L.M. Deijkers, The uncommon trapezium fracture: a case series, *J. Wrist Surg.* 9 (February (1)) (2020) 63–70, Epub 2020/02/07.
- [3] F.X. McGuigan, R.W. Culp, Surgical treatment of intra-articular fractures of the trapezium, *J. Hand Surg.* 27 (July (4)) (2002) 697–703, Epub 2002/07/20.
- [4] L.J. Cordrey, M. Ferrer-Torells, Management of fractures of the greater multangular. Report of five cases, *J. Bone Joint Surg. Am.* (October) (1960), 42-a:1111–8. Epub 1960/10/01.
- [5] R.A. Agha, T. Franchi, C. Sohrabi, G. Mathew, A. Kerwan, The SCARE 2020 guideline: updating consensus Surgical CAse REport (SCARE) guidelines, *Int. J. Surg.* (November) (2020), Epub 2020/11/13.
- [6] S. Kohyama, T. Tanaka, A. Ikumi, Y. Totoki, K. Okuno, N. Ochiai, Trapezium fracture associated with thumb carpometacarpal joint dislocation: a report of three cases and literature review, *Case Rep. Orthop.* 2018 (2018), 2408708, Epub 2018/04/24.
- [7] D.N. Ramoutar, C. Katevu, A.G. Titchener, A. Patel, Trapezium fracture - a common technique to fix a rare injury: a case report, *Cases J.* 2 (September) (2009) 8304, Epub 2009/11/18.
- [8] J. Roger, L. Mathieu, F. Mottier, F. Vigouroux, F. Chauvin, F. Rongi eras, Trapeziometacarpal joint dislocation complicated by a trapezium fracture: a case report and literature review, *Hand Surg. Rehabil.* 35 (September (4)) (2016) 288–291, Epub 2016/10/27.
- [9] D. Samson, M. Jones, A. Mahon, Non-union of the trapezium: rare consequence of a rare injury, *J. Surg. Case Rep.* 2018 (April (4)) (2018), rjy076, Epub 2018/05/17.
- [10] O. Kose, M. Keskinbora, F. Guler, Carpometacarpal dislocation of the thumb associated with fracture of the trapezium, *J. Orthop. Traumatol.* 16 (June (2)) (2015) 161–165, Epub 2014/03/29.
- [11] J.L. Walker, T.L. Greene, P.A. Lunseth, Fractures of the body of the trapezium, *J. Orthop. Trauma* 2 (1) (1988) 22–28, Epub 1988/01/01.
- [12] G. Nigris, G. Falzarano, A. Medici, S. McCabe, G. Predrag, M. Meccariello, et al., A rare case of isolated trapezium fracture in motorcycle polytrauma patient in emergency department, *J. Acute Dis.* (2016), 2016 04/01;5.
- [13] R. Horch, A new method for treating isolated fractures of the os trapezium, *Arch. Orthop. Trauma Surg.* 117 (3) (1998) 180–182, Epub 1998/04/01.
- [14] R.H. Gelberman, R.M. Vance, G.S. Zakaib, Fractures at the base of the thumb: treatment with oblique traction, *J. Bone Joint Surg. Am.* 61 (March (2)) (1979) 260–262, Epub 1979/03/01.
- [15] L. Alonso, J. Couceiro, Comminuted fracture of the body of the Trapezium and thumb carpometacarpal dislocation: a particular pattern, *Surg. J. (N. Y.)* 4 (January (1)) (2018), e34–e6. Epub 2018/03/14.

Open Access

This article is published Open Access at [sciencedirect.com](https://www.sciencedirect.com). It is distributed under the [IJSCR Supplemental terms and conditions](#), which permits unrestricted non commercial use, distribution, and reproduction in any medium, provided the original authors and source are credited.