


# Comparison of Sleeve Lobectomy for Lung Cancer Using Mini-Thoracotomy and an Optimized Robot-Assisted Technique

Technology in Cancer Research & Treatment  
 Volume 20: 1–9  
 © The Author(s) 2021  
 Article reuse guidelines:  
[sagepub.com/journals-permissions](https://sagepub.com/journals-permissions)  
 DOI: 10.1177/15330338211051547  
[journals.sagepub.com/home/tct](https://journals.sagepub.com/home/tct)  


Tao Shaolin\*, Feng Yonggeng\*, Kang Poming, Mei Longyong, Shen Cheng, Fang Chunshu, Wu Licheng, Tan Qunyou , and Deng Bo 

## Abstract

**Objective:** To evaluate the clinical significance of an optimized approach to improve surgical field visualization and simplify anastomosis techniques using robotic-assisted sleeve lobectomy for lung or bronchial carcinoma. **Method:** A total of 26 consecutive patients who underwent sleeve lobectomy between January 2017 and April 2020 were enrolled in the study. The cohort included 11 cases of robotic-assisted surgery (RAS group) and 15 cases of mini-thoracotomy (MT group). RAS was performed via an exclusive optimized approach utilizing the “3 to 4-6 to 8/9” four-port technique. Retrieved demographical and clinical data included operation time, anastomosis time, blood loss, chest drainage time and volume, postoperative pain scores, complications, white blood cell (WBC) levels, and duration of hospital stay and follow-up. **Results:** No cases of perioperative death were recorded. Compared to MT group, the RAS group had a similar anastomosis time ( $30.82 \pm 6.08$  vs  $33.20 \pm 7.73$  min, respectively,  $p > 0.05$ ) and shorter operation time ( $189.73 \pm 36.41$  vs  $225.33 \pm 38.19$  min, respectively,  $p < 0.05$ ). The RAS group had lower pain scores ( $4.23 \pm 0.26$  vs  $4.91 \pm 0.51$ ,  $p < 0.05$ ), lower levels of WBC ( $p < 0.05$ ), and no anastomotic complications postoperatively. The RAS and MT groups demonstrated a successful bronchus reconstruction with low risk of angulation (1/11 vs 1/15,  $p > 0.05$ ) and satisfactory disease-free survival (eight cases, 72.73% and 12 cases, 80%, respectively). **Conclusion:** The optimized approach to RA sleeve lobectomy is convenient and efficient and provides satisfactory clinical outcomes. Further study with a large sample size and evaluation of long-term survival are warranted. **Key points:** (i) we present a novel, convenient, and efficient approach for robotic-assisted sleeve lobectomy, ie, “3 to 4-6 to 8/9” four-port technique. The optimized approach for RA sleeve lobectomy is convenient and efficient and provides satisfactory clinical outcomes; (ii) details for the “3 to 4-6 to 8/9” four-port method: the assistant port was located at the fourth intercostal space. The 1-cm camera port was inserted at the sixth intercostal space in the posterior axillary line. The 0.5-cm da Vinci ports of the instrument arms were placed at the third intercostal space in the anterior axillary line and the eighth or ninth intercostal space in the posterior axillary line. The patient cart was inserted from the back of the patient’s head and shoulders at 75° to the longitudinal line.

## Keywords

sleeve lobectomy, RAS-assisted thoracic surgery, mini-thoracotomy surgery

## Abbreviations

RAS, robotic-assisted surgery; MT, mini-thoracotomy; WBC, white blood cell

Received: July 27, 2021; Revised: August 31, 2021; Accepted: September 17, 2021.

## Introduction

Sleeve lobectomy is a frequently used operation for central lung cancer or tracheal/bronchial tumor treatment. It allows for complete tumor resection, maximized preservation of residual pulmonary function, and improvement of life quality, especially for those who cannot tolerate pneumonectomy due to poor cardiopulmonary function.<sup>1–3</sup> However, sleeve lobectomy using minimally invasive surgery is still challenging.

Department of Thoracic Surgery, Institute of Surgery Research, Daping Hospital, Army Medical University, Chongqing 400042, China

\*contributed equally

### Corresponding Author:

Bo Deng, M.D., PhD, Changjiang Branch St, 10#, Yuzhong District, Chongqing city, 400042, China.  
 Email: dengbo@tmmu.edu.cn



Creative Commons Non Commercial CC BY-NC: This article is distributed under the terms of the Creative Commons Attribution-NonCommercial 4.0 License (<https://creativecommons.org/licenses/by-nc/4.0/>) which permits non-commercial use, reproduction and distribution of the work without further permission provided the original work is attributed as specified on the SAGE and Open Access page (<https://us.sagepub.com/en-us/nam/open-access-at-sage>).

With the development of endoscopic technology and artificial intelligence, robotic-assisted surgery (RAS) systems have been utilized for sleeve lobectomies.<sup>4,5</sup> Although their results are encouraging, a longer learning curve, lack of tactile feedback to the operator, and tricky bronchial anastomosis RAS techniques are all associated issues that remain unresolved.<sup>6-8</sup> Some current studies have pointed out that visual compensation may be a better alternative to the tactile feedback once the surgeon is proficient.<sup>8,9</sup> Therefore, we created a new modified approach to RA sleeve lobectomy optimization in order to improve surgical field visualization and simplify anastomosis techniques. The study retrospectively reviewed and analyzed the clinical data for sleeve lobectomy using the optimized RAS and mini-thoracotomy (MT), especially focusing on the efficacy, safety, and postoperative outcomes.

## Patients and Methods

### Patients

The retrospective study included 26 consecutive patients between January 2017 and April 2020. The cohort included 11 cases (10 males, one female, mean age,  $54.82 \pm 9.21$  years) of sleeve lobectomy using RAS (RAS group) and 15 cases (13 males, two females, mean age,  $56.53 \pm 8.25$  years) of sleeve lobectomy using MT (MT group). Systemic examinations including enhanced chest computed tomography (CT), head magnetic resonance imaging (MRI), abdominal B-ultrasound, whole-body bone scan (or positron emission tomography [PET]-CT), fiberoptic bronchoscopy, electrocardiogram, and pulmonary, hepatic, and renal function evaluations were administered for all patients prior to surgery. All patients who agreed to participate in the study signed an informed consent form. This retrospective study was approved by the Ethics Committee of Army Medical Center of PLA (Daping Hospital, Chongqing City, P.R. China) on September 26, 2019 [IRB: 2019 to 081].

Inclusion criteria included the following: (i) central lung tumors that have moved to the lobar bronchus; (ii) sufficient bronchus for anastomosis; (iii) no invasion of blood vessels; (iv) no obvious calcification in hilar and mediastinal lymph nodes; (v) relatively abnormal physical function of the heart, lung, liver, and kidney; and (vi) no other absolute contraindications.

Exclusion criteria were as follows: (i) invasion of multiple lobes requiring pneumonectomy; and (ii) invasion of blood vessels or obvious calcification in hilar and mediastinal lymph nodes.

### Surgical Methods

#### (1) Anesthesia, position, and port approaches

The patient was positioned in the lateral decubitus position after general endotracheal anesthesia was induced using a double-lumen tube to facilitate lung isolation.

In the RAS group (Da Vinci Si Robot Surgical System [Intuitive Surgical, Sunnyvale, CA, USA], our exclusive optimized “3-4-6-8/9” four-port technique was performed according to a previously published method.<sup>10</sup> Lap protectors of the same size were placed in all incisions prior to port insertion as follows [Figure 1a]: [i] the assistant port was located at the fourth intercostal space at  $\sim 4$  cm outward from the midclavicular line; [ii] the 1-cm camera port was inserted at the sixth intercostal space in the posterior axillary line; and [iii] the 0.5-cm da Vinci ports for instrument arms were placed at the third intercostal space in the anterior axillary line and the eighth or ninth intercostal space in the posterior axillary line. The patient cart entered from the back of the patient’s head and shoulders at  $75^\circ$  to the longitudinal line. The assistant was located at the ventral side of the patient in order to install the endoscope and instruments for linkage [docking process; Figure 1a].

In the MT group, the seventh intercostal space in the midaxillary line was selected as the endoscope port (1 cm), and the lateral incision (15-20 cm) was performed over the fourth intercostal space in the inframammary groove.

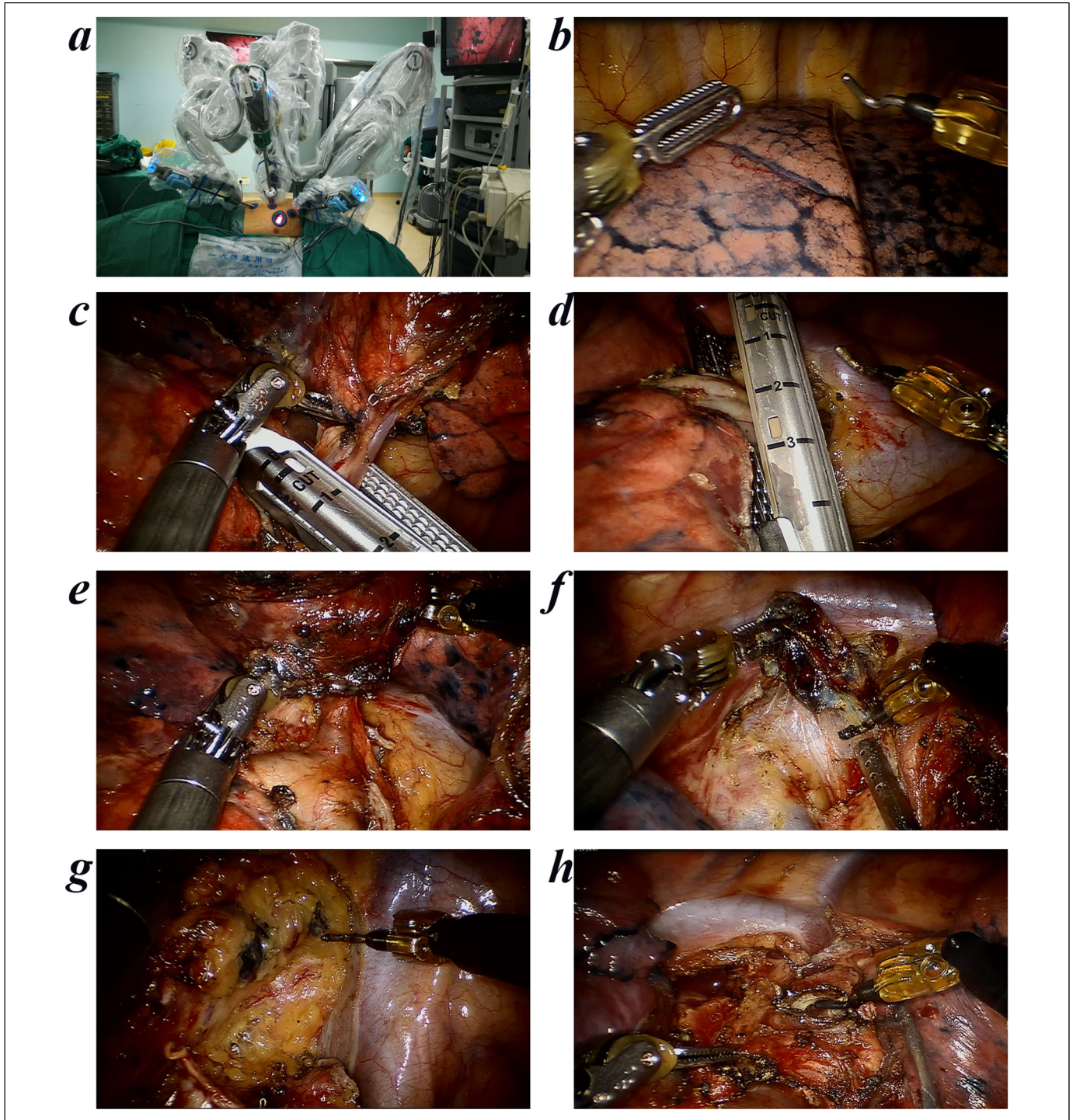
(2) The surgical steps and suture methods for RAS and MT were similar. For the lobectomy using RAS: (i) the inferior pulmonary ligament and mediastinal pleura were dissected; (ii) the pulmonary vessels were divided and exposed; (iii) the hilar and mediastinal lymph nodes were removed; (iv) the main and all lobar bronchi were exposed and the tumors and invaded bronchus and lung parenchyma were removed (Figure 2); (v) end-to-end anastomosis using continuous 3 to 0 Prolene sutures was performed after negative bronchus stump biopsy results were confirmed; and (vi) figure-of-8 (F8) suture and a surgeon’s knot were made at the midpoints of posterior walls of both bronchial ends. The two ends of Prolene suture were used to make continuous sutures posterior to lateral and anterior walls with a bulldog clamp holding the other stitch end to avoid twisting. The final surgeon’s knot was made on the anterior walls of the bronchial ends to complete the anastomosis (Figure 3); and (vi) in case of air leakage, the interrupted sutures using Vicryl 3.0 were introduced with an absorbable polyglycolic acid sheet (NEOVEIL, GUNZE limited, Japan) coating the anastomosis.

### Retrieving Clinical Data

Retrieved demographical and clinical data included operation time, anastomosis time, intraoperative blood loss, chest drainage time and volume, postoperative pain scores (Visual Analogue Scale),<sup>11</sup> complications, and white blood cell (WBC) levels on days 1, 3, and 7 after the operation and hospital stay.

### Follow-up

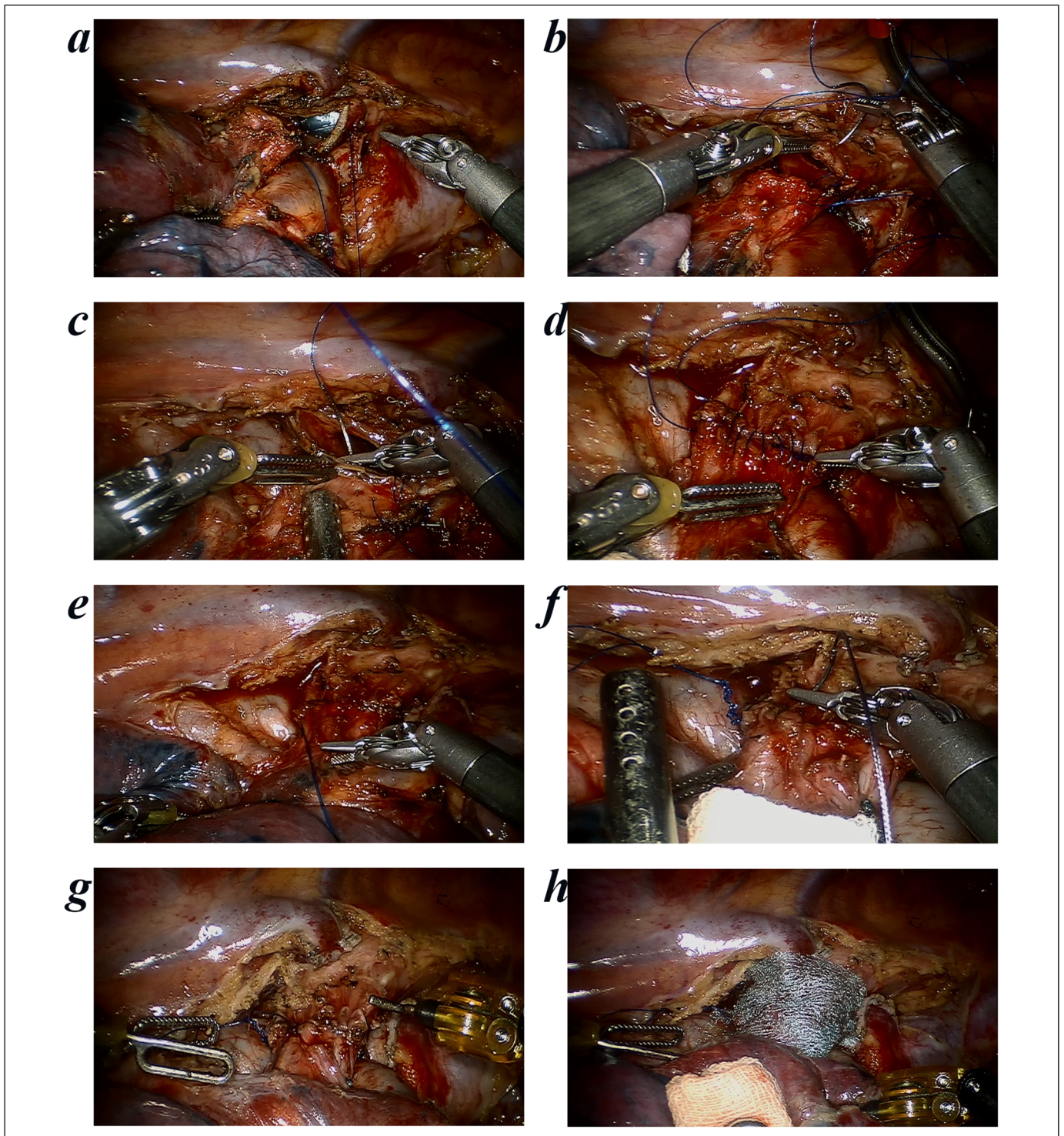
All of the patients underwent a routine outpatient or telephone follow-up every three months after the operation. Physical and systemic examinations, including chest CT, brain MRI, abdominal B-ultrasonography, and bone scintigraphy or PET-CT as an



**Figure 1.** Right upper sleeve lobectomy using RAS (surgical processes prior to anastomosis)

- a:** Optimized approach (“3-4-6-8/9” four-port method): the assistant port was located at the fourth intercostal space ~4 cm outward from the midclavicular line; 1-cm camera port was inserted at the sixth intercostal space in the posterior axillary line; 0.5-cm da Vinci ports for instrument arms were placed at the third intercostal space in the anterior axillary line and the eighth or ninth intercostal space in the posterior axillary line. The patient cart entered from the back of the patient’s head and shoulders at 75° to the longitudinal line. The assistant was located at the ventral side of the patient to install endoscope and instruments for linkage.
- b:** Install camera and instrument arms via optimized approach.
- c:** Divide and expose right upper pulmonary vessels.
- d:** Divide and expose arterial vessels.
- e:** Divide and expose posterior artery vessels.
- f and g:** Remove hilar and mediastinal lymph nodes.
- h:** Expose and remove tumor and tumor-invaded bronchus and lung parenchyma.





**Figure 2.** Right upper sleeve lobectomy using RAS (anastomosis processes)

**a:** Figure-of-8 (F8) suture and surgeon's knot were made at the midpoints of posterior walls of both bronchial ends.

**b and c:** Two ends of Prolene suture were used for continuous sutures posterior to lateral and anterior walls with bulldog clamps holding the other stitch end to avoid suture winding.

**d:** Carefully examine and tighten suture step-by-step.

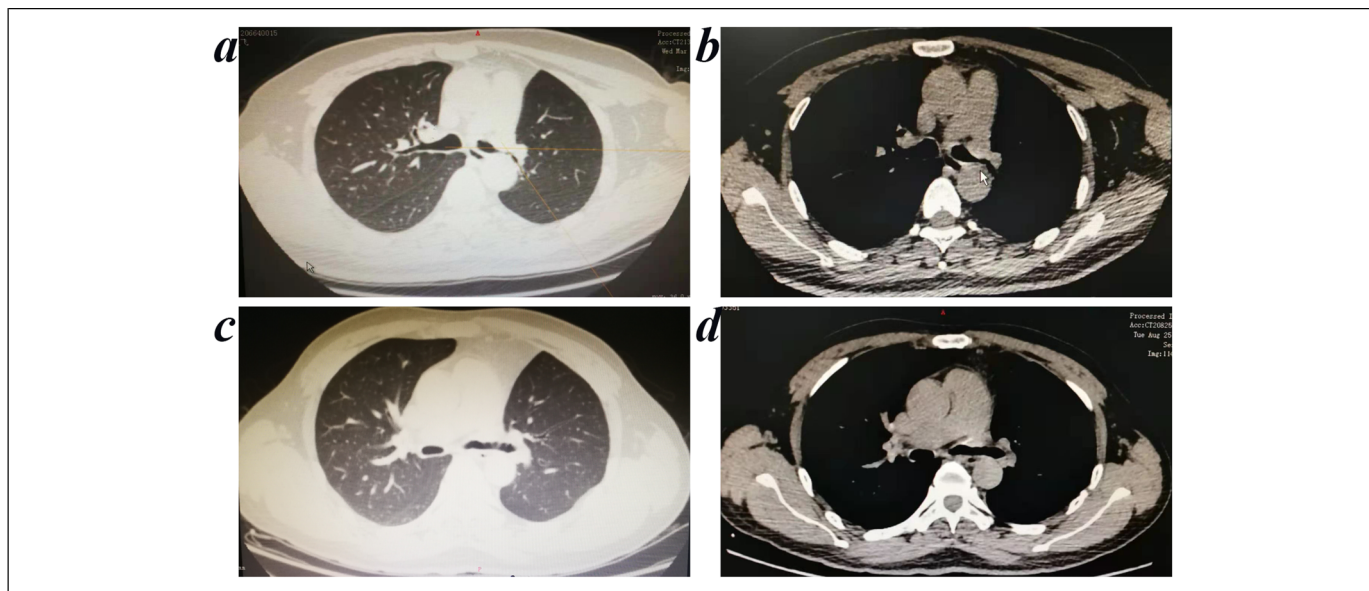
**e:** Final surgeon's knot was made on anterior walls of bronchial ends to complete anastomosis.

**f:** Interrupted sutures using Vicryl 3.0.

**g:** Detect air leakage using water test at bronchial anastomosis.

**h:** Absorbable polyglycolic acid sheet (NEOVEIL) coating for anastomosis.





**Figure 3.** Evaluation of postoperative bronchus protrusion via chest CT (three months after RA sleeve lobectomy).

**a and b:** Protrusion from posterior wall.

**c and d:** Posterior bronchus wall is straight.

alternative, were administrated to monitor recurrence or metastasis.

Chest CT was used for evaluating bronchial angulation. Representative CT in anastomotic stoma showing a protrusion arising from the posterior wall or bronchial kinking while other was straight.<sup>12</sup>

### Statistical Analysis

All data analyses were performed using IBM SPSS Statistics for Windows, version 23.0 (IBM Corporation, Armonk, NY, USA) and GraphPad Prism software (GraphPad Software, Inc., San Diego, CA, USA). Measurement data were expressed as means and standard deviation ( $\bar{x} \pm s$ ) in cases of normal distribution. Otherwise, a median (range) was used. The  $X^2$  test or one-way analysis of variance was used for comparison between groups. Count data were expressed as cases or percentage, and Pearson's chi-square test was used for comparison between groups. A two-sided  $p < 0.05$  was considered statistically significant. The statistical powers were calculated using XLSTAT (Addinsoft Inc., New York, NY, USA).

### Results

There was no significant difference in sex, age, smoking status, underlying disease, tumor location, tumor size, pathological type, and TNM stage between the two groups (Table 1).

#### *RAS Group had Similar Anastomosis Time but Shorter Operation Time*

There were no cases of perioperative death. All of the cases underwent an end-to-end bronchial anastomosis procedure,

which took approximately half an hour in the RAS and MT groups ( $30.82 \pm 6.08$  vs  $33.20 \pm 7.73$  min,  $p > 0.05$ ). However, the operation time in the RAS group was 30 min shorter compared to the MT group ( $189.73 \pm 36.41$  vs  $225.33 \pm 38.19$  min, respectively,  $p < 0.05$ ). This was probably due to more convenient manipulation and shorter time needed to open and close the chest cavity. Intriguingly, the docking did not significantly increase the operation time in the RAS group because it only took  $6.64 \pm 2.91$  min compared to our approach. Furthermore, there were no significant disparities in blood loss and number of resected lymph nodes (Table 2).

#### *RAS Group had Lower Pain Scores and WBC Levels and no Anastomotic Complications Following Operation*

Postoperatively, there were two and three cases with complications in the RAS and MT groups, respectively (2/11 vs 3/15,  $p > 0.05$ ). However, stratified analysis indicated that anastomotic complications were more likely to occur in the MT group, which included one anastomotic stenosis and two bronchopleural fistulas. Intriguingly, the RAS group had one incident of prolonged air leakage and one case of chylothorax without any anastomotic complications.

Moreover, the postoperative pain scores in the RAS group were  $4.23 \pm 0.26$ , which is statistically significantly lower than those in the MT group ( $4.23 \pm 0.26$  vs  $4.91 \pm 0.51$ ,  $p < 0.05$ ).

The two groups had similar results for postoperative drainage time, total thoracic drainage volume, and postoperative hospital stay (Table 2).

WBC levels in both groups increased on the first postoperative day (Table 2). However, the RAS group patients had lower WBC levels on the third and seventh day after operation

**Table 1.** Clinical demographical characteristics of RAS and MT groups

Data		RAS (n = 11)	Mini-thoracotomy (n = 15)	P-value
Sex	Male	10 (38.46)	13 (50)	.619
	Female	1 (3.85)	2 (7.69)	
Age (years, Mean $\pm$ SD)		54.82 $\pm$ 9.21	56.53 $\pm$ 8.25	.622
Smoking status	Yes	10 (38.46)	12 (46.15)	.426
	No	1 (3.85)	3 (11.54)	
Basic diseases	Yes	7 (53.8) <sup>i</sup>	6(46.2) <sup>ii</sup>	.251
	No	4 (36.4)	9 (60)	
Tumor location <sup>iii</sup>	RUL	7 (26.92)	10 (38.46)	.500
	LUL	0	2 (7.69)	
	LLL	2 (7.69)	1 (3.85)	
	RSB	0	1 (3.85)	
	RMB	1 (3.85)	1 (3.85)	
	LMB	1 (3.85)	0	
Maximum diameter of tumor (cm, Mean $\pm$ SD)		2.76 $\pm$ 1.30	3.49 $\pm$ 1.69	.243
Pathological type	Squamous carcinoma	8 (30.77)	10 (38.46)	.741
	Others	3(11.54) <sup>iv</sup>	5 (19.23) <sup>v</sup>	
Postoperative TNM stage	I	5(21.74)	6 (26.08)	.982
	II	3 (11.54)	5 (19.23)	
	III	2 (7.69)	2 (7.69)	

Note:

i: In RAS group: two diabetes cases; two chronic obstructive pulmonary disease cases; one hyperthyroidism case; one case with history of pulmonary tuberculosis; one arrhythmia case.

ii: In MT group: five hypertension cases and one diabetes case.

iii: RUL: right upper lobe; LUL: left upper lobe; LLL: left lower lobe; RSB: right secondary bronchus; RMB: right main bronchus; LMB: left main bronchus.

iv: Large-cell carcinoma, adenocarcinoma, and epithelial-myoepithelial carcinoma.

v: Small-cell carcinoma, large-cell carcinoma, epithelial-myoepithelial carcinoma, Castleman's disease (mixed type), and hamartoma.

compared to the MT group (Table 2), demonstrating a lower inflammatory response caused by RAS.

### **Both Groups Demonstrated Successful Bronchus Reconstruction with low Risk of Angulation and Satisfactory Short-Term Outcomes**

Bronchial angulation can be clearly identified using a chest CT after three months following the operation (Figure 3). Fortunately, the incidence of bronchial angulation was low in both groups (1/11 vs 1/15,  $p > 0.05$ ). To date, the follow-up times in the RAS and MT groups have been similar (32.27.30  $\pm$  17.65 vs 33.93  $\pm$  13.92 months,  $p = 0.922$ ). In the RAS group, one (3.85%) and two (7.70%) patients suffered from metastasis of mediastinal lymph nodes and distal metastasis, respectively. One patient (3.85%) died from chemotherapy side effects. In the MT group, two patients (7.69%) experienced anastomotic recurrence and another two patients (7.69%) had intracranial metastasis. Two patients (7.69%) died from anastomotic recurrence and chemotherapy side effects. The K-M plotter did not show any statistical differences in disease-free survival of the two groups (Figure 4).

## **Discussion**

In 1947, Thomas et al. reported the first sleeve lobectomy<sup>13</sup> that can achieve the same effect as pneumonectomy and retain a maximum pulmonary function.<sup>1,14</sup> With the developments of

a variety instruments and techniques, thoracic surgeons began to perform video-assisted minimally invasive sleeve lobectomy in 2002.<sup>15</sup> Sleeve lobectomy via video-assisted thoracoscopic surgery (VATS) has the advantages of less trauma, less bleeding, less postoperative pain, and better quality of life.<sup>2,16-21</sup> Thus, the National Comprehensive Cancer Network guidelines recommend this technique as a standard operation for lung cancer treatment.<sup>22,23</sup>

Currently, RAS represents a feasible and reliable alternative to this complex surgery. For instance, the da Vinci surgery provides a realistic three-dimensional stereoscopic image that can amplify the surgical field of view 10 to 40 times. Furthermore, the robotic instruments make the manipulations of pulling, rotating, clipping, cutting, suturing, and knotting more flexible and accurate. All of these advantages are supposed to facilitate sleeve lobectomy in a narrow space.<sup>4,7,24,25</sup> However, there are some barriers to effective RAS, which include slower post-surgery recovery, increased set-up time, and higher cost.<sup>26</sup> RAS shows a promise in reducing the operation time for treating large and complex lesions when compared to the VATS approach, when an effective RAS team is involved in.<sup>26</sup> Furthermore, when assessing hospital stay cost exclusive of initial purchase cost, RAS has been found to be cheaper than open thoracotomy.<sup>26</sup>

In 2006, Ishikawa et al.<sup>27</sup> performed the first "hybrid" surgery in a freshly frozen human cadaver using VATS to separate and dissect vessels and using RAS to perform bronchus anastomosis. They located three ports for RAS, including a 5-cm-long in the fourth intercostal space and a 0.5-cm-long in the third intercostal



**Table 2.** Comparison of clinical outcomes between RAS and MT groups

Data (Mean ± SD)	RAS group (n = 11)	MT group (n = 15)	P-value
Operation time (min)	189.73 ± 36.41	225.33 ± 38.19	.025 <sup>i</sup>
Intraoperative blood loss (ml)	154.55 ± 121.36	170 ± 90.24	.712
Total number of lymph node removed (n)	20.60 ± 9.94	17.79 ± 7.87	.447
Thoracic drainage time (d)	9.64 ± 4.95	9.27 ± 8.01	.894
Total thoracic drainage volume (mL)	2662.27 ± 1291.05	1992.67 ± 1226.95	.191
Postoperative pain score	4.23 ± .26	4.91 ± .51	.000 <sup>ii</sup>
Postoperative hospital stay (d)	12.18 ± 5.25	12.53 ± 7.12	.891
WBC(× 10 <sup>9</sup> /L)			
Preoperative	5.96 ± 1.22	6.57 ± 2.17	.409
Postoperative Day1	12.48 ± 3.42	15.09 ± 3.34	.064
Postoperative Day3	7.09 ± 1.41	9.58 ± 2.61	.012 <sup>iii</sup>
Postoperative Day7	6.66 ± 1.43	9.38 ± 2.27	.003 <sup>iv</sup>

Note: statistical powers: i: .752; ii: .989; iii: 0.842; iv: .936

space on the anterioraxillary line and in the sixth intercostal space on the midaxillary line. In 2007, Schmid et al. reported a right upper sleeve lobectomy on a 30-year-old female patient using a similar “hybrid” surgery.<sup>28</sup> Subsequently, more experience has been accumulated and reported on sleeve lobectomies achieved using only RAS, which demonstrated feasibility and safety.<sup>4,29–31</sup>

Thus far, Jiao et al.<sup>32</sup> reported the largest series of 67 patients with sleeve lobectomy using RAS. They demonstrated their experience with three 1.5-cm port incisions and one 3-cm utility incision (the sixth intercostal space on the posterior axillary primarily for the robotic camera, the 4<sup>rd</sup> intercostal space on the anterioraxillary line, the seventh intercostal space on the scapularis line for arms, and the sixth intercostal space on the midaxillary line for the assisted port). However, the study curve seemed to be relatively long with ~100 sleeve lobectomies using thoracotomy or VATS and 30 cases using RAS as the study cohort before stably entering the plateau phase. Furthermore, the robotic system was brought into the operating field and situated over the patient’s head, which potentially affects anesthesia management during the operation.

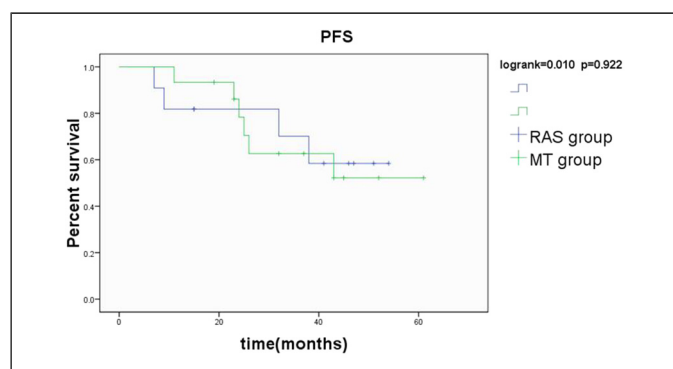
Scheinerman et al.<sup>5</sup> reported another series of 23 patients receiving sleeve lobectomy using RAS with minimal morbidity and without short-term mortality. They designed and used four robotic ports and one assistant port. Pan et al.<sup>33</sup> reported a series

of 21 cases of sleeve lobectomy using RAS via similar approaches. However, one patient suffered from an anastomosis fistula and subsequent pneumonia and died of multiple organ failure. Thus, some controversies remain regarding robotic arm and camera use. Moreover, RAS anastomotic techniques need to be optimized.<sup>32–37</sup>

Sleeve lobectomy using RAS has been carried out in our institution since 2017. With the accumulation of clinical cases and surgical experience, we modified the sleeve lobectomy using RAS approaches to reduce the port number and simplify the anastomotic techniques. The comparative analysis showed that intraoperative blood loss, postoperative complications, chest drainage time, and hospital stay are similar to those of the MT group, demonstrating safety, efficiency, and feasibility. Moreover, both operation time and postoperative pain scores are significantly superior to those of the MT group.

Anastomotic complications and bronchial angulation after sleeve lobectomy are a common and expected postoperative change, leading to atelectasis, pneumonia, dyspnea, and even complete collapse of the residual lung.<sup>12,38</sup> Our study demonstrated no anastomotic complications even at the early stage of the learning curve, which was in accordance with the published studies focusing on sleeve lobectomy using RAS. (1) In a cohort of 67 cases, there were two cases of prolonged air leaks, one of bronchial stenosis, one of pneumonia, one of chylothorax, and one of cough-variant asthma, but no anastomotic complications.<sup>32</sup> (2) In a cohort of 23 cases, there was one case of pneumonia and one of transfusion, but no anastomotic complications.<sup>5</sup> (3) In a cohort of 21 cases, there were two cases of pneumonia, two cases of pyothorax, and only one of anastomotic leak.<sup>33</sup> All of the studies with small sample sizes demonstrated that the incidence of anastomotic complications when using RAS was promisingly low.

In this study, the RAS group had one case of prolonged air leakage and one case of chylothorax, which delayed chest tube removal and caused a longer hospital stay. Furthermore, the sample size was relatively small. Therefore, there are no statistical advantages for postoperative rehabilitation between the two groups. However, it is possible that the RAS group may exhibit rapid rehabilitation in a large cohort study.



**Figure 4.** Kaplan–Meier curve showing that cases in two groups had no significant differences and present satisfactory short-term outcomes.

Postoperative detection of WBCs has been demonstrated to be an indicator that predicts complications, such as infection or anastomotic leakage.<sup>39</sup> Theoretically, it is supposed to be conducive to evaluation of an inflammatory reaction following sleeve lobectomy. In the present study, the RAS group had lower WBC levels after operation compared to those of the MT group.

We believe that these encouraging outcomes are attributed to the following novel attributes of our technique:

- (i) Less docking time (2-10 min, mean: 6 min) compared to traditional RA technique ( $17 \pm 10$  min)<sup>9,33</sup> because the camera can directly and conveniently guide the instrument arms via the ports to avoid repeating cannula adjustments;
- (ii) The surgical field of view is similar to that of VATS, thus shortening the learning curve and operation time for the surgical team with VATS experience.

Moreover, anastomosis is critical in sleeve lobectomy. The techniques include multiple interrupted sutures using absorbable VICRYL, running 3 to 0 Prolene suture, or a combination of both.<sup>4,8,40</sup> All of the bronchial anastomoses in the present study were made using continuous running suture with 3 to 0 Prolene. Notes on our experiences using this method are as follows:

- (i) The process of running 3 to 0 Prolene suture with bulldog clamps holding the other suture end can smooth and simplify the anastomosis and avoid suture twisting. In addition, a nerve hook can be used to pull and tighten sutures;
- (ii) The needle distance and margin should be adjusted and matched appropriately to reduce stress and avoid tearing of bronchial walls;
- (iii) Additional reinforced suture is unnecessary unless there is air leakage confirmed by the intraoperative water testing.

We also acknowledge the limitations of the study, which include a small sample size and the lack of survival evaluation due to limited follow-up time. However, the present pilot study demonstrates the strengths of the optimized RAS in comparison with MT. In addition, our results underscore the importance of adopting minimally invasive surgery for this type of operation.

## Conclusion

The optimized approach for RA sleeve lobectomy is convenient and efficient and provides satisfactory clinical outcomes that include shorter operation time, lower incidence of anastomotic complication, and lower pain scores. Further study with a large sample size and evaluation of long-term survival are warranted.

## Ethics Approval and Patient Consent Statement

This retrospective study was approved by the Research Ethics Board in Daping hospital (Chongqing City, P.R. China) [IRB: 2021 to 014]. However, it was not a prospective trial, consent to participate was not required.

## Acknowledgments

This study is supported by the joint project of Science and Technology Committee and Health Commission of Chong-qing(No. 2020FYYX061) and the Natural Science Foundation of Chongqing City (No. cstc2015jcyjA10073, No. cstc2019jcsx-msxmX0252)

## Conflict of Interests Statement

Tao Shaolin, Feng Yonggeng, Kang Poming, Mei Longyong, Shen Cheng, Fang Chunshu, Wu Licheng, Deng Bo and Tan Qunyou have no conflicts of interest or financial ties to disclose.

## Funding

The authors declare no competing financial and non-financial interests in relation to the work described in the manuscript.

## Data Availability Statement

The data that support the findings of this study are available from the corresponding author upon reasonable request.

## Code Availability

All data, models, and code generated or used during the study appear in the submitted article.

## Author Contribution Statement

Shao-Lin Tao and Yong-Geng Feng performed the operations, reviewed the clinical data and write the manuscript. Mei Longyong, Fang Chunshu and Wu Licheng reviewed the clinical and pathological data. Kang Poming and Shen Cheng designed the clinical treatment strategies. Deng Bo and Tan Qunyou designed the surgical strategies, supervised the whole project and proofread the manuscript.


## Consent to Participate


Written informed consent for publication was obtained from all participants.

## Consent for Publication

Written informed consent for publication was obtained from all participants.

## ORCID iDs

Wu Licheng  <https://orcid.org/0000-0001-9821-6800>

Deng Bo  <https://orcid.org/0000-0002-5112-9221>

## References

1. Pagès PB, Mordant P, Renaud S, et al. Sleeve lobectomy may provide better outcomes than pneumonectomy for non-small cell



- lung cancer. A decade in a nationwide study. *J Thorac Cardiovasc Surg.* 2017;153(1):184-195.e183.
2. Deng HY, Qiu XM, Zhu DX, et al. Video-Assisted thoracoscopic sleeve lobectomy for centrally located Non-small cell lung cancer: a meta-analysis. *World J Surg.* 2021;45(3):897-906.
  3. Beauchamp G. Fundamentals of standard sleeve resection. *Thorac Surg Clin.* 2018;28(3):285-289.
  4. Cerfolio RJ. Robotic sleeve lobectomy: technical details and early results. *J Thorac Dis.* 2016;8(Suppl 2):S223-S226.
  5. Scheinerman JA, Jiang J, Chang SH, et al. Extended robotic pulmonary resections. *Front Surg.* 2021;8:597416.
  6. Moglia A, Ferrari V, Morelli L, et al. A systematic review of virtual reality simulators for robot-assisted surgery. *Eur Urol.* 2016;69(6):1065-1080.
  7. Cohen BD, Marshall MB. Robotic-assisted tracheobronchial surgery. *J Thorac Dis.* 2020;12(10):6173-6178.
  8. Campisi A, Ciarrocchi AP, Congiu S, et al. Sleeve lobectomy: to wrap or not to wrap the bronchial anastomosis? *Ann Thorac Surg.* 2021; S0003-4975(21)00224-1. 10.1016/j.athoracsur.2021.01.038.
  9. Lin MW, Kuo SW, Yang SM, et al. Robotic-assisted thoracoscopic sleeve lobectomy for locally advanced lung cancer. *J Thorac Dis.* 2016;8(7):1747-1752.
  10. Chen D, Kang P, Tao S, et al. Risk factors of conversion in robotic- and video-assisted pulmonary surgery for non-small cell lung cancer. *Updates Surg.* 2021.
  11. Williamson A, Hoggart B. Pain: a review of three commonly used pain rating scales. *J Clin Nurs.* 2005;14(7):798-804.
  12. Arai H, Tajiri M, Masuda H, et al. Intermediate bronchial kinking after right upper lobectomy for lung cancer. *Asian Cardiovasc Thorac Ann.* 2021;29(1):19-25.
  13. Thomas CP. The surgical treatment of tuberculous empyema. *Ir J Med Sci.* 1947;256:148-153.
  14. Caso R, Watson TJ, Khaitan PG, et al. Outcomes of minimally invasive sleeve resection. *J Thorac Dis.* 2018;10(12):6653-6659.
  15. Santambrogio L, Cioffi U, De Simone M, et al. Video-assisted sleeve lobectomy for mucoepidermoid carcinoma of the left lower lobar bronchus: a case report. *Chest.* 2002;121(2):635-636.
  16. Mahtabifard A, Fuller CB, McKenna RJr. Video-assisted thoracic surgery sleeve lobectomy: a case series. *Ann Thorac Surg.* 2008;85(2):S729-S732.
  17. Liu L, Mei J, Pu Q, et al. Thoracoscopic bronchovascular double sleeve lobectomy for non-small-cell lung cancer. *Eur J Cardiothorac Surg.* 2014;46(3):493-495.
  18. Deng HY. Sleeve lobectomy for centrally located Non-small cell lung cancer: does incision size really matter? *Ann Thorac Surg.* 2020;109(2):612.
  19. Huang J, Li J, Qiu Y, et al. Thoracoscopic double sleeve lobectomy in 13 patients: a series report from multi-centers. *J Thorac Dis.* 2015;7(5):834-842.
  20. Gonzalez-Rivas D, Fernandez R, Fieira E, et al. Uniportal video-assisted thoracoscopic bronchial sleeve lobectomy: first report. *J Thorac Cardiovasc Surg.* 2013;145(6):1676-1677.
  21. Bendixen M, Jørgensen OD, Kronborg C, et al. Postoperative pain and quality of life after lobectomy via video-assisted thoracoscopic surgery or anterolateral thoracotomy for early stage lung cancer: a randomised controlled trial. *Lancet Oncol.* 2016;17(6):836-844.
  22. Davoli F, Bertolaccini L, Pardolesi A, et al. Video-assisted thoracoscopic surgery bronchial sleeve lobectomy. *J Vis Surg.* 2017;3:41.
  23. Ettinger DS, Wood DE, Aisner DL, et al. NCCN Guidelines insights: non-small cell lung cancer, version 2.2021. *J Natl Compr Canc Netw.* 2021;19(3):254-266.
  24. Qiu T, Zhao Y, Xuan Y, et al. Robotic sleeve lobectomy for centrally located non-small cell lung cancer: a propensity score-weighted comparison with thoracoscopic and open surgery. *J Thorac Cardiovasc Surg.* 2020;160(3):838-846.e832.
  25. Radkani P, Joshi D, Barot T, et al. Robotic video-assisted thoracoscopic lung resection for lung tumors: a community tertiary care center experience over four years. *Surg Endosc.* 2016;30(2):619-624.
  26. Garbutt AM. Working towards clinical effectiveness-a multidisciplinary approach to robotic surgery. *Ann Cardiothorac Surg.* 2019;8(2):255-262.
  27. Ishikawa N, Sun YS, Nifong LW, et al. Thoracoscopic robot-assisted bronchoplasty. *Surg Endosc.* 2006;20(11):1782-1783.
  28. Schmid T, Augustin F, Kainz G, et al. Hybrid video-assisted thoracic surgery-robotic minimally invasive right upper lobe sleeve lobectomy. *Ann Thorac Surg.* 2011;91(6):1961-1965.
  29. Egberts JH, Möller T, Becker T. Robotic-Assisted sleeve lobectomy using the four-Arm technique in the DaVinci Si® and Xi® systems. *Thorac Cardiovasc Surg.* 2019;67(7):603-605.
  30. Jo MS, Kim DY, Jeong JY, et al. Robotic sleeve lobectomy with four arms for lung cancer centrally located in the right lower lobe: a case report. *J Cardiothorac Surg.* 2017;12(1):108.
  31. Durand M. Four-arm robotic sleeve right upper lobectomy. *Ann Cardiothorac Surg.* 2019;8(2):286-287.
  32. Jiao W, Zhao Y, Qiu T, et al. Robotic bronchial sleeve lobectomy for central lung tumors: technique and outcome. *Ann Thorac Surg.* 2019;108(1):211-218.
  33. Pan X, Gu C, Wang R, et al. Initial experience of robotic sleeve resection for lung cancer patients. *Ann Thorac Surg.* 2016;102(6):1892-1897.
  34. Pan X, Chen Y, Shi J, et al. Robotic assisted extended sleeve lobectomy after neoadjuvant chemotherapy. *Ann Thorac Surg.* 2015;100(6):e129-e131.
  35. Zhao Y, Chen H, Qiu T, et al. Robotic-assisted sleeve lobectomy for right upper lobe combining with middle lobe resection of lung cancer. *J Vis Surg.* 2016;2:178.
  36. Qiu T, Zhao Y, Xuan Y, et al. Robotic-assisted double-sleeve lobectomy. *J Thorac Dis.* 2017;9(1):E21-e25.
  37. Cosgun T, Kaba E, Ayalp K, et al. Successful sleeve resection as a marker for proficiency for robotic pulmonary resection. *Thorac Cardiovasc Surg.* 2019.
  38. Seok Y, Cho S, Lee JY, et al. The effect of postoperative change in bronchial angle on postoperative pulmonary function after upper lobectomy in lung cancer patients. *Interact Cardiovasc Thorac Surg.* 2014;18(2):183-188.
  39. Kirdak T, Uysal E, Sezgin E, et al. Inflammatory response markers in rats undergoing abdominal surgical procedures. *Ann Gastroenterol.* 2020;33(5):528-535.
  40. Chamogeorgakis T, Moquin K, Simoff M, et al. Repair of bronchial anastomosis following lung transplantation. *Thorac Cardiovasc Surg.* 2021.