

Original research

# Chronic subclinical inflammation after phakic intraocular lenses implantation: Comparison between Artisan and Artiflex models

Alireza Hedayatfar<sup>a,b,\*</sup>, Hassan Hashemi<sup>c</sup>, Soheila Asghari<sup>d</sup>, Negin Badie<sup>a</sup>,  
Mohammad MirafTAB<sup>a</sup>

<sup>a</sup> Noor Ophthalmology Research Center, Noor Eye Hospital, Tehran, Iran

<sup>b</sup> Rassoul Akram Hospital, Iran University of Medical Sciences, Tehran, Iran

<sup>c</sup> Noor Research Center for Ophthalmic Epidemiology, Noor Eye Hospital, Tehran, Iran

<sup>d</sup> Department of Epidemiology and Biostatistics, School of Public Health, Tehran University of Medical Sciences, Tehran, Iran

Received 6 March 2017; revised 29 May 2017; accepted 13 June 2017

Available online 27 June 2017

## Abstract

**Purpose:** To compare chronic subclinical inflammation induced after implantation of Artisan vs. Artiflex phakic intraocular lenses (pIOLs).

**Methods:** This prospective, comparative, non-randomized study included consecutive patients with moderate to high myopia who underwent Artisan or Artiflex pIOL implantation with standard surgery and postoperative care. Anterior chamber flare was assessed quantitatively using laser flare photometry (LFP) at baseline, 1 week, 1 month, 3 months, 6 months, and 2 years after surgery.

**Results:** pIOLs were implanted in 72 eyes (40 patients); Artisan pIOLs in 16 eyes (Artisan group) and Artiflex pIOLs in 56 eyes (Artiflex group). The mean preoperative anterior chamber flare was  $6.5 \pm 2.3$  (range, 4.2–9.5) photons per millisecond (ph/ms) and  $4.2 \pm 0.9$  (range, 2.5–11.7) ph/ms in Artisan and Artiflex groups, respectively ( $P = 0.400$ ). In spite of early postoperative rise, the flare value returned to preoperative levels 6 months after pIOL implantation and remained stable up to 2 years. The amount of flare was not statistically different between Artisan and Artiflex groups in any postoperative follow-up (all  $P > 0.05$ ). The trend in flare changes was not different between the studied groups (ANCOVA,  $P = 0.815$ ).

**Conclusion:** The inflammatory response induced by implantation of either type of Artisan and Artiflex pIOLs is short-lived without statistically significant difference between the two models.

Copyright © 2017, Iranian Society of Ophthalmology. Production and hosting by Elsevier B.V. This is an open access article under the CC BY-NC-ND license (<http://creativecommons.org/licenses/by-nc-nd/4.0/>).

**Keywords:** Subclinical inflammation; Flare; Phakic intraocular lens; Artisan; Artiflex

## Introduction

The surgical implantation of phakic intraocular lenses (pIOLs) offers advantages in the correction of moderate to

high myopia comparing to excimer laser treatment by providing higher chance of maintaining the best corrected visual acuity (BCVA), quality of vision and stable refractive results.<sup>1,2</sup> Among various pIOLs that have been designed, Artisan and Artiflex lenses (Ophtec BV, Groningen, The Netherlands) have been widely used since their introduction to market. Because they are fixated directly to the iris tissue, chronic inflammation has been a major concern with these lenses.<sup>3</sup> To verify the validity of a common belief that Artiflex implantation is associated with more postoperative inflammation than Artisan,<sup>4,5</sup> we designed the current study to compare the amount of blood-aqueous disruption that would

Conflict of interest: All authors have no financial disclosure. This research did not receive any specific grant from funding agencies in the public, commercial, or not-for-profit sectors.

\* Corresponding author. Ocular Inflammation and Uveitis Clinic, Noor Ophthalmology Research Center, Noor Eye Hospital, #96 Esfandiari Blvd., Vali'asr Ave., Tehran, 196865311, Iran.

E-mail address: [ahedayatfar@norc.ac.ir](mailto:ahedayatfar@norc.ac.ir) (A. Hedayatfar).

Peer review under responsibility of the Iranian Society of Ophthalmology.

be induced over time by implantation of either type of the two pIOLs.

## Methods

This prospective, non-randomized, comparative study includes consecutive patients with moderate to high myopia who underwent implantation of either type of Artisan or Artiflex pIOLs (Ophtec BV, Groningen, The Netherlands) at Noor Eye Hospital during an approximate three and half year period. None of the patients were eligible for excimer laser surgery. The surgeries were performed by 2 experienced surgeons (H.H. and M.M.) with the same surgical method and postoperative care. For each patient, the choice for Artisan vs Artiflex implantation was determined individually, based on the degree of refractive error, the amount of surgically induced astigmatism, and patients' demand for a faster visual recovery. The study protocol was approved by the institutions' ethics committee and informed consent was obtained before the surgical procedure.

Inclusion criteria were age above 20 and stable myopia with spherical equivalent (SE) of at least  $-5.0$  diopters (D). Exclusion criteria were any history of ocular disease including uveitis, cataract or glaucoma, history of systemic diseases (e.g. diabetes, rheumatologic diseases), history of ocular surgery, anterior chamber depth (ACD) less than 3.0 mm, and central endothelial cell count less than 2250.

### Preoperative assessment

Preoperatively, a complete ocular examination including determination of uncorrected visual acuity (UCVA) and BCVA, objective and subjective refraction before and after cycloplegia, slit-lamp biomicroscopy and dilated fundus examination, applanation Goldmann tonometry, endothelial cell count (Topcon SP-2000P, Tokyo, Japan) and corneal Scheimpflug imaging (Pentacam, OCULUS, Inc., Lynnwood, WA, USA) was performed in all eye. Anterior chamber flare was considered as the main variable of study and was assessed using the laser flare photometer (FM-600; Kowa, Tokyo, Japan) by one technician in a similar condition, prospectively. Seven measurements were taken at the lower third of anterior chamber. The highest and lowest values were discarded and the remaining 5 were averaged to obtain the flare measurement. Laser flare values were expressed in photons per millisecond (ph/ms). The anterior chamber cell was assessed by primary surgeon and was graded based on method described elsewhere according to SUN Working Group Classification.<sup>6</sup> Data regarding the cell grading and postoperative uveitis were extracted from the medical charts, retrospectively.

### Surgical technique

Pupils were constricted with pilocarpine 2% before surgery. Under regional anesthesia, a 6.5 mm corneoscleral tunnel or 3.2 mm clear corneal incision was made at the 12 o'clock position to implant Artisan or Artiflex lenses, respectively. The

anterior chamber was filled with viscoelastic, and the lens was introduced into the anterior chamber, rotated to horizontal position, and fixed to the mid-peripheral iris. A peripheral iridectomy was performed superiorly. After removal of the ophthalmic viscoelastic agent, the 6.5-mm wound was closed with 10-0 nylon sutures, and the 3.2-mm incision was hydrated without sutures.

### Postoperative care

Eyes were patched for 24 h. Postoperative topical medications included ciprofloxacin 0.3% (Ciplex, Sina Darou Pharm. Co., Tehran, Iran), one drop every 8 h for 1 week, and betamethasone 0.1% (Betasonite, Sina Darou Pharm. Co., Tehran, Iran), one drop every 4 h tapered over 8 weeks. The patients were examined the day after surgery. In addition to regular slit-lamp examination, UCVA and BCVA, objective and subjective refraction were determined and laser flare photometry (LFP) was performed at 1 week, 1 month, 3 months, 6 months and 2 years after surgery.

### Statistical analysis

Quantitative variables were expressed as mean and standard deviation. The association of pIOL model and mean flare changes were evaluated using repeated measures analysis of covariance. For bilateral cases, correlation between the two eyes was adjusted. The association between type of lens and occurrence of postoperative uveitis was assessed using the chi-square (Fischer exact) test.  $P$  value  $< 0.05$  was considered statistically significant.

## Results

Seventy-two eyes (40 patients) were studied: 16 eyes (10 patients) with a mean age of  $25.5 \pm 6.0$  years (range, 20–35 years) in Artisan group and 56 eyes (30 patients) with a mean age of  $27.8 \pm 4.8$  years (range, 21–37 years) in Artiflex group ( $P = 0.118$ ). The amount of myopia, astigmatism, and SE in each group are shown in Table 1.

The mean preoperative anterior chamber flare was  $6.5 \pm 2.3$  (range, 4.2–9.5) ph/ms and  $4.2 \pm 0.9$  (range, 2.5–11.7) ph/ms in Artisan and Artiflex groups, respectively ( $P = 0.400$ ). Postoperatively, anterior chamber laser flare values spiked at

Table 1  
Demographics, baseline (preoperative) visual acuities, and refractive errors.

	Artisan (n = 16)	Artiflex (n = 56)	P value	
Sex (F/M)	1.29	2.28	0.316	
Age (years)	$25.5 \pm 6.0$	$27.8 \pm 4.8$	0.118	
UCVA (logMAR)	$2.26 \pm 0.64$	$1.87 \pm 0.29$	0.030	
BCVA (logMAR)	$0.23 \pm 0.18$	$0.10 \pm 0.10$	0.017	
Refractive error (diopter)	Sphere	$-14.25 \pm 6.12$	$-8.63 \pm 2.81$	0.002
	Cylinder	$-1.84 \pm 1.19$	$-1.85 \pm 1.43$	0.995
	SE	$-16.64 \pm 6.83$	$-10.33 \pm 3.15$	0.005

UCVA: Uncorrected visual acuity; BCVA: Best corrected visual acuity; SE: Spherical equivalent.

one week in both Artisan ( $P = 0.038$ ) and Artiflex ( $P = 0.012$ ) groups. From the first postoperative week until the third month follow-up, the flare values were significantly higher than baseline values in both groups (all  $P$  values  $< 0.050$ ). At the sixth month follow-up, the flare value returned to preoperative levels and remained stable for up to 2 years after lens implantation (Table 2). The difference in flare values were not statistically significant between Artisan and Artiflex groups at 1 week ( $P = 0.483$ ), 1 month ( $P = 0.865$ ), 3 months ( $P = 0.082$ ), 6 months ( $P = 0.611$ ), or 2 years ( $P = 0.882$ ). The trend of flare changes was not statistically different between the studied groups (ANCOVA,  $P = 0.815$ ) (Fig. 1).

Preoperatively, the mean SE manifest refraction was  $-16.64 \pm 6.83$  D (range,  $-23.50$  to  $-13.50$  D) in the Artisan group and  $-10.33 \pm 3.15$  D (range,  $-17.00$  to  $-5.25$ ) in the Artiflex group ( $P = 0.005$ ). Six months after pIOL implantation, the SE was within  $\pm 1.0$  D in 64.3% of the eyes in the Artisan group and 72.7% of those in the Artiflex group ( $P = 0.729$ ). The trend of SE changes was statistically different between two groups (ANCOVA,  $P < 0.001$ ) (Fig. 2).

The preoperative and postoperative changes of UCVA and BCVA in the Artisan and Artiflex groups are depicted in Fig. 3. The logarithm of minimum angle of resolution (log-MAR) calculated for UCVA and BCVA were not statistically different between the two groups at any postoperative visit ( $P = 0.235$  and  $P = 0.386$ , respectively) (Fig. 3).

None of the eyes in either group had cells in the anterior chamber preoperatively. In both groups, the presence of anterior chamber cells was highest 1 week postoperatively and gradually decreased at subsequent visits. Except for eyes with acute postoperative uveitis, no eyes had anterior chamber cells after the first month of surgery. Postoperative uveitis, defined as severe anterior uveitis and evident flare, and fibrin formation occurred in a total of 3 eyes (4.17%); 1 eye (6.25%) belonged to the Artisan group and 2 (3.58%) to the Artiflex group ( $P = 0.535$ ). None of the eyes with uveitis had hypopyon. Postoperative uveitis developed from the third day to the third week after surgery. Two eyes were treated with topical corticosteroid successfully. One eye in the Artiflex group received systemic corticosteroid (prednisolone 1 mg/kg/day) in addition to topical treatment. The inflammation in all eyes resolved completely after treatment without posterior synechiae formation.

**Discussion**

Chronic inflammation has been a major concern with implantation of iris-claw pIOLs.<sup>4</sup> While the prior reports

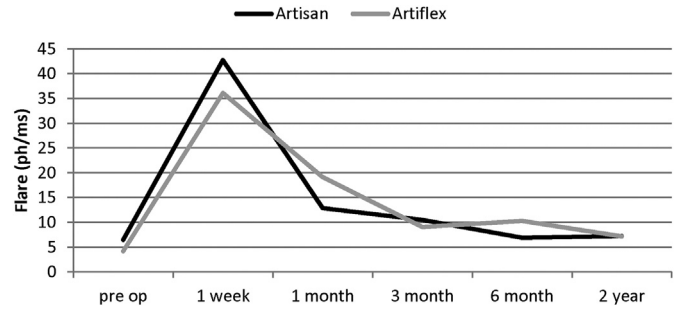


Fig. 1. Trend of flare changes after Artisan and Artiflex implantation in moderate to high myopia.

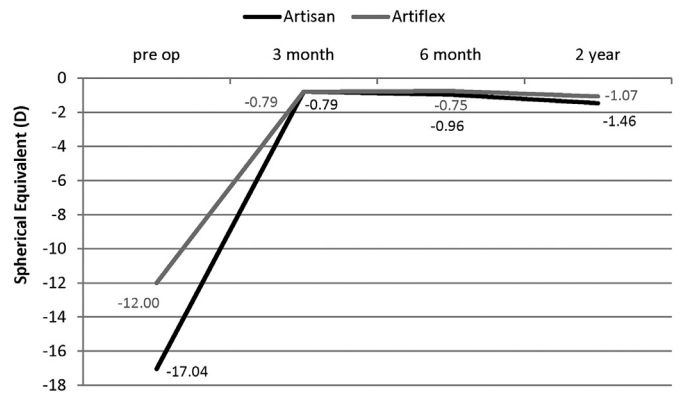


Fig. 2. Trend of spherical equivalent (SE) changes after Artisan and Artiflex implantation in moderate to high myopia.

indicates the tendency of pIOL to induce a chronic inflammatory reaction, especially after Artiflex implantation,<sup>4,5</sup> the results of the current study states that the inflammatory response induced by either type of Artisan and Artiflex pIOLs is short-lived without significant difference between the two models.

Chronic inflammation after implantation of pIOL has probably diverse mechanisms. Incarceration of iris tissue by pIOL haptics may lead to chronic iris irritation with breakdown of the blood–aqueous barrier and subsequent inflammation.<sup>7</sup> Abnormal pressure on the iris, which can become sandwiched between the crystalline lens and pIOL, may contribute to pigment dispersion and induction of an inflammatory reaction.<sup>8,9</sup> The flexible Artiflex lens may be more susceptible for these mechanical factors than the rigid Artisan lenses. An iris that is not flat or having too much iris tissue enclavated between the claws of the IOL may cause too much contact between the Artiflex and the iris, resulting in rubbing

Table 2  
Comparison of preoperative and postoperative mean flare values in Artisan and Artiflex groups.

	Pre-op	After surgery					P-value <sup>a</sup>	P-value <sup>b</sup>
		1 week	1 month	3 months	6 months	2 years		
Artisan	6.5 ± 2.3	42.7 ± 47.7	12.9 ± 10.5	10.5 ± 4.4	6.9 ± 1.9	7.2 ± 8.9	0.802	0.815
Artiflex	4.2 ± 0.9	36.1 ± 62.1	19.1 ± 39.4	9.1 ± 5.9	10.3 ± 14.5	7.2 ± 7.5	0.242	

<sup>a</sup> Two year changes of flare in each group.  
<sup>b</sup> Inter-group difference in two year changes.

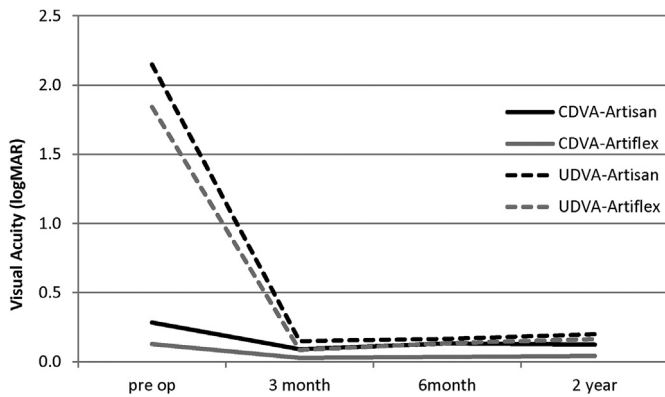


Fig. 3. Trend of uncorrected and corrected visual acuity changes after Artisan and Artiflex implantation in moderate to high myopia.

between them.<sup>5</sup> It is also hypothesized that the decreased vault between the optic–haptic junction of the Artiflex lens and the iris plane may result in mechanical irritation of iris tissue during pupillary constriction and dilation.<sup>4</sup>

Further to mechanical mechanism, biocompatibility of pIOL material has also been proposed to have some role in chronic inflammation. Various reports have described lower uveal biocompatibility of silicone intraocular lens after cataract surgery in eyes with uveitis.<sup>10,11</sup> Although silicone material of the Artiflex optics has been accused as the trigger of anterior chamber inflammation,<sup>12</sup> it is unclear whether the biocompatibility of the silicone material, which has been used for the manufacturing of foldable posterior chamber lenses for many years by the same company without adverse sequelae, plays a role in addition to the mechanical hypothesis.<sup>4</sup>

Contrary to acute postoperative uveitis which is characterized by significant anterior chamber reaction, chronic inflammatory response induced after implantation of iris-claw pIOL is low grade in nature and is particularly manifested by anterior chamber flare which can best be assessed quantitatively by LFP. LFP is currently the only objective method to reliably measure the anterior chamber flare. It can detect subclinical changes of flare in follow-up observation which is not detectable by slit-lamp examination. The LFP principle is based on detecting the back scattered light from aqueous proteins when a narrow laser beam is shone into anterior chamber. The amount of back scattered light is proportional to the concentration of protein in the aqueous and hence is indicating the level of blood–aqueous–barrier disruption.<sup>13,14</sup> Previous studies had proved the accuracy and reproducibility of the procedure.<sup>15</sup>

Few studies have evaluated the chronic postoperative inflammatory response in iris-claw pIOL implantation by LFP. Perez-Santonja compared postoperative flare levels after implantation of two types of iris-fixated pIOLs, the Worst-Fechner, and Baikoff pIOL. He reported a low grade subclinical inflammation which persisted up to 2 years after surgery.<sup>16</sup> Contrary to his report, our result showed only a short-lived higher flare values that return back to preoperative state 6 month after surgery in both Artisan and Artiflex groups.

The disparity of the two observations may be explained by different anatomical profile of pIOLs implanted and subsequent different mechanical mechanisms involved in induction of inflammation. Nonetheless, our findings are in agreement with Fechner report who found no significant inflammation using a flare-cell meter at 1 year follow-up in eyes received a concave Worst-iris claw lens.<sup>17</sup>

We found that the flare values were highest at first postoperative week in both studied groups. We assume that surgical trauma and iris manipulation during incision is the main reason for this early postoperative flare spike. Although the difference did not reach to a statistically significant level ( $P = 0.483$ ), the early postoperative flare was higher in Artisan-treated eyes (42.7 ph/ms) compared to that in Artiflex-treated group (36.1 ph/ms), a finding which can probably be explained by larger incision and consequent more extensive surgical trauma required for Artisan implantation.

This is the first study that compares the chronic subclinical inflammation between Artisan and Artiflex-treated eyes using LFP; however, there are some shortcomings. First, the number of eyes in Artiflex group is more than Artisan group. Because the foldable type induces less surgical astigmatism, Artiflex is more demanding and hence, the matching of participants was not implemented due to ethical constraints. Second, because the correction of higher degree of myopia was not feasible by Artiflex model, Artisan-treated eyes were generally more myopic than the Artiflex-treated eyes. The fact that degree of myopia was not similar between the two groups can potentially affect the outcomes. However, in one study, Shih reported that flare density measured by LFP in high myopic eyes was not different from that of the emmetropic control group.<sup>18</sup> Finally, multiple surgeons and inter-individual difference in the use of postoperative corticosteroid are among other limitations of this study.

Conclusively, we administered LFP, as a sensitive tool to assess and compare the amount of anterior chamber flare as an indicator of chronic inflammation after implantation of two commonly used pIOLs. The result of current study indicates that the inflammatory response induced by implantation of either type of Artisan and Artiflex pIOLs is short-lived (up to 6 months after surgery). Moreover, the amount of subclinical inflammation was not different between the two groups of patients.

## References

- Malecaze FJ, Hulin H, Bierer P, et al. A randomized paired eye comparison of two techniques for treating moderately high myopia: LASIK and artisan phakic lens. *Ophthalmology*. 2002;109(9):1622–1630.
- El Danasoury MA, El Maghraby A, Gamali TO. Comparison of iris-fixed Artisan lens implantation with excimer laser in situ keratomileusis in correcting myopia between  $-9.00$  and  $-19.50$  diopters: a randomized study. *Ophthalmology*. 2002;109(5):955–964.
- Kohnen T, Kook D, Morral M, Güell JL. Phakic intraocular lenses: part 2: results and complications. *J Cataract Refract Surg*. 2010;36(12):2168–2194.
- Tahzib NG, Eggink FA, Frederik PM, Nuijts RM. Recurrent intraocular inflammation after implantation of the Artiflex phakic intraocular lens for

- the correction of high myopia. *J Cataract Refract Surg.* 2006;32(8):1388–1391.
5. Dick HB, Budo C, Malecaze F, et al. Foldable Artiflex phakic intraocular lens for the correction of myopia: two-year follow-up results of a prospective European multicenter study. *Ophthalmology.* 2009;116(4):671–677.
  6. Jabs DA, Nussenblatt RB, Rosenbaum JT. Standardization of uveitis nomenclature (SUN) working group. Standardization of uveitis nomenclature for reporting clinical data: results of the first international workshop. *Am J Ophthalmol.* 2005;140(3):509–516.
  7. Pérez-Santonja JJ, Hernández JL, Benítez del Castillo JM, Rodríguez-Bermejo C, Zato MA. Fluorophotometry in myopic phakic eyes with anterior chamber intraocular lenses to correct severe myopia. *Am J Ophthalmol.* 1994;118(3):316–321.
  8. Alió JL, Mulet ME, Shalaby AM. Artisan phakic iris claw intraocular lens for high primary and secondary hyperopia. *J Refract Surg.* 2002;18(6):697–707.
  9. Baikoff G, Bourgeon G, Jodai HJ, Fontaine A, Lellis FV, Trinquet L. Pigment dispersion and Artisan phakic intraocular lenses: crystalline lens rise as a safety criterion. *J Cataract Refract Surg.* 2005;31(4):674–680.
  10. Alió JL, Chipont E, BenEzra D, Fakhry MA. Comparative performance of intraocular lenses in eyes with cataract and uveitis. *J Cataract Refract Surg.* 2002;28(12):2096–2108.
  11. Abela-Formanek C, Amon M, Schauersberger J, Kruger A, Nepp J, Schild G. Results of hydrophilic acrylic, hydrophobic acrylic, and silicone intraocular lenses in uveitic eyes with cataract: comparison to a control group. *J Cataract Refract Surg.* 2002;28(7):1141–1152.
  12. Koss MJ, Cichocki M, Kohnen T. Posterior synechias following implantation of a foldable silicone iris-fixated phakic intraocular lens for the correction of myopia. *J Cataract Refract Surg.* 2007;33(5):905–909.
  13. Sawa M, Tsurimaki Y, Tsuru T, Shimizu H. New quantitative method to determine protein concentration and cell number in aqueous in vivo. *Jpn J Ophthalmol.* 1988;32(2):132–142.
  14. Herbort CP, Guex-Crosier Y, de Ancos E, Nussenblatt Pittet N. Use of laser flare photometry to assess and monitor inflammation in uveitis. *Ophthalmology.* 1997;104(1):64–72.
  15. Shah SM, Spalton DJ, Taylor JC. Correlations between laser flare measurements and anterior chamber protein concentrations. *Invest Ophthalmol Vis Sci.* 1992;33(10):2878–2884.
  16. Pérez-Santonja JJ, Iradier MT, Benítez del Castillo JM, Serrano JM, Zato MA. Chronic subclinical inflammation in phakic eyes with intraocular lenses to correct myopia. *J Cataract Refract Surg.* 1996;22(2):183–187.
  17. Fechner PU, Strobel J, Wichmann W. Correction of myopia by implantation of a concave Worst-iris claw lens into phakic eyes. *Refract Corneal Surg.* 1991;7(4):286–298.
  18. Shih YF, Chen MS, Huang JK, Lin LL, Hung PT, Hou PK. The blood-aqueous barrier in anisometropia and high myopia. *Ophthalmic Res.* 1996;28(2):137–140.