

# Myelopathy in adult aortic coarctation: Causes and caveats of an atypical presentation

Chandan Mourya, Ashish Verma, Anand Bansal, Ram C Shukla, Arvind Srivastava

Department of Radiodiagnosis and Imaging, Institute of Medical Sciences, Banaras Hindu University, Varanasi, Uttar Pradesh, India

**Correspondence:** Dr. Ashish Verma, Department of Radiodiagnosis and Imaging, Institute of Medical Sciences, Banaras Hindu University, Varanasi - 221 005, Uttar Pradesh, India. E-mail: drdnv5@gmail.com

## Abstract

A 57-year-old female presenting with acute-onset paraplegia was referred for magnetic resonance imaging (MRI) of cervico-dorsal spine. On MRI, multiple tortuous dilated vessels were noted in the epidural space with long segment cord compression and imaging features of compressive myelopathy. Associated small acute cervico-dorsal epidural hematoma was also noted in the same region. Computed tomography (CT) angiography was performed subsequently which revealed post-ductal coarctation of aorta with multiple arterial collaterals in the chest wall and spinal canal. An extensive review of English language literature pertaining to the clinical presentations of adult aortic coarctation revealed only few reports of acute compressive myelopathy due to spinal epidural collateral vessels. Further, presentation at such a late age has not been reported before. In the present case, apart from a hypertrophied anterior spinal artery and perispinal collaterals, an anterior epidural hematoma was an additional important factor in the causation of myelopathy.

**Key words:** Coarctation; collaterals; compressive myelopathy; epidural hematoma

## Introduction

Coarctation of the aorta refers to a congenital narrowing of the aortic lumen and occurs in approximately 3.2 of 10,000 live births. The overall incidence has been reported to be between 5 and 8% of all congenital heart defects.<sup>[1]</sup> Aortic coarctation can be either pre-ductal (10%) or post-ductal (90%), depending upon the relation of the point of narrowing with the embryological ductus arteriosus (or ligamentum arteriosum) and the origin of the left subclavian artery.<sup>[1,2]</sup> While the former presents with severe heart failure, mostly within the first week of life, the latter form has a relatively late presentation with incidental hypertension noted during evaluation of acute associated ailments or non-specific

pathologies like life-threatening intracranial hemorrhage. Patient may have vague symptoms like headaches, chest pain, and fatigue.<sup>[3]</sup> The obstruction of blood flow through the aortic arch provokes the development of collateral vessels that would allow blood to flow from high-pressure to low-pressure areas. Collateral vessels most frequently emerge from the branches of the subclavian arteries above the obstruction and supply blood to the tissues below the obstruction. The collateral pathways that develop most commonly in proximal thoracic aortic stenosis are as follows: (1) Subclavian artery-internal mammary artery (also called internal thoracic artery)-intercostal arteries (retrograde flow)-postcoarctation descending thoracic aorta; (2) subclavian artery-thyrocervical and costocervical trunks-thoracoacromial and descending scapular arteries-postcoarctation descending thoracic aorta; and (3) subclavian artery-vertebral artery-anterior spinal artery-intercostal arteries-postcoarctation descending thoracic aorta. These abnormal vessels, rarely if ever, appear due to compression of adjacent vital structures or hemorrhages.<sup>[4,5]</sup> Only few reports were encountered in the contemporary literature where intraspinal collaterals and a hypertrophied anterior spinal artery had a causative

### Access this article online

#### Quick Response Code:



**Website:**  
www.ijri.org

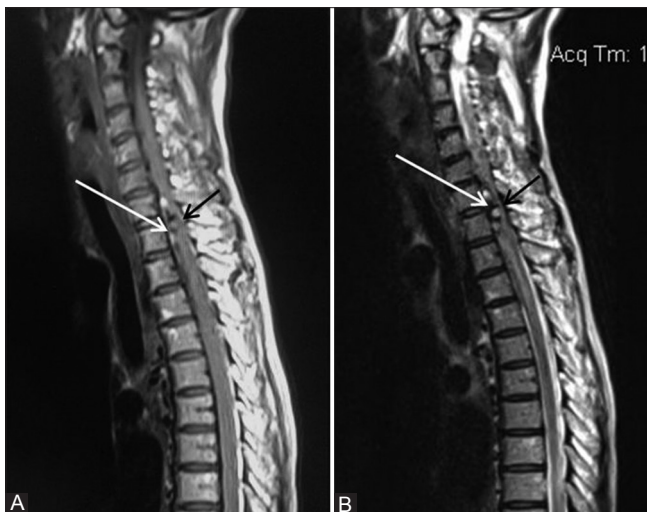**DOI:**  
10.4103/0971-3026.195775

role toward compressive myelopathy in a case of aortic coarctation, as in the present case, with the maximum documented age of a patient being 30 years as against an advanced age of 57 years in this case.<sup>[1,2,5]</sup> Further, none of these patients had an associated epidural hematoma, which was seen in this case and was an important cause of cord compression probably due to rupture of one of these abnormal vessels.

## Case Report

A 57-year-old female patient presented to the emergency department of our hospital with sudden-onset symmetric paralysis of bilateral lower limbs. The power was grade 0 with associated sensory loss as well. The patient had no other contributory history including that of fever, acute bouts of cough, coagulopathy, or any other chronic medical or surgical co-morbidity. She was referred for magnetic resonance imaging (MRI) of the spinal cord to evaluate the cause of paraplegia on a 1.5 Tesla whole body magnet (Siemens Medical Systems, Erlangen, Germany). An examination was performed on a 1.5 T scanner [Figure 1] which revealed a mixed intensity complex multilobulated lesion in the anterior epidural space with convex posterior margin, adjacent to the C7-D2 vertebral bodies. The lesion was seen to cause gross compression and displacement of the spinal cord in the region with altered cord signal intensity (extending from C3 to D3 levels) suggestive of cord edema. This raised a suspicion of small anterior epidural hematoma which, however, could not explain the gross compression of cord

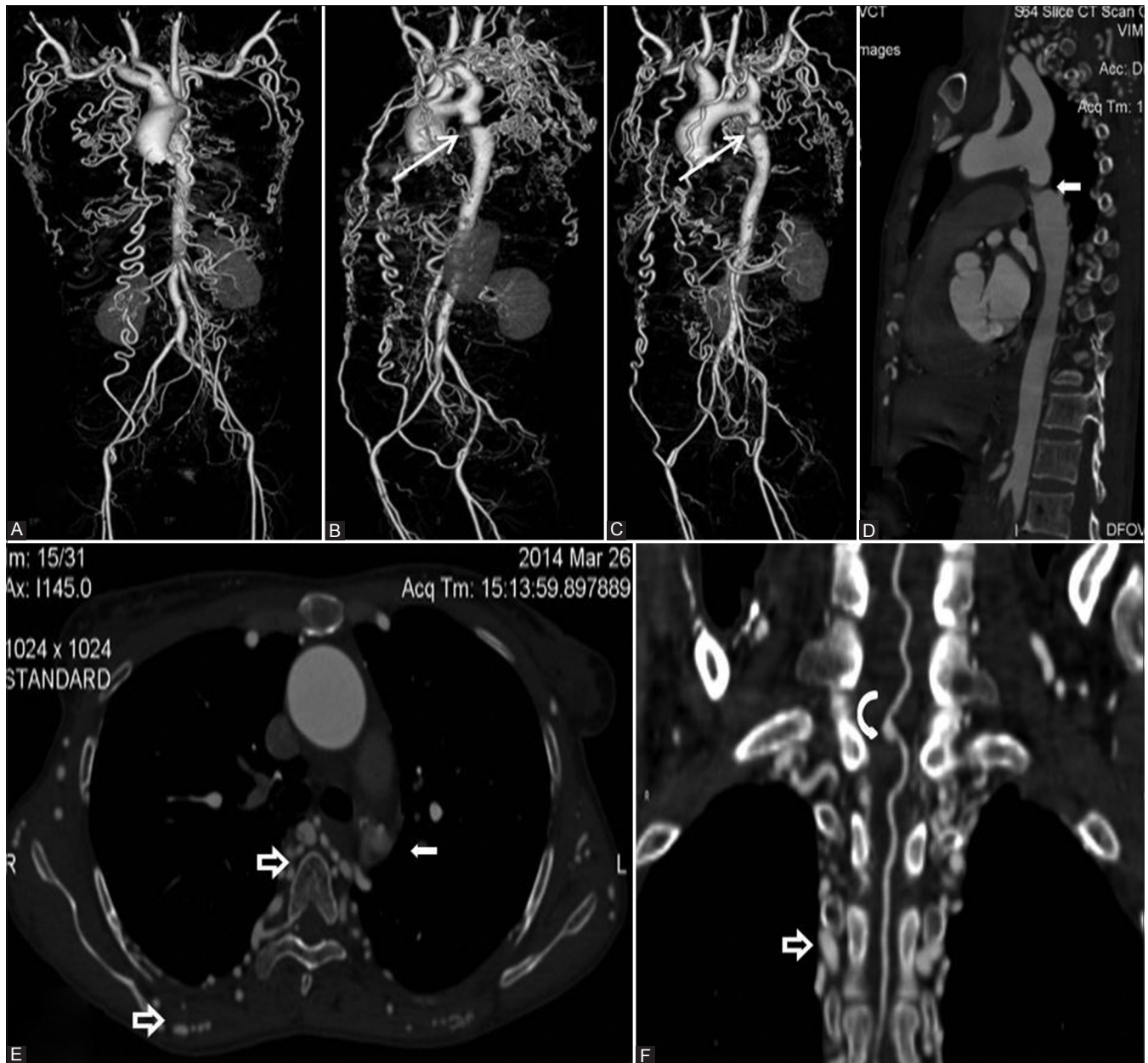
along with the length of the edematous cord segment. The MRI also showed multiple dilated tortuous vascular channels in the epidural space along with the hematoma, as well as in the paravertebral space. This prompted a computed tomography (CT) angiography [Figure 2] which confirmed the presence of extensive epidural, paravertebral, and chest wall collateral vessels, along with a hypertrophied anterior spinal artery compressing the spinal cord in the cervicodorsal region. The imaging was performed on a 64 Slice MDR CT scanner (GE Medical Systems, Milwaukee, USA). The collaterals were connected to bilateral internal thoracic, vertebral, and anterior spinal arteries. In addition, the long segment cord edema was probably due to vascular congestive state in the region as a result of slow flow and compression of perimedullary veins by the intraspinal space-occupying lesion hence formed. An interesting finding emerging at this stage was severe post-ductal coarctation of aorta, which could explain the genesis of all above features. No evidence of any abnormal spinal vascular malformation was noted. The patient was referred for further management to the cardiovascular surgery unit, where she was counseled for a possible shunt surgery, in the event of a cardiac emergency. Surgical therapy is associated with a low risk of restenosis and recurrence, whereas endovascular therapy, consisting of percutaneous balloon angioplasty and endovascular stent repair, has much higher incidence of restenosis, but is a safe and acceptable modality in poor surgical candidates.<sup>[6,7]</sup> As for the present episode, she was managed conservatively with supportive hospital care and showed satisfactory improvement in grade of power, sensations and gait. She was discharged after 2 weeks once she became ambulatory.



**Figure 1 (A and B):** MR images of the patient that were acquired at admission. Sagittal T1W (A) and T2W (B) images showing the multilobulated intraspinal extradural space-occupying lesion (white arrow) grossly compressing and displacing the spinal cord. The cord (black arrow) appears hyperintense on T2W images over a long segment suggesting edema (myelopathy). Note the flow voids (dark areas on both T1W and T2W) and areas of organized blood (bright areas on T1W) on the images, which raise a suspicion of abnormal vessels with small epidural hematoma

## Discussion

Collateral shunting of blood, in a case of post-ductal aortic coarctation, develops to decompress the high-pressure proximal segment to the low-pressure distal segment, usually via dilated intercostal and internal mammary arteries.<sup>[1,3-5]</sup> The same remains a slowly evolving process, hence the patient may present in second or early third decade with systemic hypertension. Aortic coarctation is not uncommonly diagnosed during evaluation of such “incidental hypertension,” unless the patient presents due to associated complex cardiac anomalies. As the pressure of the proximal segment increases, certain pre-existing embryologic vessels also hypertrophy, along the body wall, as was seen in the present case.<sup>[5,8]</sup> All these vessels, however, remain asymptomatic *per se*, serving as the tell-tale sign of the inciting pathology. Under rare circumstances, collaterals develop inside the spinal canal as well, along with hypertrophy of the spinal cord vasculature. When present, these vessels can be potentially dangerous, mainly due to chances of hemorrhage associated with rupture of these channels.<sup>[1,5,8]</sup> In exceptionally rare cases, these vessels may contribute toward spinal cord



**Figure 2 (A-F):** CT scan of the patient performed during clinical workup, (A-C) volume-rendered, and (D-F) multiplanar thick maximum intensity projection images. Note the stenosed aortic segment (straight white arrows), as described in text, associated with extensive collaterals in all areas including the paravertebral and epidural space (hollow arrows). The anterior spinal artery appears quite dilated (curved arrow), especially in the compressed segment of the cord

compression, as was noted in our patient. Although these vessels rarely attain aneurysmal dimensions, the compression is probably a result of constant pulsation under pressure in a closed space.<sup>[3-5]</sup> Further, increased intraspinal canal pressure can lead to lymphovenous congestion which can result in chronic myelopathy. The patient described in the present report represents one such situation where a sub-acute process of cord edema and sub-clinical myelopathy was unmasked by an acute episode of epidural hematoma, which led to presentation above the clinical horizon. Other uncommon causes of primary compressive myelopathy in a case of aortic coarctation are spinal artery aneurysm,

compression due to radicular artery aneurysm, aortic steal mechanism, dislodgement of microthrombi from dilated collaterals, and spontaneous bleed from dilated weak collaterals.<sup>[3,8,9]</sup> However, all these complications have been described within the age window of first to third decades, unlike the present patient where the presentation was delayed to the late sixth decade.<sup>[10,11]</sup> From an imaging perspective, on one hand, this case emphasizes the importance of thorough evaluation of the vascular system in all cases of spinal epidural hematomas, while on other hand it warns one to be wary of making a blind diagnosis of spinal arteriovenous malformations without such investigation.

## References

1. Gill M, Pathak HC, Singh P, Pathak K. A case of aortic coarctation presenting with quadriparesis due to dilated tortuous anterior spinal artery. *Neurol India* 2011;59:317-8.
2. Tan KP, Ng FC, Ong PL. Paraparesis due to dilated spinal collaterals. *Singapore Med J* 1979;20:454-6.
3. Doppman JL, Di Chiro G, Glancy DL. Collateral circulation through dilated spinal cord arteries in aortic coarctation and extraspinal arteriovenous shunts. An arteriographic study. *Clin Radiol* 1969;20:192-7.
4. Kendall BE, Andrew J. Neurogenic intermittent claudication associated with aortic steal from the anterior spinal artery complicating coarctation of the aorta. *J Neurosurg* 1972;37:89-94.
5. Banna MM, Rose PG, Pearce GW. Coarctation of aorta as a cause of spinal subarachnoid haemorrhage. Case report. *J Neurosurg* 1973;39:761-3.
6. Kische S, Schneider H, Akin I, Ortak J, Rehders TC, Chatterjee T, *et al.* Technique of interventional repair in adult aortic coarctation. *J Vasc Surg* 2010;51:1550-9.
7. Carr JA. The results of catheter-based therapy compared with surgical repair of adult aortic coarctation. *J Am Coll Cardiol* 2006;47:1101-7.
8. Tsutsumi K, Nagata K, Terashi H, Sato M, Hirata Y. A case of aortic coarctation presenting with Brown-Séquard syndrome due to radicular artery aneurysm. *Rinsho Shinkeigaku* 1998;38:625-30.
9. Hino H, Maruyama H, Inomata H. A case of spinal artery aneurysm presenting transverse myelopathy associated with coarctation of the aorta. *Rinsho Shinkeigaku* 1989;29:1009-12.
10. Laguna J, Cravioto H. Spinal cord infarction secondary to occlusion of the anterior spinal artery. *Arch Neurol* 1973;28:134-6.
11. Chaddock WM, Cathey SL, Gearhart AT, Cavin L, Glasier CM. Paraplegia caused by coarctation of the aorta and hydrocephalus. *Childs Nerv Syst* 1986;2:162-4.

**Cite this article as:** Mourya C, Verma A, Bansal A, Shukla RC, Srivastava A. Myelopathy in adult aortic coarctation: Causes and caveats of an atypical presentation. *Indian J Radiol Imaging* 2016;26:451-4.

**Source of Support:** Nil, **Conflict of Interest:** None declared.