

Hypoglossal Nerve Palsy as a Rare Complication of C1–C2 Pott’s Spine

Abstract

Reporting a rare scenario of hypoglossal nerve palsy in craniovertebral tuberculosis. Two patients presented in outpatient department with chief complaints of pain in neck, restricted neck movements, gait changes, difficulty in speech and weakness in all the extremities. On the basis of clinicoradiological correlation, the patients were diagnosed with tuberculosis of C1–C2 spine. They were started on antituberculosis therapy Category 1. The patients improved clinically and there was no worsening of symptoms, but they noticed tongue deviation and hypotrophy on one side of the tongue. C1–C2 tuberculosis along with cranial nerve palsy, especially hypoglossal nerve is one of the rarest presentations. Hypoglossal nerve arises from the medulla, exits through hypoglossal canal in the base of the skull and traverses neck to supply tongue musculature. Prevertebral fascia extends from superior mediastinum to base of the skull. Abscess in this area can cause either actual compression of the hypoglossal canal or C1 and base of the skull dissociation which can lead to compression of the canal.

Keywords: *Atlas, axis, C1–C2 tuberculosis, hypoglossal nerve, prevertebral fascia, tuberculosis*

**Rohit Pandey,
Himanshu Bhayana,
Ish Kumar Dhammi,
Anil Kumar Jain**

*Department of Orthopedics,
UCMS and GTB Hospital,
New Delhi, India*

Introduction

Tuberculosis of craniovertebral region accounts for 0.3%–1% of all tuberculosis spine cases.¹ The most common clinical manifestations are neck pain, restriction of neck movements, difficulty in deglutition, and torticollis.^{2,3} Neurological deficit in such cases is very rare.^{4–8} As the cervical spine region is involved quadripareisis or quadriplegia is common, but very rarely, hemiplegic and monoplegic presentations are also noticed.³ Involvement of cranial nerve along with craniovertebral tuberculosis is very unusual, in that to hypoglossal nerve is extremely rare. Mostly described in the literature as occipital condyle syndrome having occipital pain along with hypoglossal nerve palsy,⁹ but this is reported mainly in case of metastasis and head-and-neck tumors. Hypoglossal nerve palsy in cervicovertebral junctional tuberculosis, especially C1–C2 is extremely rare. We, hereby, report two such cases.

complaints of pain in neck, restricted neck movement, gait changes, and weakness in all the extremities for the past 3 months. She had no history of trauma, but the history of difficulty in speech and constitutional symptoms were present. The general physical examination was within normal limits. On clinical examination, cervical spine tenderness was present with paraspinal muscle spasm. There was no palpable swelling or sinus. Cervical lymph nodes were not palpably enlarged. The range of motion of neck was markedly reduced due to pain and spasm. Neurological examination revealed that a higher mental function and cranial nerves except hypoglossal nerve within normal limits. The upper motor neuron signs were present in bilateral upper and lower limbs. Tone was increased with clasp knife type of rigidity. Power was grossly 5/5 in all the limbs, with exaggerated deep tendon reflexes, and planters were upgoing.

On hematological investigation, erythrocyte sedimentation rate (ESR) was 90 mm, rest hematological, and biochemical examinations were normal. HIV, HBsAg, anti-HCV, X-ray chest, and ultrasonography abdomen were normal. The patient had X-ray of cervical spine showing increased soft-tissue shadow [Figure 1] and magnetic resonance imaging (MRI) of

Case Reports

Case 1

A 23-year-old female patient presented in outpatient department with chief

This is an open access journal, and articles are distributed under the terms of the Creative Commons Attribution-NonCommercial-ShareAlike 4.0 License, which allows others to remix, tweak, and build upon the work non-commercially, as long as appropriate credit is given and the new creations are licensed under the identical terms.

For reprints contact: reprints@medknow.com

How to cite this article: Pandey R, Bhayana H, Dhammi IK, Jain AK. Hypoglossal nerve palsy as a rare complication of C1–C2 pott’s spine. Indian J Orthop 2019;53:204-7.

Address for correspondence:

*Dr. Himanshu Bhayana,
Senior Resident Hostel,
Room 304, UCMS and GTB
Hospital, Dilshad Garden,
New Delhi, India.
E-mail: himanshu.bhayana.
manc@gmail.com*

Access this article online

Website: www.ijoonline.com

DOI:
10.4103/ortho.IJOrtho_600_17

Quick Response Code:



occipitocervical junction and cervical spine. An MRI was suggestive of destruction of atlas and axis vertebra with an abscess in the prevertebral region and cord having a mild compression from anterior aspect [Figure 2].

By clinical-radiological correlation, the patient was diagnosed with Pott's spine of C1-C2. She was started on antituberculosis therapy (ATT) Category 1 (Rifampicin 450 mg, Ethambutol 1000 mg, INH 300 mg, and Pyrazinamide 1500 mg), advised complete bed rest and initially kept on head halter traction for 6 weeks, at 6 weeks of patient was given four postcollar, and was mobilized. Patient improved clinically with no worsening of symptoms, but she noticed tongue deviation and hypotrophy of the right side of the tongue.

She was followed up regularly in the outpatient department. Four postcollar was removed at 1 year, and ATT was given for 18 months. At followup of 4 years, flexion and extension X-ray of cervical spine shows no instability, on repeat MRI there are healed lesion of C1-C2 spine with no abscess [Figure 3].

Clinically, she has no neck pain, there is a terminal restriction of neck nodding movements, and on the protrusion of tongue there is deviation of tongue with hypotrophy on the right side [Figure 4]. She has some difficulty in speaking, apart from that patient is doing all her activities without any difficulty.

Case 2

A 13-year-old female patient presented in the orthopedic department with chief complaints of pain in neck, difficulty in walking, and difficulty in deglutition for 2 months. General physical examinations were within normal limits except posterior cervical lymphadenopathy. On further examination, she had cervical tenderness along with grossly normal power in all four limbs with exaggerated reflexes and plantar upgoing. Blood investigations were done which showed raised ESR along with raised lymphocyte count and rest parameters were within normal limits. X-rays were done which showed destruction at C1-C2 level with increased prevertebral shadow. CT was done which also showed destructive lesion in C1 vertebra [Figure 5].

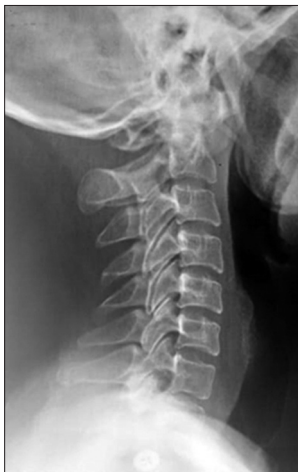

Figure 1: X-ray showing increased soft-tissue shadow

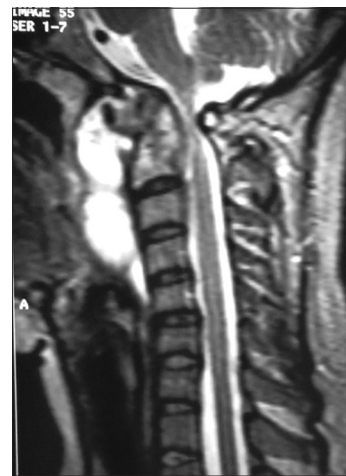

Figure 2: Magnetic resonance imaging showing craniovertebral prevertebral abscess at initial presentation

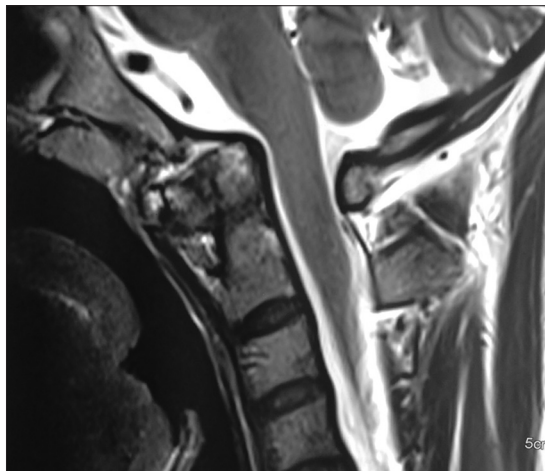


Figure 3: Magnetic resonance imaging showing craniovertebral healed lesion

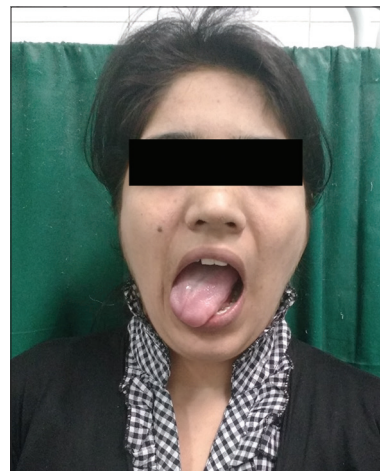


Figure 4: Clinical photograph showing the tongue deviation in Case 1

Clinicoradiologically diagnosis was made of tuberculosis, and the patient was started on ATT Category 1 and head halter traction was given for 3 months. ENT opinion was also taken regarding difficulty in deglutition but conservative treatment was planned.

The patient was serially followed and at 1-year followup, she has no complaint in neck or difficulty in walking, but on the protrusion of tongue, there is deviation of tongue to the left side [Figure 6].

Discussion

Tuberculosis of craniovertebral region is one of the rare presentations reported in the literature. C1–C2 tuberculosis along with hypoglossal nerve is one of the rarest complications. In context to craniovertebral tuberculosis, the most common presentations described are quadriplegia, quadriparesis and isolated monoplegia, and hemiplegia.³

Spread of tuberculosis in this area is mostly by retropharyngeal spread to the bone and rarely initiated from bone. This mainly affects the ligamentous structures first which, in turn, leads to subluxation at atlantoaxial level.

Lifeso classified C1–C2 tuberculosis into three stages.⁷ Stage I-minimal ligamentous or bone destruction and no displacement of C1 on C2; stage II has ligamentous disruption and minimal bone destruction but anterior displacement of C1 on C2; and stage III has marked ligamentous and bone destruction with displacement of C1 forward on C2. Our cases were in stage II of this classification.

Neurological deficit at this craniovertebral level can occur due to a variety of reasons abscess, granulation tissue, subluxation, upward translocation of dens, and vascular ischemia to name a few. Involvement of cranial nerves can also occur remotely. Hypoglossal nerve arises from the medulla, exists through the hypoglossal canal in the base of the skull and traverses neck to supply tongue musculature. Prevertebral fascia extends from superior mediastinum to base of the skull, abscess in this area can cause actual compression of the hypoglossal canal, or a C1 and base of the skull dissociation can lead to compression of the canal [Figure 7].

Sometimes in the literature, hypoglossal nerve palsy along with severe ipsilateral headache had been described as occipital condyle syndrome.⁹ The most common association of this condition is with metastasis to the base of the skull and head, neck tumors. In one of the largest study, malignancy was the cause of 49% cases.¹⁰ Infective cause of this condition is extremely rare and only one case report that to with headache is described in the literature.¹¹

Medial medullary syndrome can also occur as a rare manifestation of craniovertebral tuberculosis,¹² causing contralateral hemiplegia with no sensory loss.

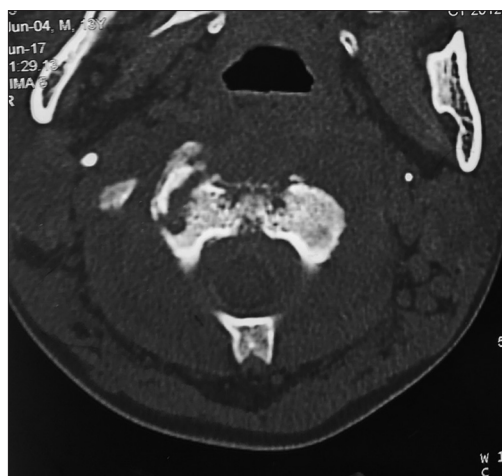

Figure 5: Computed tomography showing destruction at C1 in Case 2

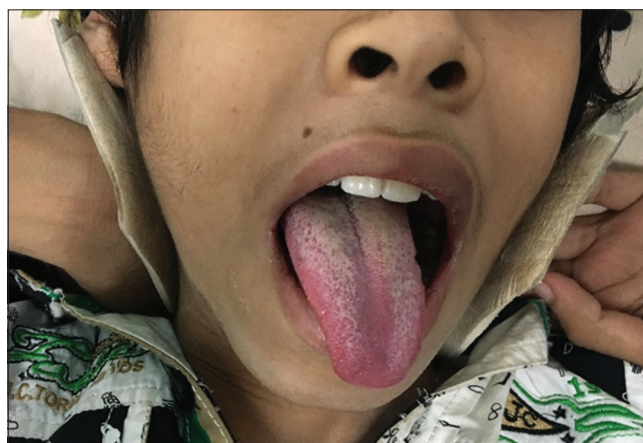

Figure 6: Clinical photograph showing the tongue deviation in Case 2

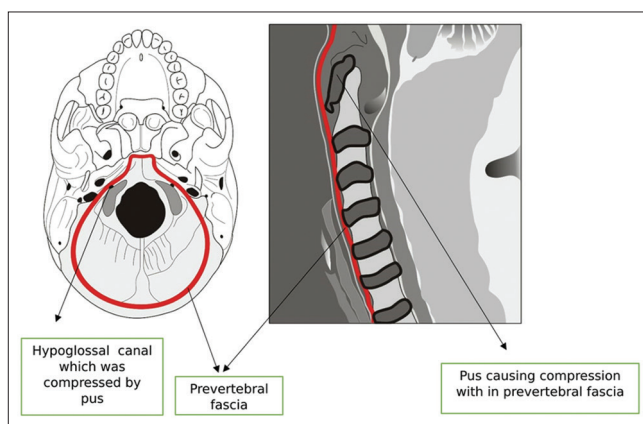


Figure 7: Schematic representation of route of spread of abscess

Early initiation of antitubercular therapy is the epitome for the management of spinal tuberculosis. These drugs have good penetration into the infected area. There have always been controversy regarding the management of tuberculosis whether operative or conservative treatment is required.

Numerous studies have revealed that medical treatment led to the resolution of disease in 82%–95% of cases.^{13–15}

Hodgson and stock advocated surgery in addition to chemotherapy,¹⁶ but a Cochrane database did not support this, it concluded that there were insignificant outcome measures such as neurological deficit, bony fusion, kyphotic angle, change of allocated treatment, or bone loss.¹⁴

Tuli in his famous paper laid down the concept of middle path regime,¹⁷ according to which, all cases should be started on antitubercular drugs therapy and according to the response to treatment surgical management should be considered except few definitive indications for surgery (difficulty in deglutition and Grade IV paraplegia). Apart from this, instability and deformity correction are other indications for surgery.

In our cases, we have followed the middle path regime, we initiated antitubercular drug therapy and immobilized the patient initially with headhalter traction, and the patient showed clinical and radiological improvement after 6 weeks of therapy. We noticed deviation of tongue and difficulty in speaking, but there is no further deterioration in neurological status and upper motor neuron signs also disappeared. On further radiological examination on flexion and extension view of the spine, there was no instability detected.

Here, we have presented two unusual cases of C1–C2 tuberculosis having isolated hypoglossal nerve palsy showing the possible routes of spread of disease managed by middle path regimen, causing this rare presentation.

Ethical approval

All procedures performed in studies involving human participants were in accordance with the ethical standards of the Institutional and/or National Research Committee and with the 1964 Helsinki declaration and its later amendments or comparable ethical standards.

Declaration of patient consent

The authors would like to certify that they have obtained all appropriate patient consent forms. In the form, the patients have given their consent for their images and other clinical information to be reported in the journal. The patient understand that name and initials will not be published and due efforts will be made to conceal identity, but anonymity cannot be guaranteed.

Financial support and sponsorship

Nil.

Conflicts of interest

There are no conflicts of interest.

References

1. Mehrotra A, Das KK, Nair AP, Kumar R, Srivastava AK, Sahu RN, *et al.* Pediatric cranio-vertebral junction tuberculosis: Management and outcome. *Childs Nerv Syst* 2013;29:809-14.
2. Chaudhary K, Potdar P, Bapat M, Mathod A, Laheri V. Structural odontoid lesions in craniovertebral tuberculosis: A review of 15 cases. *Spine* 2012;37:836-43.
3. Dhammi IK, Singh S, Jain AK. Hemiplegic/monoplegic presentation of cervical spine (C1-C2) tuberculosis. *Eur Spine J* 2001;10:540-4.
4. Fang D, Leong JC, Fang HS. Tuberculosis of the upper cervical spine. *J Bone Joint Surg Br* 1983;65:47-50.
5. Jain AK, Kumar S, Tuli SM. Tuberculosis of spine (C1 to D4). *Spinal Cord* 1999;37:362-9.
6. Karapurkar AP. Tuberculosis atlantoaxial disease including dislocation. *Vimhans J* 1988;89-98.
7. Lifeso R. Atlanto-axial tuberculosis in adults. *J Bone Joint Surg Br* 1987;69:183-7.
8. Tuli SM. Tuberculosis of the craniovertebral region. *ClinOrthopRelat Res* 1974;104:209-12.
9. Greenberg HS, Deck MD, Vikram B, Chu FC, Posner JB. Metastasis to the base of the skull: Clinical findings in 43 patients. *Neurology* 1981;31:530-7.
10. Keane JR. Twelfth-nerve palsy. Analysis of 100 cases. *Arch Neurol* 1996;53:561-6.
11. Neera C, Yogesh P, Vinod P, Khwaja GA. Occipital condyle syndrome in a young male: A rare presentation of cranio-vertebral tuberculosis. *J ClinDiagn Res* 2014;8:MD01-3.
12. Wilson JD, Braunwald E, Isselbacher KJ. *Harrison's Principles of Internal Medicine*. 12th ed., Vol. 2. New York: McGraw-Hill; 1991. p. 1988, 1989.
13. Lifeso RM, Weaver P, Harder EH. Tuberculous spondylitis in adults. *J Bone Joint Surg Am* 1985;67:1405-13.
14. Jutte PC, Van Loenhout-Rooyackers JH. Routine surgery in addition to chemotherapy for treating spinal tuberculosis. *Cochrane Database Syst Rev* 2006;1:CD004532. Review. Update in: *Cochrane Database Syst Rev* 2013;5:CD004532.
15. Tuli SM. Treatment of neurological complications in tuberculosis of the spine. *J Bone Joint Surg Am* 1969;51:680-92.
16. Hodgson AR, Francis E. Anterior spine fusion for the treatment of tuberculosis of the spine. *J Bone Joint Surg* 1960;42:295-310.
17. Tuli SM. Results of treatment of spinal tuberculosis by "middle-path" regime. *J Bone Joint Surg Br* 1975;57:13-23.