

Ribs Formed by Prolene Mesh, Bone Cement, and Muscle Flaps Successfully Repair Chest Abdominal Wall Defects after Tumor Resection: A Long-term Study

Li Fang, Yue-Jun Chen, Guan-Yu Wu, Qiu-Yi Zou, Zhi-Gang Wang, Guang Zhu, Xing-Ming Hu, Bin Zhou, Yi Tang, Gao-Ming Xiao

Department of Thoracic Surgery, The Affiliated Cancer Hospital of Xiangya School of Medicine, Central South University, Changsha, Hunan 410013, China

To the Editor: Chest abdominal wall defects are usually the result of tumor resection, infection, radiation, or trauma. Chest abdominal wall neoplasms are classified as primary, locally invading, or metastatic. The most common primary malignancies in the chest wall are the soft tissue and bone sarcomas.^[1] In most patients, the operations of the following defect locations are at the risk of herniation or paradoxical breathing postsurgery: total or subtotal sternal resection including several ribs bilaterally or high lateral resection (more than 3–4 ribs). In these cases, patients are prone to develop respiratory problems, if the stability is not adequate as early as during the immediate postoperative period.^[2]

Here, a new method of forming ribs by Prolene mesh, bone cement, and muscle flaps and improvements in intensive care and rehabilitation is documented to lead to acceptable morbidity and mortality rates. From January 2005 to September 2005, our hospital treated six patients of the huge chest wall under part tumor, which caused part of the defects in the chest, abdominal wall, and diaphragm muscle. We used ribs made by “prolene” mesh and bone cement to repair the bony defect, and further covered the defect with the latissimus dorsi muscle and gastrocolic omentum. This method obtained a satisfying effect.

Five cases had no obvious skin invaded and cancer, one case of skin was invaded by tumor. In five cases defects ranges were between 20 and 30 cm, in one case between 30 and 40 cm. The sternum, bilateral cartilage and part of costal as well as costal arch were resected in one case, eight costal were resected in part in one case, six costa were resected in part in three cases, and five costal were resected in part in one case. In all of the six cases, the operation caused part of a defect in the thoracoabdominal wall and diaphragm muscle. Postoperative pathological diagnosis showed that five cases were ribs chondrosarcoma and one case was fusicellular tumor. Surgical margins of five cases had no residual tumor cells. One case lived 14 months accepting postoperative radiotherapy because the first lumbar vertebral body was invaded by tumor and had some tumor tissues under microscope. All the other cases survived, among them the majority lived for 7 years.

We cut open the skin 3 cm away from the tumor edge, if the skin was not invaded. We removed a small number of the skin and then removed the tumor at the 3–5 cm distance, including the attached muscles (serratus anterior and latissimus dorsi), the normal costa around the tumor, a part of the diaphragm, the adhesive lung, a part of the external oblique muscle and of the internal oblique muscle. After the *en bloc* resection of the chest wall under part tumor, we inspected several organizations around the incisional edge. If the result was negative, we decided the necessity of the costa reconstruction according to the chest wall defect situation. If there was a need to perform a costa reconstruction, we would first repair the chest wall.

We used a 15 × 15 cm Prolene net to suture on intercostals muscles while keeping the net under tension and exposed 1–2 cm of the broken parts of the ribs. We then rebuild the shape of the ribs with bone cement (before it solidified). We then sutured the Prolene on muscles at the top of the diaphragm and close the chest. We sewed up the diaphragm and the internal oblique muscle with a 15 × 15 cm Prolene net, also keeping a certain tension. If the latissimus dorsi was removed, we sutured the Prolene net together with the internal and external oblique muscles, and then closed the abdominal cavity. If we retained the latissimus dorsi, we would free it and cover its muscle flap on the Prolene net, which is sutured on the external oblique abdominal muscle. If the latissimus dorsi was removed, we used omentum instead [Figures 1]. From six cases of this group, two cases used omentum metastasis to cover the Prolene net, three cases used the latissimus dorsi muscle flap, and one case used the vastus lateralis myocutaneous flap.

After a part of the chest wall, the abdominal wall and the diaphragm was removed during the operation, Prolene could not maintain its

Address for correspondence: Dr. Gao-Ming Xiao,
Department of Thoracic Surgery, The Affiliated Cancer Hospital of
Xiangya School of Medicine, Central South University, Changsha,
Hunan 410013, China
E-Mail: xiaogaoming617@163.com

This is an open access article distributed under the terms of the Creative Commons Attribution-NonCommercial-ShareAlike 3.0 License, which allows others to remix, tweak, and build upon the work non-commercially, as long as the author is credited and the new creations are licensed under the identical terms.

© 2017 Chinese Medical Journal | Produced by Wolters Kluwer - Medknow

Received: 19-02-2017 **Edited by:** Yi Cui
How to cite this article: Fang L, Chen YJ, Wu GY, Zou QY, Wang ZG, Zhu G, Hu XM, Zhou B, Tang Y, Xiao GM. Ribs Formed by Prolene Mesh, Bone Cement, and Muscle Flaps Successfully Repair Chest Abdominal Wall Defects after Tumor Resection: A Long-term Study. Chin Med J 2017;130:1510-1.

Access this article online

Quick Response Code:



Website:
www.cmj.org

DOI:
10.4103/0366-6999.207473

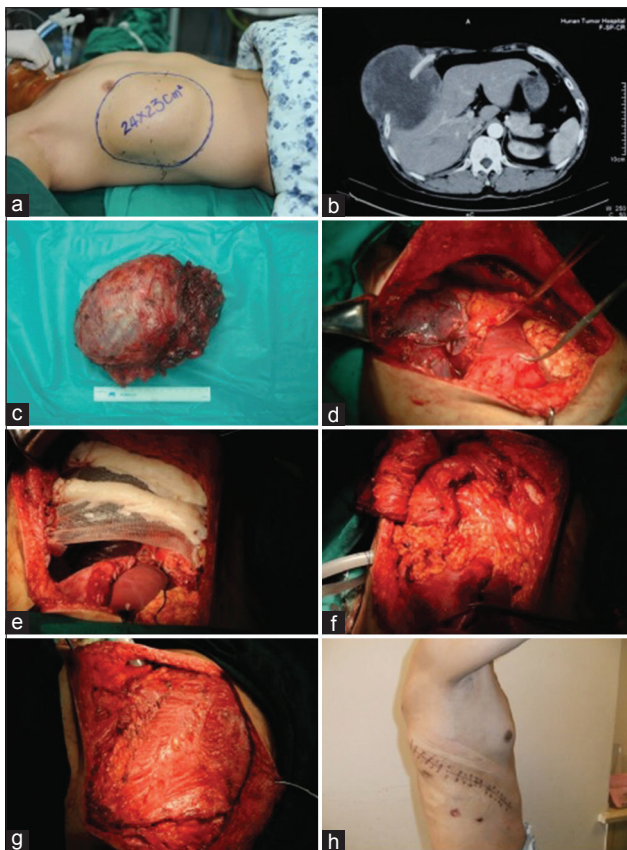


Figure 1: Male patient with the right side chondrosarcoma of the thoracoabdominal wall. A: preoperative appearance; B: preoperative imaging results; C: the removed tumor; D: the huge defect of chest abdominal wall; E-F: reconstructing the huge chest wall defect; G: reconstructing the huge chest wall defect; H: 14 days after surgery.

bony hardness effectively because the lower ribs in the chest wall had been removed and the bony structure had been destroyed during the chest wall reconstruction.^[3]

Here, if the superior border of the chest wall defect was over the top of the diaphragm, we used net and bone cement for the reconstruction of the chest wall ribs. If the superior border of the chest wall defect was under the top of diaphragm, we joined the

inferior border defect of the chest wall and the diaphragm together with a “Prolene” net to make part of the chest into an “abdomen”, so that we could eliminate the sinus phrenicocostalis to prevent paradoxical breathing.^[4]

Six cases did not exhibit breathing difficulties after surgery and had no obvious change on the activity of daily living 3 months after surgery. To prevent failure of the surgery due to Prolene net or bone cement leakage after a skin necrosis around the incision or after an infection, reliable autologous tissue (e.g., a muscle flap or the greater omentum) needed to separate the skin and the Prolene net.

Declaration of patient consent

The authors certify that they have obtained all appropriate patient consent forms. In the form the patient(s) has/have given his/her/their consent for his/her/their images and other clinical information to be reported in the journal. The patients understand that their names and initials will not be published and due efforts will be made to conceal their identity, but anonymity cannot be guaranteed.

Financial support and sponsorship

This work was supported by the provincial key construction specialty: Chest surgery foundation from Health Department of Hunan Province, Hunan health science and education, 2009-1.

Conflicts of interest

There are no conflicts of interest.

REFERENCES

1. Tukiainen E. Chest wall reconstruction after oncological resections. *Scand J Surg* 2013;102:9-13. doi: 10.1177/145749691310200103.
2. Tukiainen E, Popov P, Asko-Seljavaara S. Microvascular reconstructions of full-thickness oncological chest wall defects. *Ann Surg* 2003;238:794-802. doi: 10.1097/01.sla.0000098626.79986.51.
3. Berthet JP, Wihlm JM, Canaud L, Joyeux F, Cosma C, Hireche K, *et al.* The combination of polytetrafluoroethylene mesh and titanium rib implants: An innovative process for reconstructing large full thickness chest wall defects. *Eur J Cardiothorac Surg* 2012;42:444-53. doi: 10.1093/ejcts/ezs028.
4. Rocco G, Fazioli F, La Manna C, La Rocca A, Mori S, Palaia R, *et al.* Omental flap and titanium plates provide structural stability and protection of the mediastinum after extensive sternocostal resection. *Ann Thorac Surg* 2010;90:e14-6. doi: 10.1016/j.athoracsur.2010.04.071.