



Arthroscopic Dorsal Closing-Wedge Osteotomy of Metatarsal Head for Management of Freiberg Infraction

Tun Hing Lui, M.B.B.S.(HK), and Andrew Ka Hei Fan, M.B.B.S.(HK)

Abstract: Freiberg infraction is a relatively rare osteochondrosis of the lesser metatarsal head. Operative treatment is indicated if conservative treatment fails to relieve the pain. Dorsal closing-wedge osteotomy is a realignment osteotomy of the metatarsal head and neck to redirect the articular surface, allowing the intact plantar cartilage to articulate with the proximal phalanx. The purpose of this technical note is to describe the details of arthroscopic dorsal closing-wedge osteotomy of the metatarsal head for management of Freiberg infraction. Although dorsal closing-wedge osteotomy has been proposed for the treatment of late-stage Freiberg infraction, we reserve this technique for early stages of the disease.

Freiberg infraction is a relatively rare osteochondrosis of the lesser metatarsal head.^{1,2} It usually involves the second metatarsal in female patients and presents during the second or third decade of life.¹⁻³ The pathophysiology is unknown, but studies suggest a combination of vascular compromise, genetic predisposition, and altered biomechanics.^{4,5} Diagnosis is made clinically, and imaging is used for confirmation.⁵

Conservative measures to decrease foot pressure and unload the affected metatarsal are the first-line treatments.^{1,5} They are thought to be effective in the early stages but not the late stages of the disease.⁶ Operative treatment is indicated if conservative treatment fails to relieve the pain, and it can be divided into joint-preserving and joint-reconstructing procedures.¹ These

procedures include intra- or extra-articular dorsal closing-wedge osteotomy, osteochondral transplant, metatarsal shortening osteotomy, marrow stimulation, and micronized allograft cartilage matrix.^{3-5,7-11} Osteotomy improves pain and function in terms of shortening the metatarsal length and restoring the metatarsal head's sphericity and metatarsophalangeal joint congruency.^{6,12,13} In advanced disease, open or arthroscopic salvage procedures including debridement, removal of the loose bodies, synovectomy, drilling of the metatarsal head, distraction arthroplasty, interpositional arthroplasty, and resection arthroplasty have been proposed.^{2,5,14-17}

Dorsal closing-wedge osteotomy is a realignment osteotomy of the metatarsal head and neck. Its aim is to redirect the articular surface, allowing the intact plantar cartilage to articulate with the proximal phalanx.¹¹ Theoretically, dorsal closing-wedge osteotomy can also restore the blood supply to the metatarsal head, preventing further deformity and collapse.¹¹ To minimize the surgical trauma, surgeons are interested in exploring minimally invasive approaches to osteotomy. Percutaneous surgery bears the risk of damage to the normal cartilage as it is essentially a blind procedure.¹⁰ In this report, we describe the technical details of arthroscopic dorsal closing-wedge osteotomy of the metatarsal head for management of Freiberg infraction. The whole procedure can be performed in a minimally invasive manner and under arthroscopic visualization. Although it has been proposed for treatment of late-stage Freiberg infraction,⁶ we reserve it for early

From the Department of Orthopaedics and Traumatology, North District Hospital (T.H.L.), Sheung Shui, and Department of Orthopaedics and Traumatology, United Christian Hospital (A.K.H.F.), Hong Kong, China.

The authors report that they have no conflicts of interest in the authorship and publication of this article. Full ICMJE author disclosure forms are available for this article online, as [supplementary material](#).

Received June 4, 2019; accepted July 2, 2019.

Address correspondence to Tun Hing Lui, M.B.B.S.(HK), Department of Orthopaedics and Traumatology, North District Hospital, 9 Po Kin Road, Sheung Shui, NT, Hong Kong SAR, China. E-mail: luithderek@yahoo.co.uk

© 2019 by the Arthroscopy Association of North America. Published by Elsevier. This is an open access article under the CC BY-NC-ND license (<http://creativecommons.org/licenses/by-nc-nd/4.0/>).

2212-6287/19724

<https://doi.org/10.1016/j.eats.2019.07.003>

stages of the disease.¹¹ This arthroscopic approach is indicated for early-stage Freiberg infraction with the lesion localized at the dorsal part of the metatarsal head. It is contraindicated if there is late-stage Freiberg infraction or the pain is not related to the disease (Table 1).

Technique

In this illustrated case, the second metatarsal head is involved and second metatarsophalangeal arthroscopy is performed. The same arthroscopic technique can be applied for Freiberg infraction of the other metatarsal heads.

Preoperative Planning and Patient Positioning

The patient's symptoms should be localized to the corresponding metatarsophalangeal joint with local joint-line tenderness. Other causes of metatarsalgia including Morton neuroma, stress fracture of the metatarsal, and synovitis should be excluded. Radiographs, computed tomogram, and magnetic resonance are helpful to confirm the diagnosis and stage the disease.⁸

The patient is in the supine position. A triangular supporting frame (Innomed, Savannah, GA) is placed under the knee to flex the knee and put the foot flat onto the operating table. The surgeon should sit at the distal end of the table. A thigh tourniquet is applied to provide a bloodless operative field. A 1.9-mm 30° arthroscope (Henke Sass Wolf, Tuttlingen, Germany) is used for this procedure. Fluid inflow is by gravity, and no arthro-pump is used.

Portal Placement

This procedure is performed via the dorsomedial and dorsolateral portals, which are at the metatarsophalangeal joint level and at the medial and lateral sides of the extensor digitorum longus tendon to the second toe, respectively (Fig 1).

Arthroscopic Debridement of Osteochondral Lesion

Three-millimeter skin incisions are made at the portal sites. The subcutaneous tissue is bluntly dissected by a hemostat, and the joint capsule is perforated by the tip of the hemostat. Metatarsophalangeal arthroscopy is performed. The dorsomedial and dorsolateral portals are interchangeable as the viewing and working portals.

Table 1. Indications and Contraindications of Arthroscopic Dorsal Closing-Wedge Osteotomy of Metatarsal Head for Management of Freiberg Infraction

Indications	Early-stage Freiberg infraction with lesion localized at dorsal part of metatarsal head
Contraindications	Late-stage Freiberg infraction Pain is not related to disease

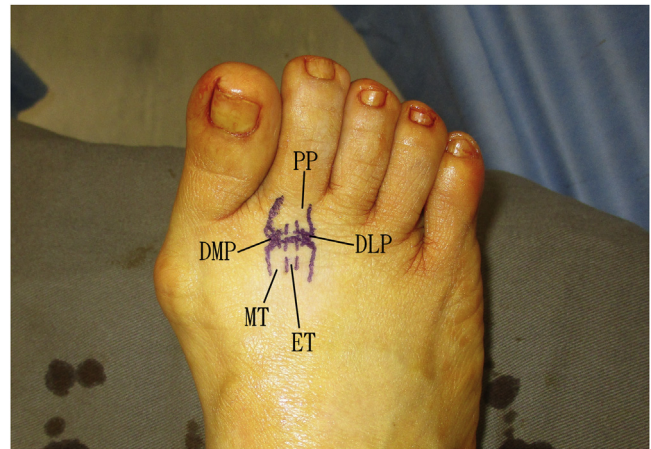


Fig 1. Arthroscopic dorsal closing-wedge osteotomy of the second metatarsal (MT) head of the right foot. The patient is in the supine position. A triangular supporting frame is placed under the knee to flex the knee and put the foot flat onto the operating table. This procedure is performed via the dorsomedial portal (DMP) and dorsolateral portal (DLP), which are at the metatarsophalangeal joint level and at the medial and lateral sides of the extensor digitorum longus tendon to the second toe, respectively. (ET, extensor tendon; PP, proximal phalanx.)

Any associated inflamed synovium is resected. Loose bodies, if present, are removed. The location and size of the osteochondral lesion are assessed. The condition of the remaining cartilage is also examined. The

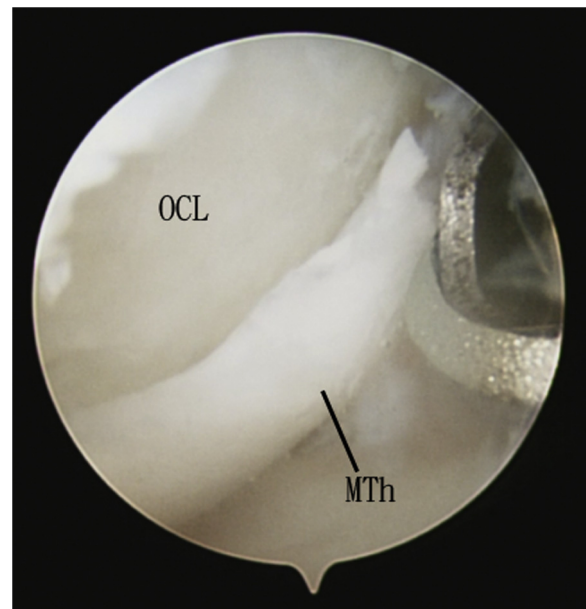


Fig 2. Arthroscopic dorsal closing-wedge osteotomy of the second metatarsal head (MTh) of the right foot. The patient is in the supine position. A triangular supporting frame is placed under the knee to flex the knee and put the foot flat onto the operating table. The dorsolateral portal is the viewing portal, and the dorsomedial portal is the working portal. The osteochondral lesion (OCL) is debrided with an arthroscopic shaver, and all the loose cartilage flaps are removed.

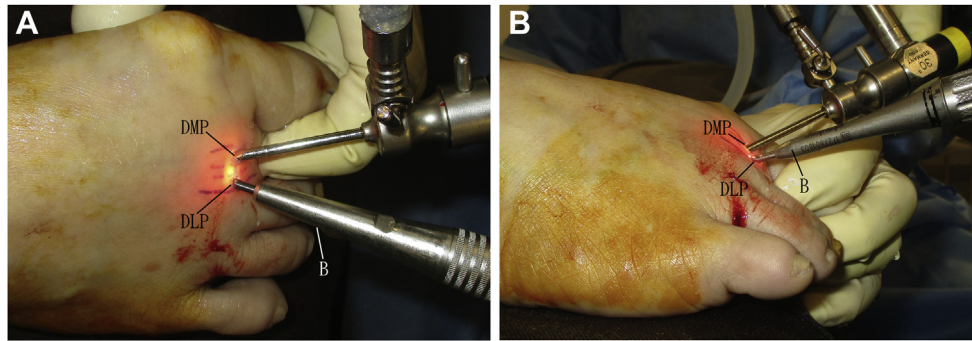


Fig 3. Arthroscopic dorsal closing-wedge osteotomy of the second metatarsal head of the right foot. The patient is in the supine position. A triangular supporting frame is placed under the knee to flex the knee and put the foot flat onto the operating table. The metatarsophalangeal joint undergoes plantar flexion to facilitate the approach to the dorsal half of the metatarsal head. (A) Dorsoplantar view. (B) Lateral view. (B, burr; DLP, dorsolateral portal; DMP, dorsomedial portal.)

osteocondral lesion is debrided with an arthroscopic shaver (Dyonics; Smith & Nephew, Andover, MA), and all the loose cartilage flaps are removed (Fig 2).

Arthroscopic Wedge Osteotomy of Metatarsal Head

The metatarsophalangeal joint undergoes plantar flexion to facilitate access to the dorsal half of the metatarsal head (Fig 3). The dorsolateral portal is the viewing portal, and the dorsomedial portal is the working portal. The medial half of the bone wedge is resected via the osteochondral lesion by a 1.5-mm burr (Signature high-speed drill; Stryker, Kalamazoo,

MI) (Fig 4). The direction of resection is from dorsal-distal to plantar-proximal. The inclination of the bone wedge should be adjusted according to the presence of associated metatarsal anomalies. If there is associated callosity under the metatarsal head, the burr is positioned more horizontally. This results in elevation of the metatarsal head after closing the wedge osteotomy site. If the metatarsal is excessively long, the burr is positioned more vertically. This results in shortening of the metatarsal after closing the

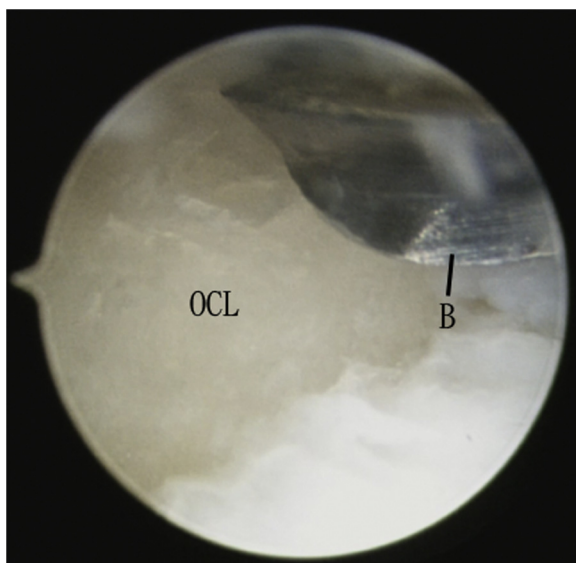


Fig 4. Arthroscopic dorsal closing-wedge osteotomy of the second metatarsal head of the right foot. The patient is in the supine position. A triangular supporting frame is placed under the knee to flex the knee and put the foot flat onto the operating table. The dorsolateral portal is the viewing portal, and the dorsomedial portal is the working portal. The medial half of the bone wedge is resected via the osteochondral lesion (OCL) by a 1.5-mm burr (B).

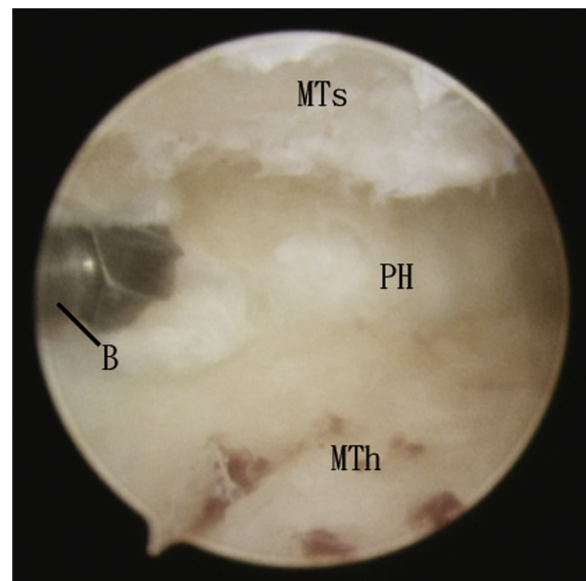


Fig 5. Arthroscopic dorsal closing-wedge osteotomy of the second metatarsal head of the right foot. The patient is in the supine position. A triangular supporting frame is placed under the knee to flex the knee and put the foot flat onto the operating table. The dorsomedial portal is the viewing portal, and the dorsolateral portal is the working portal. The lateral half of the bone wedge is resected with the burr (B) via the dorsolateral portal. (MTh, metatarsal head fragment; MTs, metatarsal shaft fragment; PH, plantar hinge of osteotomy site.)

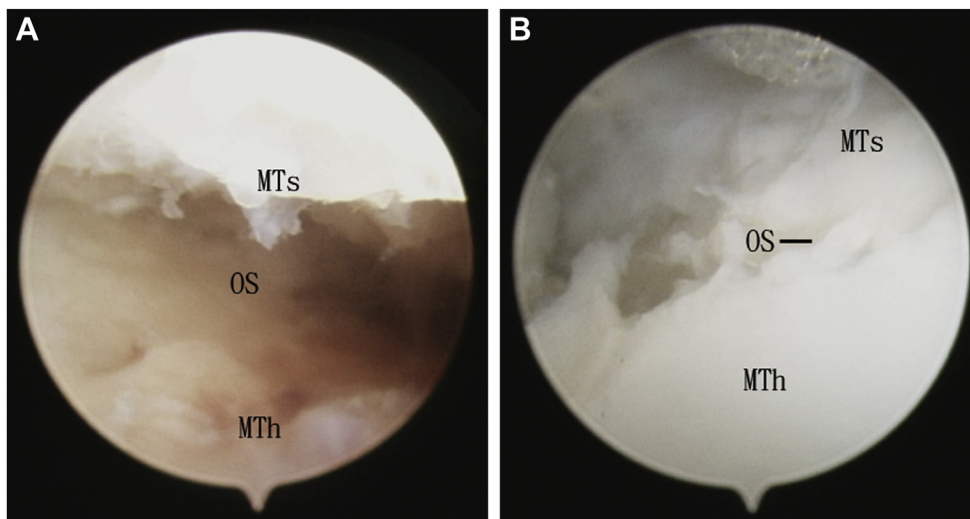


Fig 6. Arthroscopic dorsal closing-wedge osteotomy of the second metatarsal head of the right foot. The patient is in the supine position. A triangular supporting frame is placed under the knee to flex the knee and put the foot flat onto the operating table. The dorsomedial portal is the viewing portal. (A) Arthroscopic view of osteotomy site (OS) before its closure. (B) Arthroscopic view of osteotomy site (OS) after its closure. (MTh, metatarsal head fragment; MTs, metatarsal shaft fragment.)

wedge osteotomy site. The medial edge of the metatarsal is regularly “probed” with the burr to determine the depth of bone resection. The plantar cortical hinge can be drilled with the burr to facilitate subsequent closure of the osteotomy site, but the gross integrity of the hinge should be preserved.

After resection of the medial half of the bone wedge is completed, the arthroscope is switched to the dorsomedial portal. The lateral half of the bone wedge is resected with the burr via the dorsolateral portal (Fig 5). It is important to keep the orientation of bone resection the same as the resection of the medial half of the bone wedge.

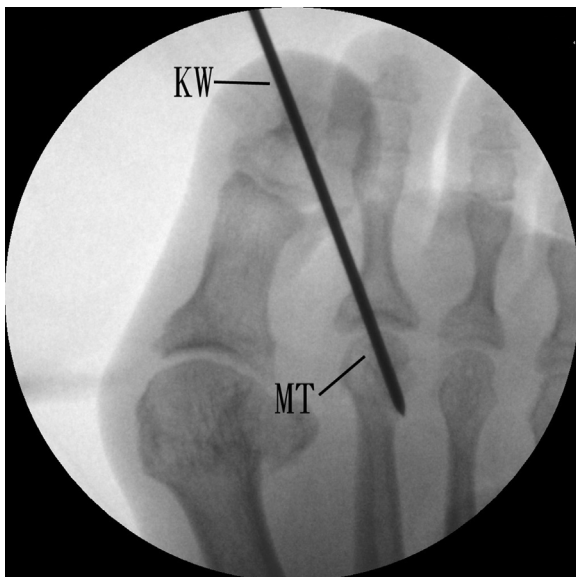


Fig 7. Arthroscopic dorsal closing-wedge osteotomy of the second metatarsal (MT) head of the right foot. The patient is in the supine position. A triangular supporting frame is placed under the knee to flex the knee and put the foot flat onto the operating table. The osteotomy site is stabilized with a 1.6-mm K-wire (KW).

Closing of Wedge Osteotomy

After completion of resection of the bone wedge, the osteotomy site can be closed up by pushing the toe proximally (Fig 6). The osteotomy site can be examined for completeness of closure. The plantar metatarsal head cartilage is shifted dorsally.

Fixation With K-Wire

The osteotomy site is stabilized with a 1.6-mm K-wire (Zimmer, Warsaw, IN). If there is associated instability of the metatarsophalangeal joint, the K-wire can also be used to splint the joint (Fig 7, Table 2, Video 1).

Rehabilitation and K-Wire Removal

The K-wire is retained for 4 to 6 weeks. The patient is advised to be non-weight bearing during this period. Toe mobilization and weight-bearing walking can be started after removal of the K-wire.

Table 2. Pearls and Pitfalls of Arthroscopic Dorsal Closing-Wedge Osteotomy of Metatarsal Head for Management of Freiberg Infracture

Pearls

- The surgeon sits at the end of the operating table, allowing a more logical arthroscopic orientation and ergonomic hand motion during the osteotomy procedure.
- The inclination of the bone wedge should be adjusted according to the presence of associated metatarsal anomalies.
- The orientation of resection of the lateral half of the bone wedge should be the same as the resection of the medial half of the bone wedge.
- The edges of the metatarsal are regularly “probed” with the burr to determine the depth of bone resection.

Pitfalls

- The osteotomy will be unstable if the plantar cortical hinge is broken.
- The osteotomy cannot be closed up if the orientation of bone cut at the medial and lateral halves of the osteotomy is different.

Table 3. Advantages and Risks of Arthroscopic Dorsal Closing-Wedge Osteotomy of Metatarsal Head for Management of Freiberg Infraction

Advantages
Better cosmetic results
Less pain
Less surgical trauma
Preservation of normal articular cartilage
Risks
Injury to interdigital nerve and vessels
Risk of vascular compromise of metatarsal head fragment
Risk of stiff or floating toe
Transfer metatarsalgia

Discussion

Arthroscopic surgery can avoid excessive damage to normal cartilage and allows titration of the size of bone wedge removed. Because this approach is an intra-articular dorsal closing-wedge osteotomy, it enables less metatarsalgia than that of extra-articular osteotomy, which often leads to excessive elevation of the metatarsal head.¹⁵ The surgeon sits at the end of the operating table, allowing a more logical arthroscopic orientation and ergonomic hand motion during the osteotomy procedure.

This arthroscopic approach has the advantages of better cosmetic results, less pain, less surgical trauma, and preservation of the normal articular cartilage. The potential risks of this technique include injury to the interdigital nerve and vessels. There is a risk of vascular compromise of the metatarsal head fragment. Similarly to other surgical techniques, our approach carries a risk of a stiff or floating toe and transfer metatarsalgia (Table 3). This technique is not technically demanding and can be attempted by the average foot and ankle arthroscopist.

References

- Seybold JD, Zide JR. Treatment of Freiberg disease. *Foot Ankle Clin* 2018;23:157-169.
- Lee SK, Kim KJ, Yang DS, Choy WS. Metatarsophalangeal arthroscopic treatment for early stage IV of Freiberg's disease: A case report. *Eur J Orthop Surg Traumatol* 2012;22:233-237 (suppl 1).
- Desai S. Freiberg's infraction treated with metatarsal shortening osteotomy, marrow stimulation, and micronized allograft cartilage matrix: A case report. *Foot Ankle Spec* 2017;10:258-262.
- Daoudi A, Abbassi N, Yahyaoui M, et al. Gauthier's osteotomy and fixation using osteosuture in the treatment of Freiberg's disease. *Pan Afr Med J* 2018;29:33.
- Talusan PG, Diaz-Collado PJ, Reach JS Jr. Freiberg's infraction: Diagnosis and treatment. *Foot Ankle Spec* 2014;7:52-56.
- Lin SY, Cheng YM, Huang PJ. Freiberg's infraction—Treatment with metatarsal neck dorsal closing wedge osteotomy: Report of two cases. *Kaohsiung J Med Sci* 2006;22:580-585.
- Pereira BS, Frada T, Freitas D, et al. Long-term follow-up of dorsal wedge osteotomy for pediatric Freiberg disease. *Foot Ankle Int* 2016;37:90-95.
- Chao KH, Lee CH, Lin LC. Surgery for symptomatic Freiberg's disease: Extraarticular dorsal closing-wedge osteotomy in 13 patients followed for 2-4 years. *Acta Orthop Scand* 1999;70:483-486.
- Ikoma K, Maki M, Kido M, et al. Extra-articular dorsal closing-wedge osteotomy to treat late-stage Freiberg disease using polyblend sutures: Technical tips and clinical results. *Int Orthop* 2014;38:1401-1405.
- Lee SK, Chung MS, Baek GH, Oh JH, Lee YH, Gong HS. Treatment of Freiberg disease with intra-articular dorsal wedge osteotomy and absorbable pin fixation. *Foot Ankle Int* 2007;28:43-48.
- Kim J, Choi WJ, Park YJ, Lee JW. Modified Weil osteotomy for the treatment of Freiberg's disease. *Clin Orthop Surg* 2012;4:300-306.
- Lee HS, Kim YC, Choi JH, Chung JW. Weil and dorsal closing wedge osteotomy for Freiberg's disease. *J Am Podiatr Med Assoc* 2016;106:100-108.
- Helix-Giordanino M, Randier E, Frey S, Piclet B. French association of foot surgery (AFCP). Treatment of Freiberg's disease by Gauthier's dorsal cuneiform osteotomy: Retrospective study of 30 cases. *Orthop Traumatol Surg Res* 2015;101:S221-S225 (suppl).
- Erdil M, Imren Y, Bilsel K, Erzincanli A, Bulbul M, Tuncay I. Joint debridement and metatarsal remodeling in Freiberg's infraction. *J Am Podiatr Med Assoc* 2013;103:185-190.
- DeVries JG, Amiot RA, Cummings P, Sockrider N. Freiberg's infraction of the second metatarsal treated with autologous osteochondral transplantation and external fixation. *J Foot Ankle Surg* 2008;47:565-570.
- Lui TH. Arthroscopic interpositional arthroplasty for Freiberg's disease. *Knee Surg Sports Traumatol Arthrosc* 2007;15:555-559.
- Lui TH. Arthroscopic interpositional arthroplasty of the second metatarsophalangeal joint. *Arthrosc Tech* 2016;5:e1333-e1338.