

## Electron microscopy in Cogan–Reese syndrome

Geeta Behera, Tapas C Nag<sup>1</sup>, Sudarshan K Khokhar<sup>2</sup>,  
Suneel Sangaraju

**Key words:** Cogan–Reese syndrome, iridocorneal endothelial syndrome, iris nodule, melanocyte, transmission electron microscopy

The iridocorneal endothelial (ICE) syndrome consists of Chandler’s syndrome, essential iris atrophy, and Cogan–Reese syndrome.<sup>[1]</sup> It is usually unilateral, observed in the third decade of life. The ocular changes of corneal edema, glaucoma, and iris defects in ICE syndromes are secondary to corneal endothelial abnormality.<sup>[2]</sup> Most electron microscopy studies focus on Chandler’s syndrome with detailed evaluation of the abnormal endothelium, the other two variants with predominantly iris changes and glaucoma being underreported.<sup>[3–6]</sup> We performed histopathology and transmission electron microscopy (TEM) in the trabecular block and iris nodule in a case of Cogan–Reese syndrome to further explore this pathology.

Access this article online	
Quick Response Code:	Website: www.ijo.in
	DOI: 10.4103/ijo.IJO_2777_21

Department of Ophthalmology, Jawaharlal Institute of Post-Graduate Medical Education and Research (JIPMER), Puducherry, <sup>1</sup>Department of Anatomy, <sup>2</sup>Dr. Rajendra Prasad Centre for Ophthalmic Sciences, All India Institute of Medical Sciences (AIIMS), New Delhi, India

**Correspondence to:** Dr. Geeta Behera, Department of Ophthalmology, Jawaharlal Institute of Post-Graduate Medical Education and Research (JIPMER), Puducherry - 605 006, India. E-mail: geeta.anandaraja@gmail.com

Received: 08-Nov-2021

Revision: 09-Dec-2021

Accepted: 11-Jan-2022

Published: 30-Jun-2022

### Case

A 26-year-old woman presented with gradual diminution of vision for 5 months in her right eye. Her BCVA was 20/20 in both eyes. On slit-lamp examination, the right cornea showed a mild subepithelial haze and hammered metal appearance of the endothelium; the anterior chamber was shallow, and the iris pattern effaced with multiple dark brown nodules and ectropion uveae in the superior and temporal quadrants causing pupillary distortion [Fig. 1]. Right eye fundus revealed advanced glaucomatous optic neuropathy with marked neuroretinal rim thinning and a cup-to-disc ratio of 0.9:1. The left eye was normal. The intraocular pressure (IOP) was OD: 40 mmHg (oral acetazolamide, topical timolol 0.5%, and brimonidine 0.15%) and OS: 12 mmHg. Gonioscopy showed OD: three quadrants of peripheral anterior synechiae (entire superior angle and inferonasal angle) and OS: normal. Visual fields revealed OD: advanced glaucomatous field changes OD: MD: -12.76 dB, PSD: 9.33 dB;  $P < 0.5\%$ , and OS: normal field. Specular microscopy of the right eye showed pleomorphic endothelial cells with dark-light reversal typical of “ICE cells.” A diagnosis of Cogan–Reese syndrome was made based on clinical findings. Conventional trabeculectomy with mitomycin C was done for IOP control. Toward the end of the surgery, an iris nodule was excised through the paracentesis port. A portion of the trabecular block underwent histopathological evaluation; the rest and the iris nodule underwent TEM. The IOP of the patient was well controlled until 6 months of postoperative follow-up.

### Transmission electron microscopy evaluation

A part of the trabecular tissue and iris nodule was analyzed by TEM. The tissue samples were fixed in modified Karnovsky’s fixative (2% paraformaldehyde and 2.5% glutaraldehyde in 0.1 M phosphate buffer, pH 7.4) for 4 h at 4°C. Following washes, they were postfixated in 1% osmium tetroxide for 1 h, dehydrated in acetone, infiltrated, and polymerized in Araldite

This is an open access journal, and articles are distributed under the terms of the Creative Commons Attribution-NonCommercial-ShareAlike 4.0 License, which allows others to remix, tweak, and build upon the work non-commercially, as long as appropriate credit is given and the new creations are licensed under the identical terms.

**For reprints contact:** WKHLRPMedknow\_reprints@wolterskluwer.com

**Cite this article as:** Behera G, Nag TC, Khokhar SK, Sangaraju S. Electron microscopy in Cogan–Reese syndrome. Indian J Ophthalmol 2022;70:2666-8.

CY212. Sections (70–80 nm thick) were contrasted with uranyl acetate and alkaline lead citrate and viewed under a Tecnai G2-20 S-Twin transmission electron microscope (Fei Company, Eindhoven, The Netherlands). Images were digitally acquired using software (DigitalMicrograph, Gatan, Inc).

### Histopathology and TEM

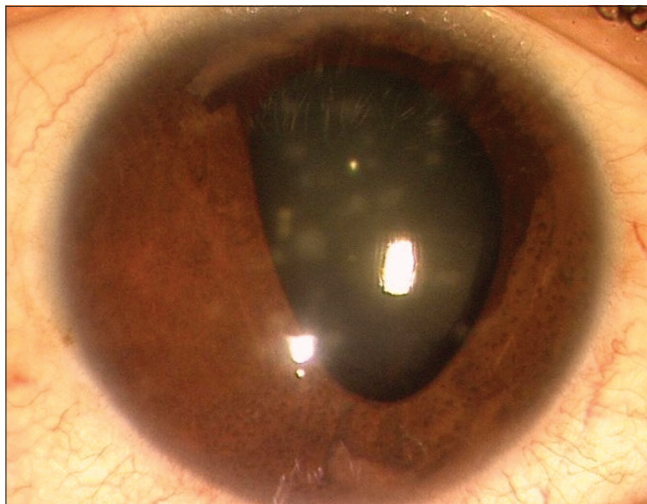
Histopathology of the trabecular tissue block revealed fibrous tissue and clumps of cells with a membrane on the endothelial side. TEM showed irregular Descemet's membrane with loose fibrillary material [Fig. 2a and b]. A nonspecific, irregular

layer containing wide-spaced collagen, supposedly parts of the abnormal Descemet's membrane, was noted [Fig. 2b]. The angle tissue showed extensive infoldings of the abnormal Descemet's membrane [Fig. 2c and d] with lysosome-like granules [Fig. 2d, long arrow]. Abnormal degenerating keratocyte processes and empty space, indicating loss of collagen fibrils, were also noted [Fig. 2e and f]. On TEM of the iris nodule tissue, melanocytic cells with abnormal clumping of large melanin granules were noted [Fig. 3a, stars]. A part of the anterior iris surface excised with the nodule showed an amorphous basement membrane overlying the iris stroma, which appeared normal [Fig. 3b, arrow].

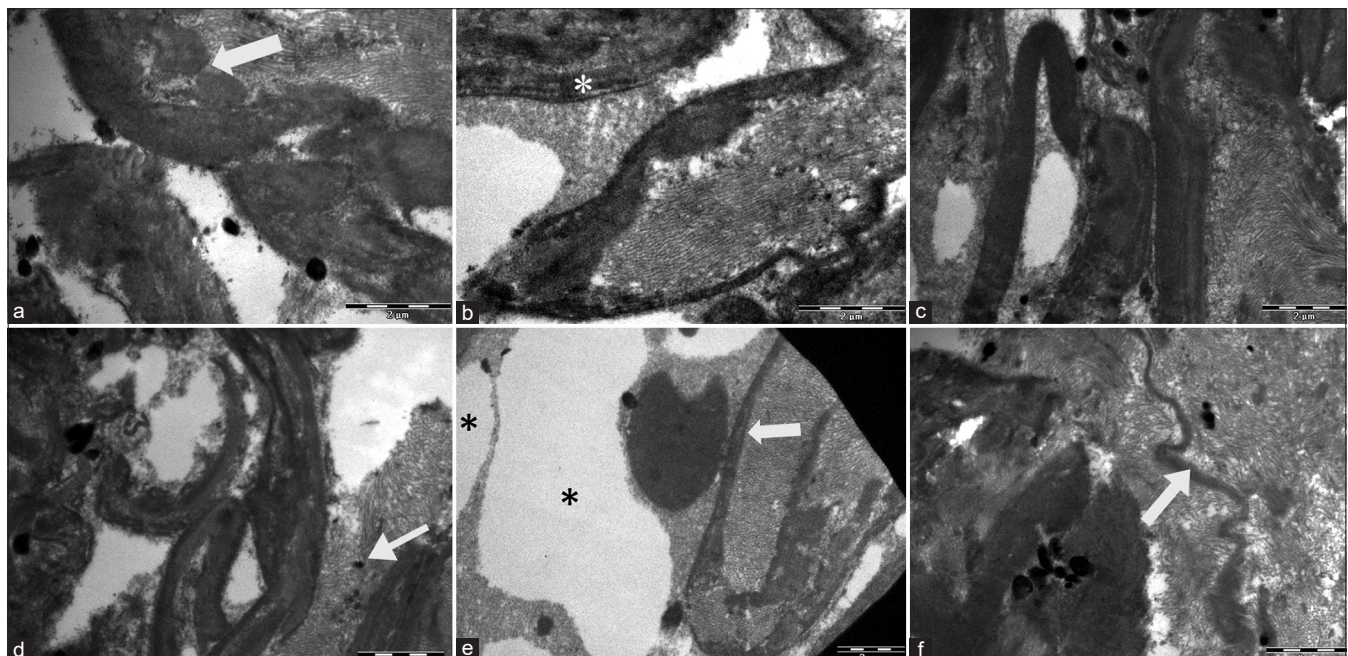
### Discussion

Eagle *et al.*, in 1980, described electron microscopy features of Cogan–Reese syndrome in an enucleated eye.<sup>[5]</sup> They observed the corneal endothelium with an abnormal basement membrane resembling Descemet's membrane, extending across the angle onto the iris surface, causing angle closure. This was predominantly filamentous with the patches of the banded basement membrane, its contraction responsible for angle-closure glaucoma.<sup>[5]</sup> Our patient similarly had extensive peripheral anterior synechiae (270 degrees) that resulted in glaucoma, needing filtering surgery. Tissue from the angle showed the presence of an abnormal membrane with wide-spaced collagen, which is likely to have caused the angle closure [Fig. 1a and b]. We also noted abnormal degenerating keratocyte processes and empty space, indicating loss of collagen fibrils probably due to associated pathological changes.

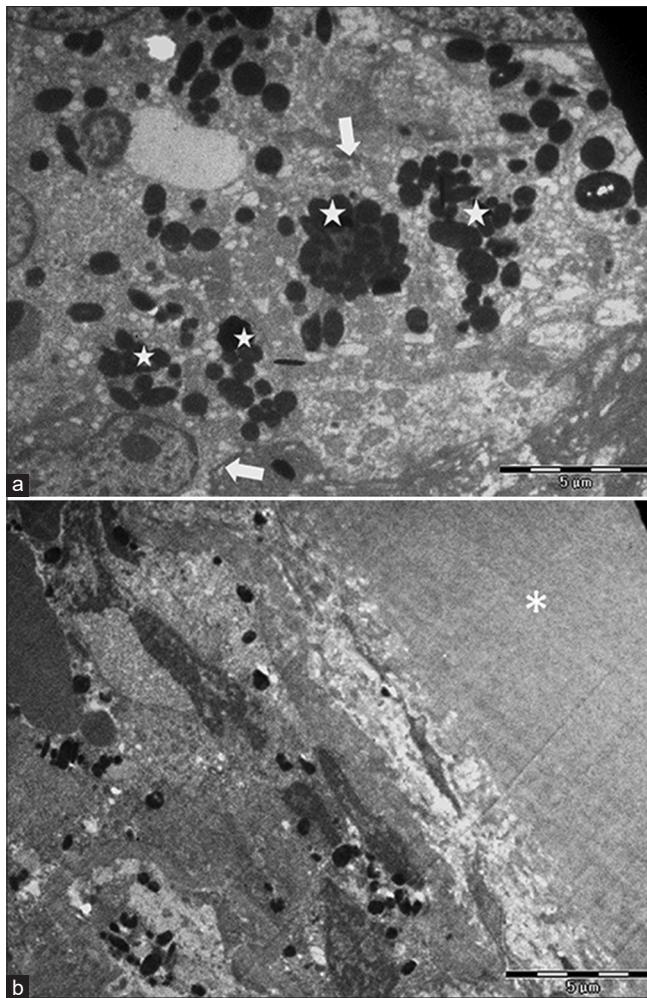
Eagle *et al.* reported abnormal endothelial cells and membrane extending onto the iris surface with effacement of the iris and ectropion uveae, and two types of melanocytic cells in the iridic stroma: heavily pigmented, plump surface



**Figure 1:** Slit-lamp photograph of the right eye showing an effaced iris with superficial nodules and ectropion uvea in the superior and temporal quadrants, leading to a distorted pupil. Anterior lenticular opacities are also seen



**Figure 2:** Transmission electron micrographs of the trabecular block showing irregular Descemet's membrane remnants (a-d); (a) with loose fibrillary material (arrow). (b) A nonspecific, irregular layer containing wide-spaced collagen (\*), supposedly abnormal Descemet's membrane. (c and d) Folded abnormal Descemet's membrane (d) with lysosome like granules (long arrow). (e) Abnormal degenerating keratocyte processes (arrows). Irregular stromal collagen lamellae and empty spaces (\*), indicating keratocyte degeneration. (f) Loose fibrillary material with the degenerating keratocyte process (arrow)



**Figure 3:** Transmission electron micrographs of the iris nodule showing (a) melanocytic cells (arrows) of the iris, showing abnormal clumping of the large oval to spherical melanin granules (stars). (b) An abnormal amorphous membrane overlying the iris stroma (\*)

cells containing large melanin granules and underlying stromal melanocytes.<sup>[5]</sup> Iris nodules in the endothelialised part of the anterior iris surface were composed of plump melanocytic cells with large melanin granules.<sup>[5]</sup> We too observed an abnormal amorphous basement membrane and abnormal melanocytic cells with clumping of large melanin granules in the iris nodule overlying the stroma [Fig. 2c]. These atypical melanocytes have not been described in histopathological or electron microscopy studies of the other variants (Chandler's syndrome and essential iris atrophy) of ICE syndrome.<sup>[3,4,6]</sup> The prior description of plump melanocytic cells with abnormal clumping of melanin nodules matches our findings. Eagle *et al.*<sup>[5]</sup> postulated that the plump cells with larger melanin granules were atypical melanocytes and probably a primary iris abnormality exclusive to Cogan–Reese syndrome.

The small portion of anterior iris tissue to which the nodule was attached showed an amorphous membrane with normal iris stroma underlying it. The loss of iris surface architecture was due to the surface naevus and the sheet of endothelial cells/abnormal basement membrane material on the anterior

iris. The iris nodules were formed either due to the active proliferation of melanocytes or herniation of iridic stroma.<sup>[5]</sup>

We performed TEM for small tissue specimens of the trabecular block (1 mm × 1 mm) and the iris nodule, in which no endothelial cells were present. They may have been lost due to irrigation during the surgery. Hence, we cannot comment on the typical changes described in ICE cells in studies using larger tissue samples. Therefore, our observations and interpretations need confirmation with more extensive studies. Various theories about the evolution of this rare, acquired disorder include virally inducing corneal endothelial disorder, an endothelioma or embryologic ectopia of ocular surface epithelium as evidenced by immunocytochemistry.<sup>[6–8]</sup> Until a causal association can be proven by more extensive studies evaluating the different variants, the origin of ICE syndrome will remain an enigma.

#### Patient consent

Written informed consent was obtained from the patient for publication of this case and any accompanying images.

#### Declaration of patient consent

The authors certify that they have obtained all appropriate patient consent forms. In the form the patient(s) has/have given his/her/their consent for his/her/their images and other clinical information to be reported in the journal. The patients understand that their names and initials will not be published and due efforts will be made to conceal their identity, but anonymity cannot be guaranteed.

#### Financial support and sponsorship

Nil.

#### Conflicts of interest

There are no conflicts of interest.

#### References

1. Yanoff M. Iridocorneal endothelial syndrome: Unification of a disease spectrum. *Surv Ophthalmol* 1979;24:1-2.
2. Sherrard ES, Frangoulis MA, Muir MG, Buckley RJ. The posterior surface of the cornea in the irido-corneal endothelial syndrome: A specular microscopical study. *Trans Ophthalmol Soc U K* 1985;104:766-74.
3. Patel A, Kenyon KR, Hirst LW, Quigley HA, Stark WJ, Meyer RF, *et al.* Clinicopathologic features of Chandler's syndrome. *Surv Ophthalmol* 1983;27:327-44.
4. Levy SG, McCartney AC, Sawada H, Dopping-Hepenstal PJ, Alexander RA, Moss J. Descemet's membrane in the iridocorneal-endothelial syndrome: Morphology and composition. *Exp Eye Res* 1995;61:323-33.
5. Eagle RC Jr, Font RL, Yanoff M, Fine BS. The iris naevus (Cogan-Reese) syndrome: Light and electron microscopic observations. *Br J Ophthalmol* 1980;64:446-52.
6. Eagle RC Jr, Shields JA. Iridocorneal endothelial syndrome with contralateral guttate endothelial dystrophy. A light and electron microscopic study. *Ophthalmology* 1987;94:862-70.
7. Alvarado JA, Underwood JL, Green WR, Wu S, Murphy CG, Hwang DG, *et al.* Detection of herpes simplex viral DNA in the iridocorneal endothelial syndrome. *Arch Ophthalmol* 1994;112:1601-9.
8. Levy SG, McCartney AC, Baghai MH, Barrett MC, Moss J. Pathology of the iridocorneal-endothelial syndrome. The ICE-cell. *Invest Ophthalmol Vis Sci* 1995;36:2592-601.