

Deep Brain Stimulation of the Globus Pallidus Internus in Patients with Intractable Tourette Syndrome: A 1-year Follow-up Study

Xiao-Hua Zhang, Jian-Yu Li, Yu-Qing Zhang, Yong-Jie Li

Department of Functional Neurosurgery, Beijing Institute of Functional Neurosurgery, Xuanwu Hospital, Capital Medical University, Beijing 100053, China

Abstract

Background: Deep brain stimulation (DBS) has been a promising treatment for patients with refractory Tourette syndrome (TS) for more than a decade. Despite successful DBS treatment of TS in more than 100 patients worldwide, studies with a large patient sample and long-term follow-up assessments are still scarce. Accordingly, we investigated the clinical efficacy and safety of globus pallidus internus (GPI) DBS in the treatment of intractable TS in 24 patients with a 1-year follow-up assessment.

Methods: Bilateral/unilateral GPI-DBS was performed in 24 patients with TS. We evaluated symptoms of tics and obsessive-compulsive disorder (OCD) through the Yale Global Tic Severity Scale (YGTSS) and Yale-Brown Obsessive-compulsive Scale (Y-BOCS). We used the Wechsler Adult Intelligence Scale-Revised in China (WAIS-RC) to evaluate the safety of the treatment. We conducted follow-up assessments of all patients for at least 12 months (12–99 months).

Results: Symptoms of tics and OCD were significantly relieved at a 12-month follow-up assessment. The mean YGTSS score was 74.04 ± 11.52 , 49.83 ± 10.91 , 32.58 ± 7.97 , and 31.21 ± 8.87 at baseline, 3, 6, and 12 months, respectively. The mean YGTSS scores obtained at the follow-up assessments were significantly different from the baseline ($P < 0.05$). The improvement in motor tics was superior to that in phonic tics. The mean Y-BOCS scores were 21.61 ± 4.97 , 18 ± 4.58 , 14.39 ± 3.99 , and 13.78 ± 4.56 at baseline, 3, 6, and 12 months, respectively ($P < 0.05$). We observed a remarkable improvement in psychiatric comorbidities, such as OCD and attention-deficit hyperactivity disorder, after the procedure. WAIS-RC scores were comparable before and after the operation. There were no severe postoperative complications.

Conclusion: GPI-DBS appears to comprehensively alleviate tic symptoms and psychiatric comorbidities in patients with TS, thus significantly improving patients' quality of life.

Key words: Deep Brain Stimulation; Tourette Syndrome; Treatment

INTRODUCTION

Tourette syndrome (TS) is a childhood neuropsychiatric disorder characterized by motor and phonic tics. TS is often complicated by behavioral disorders such as attention-deficit hyperactivity disorder (ADHD), obsessive-compulsive disorder (OCD), and anxiety and emotional disorders. Approximately one-third of TS patients engage in self-injurious behaviors. As a self-limited disease, the symptoms of TS gradually disappear in most patients after puberty. While TS symptoms are often controlled effectively via behavioral and drug therapies, conventional therapy does not work for a small number of patients. Consequently,

symptoms continue into adulthood in this patient group.^[1] Since 1995, researchers have been working toward the use of stereotactic surgery in the treatment of TS.^[2] In 1999, bilateral subthalamic deep brain stimulation (DBS) was first

Address for correspondence: Prof. Yong-Jie Li, Department of Functional Neurosurgery, Beijing Institute of Functional Neurosurgery, Xuanwu Hospital, Capital Medical University, No. 45, Changchun Street, Xicheng District, Beijing 100053, China
E-Mail: lyj8828@vip.sina.com

This is an open access article distributed under the terms of the Creative Commons Attribution-NonCommercial-ShareAlike 3.0 License, which allows others to remix, tweak, and build upon the work non-commercially, as long as the author is credited and the new creations are licensed under the identical terms.

For reprints contact: reprints@medknow.com

© 2016 Chinese Medical Journal | Produced by Wolters Kluwer - Medknow

Received: 09-10-2015 **Edited by:** Peng Lyu

How to cite this article: Zhang XH, Li JY, Zhang YQ, Li YJ. Deep Brain Stimulation of the Globus Pallidus Internus in Patients with Intractable Tourette Syndrome: A 1-year Follow-up Study. Chin Med J 2016;129:1022-7.

Access this article online

Quick Response Code:



Website:
www.cmj.org

DOI:
10.4103/0366-6999.180512

applied in the treatment of TS with substantial efficacy.^[3] Subsequently, researchers have attempted the use of DBS for the treatment of TS with various targets.

This study was conducted at the Department of Functional Neurosurgery at Xuanwu Hospital, Capital Medical University. We performed globus pallidus internus (GPi) DBS on 25 patients with drug-resistant TS and conducted follow-up assessments of 24 of the patients for over 1 year. The treatment has demonstrated high efficacy with limited complications.

METHODS

Patients

Twenty-five patients with refractory TS were admitted to our hospital for treatment between September 2007 and August 2014. Following the electrode placement surgery, one of the 25 patients exhibited clear signs of electrode deviation. Specifically, he experienced severe anxiety when the DBS stimulator was turned on. Because of this side effect and the observation that DBS produced no remarkable improvement in TS symptoms, the patient requested that the stimulator to be switched off. As this patient refused to undergo a procedure to adjust the electrode position, we excluded him from our research sample. Thus, the study population included 24 patients: 22 male and two female individuals aged 18–41 years (mean age: 25.3 ± 6.4 years) with an average medical history of TS of 14.7 years (8–21 years). Most of the patients had comorbid disorders, including OCD (18 cases), ADHD (16 cases), emotional disorder (15 cases), and self-injury behavior (three cases). All patients met the diagnostic criteria for TS as per the Diagnostic and Statistical Manual of Mental Disorders, 4th Edition, Text Revision (DSM-IV-TR)^[4] and exhibited complex motor tics complicated with phonic tics. The Diagnostic Confidence Index (DCI)^[5] scores for the participant group ranged from 58 to 96 (77.71 ± 12.12) [Table 1]. Surgical procedures were performed according to the *Declaration of Helsinki* and were approved by the Institutional Review Board at Xuanwu Hospital. Informed consent was obtained from all patients.

Inclusion and exclusion criteria

The surgical inclusion criteria were as follows:^[6] (1) TS diagnosis according to Diagnostic and Statistical Manual of Mental Disorders, 4th Edition, Text Revision criteria and the DCI, (2) chronic and severe tic disorder with severe functional impairment, (3) the patient had not responded to adequate doses of three classes of drugs administered for at least 12 weeks each or could not tolerate medications because of side effects, and (4) the patient was over 18 years of age. Our exclusion criteria barred patients whose tic disorder was attributable to another medical, psychiatric, or neurological disease, those with severe cardiovascular, pulmonary, or hematological disorders, and those with cerebral structural abnormalities from participation.

Surgical methods

We used a CRW human stereotactic instrument (Radionics Inc., USA) for location orientating. We first performed magnetic

resonance scanning (1.5 Tesla, Siemens, Germany) and identified the three-dimensional coordinates of the posterior ventral globus pallidus according to the Schaltenbrand–Wahren atlas. After placing the patient under local anesthesia with mild sedation, we created a 2.5 cm long incision in the scalp, starting 2.5 cm from the coronal suture and running parallel to the midline. After drilling a hole in the skull, we ensured that the dura mater had been coagulated before opening it via a cruciate incision. Using a high-impedance microelectrode with a tip diameter of 1–2 μm , we recorded extracellular discharges 10 mm above the target and confirmed the tissue characteristics. A DBS device (model 3387, Medtronic, Minneapolis, MN, USA) was implanted intracranially and fixed in place. We did not observe any adverse effects during the intraoperative prestimulation. We then incised the retroauricular and subclavian regions and implanted the connecting wire and implantable pulse generator (IPG, Kinetra 7428 or Solettra 7426).

We conducted bilateral GPi stimulation in twenty patients and unilateral GPi stimulation in four other patients who could not afford bilateral stimulation device or whose symptoms affected only one side. The DBS devices were switched on 1 week after surgery in a unipolar stimulation mode. The stimulation parameters included a pulse width of 90–120 μs , frequency of 65–185 Hz, and amplitude of 2.5–3.7 V. The stimulation parameters were individually adjusted according to the extent of symptomatic improvement and degree of side effects with the goal of obtaining an optimal treatment with minimal side effects. Patients continued the use of any medications they had been treated with before the surgery.

Efficacy assessment

The follow-up data were compiled by an assessment group that was independent from the surgical group. The severity scores for motor tics, phonic tics, overall damage, and global tics were assessed based on the Yale Global Tic Severity Scale (YGTSS). The assessments were performed 1 week before the surgery and 3, 6, and 12 months after the surgery. The symptoms of OCD were assessed using the Yale-Brown Obsessive-compulsive Scale (Y-BOCS). Surgical safety was evaluated by means of the Wechsler Adult Intelligence Scale-Revised in China (WAIS-RC).

The postoperative improvement rate of symptoms was calculated as follows: Improvement rate = (preoperative YGTSS score – postoperative YGTSS score)/preoperative YGTSS score \times 100%.

Statistical analysis

All statistical analyses were performed using the statistical software package SPSS version 17.0 (IBM Statistics, Chicago, IL, USA). Data were shown as mean \pm standard deviation (SD). Statistical differences were assessed through a one-way analysis of variance (ANOVA) using the Student–Newman–Keuls test for *post hoc* comparisons after assessing the normality of data distribution. A criterion of $P < 0.05$ was used for statistical significance.

Table 1: Baseline clinical characteristics and DBS complications of the 24 patients with Tourette syndrome

Patients number	Gender	Age at symptom onset (years)	Age at surgery (years)	DCI	YGTSS (preoperation)	Comorbidities	Laterals of DBS	Follow-up (months)	DBS surgery complications
1	Male	8	19	58	72	OCD, ADHD, ED	Right	12	None
2	Male	24	43	85	87	ADHD, ED	Bilateral	13	None
3	Male	9	26	78	67	OCD, ED	Bilateral	19	Fatigue, dizziness, and limb convulsions
4	Male	7	25	62	81	OCD, ADHD	Right	20	None
5	Male	9	24	75	86	OCD, ADHD	Bilateral	21	Fatigue
6	Male	8	26	96	76	OCD	Bilateral	28	None
7	Male	12	20	58	65	ADHD, ED	Bilateral	32	None
8	Male	11	23	64	94	OCD, ADHD, and ED	Bilateral	38	Dizziness
9	Male	13	33	75	56	ED	Bilateral	53	None
10	Female	8	29	62	88	OCD, ED	Bilateral	53	None
11	Male	9	21	79	73	OCD, ADHD	Bilateral	53	None
12	Male	11	22	72	78	ADHD, ED	Right	54	Diplopia, flashing
13	Male	8	24	71	57	OCD, SIB	Bilateral	64	None
14	Male	9	28	84	78	OCD, ADHD	Bilateral	65	None
15	Male	29	41	86	53	ED	Right	65	Fatigue
16	Male	13	23	87	64	OCD, ADHD, and ED	Bilateral	73	None
17	Male	11	20	59	77	OCD, ADHD, and ED	Bilateral	73	None
18	Male	7	28	93	72	OCD, SIB	Bilateral	76	None
19	Female	9	25	79	92	OCD, ADHD, and ED	Bilateral	76	None
20	Male	9	21	88	75	OCD, ADHD, and ED	Removed	23	Mild sexual dysfunction, subcutaneous fluid, and infection
21	Male	7	18	81	81	OCD, ADHD, and ED	Bilateral	89	None
22	Male	8	21	90	55		Removed	26	Infection
23	Male	10	30	89	78	OCD, ADHD, and SIB	Removed	22	Infection
24	Male	9	18	94	72	OCD, ADHD, and ED	Bilateral	99	None

One patient experienced a mild sexual dysfunction, subcutaneous fluid accumulation, and infection in the IPG site. Two patients had subcutaneous fluid accumulation and infection at the IPG site. Diplopia, flashing, fatigue, dizziness, and limb convulsions were observed as transient complications and disappeared following adjustment the stimulation parameters and electrode settings. DBS: Deep brain stimulation; DCI: Diagnostic confidence index; YGTSS: Yale Global Tic Severity Scale; ADHD: Attention deficit hyperactivity disorders; ED: Emotional disorder; OCD: Obsessive-compulsive disorder; SIB: Self-injury behavior; IPG: Implantable pulse generator.

RESULTS

Assessment of tics

Among 24 cases, 18 patients experienced a lesion-like effect after the DBS surgery and exhibited varying symptomatic improvement ranging from 10% to 80% (self-assessment). When the lesion-like effect disappeared 3–7 days later, such that the symptoms had completely reappeared, we switched the DBS on.

The follow-up data were obtained over a period of more than 12 months (ranging from 12 to 99 months) after the operation [Table 2]. At the 3-month follow-up assessment, six of the patients reported that they had received no benefit from the stimulation while the remaining 18 cases exhibited varying degrees of symptom amelioration.

At the 6-month follow-up assessment, all patients had significantly improved symptoms and 56% of patients had a significant decrease in YGTSS scores compared with the baseline ($P < 0.01$). At the 12-month follow-up, symptom improvements tended to be stable (YGTSS scores had improved by 57.8% from baseline, $P < 0.01$). Improvement

Table 2: Pre- and post-operative YGTSS scores

Follow-up	Patients (n)	Motor tic	Phone tic	Social impairment	Global
Baseline	24	18.9 ± 4.0	15.6 ± 4.8	39.2 ± 7.8	74.0 ± 11.5
3 months	24	12.8 ± 4.3*	11.7 ± 4.3*	25.4 ± 7.2*	49.8 ± 10.9*
6 months	24	9.3 ± 3.2*	8.8 ± 3.3*	15.0 ± 5.1*	32.6 ± 8.0*
12 months	24	8.8 ± 3.5*	8.3 ± 2.9*	14.2 ± 5.8*	31.2 ± 8.9*
<i>F</i>		36.680	19.649	35.269	165.396
<i>P</i>		0.000	0.001	0.000	0.000

Values are demonstrated as mean ± SD. * $P < 0.01$ versus baseline (preoperative YGTSS scores). Compared with baseline YGTSS scores, we found a significant improvement in four types of YGTSS scores from 3 months onward. The final follow-up data (>12 months) are not presented in Table 2. YGTSS: Yale Global Tic Severity Scale; SD: Standard deviation.

of motor tic symptoms was superior to that of phonic tic symptoms. The average improvement of motor tics, phonic tics, social impairment, and global scores were 53.7%, 48.1%, 64.8%, and 57.8%, respectively. Particularly, the mean score of global impairment was reduced to 14.2 points, which suggested that the social function of the patients was significantly improved.

At the 12-month follow-up assessment, self-evaluations indicated that symptoms had improved by 50%–80% after the DBS surgery, with an average improvement of approximately 70%. The improvement reflected by the self-assessment was higher than that of the YGTSS score. This might be because the patients felt that their active control over tics had greatly increased after operations, such that the associated symptoms, such as emotional disorders and OCD, decreased as well.

Assessment of obsessive-compulsive disorder

We observed comorbid OCD in 18 of the TS patients. The Y-BOCS reflected a decrease in obsessive-compulsive tendencies at the 3 and 6-month follow-up assessments. We found a statistical difference between baseline score and scores at 3, 6, and 12 months. At the 12-month follow-up, Y-BOCS scores had stabilized such that they were similar to those at 6 months, with an average improvement of 38.59% compared with baseline [Figure 1].

Assessment of safety

The mean preoperative scores from the WAIS-RC were as follows: the verbal intelligence quotient (VIQ) was 98.04 ± 7.87 , the performance-IQ (PIQ) was 99.21 ± 7.26 , and the full-IQ (FIQ) was 98.30 ± 6.74 . At the 12-month follow-up assessment, the mean VIQ, PIQ, and FIQ scores were 100.08 ± 7.71 , 99.29 ± 7.32 , and 99.88 ± 7.21 , respectively. There were no significant changes before versus after the surgery in any of the patients [Figure 2].

At the early stage of DBS-on (immediately after the stimulator had been turned on), temporary complications included diplopia, flashing, fatigue, dizziness, and limb convulsions. By adjusting the stimulation parameters and electrode settings, we

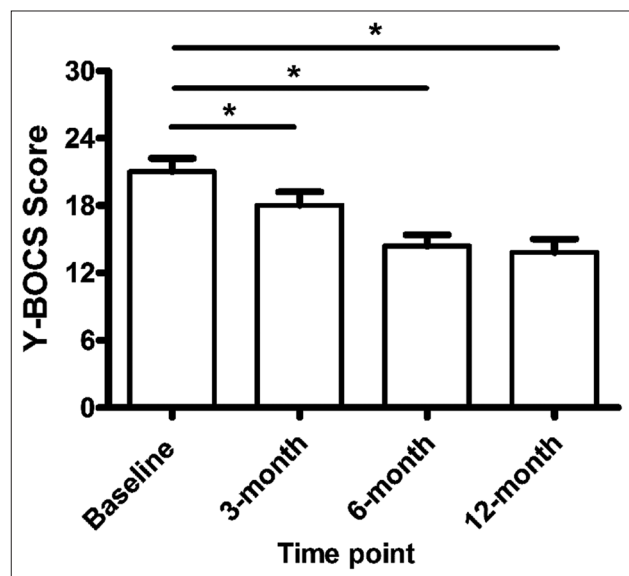


Figure 1: Y-BOCS scores before and after Gpi-DBS in TS patients. Compared with baseline values, Y-BOCS scores were statistically lower at 3, 6, and 12-month follow-up assessments. $*P < 0.01$ versus baseline. Y-BOCS: Yale-Brown Obsessive-compulsive Scale; GPi: Globus pallidus internus; DBS: Deep brain stimulation; TS: Tourette syndrome.

found that these transient complications could be eliminated. Three patients developed adverse effects of the surgery. One patient reported mild sexual dysfunction 3 months after the DBS had been switched on, and his DBS device was removed because of infection in the IPG site happening at 23 months after the operation. Another patient also experienced postoperative subcutaneous fluid accumulation in the IPG pocket, which, although improved by puncture and aspiration at 12 months, finally resulted in infection 22 months postoperation and subsequent removal of the implanted device. Interestingly, this patient exhibited stable symptomatic improvement at the follow-up.^[7] A similar incident occurred in a third patient 26 months after the surgery whose tics began to mildly deteriorate following the removal of his IPG and electrode. The rest of the patients had no long-term complications.

DISCUSSION

Approximately 30%–40% of TS patients experience complete remission after puberty whereas another 30% experience further deterioration with aging. Some TS patients do not respond to treatment with systematic drugs or behavioral therapy and, thus, search for alternative treatments. Indeed, some symptoms might last into adulthood, making TS a life-long disease.^[1,8] The management of patients with malignant TS can be very challenging, to the extent that some individuals might opt for surgical treatments.

Half a century has passed since Rauch *et al.* conducted the first transorbital frontal lobectomy for the treatment of TS. Since then, a variety of surgical methods have been tested, leading to a large body of literature concerning possible TS mechanisms and treatments.^[2] In 1999, Vandewalle *et al.*^[3] described the first use of DBS for the treatment of TS. According to the literature, more than 100 TS patients have been treated with DBS to date.^[3,6,9-24]

The thalamus and globus pallidus were selected as stimulation targets in the vast majority of patients. The average amount of tic improvement following DBS is generally 60%–70% while a few studies have reported

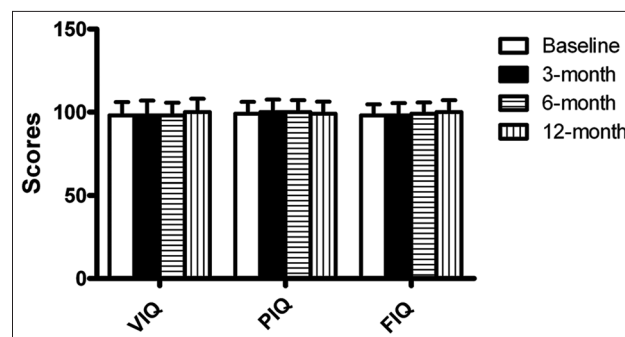


Figure 2: WAIS-RC scores before and after Gpi-DBS in TS patients. We found no significant difference between VIQ, PIQ, and FIQ scores at baseline, 3, 6, and 12-month assessments. WAIS-RC: Wechsler Adult Intelligence Scale-Revised in China; GPi: Globus pallidus internus; DBS: Deep brain stimulation; TS: Tourette syndrome; VIQ: Verbal intelligence quotient; PIQ: Performance-IQ; FIQ: Full-IQ.

rates as high as 90%–100%. There does not appear to be a significant therapeutic difference between stimulation of the thalamus or globus pallidus although stimulation of the anterior limb of the internal capsule and nucleus accumbens seems to be less effective (25%–50%) for treating TS. However, these sites might impact emotion (stimulating different regions can cause feelings of depression or anxiety). Thus, these regions might be useful targets in the treatment of severe affective disorders.

A large number of studies have suggested that the basal ganglia play an important role in the pathophysiology of TS.^[25] According to the basal ganglia-thalamus-cortex loop theory described by Mink,^[26,27] dysfunction of this loop leads to TS symptoms. Therefore, DBS stimulation of the globus pallidus or thalamus, which are positioned in this loop, could bidirectionally regulate abnormal impulses in the striatum and thalamus. This might restore balance in the circuit, thereby alleviating the symptoms of TS. Dysfunctions in the limbic striatal loop and orbitofrontal cortex-medial thalamic nuclei loop are associated with the onset of TS and OCD. As projections from the frontal thalamus and frontal striatum pass through the anterior limb of the internal capsule, DBS of this region might have therapeutic benefit.^[23]

In this study, we treated 24 TS patients with GPi-DBS and conducted follow-up assessments for over 12 months. Before the surgery, our patients responded poorly to conventional medication and psychological-behavioral treatment. At the 12-month follow-up assessment, we found that the motor and phonic tics had significantly improved in all 24 patients. Specifically, Gpi-DBS was effective for rapid and transient motor tics (clonic tics), phonic tics, and slow and sustained movements (dystonic tics). The impulse to move (sensory tics or premonitory urge) was also significantly alleviated by the surgery in this patient group. Social impairment scores were reduced by 64.8%, indicating restored social function in the patient population. In addition, we found varying degrees of improvement in comorbid disorders, such as OCD, self-injury behavior, and emotional disorders (testiness and irritability), after the surgery. A study investigating quality of life in TS patients after Gpi-DBS obtained similar findings and concluded that symptomatic improvement might lead to unexpected major psychosocial changes.^[28,29]

In our study, we observed an improvement in both tic and OCD symptoms in our patient population. The improvement in OCD symptoms that we found is similar to the outcome reported for the use of ventral capsule/ventral striatum as DBS targets for treatment of OCD.^[30] Since it can be difficult to completely distinguish OCD symptoms from tics in TS patients with comorbid OCD, it might be difficult to discern the mechanisms underlying the observed improvement. Therefore, it still needs more evidence for concluding that GPi is an appropriate target for OCD treatment based on this study.

Overall, our data indicate that bilateral GPi-DBS can be used to effectively regulate abnormal nerve impulses in the basal ganglia-related loop, thereby ameliorating tics and various

accompanying symptoms in patients with TS, and improve patients' quality of life with no significant changes in their intelligence or personality.

The incidence of complications associated with DBS generally exceeds 25%, and 4%–6% of these complications are permanent.^[13] In our study, a total of three patients encountered long-term postoperative surgical complications, which correspond to 12.5% of the participant group. The case of mild sexual dysfunction (reduced sexual drive) in one patient requires further investigation. Two patients demonstrated skin erosion and subsequent infection at the IPG site who both engaged in robust athletic exercise after the operation. It is possible that the long-term and high-intensity friction from physical activity led to broken skin and infection in this area. Compared with the disabling symptoms and refractory nature of TS, milder complications such as fatigue, a mild decrease in sex drive, and focal dystonia might be seen as acceptable. Therefore, the application of DBS to the treatment of TS seems appropriate and efficacious.

The application of DBS in the treatment of refractory TS has gained increasing attention in the academic community. In addition to the anterior limb of the internal capsule and the nucleus accumbens, all further surgery targets have been found to have good efficacy. Recently, a double-blind, randomized, crossover trial provided additional evidence that DBS in the GPi can significantly improve tics.^[18] However, the study had a small number of patients, a short follow-up period, and inconsistent assessment criteria, making it difficult to ascertain the optimal therapeutic approach. Indeed, the use of standard treatment criteria and assessment measures, as well as complete follow-up data, is essential for identifying new targets and improving surgical efficacy.

In addition, since DBS is a reversible (i.e., patients return to the preoperative state a few hours after switching off the stimulator) procedure, the combination of DBS with modern imaging techniques such as functional magnetic resonance imaging, positron emission computed tomography, and single photon emission computed tomography might greatly contribute to investigations of the pathophysiological basis of TS (such as dopamine metabolism in the cortex-striatum-thalamus-cortex loop in the basal nucleus and dopamine receptor abnormality).

Limitations

This study had several limitations. First, this study as an open research project lacks randomized, double-blind, safety/efficacy study design and thus cannot exclude the possibility of placebo effect. Second, the follow-up study lasted for only 1 year, and longer-term effect was not available. In addition, this study is limited by the lack of a comparison target of stimulation, and it is insufficient to conclude that GPi serves as the optimal stimulation target. Postoperative neuroimaging study would be helpful in future research to further delineate the relationship between actual stimulation area and treatment effect.

Financial support and sponsorship

This project was supported by a grant from National Natural Science Foundation of China (No. 81371256).

Conflicts of interest

There are no conflicts of interest.

REFERENCES

1. Kurlan RM. Treatment of Tourette syndrome. *Neurotherapeutics* 2014;11:161-5. doi: 10.1007/s13311-013-0215-4.
2. Rauch SL, Baer L, Cosgrove GR, Jenike MA. Neurosurgical treatment of Tourette's syndrome: A critical review. *Compr Psychiatry* 1995;36:141-56.
3. Vandewalle V, van der Linden C, Groenewegen HJ, Caemaert J. Stereotactic treatment of Gilles de la Tourette syndrome by high frequency stimulation of thalamus. *Lancet* 1999;353:724. doi: 10.1016/S0140-6736(98)05964-9.
4. American Psychiatric Association. *Diagnostic and Statistical Manual of Mental Disorders*. 4th ed. Text Revision. Washington: American Psychiatric Publishing, Inc; 2000.
5. Robertson MM, Banerjee S, Kurlan R, Cohen DJ, Leckman JF, McMahon W, *et al*. The Tourette syndrome diagnostic confidence index: Development and clinical associations. *Neurology* 1999;53:2108-12. doi: 10.1212/WNL.53.9.2108.
6. Ackermans L, Temel Y, Visser-Vandewalle V. Deep brain stimulation in Tourette's syndrome. *Neurotherapeutics* 2008;5:339-44. doi: 10.1016/j.nurt.2008.01.009.
7. Dong S, Zhang X, Li J, Li Y. Unexpected outcome of pallidal deep brain stimulation in a patient with Tourette syndrome. *Acta Neurochir (Wien)* 2014;156:1527-8. doi: 10.1007/s00701-014-2137-2.
8. Rotsides J, Mammis A. The use of deep brain stimulation in Tourette's syndrome. *Neurosurg Focus* 2013;35:E4. doi: 10.3171/2013.8.FOCUS13292.
9. Ackermans L, Duits A, van der Linden C, Tijssen M, Schruers K, Temel Y, *et al*. Double-blind clinical trial of thalamic stimulation in patients with Tourette syndrome. *Brain* 2011;134(Pt 3):832-44. doi: 10.1093/brain/awq380.
10. Servello D, Sassi M, Brambilla A, Defendi S, Porta M. Long-term, post-deep brain stimulation management of a series of 36 patients affected with refractory Gilles de la Tourette syndrome. *Neuromodulation* 2010;13:187-94. doi: 10.1111/j.1525-1403.2009.0253.x.
11. Bajwa RJ, de Lotbinière AJ, King RA, Jabbari B, Quatrano S, Kunze K, *et al*. Deep brain stimulation in Tourette's syndrome. *Mov Disord* 2007;22:1346-50.
12. Savica R, Stead M, Mack KJ, Lee KH, Klassen BT. Deep brain stimulation in Tourette syndrome: A description of 3 patients with excellent outcome. *Mayo Clin Proc* 2012;87:59-62. doi: 10.1016/j.mayocp.2011.08.005.
13. Pullen SJ, Wall CA, Lee KH, Stead SM, Klassen BT, Brown TM. Neuropsychiatric outcome of an adolescent who received deep brain stimulation for Tourette's syndrome. *Case Rep Neurol Med* 2011;2011:209467. doi: 10.1155/2011/209467.
14. Lee MW, Au-Yeung MM, Hung KN, Wong CK. Deep brain stimulation in a Chinese Tourette's syndrome patient. *Hong Kong Med J* 2011;17:147-50.
15. Dehning S, Feddersen B, Cerovecki A, Bötzel K, Müller N, Mehrkens JH. Globus pallidus internus-deep brain stimulation in Tourette's syndrome: Can clinical symptoms predict response? *Mov Disord* 2011;26:2440-1. doi: 10.1002/mds.23892.
16. Martínez-Fernández R, Zrinzo L, Aviles-Olmos I, Hariz M, Martínez-Torres I, Joyce E, *et al*. Deep brain stimulation for Gilles de la Tourette syndrome: A case series targeting subregions of the globus pallidus internus. *Mov Disord* 2011;26:1922-30. doi: 10.1002/mds.23734.
17. Kefalopoulou Z, Zrinzo L, Jahanshahi M, Candelario J, Milabo C, Beigi M, *et al*. Bilateral globus pallidus stimulation for severe Tourette's syndrome: A double-blind, randomised crossover trial. *Lancet Neurol* 2015;14:595-605. doi: 10.1016/S1474-4422(15)00008-3.
18. Sachdev PS, Mohan A, Cannon E, Crawford JD, Silberstein P, Cook R, *et al*. Deep brain stimulation of the antero-medial globus pallidus interna for Tourette syndrome. *PLoS One* 2014;9:e104926. doi: 10.1371/journal.pone.0104926.
19. Cannon E, Silburn P, Coyne T, O'Malley K, Crawford JD, Sachdev PS. Deep brain stimulation of anteromedial globus pallidus interna for severe Tourette's syndrome. *Am J Psychiatry* 2012;169:860-6. doi: 10.1176/appi.ajp.2012.11101583.
20. Piedimonte F, Andreani JC, Piedimonte L, Graff P, Bacaro V, Micheli F, *et al*. Behavioral and motor improvement after deep brain stimulation of the globus pallidus externus in a case of Tourette's syndrome. *Neuromodulation* 2013;16:55-8. doi: 10.1111/j.1525-1403.2012.00526.x.
21. Shields DC, Cheng ML, Flaherty AW, Gale JT, Eskandar EN. Microelectrode-guided deep brain stimulation for Tourette syndrome: Within-subject comparison of different stimulation sites. *Stereotact Funct Neurosurg* 2008;86:87-91. doi: 10.1159/000112429.
22. Sachdev PS, Cannon E, Coyne TJ, Silburn P. Bilateral deep brain stimulation of the nucleus accumbens for comorbid obsessive compulsive disorder and Tourette's syndrome. *BMJ Case Rep* 2012;2012. pii: Ber2012006579. doi: 10.1136/bcr-2012-006579.
23. Kuhn J, Lenartz D, Mai JK, Huff W, Lee SH, Koulousakis A, *et al*. Deep brain stimulation of the nucleus accumbens and the internal capsule in therapeutically refractory Tourette-syndrome. *J Neurol* 2007;254:963-5. doi: 10.1007/s00415-006-0404-8.
24. Kuhn J, Lenartz D, Huff W, Mai JK, Koulousakis A, Maarouf M, *et al*. Transient manic-like episode following bilateral deep brain stimulation of the nucleus accumbens and the internal capsule in a patient with Tourette syndrome. *Neuromodulation* 2008;11:128-31. doi: 10.1111/j.1525-1403.2008.00154.x.
25. Temel Y, Visser-Vandewalle V. Surgery in Tourette syndrome. *Mov Disord* 2004;19:3-14. doi: 10.1002/mds.10649.
26. Mink JW. Basal ganglia dysfunction in Tourette's syndrome: A new hypothesis. *Pediatr Neurol* 2001;25:190-8.
27. Mink JW. Neurobiology of basal ganglia and Tourette syndrome: Basal ganglia circuits and thalamocortical outputs. *Adv Neurol* 2006;99:89-98.
28. Dehning S, Leitner B, Schennach R, Müller N, Bötzel K, Obermeier M, *et al*. Functional outcome and quality of life in Tourette's syndrome after deep brain stimulation of the posteroventrolateral globus pallidus internus: Long-term follow-up. *World J Biol Psychiatry* 2014;15:66-75. doi: 10.3109/15622975.2013.849004.
29. Greenberg BD, Gabriels LA, Malone DA Jr., Rezaei AR, Friehs GM, Okun MS, *et al*. Deep brain stimulation of the ventral internal capsule/ventral striatum for obsessive-compulsive disorder: Worldwide experience. *Mol Psychiatry* 2010;15:64-79. doi: 10.1038/mp.2008.55.
30. Servello D, Porta M, Sassi M, Brambilla A, Robertson MM. Deep brain stimulation in 18 patients with severe Gilles de la Tourette syndrome refractory to treatment: The surgery and stimulation. *J Neurol Neurosurg Psychiatry* 2008;79:136-42. doi: 10.1136/jnnp.2006.104067.