

## Chronic atypical neutrophilic dermatosis with lipodystrophy and elevated temperature syndrome: a report of a novel mutation and review of the literature

DOI: 10.1111/bjd.12600

DEAR EDITOR, Chronic atypical neutrophilic dermatosis with lipodystrophy and elevated temperature (CANDLE) syndrome is a new autoinflammatory syndrome caused by mutations in the gene for proteasome subunit, beta type, 8 (PSMB8). We report a young adult with a novel homozygous PSMB8 mutation and marked skin disease.

A 22-year-old Bangladeshi woman was referred to the National Amyloidosis Centre, having been unwell since infancy with episodes occurring every 3–4 weeks for up to 7 days. She reported a fever of up to 42 °C associated with rigors and a red, raised, painful and itchy cutaneous eruption. Other features included pleuritic chest pain, arthralgia, mouth ulcers and painful cervical lymphadenopathy. Our patient is the eighth of nine children. Her father died in 2006 of cancer and her mother is well. Her five older brothers and a sister are healthy. Two sisters died, aged 17 and 5 years, in Bangladesh, of a similar illness characterized by fevers, rigors, rash and poor weight gain and growth (Fig. 1a).

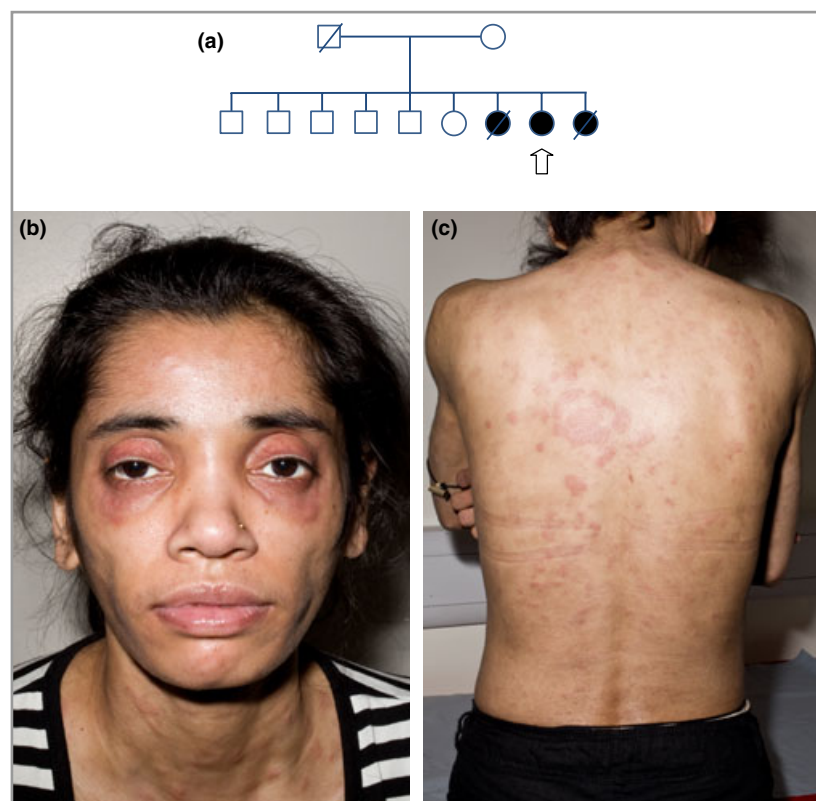On examination, she was small and thin at 38 kg, with very wasted muscles, facial lipodystrophy and hypertrichosis of the forehead. Her lips were full and there was marked erythema

of the periorbital areas (Fig. 1b). Violaceous and erythematous papules and larger annular and polycyclic erythematous plaques were distributed over her neck, shoulders, trunk and hands, with coexisting hyperpigmented patches in the same distribution reflecting resolution of older lesions (Fig. 1c). There was no hepatosplenomegaly.

Laboratory investigations (healthy levels in parentheses) revealed a microcytic anaemia [haemoglobin 8.6 g dL<sup>-1</sup>, mean corpuscular volume 78.3 fL, iron concentration 8.8 µmol L<sup>-1</sup> (11–36), iron saturation 19.3% (20–40), total iron-binding capacity 45.6 µmol L<sup>-1</sup> (53–85) and ferritin 101 µg L<sup>-1</sup>] and polyclonal hyperglobulinaemia [IgA 6.0 g L<sup>-1</sup> (0.7–4.0), IgG 32.7 g L<sup>-1</sup> (7.0–16.0) and IgM 9.2 g L<sup>-1</sup> (0.4–2.3)]. She had weakly positive cytoplasmic antineutrophil cytoplasmic antibodies, IgM anticardiolipin antibodies and antibeta 2 globulin antibodies. Monitoring over 21 months demonstrated sustained inflammation with median C-reactive protein 72 mg L<sup>-1</sup> (range 19–305) and serum amyloid A protein 218 mg L<sup>-1</sup> (range 16–693).

A punch biopsy taken from a representative plaque revealed a dense interstitial and perivascular dermal infiltrate composed of atypical mononuclear cells of myeloid lineage admixed with mature eosinophils, histiocytes and neutrophils (Fig. 2).

Screening of PSMB8 revealed that she was homozygous for a novel mutation p.M117V (c.349A > G; National Center for Biotechnology Information sequence NM\_148919.3) in exon 3. She had previously been treated with prednisolone and colchicine without improvement, and has recently commenced tocilizumab 8 mg kg<sup>-1</sup> four times weekly with some symptomatic benefit.



**Fig 1.** (a) Pedigree. The proband is marked by the arrow. (b) Periorbital erythema, hypertrichosis of the forehead and partial lipodystrophy. (c) Erythematous papules and larger annular and polycyclic erythematous plaques seen on the back.

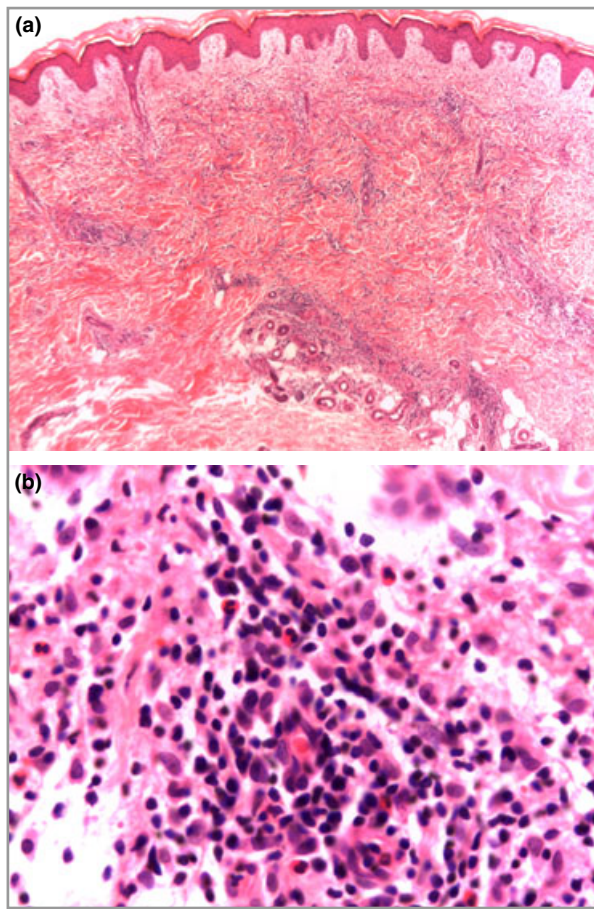


Fig 2. (a) Punch biopsy demonstrating a heavy interstitial and perivascular dermal infiltrate (haematoxylin and eosin, magnification  $\times 50$ ). (b) The dermal infiltrate is composed of atypical mononuclear cells with hyperchromatic nuclei (myeloperoxidase positive) admixed with mature eosinophils, histiocytes and occasional neutrophils (haematoxylin and eosin, magnification  $\times 400$ ).

The acronym CANDLE was proposed in 2010.<sup>1</sup> Features common to the first four reported patients were early onset, fevers, delayed physical development, microcytic anaemia, recurrent annular lesions, swollen violaceous eyelids, thick lips, progressive lipodystrophy and arthralgia. Two patients were siblings from a consanguineous family, suggesting autosomal recessive disease. Skin biopsies demonstrated a perivascular and interstitial infiltrate comprising mature neutrophils and atypical mononuclear cells of myeloid lineage. In 2011, an Israeli group reported a fifth child with clinical, laboratory and histopathological similarities.<sup>2</sup>

A recent paper describes the phenotype, genetics and immune dysregulation in nine children with presumed CANDLE syndrome.<sup>3</sup> Genome-wide analysis followed by candidate gene selection detected mutations in exon 3 of PSMB8 in seven patients. Five patients were homozygotes but a second mutation was not found in the other two.

PSMB8 encodes the inducible B5 subunit of the immunoproteasome. Proteasomes are ubiquitously expressed and are involved in proteolysis, generating antigenic peptides for class

I major histocompatibility complex presentation and maintenance of cell homeostasis. It is suggested that failure of proteolysis leads to accumulation of damaged proteins, increased cellular stress and increased interferon (IFN) signalling. Cytokine profiling and analysis of the transcriptome was consistent with dysregulation of the IFN pathway in four children.<sup>3</sup> Treatment attempts, including antitumour necrosis factor agents and the interleukin-6 receptor blocker tocilizumab, were only partially effective, with normalization of the acute phase response but persistent rash, fatigue, arthralgia and lipodystrophy. A more rational approach may be to use Janus kinase inhibitors to reduce IFN gamma-inducible protein 10 production, and there is an ongoing trial for CANDLE (ClinicalTrials.gov identifier: NCT01724580).

The finding of PSMB8 variants unites CANDLE with two other syndromes. Nakajo–Nishimura syndrome, first described in Japan in 1939 as secondary hypertrophic osteoperiostosis with pernio, is characterized by partial lipomuscular atrophy, clubbing, a pernio-like, heliotrope-like, or nodular erythema-like rash, periodic fever and joint contractures. More than 20 cases have been reported and, in 2011, seven patients were shown to be homozygous for the PSMB8 G201V mutation, with haplotype analysis suggesting a common founder.<sup>4</sup> Joint contractures, muscle atrophy, microcytic anaemia and panniculitis-induced childhood-onset lipodystrophy syndrome was described in 2010 in three adults from a Portuguese kindred and another from Mexico.<sup>5</sup> These patients are homozygous for the PSMB8 T75M mutation. This suggests that muscle involvement and joint contractures may be later-onset complications of progressive disease in untreated or partially treated patients who survive beyond childhood.<sup>6</sup>

<sup>1</sup>Department of Dermatology and

J. KLUK<sup>1</sup>

<sup>5</sup>Department of Histopathology, Royal Free London NHS Foundation Trust, Pond Street, London NW3 2QG, U.K.

M. RUSTIN<sup>1</sup>

<sup>2</sup>Institute of Child Health, University College London, 30 Guilford Street, London WC1N 1EH, U.K.

P.A. BROGAN<sup>2</sup>

<sup>3</sup>Division of Medicine, National Amyloidosis Centre, Centre for Amyloidosis and Acute Phase Proteins, University College London Medical School, Royal Free Campus, Rowland Hill Street, London NW3 2PF, U.K.

E. OMOYINMI<sup>2</sup>

<sup>4</sup>Nephrology Department, Cambridge University Hospitals NHS Foundation Trust, Hills Road, Cambridge CB2 0QQ, U.K.

D.M. ROWCZENIO<sup>3</sup>

Correspondence: Helen J. Lachmann.

L.C. WILLCOCKS<sup>4</sup>

E-mail: h.lachmann@ucl.ac.uk

L. MELLY<sup>5</sup>

H.J. LACHMANN<sup>3</sup>

## References

- Torrello A, Patel S, Colmenero I et al. Chronic atypical neutrophilic dermatosis with lipodystrophy and elevated temperature (CANDLE) syndrome. *J Am Acad Dermatol* 2010; **62**:489–95.

- 2 Ramot Y, Czarnowicki T, Maly A et al. Chronic atypical neutrophilic dermatosis with lipodystrophy and elevated temperature syndrome: a case report. *Pediatr Dermatol* 2011; **28**:538–41.
- 3 Liu Y, Ramot Y, Torrello A et al. Mutations in proteasome subunit  $\beta$  type 8 cause chronic atypical neutrophilic dermatosis with lipodystrophy and elevated temperature with evidence of genetic and phenotypic heterogeneity. *Arthritis Rheum* 2012; **64**:895–907.
- 4 Arima K, Kinoshita A, Mishima H et al. Proteasome assembly defect due to a proteasome subunit beta type 8 (PSMB8) mutation causes the autoinflammatory disorder, Nakajo–Nishimura syndrome. *Proc Natl Acad Sci USA* 2011; **108**:14914–19.
- 5 Garg A, Hernandez MD, Sousa AB et al. An autosomal recessive syndrome of joint contractures, muscular atrophy, microcytic anemia, and panniculitis-associated lipodystrophy. *J Clin Endocrinol Metab* 2010; **95**:E58–63.
- 6 Agarwal AK, Xing C, DeMartino GN et al. PSMB8 encoding the  $\beta$ 5i proteasome subunit is mutated in joint contractures, muscle atrophy, microcytic anemia and panniculitis-induced lipodystrophy syndrome. *Am J Hum Genet* 2010; **87**:866–72.

Funding sources: none.

Conflicts of interest: none declared.

© 2013 The Authors. British Journal of Dermatology published by John Wiley & Sons Ltd on behalf of British Association of Dermatologists.

This is an open access article under the terms of the Creative Commons Attribution-NonCommercial-NoDerivs License, which permits use and distribution in any medium, provided the original work is properly cited, the use is non-commercial and no modifications or adaptations are made.

## Anorectal necrosis after paracetamol abuse

DOI: 10.1111/bjd.12595

DEAR EDITOR, A 34-year-old woman presented to our Department of Dermatology with painful nonhealing anorectal skin lesions. She had been suffering from these lesions for the last 5 years. Different therapies including local antibiotics and topical steroids had not been effective.

Over the last 12 months she had been treated in a surgical outpatient clinic. At initial examination the patient had shown a circular anal and perianal firm butterfly-shaped necrosis with erythematous borders (Fig. 1a). Proctological examination revealed a gaping anus and a filiform stenosis located at 4 cm *ab ano*. No lymphadenopathy was detected, manometry was negative. The diagnosis of a carcinoma of the perianal region was suspected. However, the following biopsy showed only a pattern of chronic inflammation without any evidence of a vascular or neoplastic origin. A surgical necrectomy was performed followed by construction of a protective stoma. Due to the unusual clinical presentation and the chronicity of the lesion the patient was referred to our department.

At initial presentation to our department physical examination revealed nonirritated anorectal skin lesions after surgical

necrectomy. The remaining integument was completely inconspicuous. Proctoscopy showed a constricted anus and reduced sphincter tone. Blood analyses did not show any abnormalities. The family history was negative. The patient reported that she had been suffering from chronic back pain for the last 5 years. According to the patient, her gynaecologist had prescribed 'cortisone suppositories' for the therapy of her back pain, which she had been using regularly over the last 5 years. Otherwise she was not taking any other medication. As defecation was very painful, the patient had changed her diet and consequently had lost 30 pounds of body weight over the past 12 months.

The first view of the recorded pictures of the perianal symmetric lesions reminded us of the gangrenous symptoms of ergotism. Ergotamine is an ergopeptine and one of the family of alkaloids. It is used in neurology for the treatment of acute migraine attacks. It possesses structural similarity to several neurotransmitters and has biological activity as a vasoconstrictor. Ergotamine-induced anorectal necrosis due to abuse of suppositories is known and has been recorded in the past.<sup>1,2</sup> A more thorough medical history was taken and revealed that the 'cortisone suppositories' consisted of 1000 mg of paracetamol (acetaminophen). The suppositories were used up to five times a day. This additional information, the initial clinical presentation and the patient's past medical history led to the diagnosis of

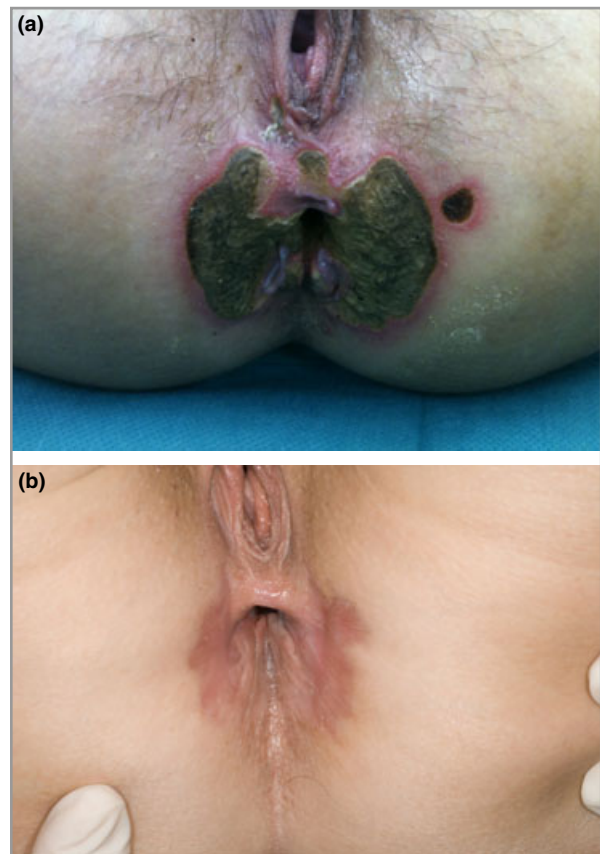


Fig. 1. (a) Circular anal and perianal firm butterfly-shaped necrosis with erythematous borders. (b) Result 8 weeks after discontinuation of paracetamol use.