


CASE REPORT

Unexpected urological presentation of COVID-19 in a 41-year-old female: A case report

Ramin Haghighi¹ | Seyed Ahmad Hashemi² | Ali Abaszade Ganji³ | Ashkan Haghighi⁴ | Samaneh Mollazadeh⁵ 

¹Department of Urology, Imam Hassan Hospital, North Khorasan University of Medical Sciences, Bojnurd, Iran

²Department of Infectious Diseases, School of Medicine, North Khorasan University of Medical Sciences, Bojnurd, Iran

³Faculty of Medicine, North Khorasan University of Medical Sciences, Bojnurd, Iran

⁴Faculty of Medicine, Mashhad University of Medical Sciences, Mashhad, Iran

⁵Natural Products and Medicinal Plants Research Center, North Khorasan University of Medical Sciences, Bojnurd, Iran

Correspondence

Ramin Haghighi, Department of Urology, Imam Hassan Hospital, North Khorasan University of Medical Sciences, Bojnurd, Iran.

Email: haghighi.ramin@yahoo.com

Abstract

Hematuria and urinary discomfort may be the first manifestations of COVID-19 infection. Nevertheless, more researches are needed to be done in this field to clarify the exact mechanism by which SARS-CoV-2 affects the urological system.

KEYWORDS

coronavirus disease 2019 (COVID-19), hematuria, kidney, urinary discomfort, urinary tract

1 | INTRODUCTION

We report a COVID-19 case whose first symptoms were hematuria and urinary discomfort. Despite the absence of urinary tract infection (UTI), an empirical antibiotic regimen had been started for her due to the suspicion of acute cystitis. Later, she returned because of fever and musculoskeletal pain. Further investigations confirmed COVID-19 infection.

In winter 2019, the spread of the coronavirus disease 2019 (COVID-19) has led to an outbreak that affected millions of people around the world. COVID-19 pathogen is an enveloped RNA virus with spike shape projections on its surface.

Since it is mainly transmitted by inhalation, using a face mask is strongly advised. Its common clinical features are unspecific and include dry cough, fever, diarrhea, and myalgia. Definitive diagnosis is based on polymerase chain reaction (PCR) test, high-resolution computed tomography (HRCT) imaging, and serological tests using the chemiluminescence immunoassay method. The disease severity varies from asymptomatic mild disease to a fatal one which leads to organ failure such as acute respiratory distress syndrome (ARDS), or acute kidney injury (AKI). So far no absolute treatment has been found for COVID-19 infection.¹⁻⁴ Here, we present a COVID-19 case whose primary symptoms were urological findings.

This is an open access article under the terms of the Creative Commons Attribution-NonCommercial-NoDerivs License, which permits use and distribution in any medium, provided the original work is properly cited, the use is non-commercial and no modifications or adaptations are made.

© 2021 The Authors. *Clinical Case Reports* published by John Wiley & Sons Ltd.

2 | CASE DESCRIPTION

A 41-year-old woman who was the ICU staff in a referral COVID-19 hospital referred to the hospital emergency department. Her chief complaint was acute gross hematuria, and dysuria as well as its frequency. She had no fever, respiratory, or gastrointestinal complications. She had no underlying disease and was not taking any medication. The history of recent trauma or UTI in the previous 3 years was negative. Besides, her first-degree relatives were not infected with COVID-19. She had not undergone any surgery before and did not mention any specific family illness. Her general condition was good, and she did not have any other remarkable signs or symptoms. So, urinalysis, urine culture (UC), and serum creatinine tests were performed (Table 1). Since bacteriuria and UC were negative, we chose an outpatient treatment plan with an empirical antibiotic regimen (Cefexime, 400 mg/day PO) due to the high clinical suspicion of acute cystitis. Although her complaints decreased after 2 days of antibiotic therapy, she was not fully cured. Three days later, she returned to the hospital due to fever and fatigue. Because of pyelonephritis suspicion, urinary tract sonography was performed which displayed no abnormality. She did not have any respiratory complaint; however, COVID-19 related tests (complete blood count [CBC] test, HRCT, and PCR) were performed because of her persistent contact with COVID-19 patients. While her CBC showed mild neutropenia, other parameters were in the normal ranges. As shown in Figure 1, HRCT result indicated right lung involvement. As well, PCR test was positive for SARS-CoV-2 infection. Based, usual COVID-19 treatment (remdesivir, naproxen) was started for her. Two days later, she was hospitalized because of worsening of her general condition and respiratory problems including shortness of breath, and severe cough. On the fifth day of hospitalization, her cough and fever became more severe. Shortly afterward, her respiratory complications progressively worsened and her oxygen saturation dropped below 90%. Consequently, she was transferred to ICU, and oxygen therapy was started via BiPAP. Then, interferon beta-1a, and

dexamethasone were added to her treatment regimen. On the eighth day of hospitalization, the patient's general condition was gradually improved. On the 15th day of hospitalization, she was discharged in a good condition due to the lack of fever, oxygen saturation >93% (without oxygen therapy), and the absence of remarkable complaints. In a 6-week follow-up, she had not any problems except minor respiratory distress. Furthermore, her hematuria was resolved, and her urinalysis turned normal.

3 | DISCUSSION

Coronavirus disease 2019 common symptoms are dry cough, fever, diarrhea, and myalgia. Nevertheless, we report a COVID-19 infected case in whom urological findings were the primary symptoms. Based, clinicians should be aware of rare irrelevant signs and symptoms in infected patients. In a systemic review by Chan et al. (2020) it was concluded that urinary symptoms accompanied by typical symptoms of COVID-19 suggestive of SARS-CoV-2 infection with renal injury. Besides, the chance of occurrence of AKI is 7.58% in COVID-19 cases which is related to the high-mortality rate. Since high procalcitonin levels are seen in bacterial, parasitic, and fungal infections, it is suggested to use procalcitonin as a marker to differentiate viral urological infections from others.⁵

Despite other studies, the first symptoms of our case were urological manifestations which were gradually accompanied by respiratory problems in the later stages of the disease. Though her serum procalcitonin level was not measured, we did not find any other origin for her symptoms other than COVID-19 infection. There are a few disagreements about the mechanism which leads to kidney

TABLE 1 The results of urinalysis, urine culture (UC), and serum creatinine tests.

Color	Yellow	Ketones	Negative
Appearance	Semi-clear	Bilirubin	Negative
Ph	5	Nitrite	Negative
Specific gravity	1020	WBC	1-2/HPF
Protein	Negative	RBC	14-16/HPF
Sugar	Negative	Crystals	-
Blood	Positive(++)	Casts	-
Urobilinogen	Negative	Mucosa	Few
Serum creatinine	1.1	UC	No growth after 24 h

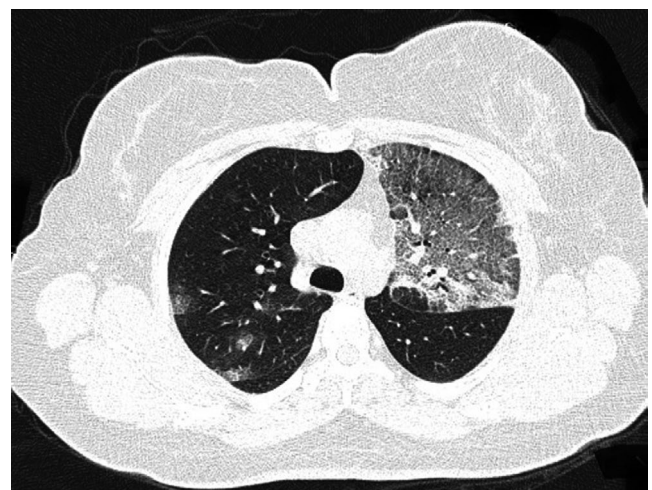


FIGURE 1 Chest HRCT of a 41-year-old woman showing ground-glass opacification in the left upper lobe changing into irregular reticulation.

problems in COVID-19. Su et al. (2020) found some evidence of direct invasion of the virus into kidney tissue despite Sharma et al. (2020) study in which the most common finding was acute tubular necrosis in the patients with AKI and COVID-19.^{6,7} Ronco and Reis explained three possible pathways leading to kidney damage without direct invasion of the viral particles. The first one is the cytokine storm theory, which causes a direct lesion in renal tissue. The second one is organ crosstalk theory that states there is a close relationship between alveolar and tubular damages in ARDS. Based, alveolar damage ultimately leads to tubular damage through various pathways. The last theory is the systemic effect of the infection which includes positive fluid balance, third-space fluid loss, and rhabdomyolysis.⁸ Pei et al. (2020) performed a research about renal injury in cases with COVID-19 pneumonia and its early prognosis. In contrast to the previous studies, renal problems were seen in most cases of their statistical society with a dramatic increase in patients' mortalities. Of note, the renal complications and urinary symptoms frequently eliminate within 3 weeks after the onset of symptoms.⁹

Pan et al. (2020) measured the co-expression of cellular transmembrane serine proteases (TMPRSSs) and angiotensin-converting enzyme 2 (ACE2) in kidney cells as the key factors that accelerate the virus entry into the cells. They found that the co-expression of the TMPRSS and ACE2 genes in kidney cells is similar to the lung and gastrointestinal tract cells. So, the kidney might also be a major target of SARS-CoV-2 virus.¹⁰

Since COVID-19 affects different organs, it may present with various symptoms. Although there are not any specific symptoms in many patients, the most common primary symptoms in symptomatic patients are respiratory problems. In very rare cases, the first manifestations of COVID-19 infection may be hematuria and urological complications probably through co-expression of ACE2 and TMPRSS genes facilitating SARS-CoV-2 entry. Taken together, clinicians would be more careful to identify this challenging disease to be successful in stopping the transmission chain.

ACKNOWLEDGMENTS

The authors are thankful to the Clinical Research Development Unit of Imam Hassan hospital for their helpful cooperation.

CONFLICT OF INTEREST

The authors declare that they have no conflict of interest.

AUTHOR CONTRIBUTIONS

RH, SAH, AAG, and AH: participated in the clinical and pathological researches. SM: studied related articles and helped in drafting the manuscript. All authors read and approved the final manuscript.

ETHICAL APPROVAL

Applicable.


INFORMED CONSENT

Informed consent was obtained from the patient included in the study.

DATA AVAILABILITY STATEMENT

The data that support the findings of this study are available from the corresponding author upon reasonable request.

ORCID

Samaneh Mollazadeh  <https://orcid.org/0000-0001-6582-4500>

REFERENCES

- Sohrabi C, Alsafi Z, O'Neill N, et al. World Health Organization declares global emergency: a review of the 2019 novel coronavirus (COVID-19). *Int J Surg*. 2020;76:71-76.
- Singhal T. A review of coronavirus disease-2019 (COVID-19). *Indian J Pediatr*. 2020;87:281-286.
- Fang Y, Zhang H, Xie J, et al. Sensitivity of chest CT for COVID-19: comparison to RT-PCR. *Radiology*. 2020;296:E115-E117.
- Lin D, Liu L, Zhang M, et al. Evaluations of the serological test in the diagnosis of novel coronavirus (SARS-CoV-2) infections during the COVID-19 outbreak. *Eur J Clin Microbiol Infect Dis*. 2020;39:2271-2277.
- Chan VWS, Chiu PKF, Yee CH, Yuan Y, Ng CF, Teoh JYC. A systematic review on COVID-19: urological manifestations, viral RNA detection and special considerations in urological conditions. *World J Urol*. 2020;1-12. <https://doi.org/10.1007/s00345-020-03246-4>
- Su H, Yang M, Wan C, et al. Renal histopathological analysis of 26 postmortem findings of patients with COVID-19 in China. *Kidney Int*. 2020;98:219-227.
- Sharma P, Uppal NN, Wanchoo R, et al. COVID-19-associated kidney injury: a case series of kidney biopsy findings. *J Am Soc Nephrol*. 2020;31:1948-1958.
- Ronco C, Reis T. Kidney involvement in COVID-19 and rationale for extracorporeal therapies. *Nat Rev Nephrol*. 2020;16:308-310.
- Pei G, Zhang Z, Peng J, et al. Renal involvement and early prognosis in patients with COVID-19 pneumonia. *J Am Soc Nephrol*. 2020;31:1157-1165.
- Pan XW, Xu D, Zhang H, Zhou W, Wang LH, Cui XG. Identification of a potential mechanism of acute kidney injury during the COVID-19 outbreak: a study based on single-cell transcriptome analysis. *Intensive Care Med*. 2020;46:1114-1116.

How to cite this article: Haghghi R, Hashemi SA, Abaszade Ganji A, Haghghi A, Mollazadeh S. Unexpected urological presentation of COVID-19 in a 41-year-old female: A case report. *Clin Case Rep*. 2021;9:1691-1693. <https://doi.org/10.1002/ccr3.3882>