

RESEARCH

Open Access



Serial intravitreal injections in age-related macular degeneration patients from the dry eye disease perspective: a cross-sectional study

Serdar Bilici^{1*}, Neriman Selçuk¹, Numan Küçük¹ and Suat Hayri Uğurbaş¹

Abstract

Background To evaluate the effects of serial intravitreal injections (IVI) on the ocular surface and meibomian glands in patients with neovascular age-related macular degeneration (nAMD).

Methods Patients receiving anti-vascular endothelial growth factor (anti-VEGF) agent injections for unilateral nAMD were included. Untreated fellow eyes served as the control group. All participants followed a pre-IVI asepsis protocol with povidone-iodine (PI). Ocular surface diseases index (OSDI) questionnaire scores, first and average non-invasive tear break-up time (fNITBUT and avgNITBUT), Schirmer-1 test results, corneal staining score (according to Oxford scale), meibomian gland (MG) loss rates of lower and upper eyelids were recorded four weeks after the last IVI.

Results Forty-two nAMD patients with a mean age of 63.3 ± 19.4 were included in the study. The mean OSDI score was 20.3 and the median of IVI number was 9 (6–22). There were no statistically significant difference between treated and untreated fellow eyes regarding fNITBUT (5.6 vs. 4.5, $p=0.872$), avgNITBUT (6.2 vs. 7.2, $p=0.968$), Schirmer-1 results (7 vs. 7, $p=0.854$), corneal staining (0.3 vs. 0.2, $p=0.341$), lower and upper MG loss rate (29.3 vs. 28.4, $p=0.162$, and 27.1 vs. 26.9, $p=0.476$, respectively). Only significant correlation was observed between age with lower and upper MG loss rate ($r:0.396$, $p=0.042$, and $r:0.365$, $p=0.047$).

Conclusion The results of the present study demonstrated that serial IVI of anti-VEGF agents with PI asepsis is well tolerated by nAMD patients in terms of ocular surface, MG loss and DED measurements.

Keywords Age-related macular degeneration, Dry eye disease, Intravitreal injection, Meibomian gland loss, Ocular surface

This study was presented in the 41st Congress of the European Cataract and Refractive Surgeons, September 8–12 2023, Vienna/AUSTRIA.

*Correspondence:

Serdar Bilici
drserdarbilici@gmail.com

¹Department of Ophthalmology, School of Medicine, Zonguldak Bulent Ecevit University, Zonguldak, Turkey



© The Author(s) 2024. **Open Access** This article is licensed under a Creative Commons Attribution-NonCommercial-NoDerivatives 4.0 International License, which permits any non-commercial use, sharing, distribution and reproduction in any medium or format, as long as you give appropriate credit to the original author(s) and the source, provide a link to the Creative Commons licence, and indicate if you modified the licensed material. You do not have permission under this licence to share adapted material derived from this article or parts of it. The images or other third party material in this article are included in the article's Creative Commons licence, unless indicated otherwise in a credit line to the material. If material is not included in the article's Creative Commons licence and your intended use is not permitted by statutory regulation or exceeds the permitted use, you will need to obtain permission directly from the copyright holder. To view a copy of this licence, visit <http://creativecommons.org/licenses/by-nc-nd/4.0/>.

Background

The intravitreal injection (IVI) procedure has become the most prevalent intraocular procedure in current ophthalmology praxis [1, 2]. Among its primary applications is anti-vascular endothelial growth factor (VEGF) treatment for neovascular age-related macular degeneration (nAMD). Due to the natural course of the disease, nAMD patients often undergo frequent intravitreal injections over extended periods [3, 4].

Each intravitreal injection requires sterile preparation of the ocular surface, typically employing povidone-iodine (PI), which is widely acknowledged for its effectiveness in sterilizing the operative area to mitigate the risk of infective endophthalmitis [5]. However, it has been reported that PI can have deleterious effects on the corneal epithelium, leading to ocular surface inflammation [6, 7]. Ocular surface inflammation is a significant contributing factor to dry eye disease (DED), particularly in the evaporative type, which is also linked to meibomian gland dysfunction (MGD) [8]. The primary objective of the present study was to assess the impact of serial IVI on the ocular surface, meibomian glands (MG) and DED in patients with unilateral nAMD receiving anti-VEGF treatment.

Materials and methods

This cross-sectional study was carried out in compliance with the principles of the Declaration of Helsinki. Prior to their involvement in the research, all participants provided written consent for the utilization of their data. Approval for the study's ethical considerations was granted by the Ethical Committee of Zonguldak Bülent Ecevit University (2023/06–2).

The study recruited patients who were diagnosed with unilateral nAMD and who had undergone a minimum of 6 consecutive IVIs of anti-VEGF treatments at the Department of Ophthalmology, Zonguldak Bülent

Ecevit University Hospital. The exclusion criteria included patients with eyelid disorders (such as ectropion, entropion, or trichiasis), a history of eye surgery, the use of topical medications, and diabetes mellitus or autoimmune diseases. Patient demographic details and their previous IVI history were retrieved from electronic records.

Patients underwent standard IVI preparation involving topical anesthesia (proparacaine HCl, Alcaine, Alcon), cleaning of periocular skin and lashes with 10% PI, and subsequent ocular surface asepsis with 5% PI for 2 min. Prior to IVI administration, the ocular surface was washed with saline. All IVIs were administered by the same surgeon (S.B.) in the inferotemporal quadrant of the eyes. No saline washout was conducted after IVI, and no topical treatments, such as antibiotics or ocular lubricants, were prescribed.

Four weeks after the final injection, all participants underwent a comprehensive ophthalmological examination. Ocular surface and MG assessments were conducted in a row to minimize subsequent measurement interference. These assessments included the ocular surface disease index (OSDI) evaluation, noninvasive tear film break-up time (first and average, fNITBUT and avgNITBUT, respectively), Schirmer-1 test, corneal and conjunctival fluorescein staining graded according to the Oxford scale, and meibography.

Participants completed the OSDI questionnaire for subjective symptom evaluation [9]. The NI-TBUT was measured using the Phoenix-Tear film imaging module on a Sirius Topography device (Costruzione Strumenti Ophthalmici, Florence, Italy). The Schirmer-1 test was performed using sterile strips, and corneal staining was assessed with fluorescein paper [10, 11]. Meibography was conducted using the Phoenix-Meibography Imaging software (v. 3.2.1.20) module of the Sirius Topography device, which captures images of the upper and lower eyelids to visualize the MG. MG that were not visible on meibography were recorded as “MG loss.” (Fig. 1).

Statistical analyses

The statistical analysis was performed utilizing SPSS 22.0 (SPSS Inc.). Descriptive statistics are presented as the mean \pm standard deviation. Variables that were quantitative and nonnormally distributed were described using the median and interquartile range (IQR). The normality of the distribution was assessed using the Shapiro–Wilk test. Paired-sample *t* tests were performed for normally distributed data, and the Wilcoxon signed-rank test was performed for nonnormally distributed data to identify differences between groups. Pearson and Spearman correlations were calculated to determine the correlation between the clinical characteristics of patients and the differences in ocular surface parameters. A significance

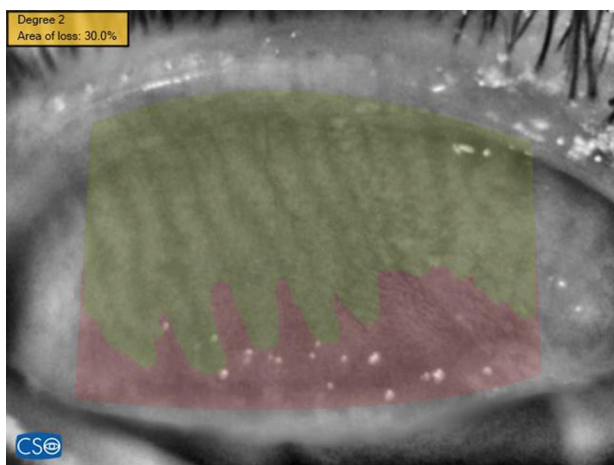


Fig. 1 Meibomian gland loss rate analysis on meibography image

level of $p < 0.05$ was considered statistically significant in all analyses.

Results

A total of 42 (22 female and 20 male) patients with a mean age of 65.04 ± 12.4 years were included in the study. The mean OSDI score was 15.1 ± 16.5 , and the median IVI number was 9 (range 6–24) (Table 1).

The median fNITBUT was 5.6 (IQR, 3.1–9.1) sec in treated eyes and 4.5 (IQR, 2.6–9.7) sec in untreated fellow eyes ($p = 0.872$). The median avgNITBUT was 6.2 (IQR, 4.1–11.8) sec in treated eyes and 7.7 (IQR, 24.4–10.4) sec in untreated fellow eyes ($p = 0.968$). The median Schirmer-1 score was 7 (IQR, 5–12) mm in treated eyes and 7 (IQR, 4–12) mm in untreated fellow eyes ($p = 0.854$). The mean Oxford score was 0.3 ± 0.4 in treated eyes and 0.2 ± 0.3 in untreated fellow eyes ($p = 0.341$). The mean MG loss rate was $56.4 \pm 6.7\%$ in treated eyes and $54.8 \pm 6.2\%$ in untreated fellow eyes ($p = 0.162$). There were no statistically significant differences between treated and untreated fellow eyes regarding fNITBUT, avgNITBUT, the Schirmer-1 test, corneal staining or MG loss. (Table 2)

Regarding the correlations of age, sex, OSDI score and IVI number with NITBUT, Schirmer, corneal staining and MG loss in treated eyes, the only significant correlation was found between age and MG loss ($p = 0.041$). (Table 3)

Discussion

The effects of serial intravitreal anti-VEGF treatment with PI asepsis on the ocular surface and MG were investigated in the present study. In contrast to our hypothesis that repeated exposure to PI may affect the ocular surface and MG morphology, the present study showed that serial IVI procedures with PI asepsis resulted in no difference in NITBUT, Schirmer, corneal staining, or MG loss compared to untreated fellow eyes in patients with nAMD.

Table 1 Demographical data and clinical characteristics of patients

Parameter	n:42
Gender (n, %)	
Female	22 (52.3%)
Male	20 (47.7%)
Age (mean \pm std)	65.04 ± 12.4
OSDI (mean \pm std)	15.1 ± 16.5
IVI (median - range)	9 (6–24)

OSDI: Ocular surface disease index, IVI: Intravitreal injection

Table 2 Comparison of dry eye and ocular surface measures, and meibomian gland loss rate between groups

Parameter	IVI treated eyes	Untreated fellow eye	p
fNITBUT			
sec, med (IQR)	5.6 (IQR, 3.1–9.1)	4.5 (IQR, 2.6–9.7)	0.872*
avgNITBUT			
sec, med (IQR)	6.2 (IQR, 4.1–11.8)	7.7 (IQR, 24.4–10.4)	0.968*
Schirmer-1			
mm/5 min, med (IQR)	7 (IQR, 5–12)	7 (IQR, 4–12)	0.854*
Oxford score			
mean \pm std	0.3 ± 0.4	0.2 ± 0.3	0.341 ^{††}
Lower eyelid MG loss rate			
%, mean \pm std	29.3 ± 3.4	28.4 ± 3.2	0.162 ^{††}
Upper eyelid MG loss rate			
%, mean \pm std	27.1 ± 3.2	26.9 ± 2.9	0.476 ^{††}

fNITBUT: First non-invasive tear break-up time, avgNITBUT: Average non-invasive tear break-up time, MG: Meibomian gland, * Wilcoxon signed-rank test, ^{††} Paired-sample t-test

The primary concern with repeated anti-VEGF therapy is the risk of endophthalmitis, prompting a standardized antiseptic procedure on the ocular surface before each IVI to reduce this risk [12]. PI is favored for its broad antimicrobial spectrum, as it can effectively target various microorganisms, including antibiotic-resistant strains [13]. Studies have demonstrated acute damage to the ocular surface following IVI, mostly as a result of the acute toxic effect of PI on the corneal epithelium,

Table 3 Correlation analysis in eyes treated with intravitreal injections

	OSDI	fNITBUT	avgNITBUT	Schirmer-1	Corneal staining	Lower eyelid MG Loss*	Upper eyelid MG Loss*
OSDI	-	r: 0.058 p=0.774	r: -0.333 p=0.089	r: 0.070 p=0.727	r: 0.313 p=0.082	r: -0.075 p=0.709	r: -0.071 p=0.729
Age	r: 0.083 p=0.680	r: -0.350 p=0.073	r: -0.337 p=0.086	r: -0.168 p=0.403	r: 0.169 p=0.103	r: 0.396 p=0.041	r: 0.365 p=0.047
Gender	r: -0.146 p=0.478	r: -0.118 p=0.556	r: 0.154 p=0.453	r: -0.263 p=0.195	r: 0.283 p=0.280	r: 0.223 p=0.274	r: 0.232 p=0.284
IVI no.	r: -0.012 p=0.954	r: -0.174 p=0.385	r: -0.160 p=0.425	r: 0.296 p=0.095	r: 0.238 p=0.108	r: 0.218 p=0.274	r: 0.222 p=0.228

OSDI: Ocular surface disease index, IVI: Intravitreal injection, fNITBUT: First non-invasive tear break-up time, avgNITBUT: Average non-invasive tear break-up time, MG: Meibomian gland

Spearman's correlation test, *Pearson correlation test

which depends on its concentration [6, 7]. Additionally, the impact of perioperative use of topical antibiotics and anesthetics on the ocular surface should be noted. However, there is potential for ocular surface recovery between IVI intervals. Understanding the long-term effects of serial IVI on the ocular surface is crucial for its management.

Chronic exposure to PI antiseptics due to the need for repeated IVI in the treatment of nAMD raises concerns about the possibility of DED induction/exacerbation in this cohort. The present study revealed no significant differences in the fNITBUT, avgNITBUT, Schirmer test, or Oxford score between IVI-treated eyes and untreated fellow eyes in nAMD patients. Recently, in their meta-analysis of the effect of serial IVI procedures on DED, Gao et al. also revealed that there was a significant increase in the OSDI score and osmolarity of the tear film, but there was no significant difference between treated and untreated eyes in the fluorescein TBUT, fNITBUT, avgNITBUT, or Schirmer test [14]. On the other hand, there was no correlation between IVI number and OSDI score in the present study. This result may have been affected by the relatively limited range of IVIs. The IVIS study also revealed no relationship between the OSDI score and the number of IVIs received [15].

MGs are responsible for the secretion of the lipid layer of the tear film, which maintains tear film stability. MGD is associated with evaporative DED [16]. There are conflicting findings regarding the impact of anti-VEGF treatment procedures on MG structure [17–19]. Kiyat et al. and Polat et al. revealed significant MG loss in the IVI treatment group [17, 18]. However, they both prescribed topical antibiotics for prophylaxis of endophthalmitis, which may have increased the exposure burden to MG. In addition, in the latter, comparison to healthy controls and the presence of diabetes may have affected the results. In contrast, Malmin et al. reported reduced MG loss in nAMD eyes treated with IVI, which was attributed to decreased inflammation of the eyelid that continued after treatment owing to the anti-VEGF agent or PI itself [19]. Our results showed no significant difference in MG loss between treated eyes and untreated fellow eyes, but there was a significant correlation with aging, as reported previously [20]. It may also prevent MG loss in the present study because no patient received topical medication after IVI.

Another aspect to consider is whether anti-VEGF treatment itself might influence dry eye measures and MG. VEGF is a proinflammatory agent that promotes the release of cytokines such as interleukin 6 and 8, as well as tumor necrosis factor- α [21]. VEGF levels are greater in tears from DED patients than in those from healthy controls [22]. Jiang et al. revealed that anti-VEGF administration to the MG improves dry eye measurements, such as

conjunctival redness and tear break-up time, in patients with MGD [23]. While systemic absorption of anti-VEGF agents is generally low, potential effects on nearby tissues cannot be entirely dismissed [24, 25].

The present study had several limitations, including its cross-sectional design, semiautomatic evaluation of MG loss, and lack of tear osmolarity measurement and staining with lisamine green. Although the fellow untreated eye was used as the control group in the present study to mitigate the impact of systemic conditions on the results, the lack of a detailed analysis of systemic diseases and medications used by the participants can also be considered another limitation of the study [26]. Therefore, a prospective multicenter clinical study with a larger sample size and longer follow-up period may be warranted in the future to reveal the longitudinal effect of IVIs on the ocular surface, MG loss and DED.

In conclusion, the results of the present study demonstrated that serial IVI of anti-VEGF agents with PI asepsis is well tolerated by nAMD patients in terms of ocular surface area, MG loss and DED measurements. The ocular surface may partially recover after IVI procedures. After undergoing IVI procedures, there might be some improvement in the condition of the ocular surface. Since dry eye significantly affects quality of life, it is important to closely monitor patients' ocular surface health during the perioperative period. More research, particularly prospective studies focusing on various aspects of dry eye, is needed to confirm these findings and better understand the underlying mechanisms involved.

Abbreviations

avgNITBUT	Average noninvasive tear break-up time
DED	Dry eye disease
fNITBUT	First noninvasive tear break-up time
IQR	Interquartile range
IVI	Intravitreal injection
MG	Meibomian glands
MGD	Meibomian gland dysfunction
nAMD	Neovascular age-related macular degeneration
OSDI	Ocular surface disease index
PI	Povidone-iodine
VEGF	Vascular endothelial growth factor

Acknowledgements

Not applicable.

Author contributions

All the authors contributed to the study's conception and design. Material preparation and data collection were performed by NS, and data analysis was performed by SB and NK. The first draft of the manuscript was written by SB and supervised by SHU. All the authors have read and approved the final manuscript.

Funding

The authors declare that no funds, grants, or other support was received during the preparation of this manuscript.

Data availability

The datasets used and analyzed in the present study are available from the corresponding author upon reasonable request.

Declarations

Ethics approval and consent to participate

This study was performed in accordance with the principles of the Declaration of Helsinki. Approval was granted by the Zonguldak Bülent Ecevit University Ethics Committee (Ethics Committee approval: 2023-04-03). Informed consent was obtained from all individual participants included in the study.

Consent to publish

Not applicable.

Competing interests

The authors declare no competing interests.

Received: 28 March 2024 / Accepted: 11 October 2024

Published online: 15 October 2024

References

1. Avery RL, Bakri SJ, Blumenkranz MS, Brucker AJ, Cunningham ET Jr, D'Amico DJ, et al. Intravitreal injection technique and monitoring: updated guidelines of an expert panel. *Retina*. 2014;34:51–18.
2. Chopra R, Preston GC, Keenan TDL, Mulholland P, Patel PJ, Balaskas K, et al. Intravitreal injections: past trends and future projections within a UK tertiary hospital. *Eye(Lond)*. 2021;36:1373–8.
3. Heier JS, Brown DM, Chong V, Korobelnik JF, Kaiser PK, Nguyen QD, et al. VIEW1 and VIEW2 study group. Intravitreal Aflibercept (VEGF trap-eye) in wet age-related macular degeneration. *Ophthalmology*. 2012;119:2537–48.
4. CATT Research Group, Martin DF, Maguire MG, Fine SL, Ying GS, Jaffe GJ, Grunwald JE, et al. Ranibizumab and Bevacizumab for treatment of neovascular age-related macular degeneration: two-year results. *Ophthalmology*. 2012;119:1388–98.
5. Uhr JH, Xu D, Rahimy E, Hsu J. Current practice preferences and safety protocols for intravitreal injection of anti-vascular endothelial growth factor agents. *Ophthalmol Retina*. 2019;3:649–55.
6. Ridder WH 3rd, Oquindo C, Dhamdhare K, Burke J. Effect of povidone iodine 5% on the cornea, vision, and subjective comfort. *Optom Vis Sci*. 2017;94:732–41.
7. Kim S, Ahn Y, Lee Y, Kim H. Toxicity of povidone-iodine to the ocular surface of rabbits. *BMC Ophthalmol*. 2020;20:359.
8. Craig JP, Nichols KK, Akpek EK, Caffery B, Dua HS, Joo CK, et al. TFOS DEWS II definition and classification report. *Ocul Surf*. 2017;15:276–83.
9. Schiffman RM, Christianson MD, Jacobsen G, Hirsch JD, Reis BL. Reliability and validity of the ocular surface disease index. *Arch Ophthalmol*. 2000;118:615–21.
10. Methodologies to diagnose and monitor dry eye disease. report of the Diagnostic Methodology Subcommittee of the International Dry Eye WorkShop. (2007). *Ocul Surf*. 2007;5:108–52.
11. Bron AJ, Evans VE, Smith JA. Grading of corneal and conjunctival staining in the context of other dry eye tests. *Cornea*. 2003;22:640–50.
12. Bhavsar AR, Glassman AR, Stockdale CR, Jampol LM. Elimination of topical antibiotics for intravitreal injections and the importance of using povidone-iodine: update from the diabetic retinopathy clinical research network. *JAMA Ophthalmol*. 2016;134(10):1181–3.
13. Lachapelle J-M, Castel O, Casado AF, Leroy B, Micali G, Tennstedt D, Lambert J. Antiseptics in the era of bacterial resistance: a focus on povidone iodine. *Clin Pract*. 2013;10:579–92.
14. Gao M, Xia F, Wang P, Feng Z, Wang X. Influence of serial intravitreal injections on measures of dry eye: a systemic review and meta-analysis. *Cont Lens Anterior Eye*. 2024;47(2):102127.
15. Verrecchia S, Chiambaretta F, Kodjikian L, Nakouri Y, El Chehab H, Mathis T, et al. A prospective multicenter study of intravitreal injections and ocular surface in 219 patients: IVIS study. *Acta Ophthalmol*. 2021;99(8):877–84.
16. Nelson JD, Shimazaki J, Benitez-del-Castillo JM, Craig JP, McCulley JP, Den S, Foulks GN. The international workshop on meibomian gland dysfunction: report of the definition and classification subcommittee. *Invest Ophthalmol Vis Sci*. 2011;52:1930-7.
17. Kıyat P, Palamar M, Nalçacı S, Akkin C. Dry Eye and Meibomian Gland Dysfunction in Neovascular Age-Related Macular Degeneration patients treated with Intravitreal injections. *Turk J Ophthalmol*. 2022;52(3):157–61.
18. Polat OA, Çetinkaya Z, Evereklioglu C, Karaca Ç, Erkişçi K. Effect of repeated topical povidone-iodine and antibiotic applications on meibomian glands and ocular surface parameters in patients with repeated intravitreal injections. *Eye Contact Lens*. 2021;47:651–4.
19. Malmın A, Thomseth VM, Førlund PT, Khan AZ, Hetland HB, Chen X, et al. Associations between serial Intravitreal injections and Dry Eye. *Ophthalmology*. 2023;130(5):509–15.
20. Arita R, Itoh K, Inoue K, Amano S. Noncontact infrared meibography to document age-related changes of the meibomian glands in a normal population. *Ophthalmology*. 2008;115:911–5.
21. Yoo SA, Kwok SK, Kim WU. Proinflammatory role of vascular endothelial growth factor in the pathogenesis of rheumatoid arthritis: prospects for therapeutic intervention. *Mediators Inflamm*. 2008;2008:129873.
22. Roda M, Corazza I, Bacchi Reggiani ML, Pellegrini M, Taroni L, Giannaccare G, Versura P. Dry eye disease and tear cytokine levels-a meta-analysis. *Int J Mol Sci*. 2020;21:3111.
23. Jiang X, Wang Y, Lv H, Liu Y, Zhang M, Li X. Efficacy of intrameibomian gland injection of the anti-VEGF agent bevacizumab for the treatment of meibomian gland dysfunction with lid-margin vascularity. *Drug Des Devel Ther*. 2018;12:1269–79.
24. Lin PY, Cheng CY, Hsu WM, Tsai SY, Lin MW, Liu JH, Chou P. Association between symptoms and signs of dry eye among an elderly Chinese population in Taiwan: the Shihpai Eye Study. *Invest Ophthalmol Vis Sci*. 2005;46(5):1593–8.
25. Avery RL, Castellarin AA, Steinle NC, Dhoot DS, Pieramici DJ, See R et al. Systemic pharmacokinetics and pharmacodynamics of intravitreal aflibercept, bevacizumab, and ranibizumab. *Retina*. 2017;37:1847-58.
26. Qian L, Wei W. Identified risk factors for dry eye syndrome: a systematic review and meta-analysis. *PLoS ONE*. 2022;17(8):e0271267.

Publisher's note

Springer Nature remains neutral with regard to jurisdictional claims in published maps and institutional affiliations.