



Making cataract surgery possible in patients with ankylosing spondylitis: A new positioning technique

Muneeb Ahmad Khan^{*}, John Burden, James Dinsmore, Alastair James Lockwood

Portsmouth Hospitals University NHS Trust, Cosham, Portsmouth, PO63LY, United Kingdom

ARTICLE INFO

Keywords:

Phacoemulsification
Cataract surgery
Glaucoma
Kyphosis
Case report

ABSTRACT

Importance: Patients with Ankylosing Spondylitis frequently have fixed kyphosis of their spine together with pain. This makes achieving acceptable head position for ocular surgery difficult. The proposal of new methods that result in successful intraocular surgery will reduce morbidity and sight loss in this group of patients.

Objective: To describe a novel technique using a vacuum bean bag positioner which enabled cataract surgery to be performed successfully under local anaesthesia. To allow prospects of technique development to standardise cataract surgery positioning in this cohort.

Results: A 42 year-old male patient underwent phacoemulsification under Sub-Tenon's local anaesthetic with intra-ocular lens implant in the inverted position with no immediate post-operative complications.

Conclusions and Relevance: Standard operating theatre equipment combined with a vacuum bean bag positioner, soft supports and securing straps can attain a position that is feasible for awake ocular surgery in patients with gross anatomical changes affecting the neck.

1. Introduction

Cataract surgery is a common procedure routinely carried out with the patient lying supine and the coronal plane of the head in a horizontal position. However, patients may find it challenging to achieve and tolerate this position if they experience breathing difficulties arising from heart or lung disease, or have musculoskeletal conditions. This report describes how an acceptable head position was achieved in a patient with ankylosing spondylitis and severe cervical kyphosis, who was unable lie supine with his head placed flat due to a fused flexion deformity of his neck. A technique employing an electric operating table capable of a range of movements, a vacuum bean bag positioner, soft supports and securing straps, was used to achieve satisfactory positioning for cataract surgery. We propose a method which could be developed to standardise cataract surgery positioning in this cohort of patients.

2. Case report

A 42-year-old male developed visual impairment in association with posterior subcapsular cataract related to topical steroid use for uveitis

and glaucoma. He had a past medical history of ankylosing spondylitis, diagnosed at the age of 16 years and disease progression over 25 years leading to joint spondylolisthesis, with his neck in fixed flexion (Fig. 1).

Due to this deformity, Aqueous Shunt Implantation with a Baerveldt tube under sedation was abandoned as it was not possible to attain appropriate positioning to gain access to his eye.

The vision in the left eye had been affected by posterior subcapsular cataract and consequently, cataract surgery was proposed in the left eye with the following rationale:

- 1) Cataract surgery should take less time than a Baerveldt plate and tube insertion.
- 2) Cataract surgery would need to be undertaken at some point to preserve vision.
- 3) Cataract surgery might regain some IOP control

The patient received an anaesthetic assessment with a view to undergoing the procedure under general anaesthesia. The severity of the fixed flexion deformity of the neck was such that the patients chin was resting on his sternum. This extreme deformity was associated with a risk of failed face-mask ventilation, precluded the insertion of a standard

Abbreviations: IOP, Intraocular Pressure.

^{*} Corresponding author.

E-mail address: muneeb.khan@liverpoolft.nhs.uk (M.A. Khan).

<https://doi.org/10.1016/j.ajoc.2021.101246>

Received 1 April 2021; Received in revised form 25 October 2021; Accepted 19 December 2021

Available online 22 December 2021

2451-9936/© 2021 Published by Elsevier Inc. This is an open access article under the CC BY-NC-ND license (<http://creativecommons.org/licenses/by-nc-nd/4.0/>).

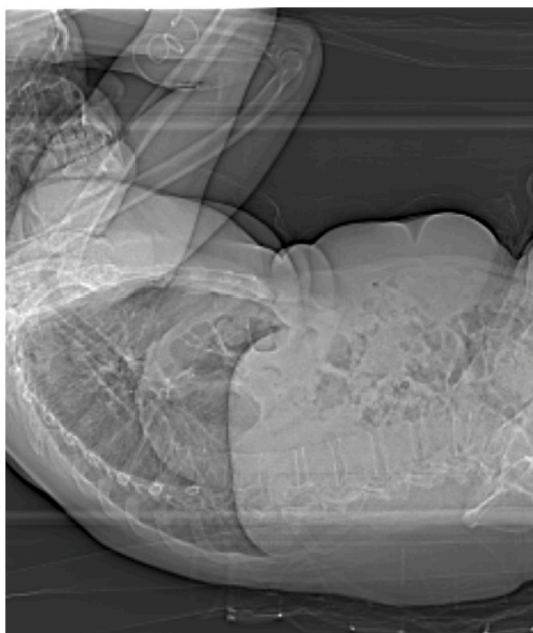


Fig. 1. CT projection radiograph illustrating extent of fusion of cervical and thoracic joint processes.

laryngoscope into the patient's mouth and would have made emergency cricothyrotomy impossible. It was advised that awake fiberoptic intubation would be indicated to safely manage the airway but there would remain a small risk of airway management difficulties with potentially significant consequence. The patient declined this option.

To attain a feasible position for surgery that could be tolerated for its duration, the patient was positioned on a vacuum bean bag positioner on a reclining operating table. Suction was applied to the vacuum bean bag so it moulded to the patient's sides in order to prevent slippage. A shaped pillow and other soft supports were placed underneath the head and neck to cushion the spine and shoulders and seatbelt straps attached to prevent the patient or mattress slipping. The patient was slowly placed in steep Trendelenburg position and asked if the position was tolerable. During a detailed team brief, it was agreed between the patient and surgeon that a return to the horizontal position at five-minute intervals would be offered as needed for patient comfort and compliance.

Thereafter, phacoemulsification under Sub-Tenon's local anaesthetic with intra-ocular lens implant was performed in the inverted position with the patient's head lying as close to the horizontal plane as able to be tolerated. The microscope was rotated to its maximum anterior position, and surgeon elevated with head forward (Fig. 2).

The procedure lasted 20 minutes. It was well tolerated by the patient with no immediate complications. He required no breaks in the procedure.

3. Discussion

This case report highlights the challenges of performing incisional ocular surgery for patients with severe kyphoscoliosis, as seen in ankylosing spondylitis. We have described a novel technique that shows it is possible to use standard theatre equipment along with a vacuum bean bag positioner to place patients in positions for cataract surgery that would not normally be tolerated.

K M Miller of UCLA (University of California, Los Angeles) has reported using pillows and tape to secure patients during cataract surgery, as have others, namely Gordon et al. (2005) and You et al. (2015).^{11,12} We found that using a vacuum beanbag enabled easy, secure, and fast positioning for our patient. Similar bean bag positioners have been used

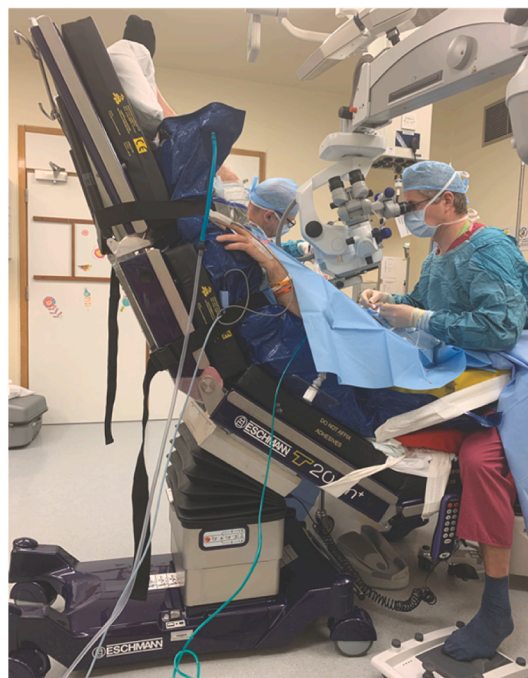

Fig. 2. Photograph depicting position of patient during surgery. The blue vacuum bean bag positioner can be seen underneath the patient. His feet are seen in the top left. (For interpretation of the references to colour in this figure legend, the reader is referred to the Web version of this article.)

in various surgeries, including reconstructive surgery and arthroscopic surgery, and have been especially used to allow for a lateral decubitus or semi-lateral decubitus position.^{13–16} The beans within the bag can be manipulated and with the help of inflation and deflation, minor adjustments made to the position of the patient, along with achieving a firm fit by increasing the contact area between the patient and the mould of the bag. Indeed certain bean bags have been designed to prevent Trendelenburg slippage.¹⁷

Our patient tolerated the position for the duration of the procedure but this might not be the case for others. For all cataract surgeries the patient's position is adjusted according to the nature of the patient's physical habitus, and ability to tolerate the procedure whilst providing the best access to perform surgery. Lee et al. (2011) has reported on 28 patients with positioning difficulties that underwent cataract surgery on a reclining cataract surgery chair with rotation of the microscope to allow for a seated or standing surgeon position.¹ We were unable to use a reclining cataract surgery chair as the patient had an extreme deformity and minimal mobility such that his thoracic spine was fused at an angle of approximately eighty degrees. Utilising a standing phacoemulsification technique with the patient in reverse Trendelenburg position does give rise to certain risks such as increases in intracranial pressure,² but with increasing Trendelenburg, other challenges come into play. Steep inclinations for prolonged periods can lead to oedema of the upper airway and the brain.³ Additionally, there is an increase in IOP and vitreous pressure from increased venous pressure.^{4,5} This may be compensated for by raising the height of the infusion bottle.⁶ Similarly, every patient presenting with spinal deformities will have curvature of the spine to varying degrees. This necessitates changes in microscope rotation capacity and the abilities of the surgeon to adjust to this change.

Various positioning techniques have been employed for cataract surgery in patients who cannot lie flat, however, a standard has not been set for each individual indication.^{7–9} In comparison to techniques employed by Ang et al. (2006), Razeghinejad et al. (2014), and Prasad et al. (2000), our patient required a very steep Trendelenburg position which further adds to the risks of vitreous bulge and a risk of the patient slipping. Similar to the straps for security used in Muthialu et al. (2009),

our patient had the added benefit of a vacuum bean bag positioner to reduce the chances of slipping, however, we utilised seatbelt straps and Oxford wedge cushions as opposed to a parachute-like harness which would have added greater security in order to prevent slippage.¹⁰ Despite this difference in arrangement, using a vacuum bean bag positioner increased contact area and friction between the patient and the mould of the bean bag, which, coupled with the seatbelt straps, resulted in greater attachment of the patient to the operating table thus reducing chances of displacement from the patient's initial position on the table, and risk of the patient falling off.

For anaesthesia, sub-Tenon's block with lignocaine and hyalase was chosen because of the surgeons experience with this technique in being able to achieve consistent, rapid, and prolonged anaesthetic block with a reduced risk of globe penetration. An anterior chamber maintainer could have provided greater support for the procedure however this was not used as we prioritised a quicker procedure length to allow for patient toleration. By developing standard positions with appropriate equipment, this cohort of patients can be taken into the operating theatre with greater confidence and assurance.

In conclusion, standard theatre equipment coupled with a vacuum bean bag positioner, soft supports and securing straps - can attain a position that is feasible for awake ocular surgery in patients with gross anatomical changes affecting the neck.

Patient consent

The patient has given written informed consent for this case to be shared.

Funding

There was no funding or grant support.

Authorship

All authors attest that they meet the current ICMJE criteria for Authorship.

Declaration of competing interest

All authors have no financial disclosures.

Acknowledgement

None.

References

- Lee RMH, Jehle T, Eke T. Face-to-face upright seated positioning for cataract surgery in patients who cannot lie flat. *J Cataract Refract Surg*. 2011;37(5):805–809. <https://doi.org/10.1016/j.jcrs.2011.03.023>.
- Mansour AM, Al-Dairy M. Modifications in cataract surgery for the morbidly obese patient. *J Cataract Refract Surg*. 2004;30(11):2265–2268. <https://doi.org/10.1016/j.jcrs.2004.02.088>.
- Hsu RL, Kaye AD, Urman RD. Anesthetic challenges in robotic-assisted urologic surgery. *Rev Urol*. 2013;15(4):178–184. <https://doi.org/10.3909/riu0589>.
- Adisa AO, Onakpoya OH, Adenekan AT, Awe OO. Intraocular pressure changes with positioning during laparoscopy. *JSLs J Soc Laparoendosc Surg*. 2016;20(4). <https://doi.org/10.4293/JSLs.2016.00078>. e2016.00078.
- Mondzelewski TJ, Schmitz JW, Christman MS, et al. Intraocular pressure during robotic-assisted laparoscopic procedures utilizing steep Trendelenburg positioning. *J Glaucoma*. 2015;24(6):399–404. <https://doi.org/10.1097/JG.0000000000000302>.
- Kelly DJ, Farrell SM. Physiology and role of intraocular pressure in contemporary anesthesia. *Anesth Analg*. 2018;126(5):1551–1562. <https://doi.org/10.1213/ANE.0000000000002544>.
- Ang GS, Ong JM, Eke T. Face-to-Face seated positioning for phacoemulsification in patients unable to lie flat for cataract surgery. *Am J Ophthalmol*. 2006;141(6):1151–1152. <https://doi.org/10.1016/j.ajo.2006.01.036>.
- Prasad S, Kamath GG, Phillips RP. Phacoemulsification in a patient with marked cervical kyphosis. *J Cataract Refract Surg*. 2000;26(8):1258–1260. [https://doi.org/10.1016/S0886-3350\(00\)00596-4](https://doi.org/10.1016/S0886-3350(00)00596-4).
- Razeghinejad M-R, Eghbal M-H. A simple way to achieve the routine position for phacoemulsification in a patient with marked thoracic kyphosis. *J Ophthalmic Vis Res*. 2014;4(4):253–255.
- Muthialu A, Rauhen M, Newsom TH, Jensen L, Oetting TA. Parachute-like harness to position patients with severe kyphosis during cataract surgery. *J Cataract Refract Surg*. 2009;35(8):1332–1334. <https://doi.org/10.1016/j.jcrs.2009.03.027>.
- Gordon MI, Rodríguez AA, Olson MD, Miller KM. Pillow case. *J Cataract Refract Surg*. 2005;31(9):1824–1825. <https://doi.org/10.1016/j.jcrs.2005.01.019>.
- You T, Huang CX, Chen S, et al. Case report: extreme patient positioning for retinal surgery in advanced kyphosis. *Retin Cases Brief Rep*. 2015;9(3):218–219. <https://doi.org/10.1097/ICB.0000000000000142>.
- Gargollo PC. Hidden incision endoscopic surgery: description of technique, parental satisfaction and applications. *J Urol*. 2011;185(4):1425–1431. <https://doi.org/10.1016/j.juro.2010.11.054>.
- Li X, Eichinger JK, Hartshorn T, Zhou H, Matzkin EG, Warner JP. A comparison of the lateral decubitus and beach-chair positions for shoulder surgery: advantages and complications. *J Am Acad Orthop Surg*. 2015;23(1):18–28. <https://doi.org/10.5435/JAAOS-23-01-18>.
- Mills JT, Burris MB, Warburton DJ, Conaway MR, Schenkman NS, Krupski TL. Positioning injuries associated with robotic assisted urological surgery. *J Urol*. 2013;190(2):580–584. <https://doi.org/10.1016/j.juro.2013.02.3185>.
- Stevens JR, Rosko AJ, Marchiano E, et al. The Spider Limb Positioner in subscapular system free flaps. *August Oral Oncol*. 2018;85:24–28. <https://doi.org/10.1016/j.oraloncology.2018.08.004>.
- Badillo FL, Goldberg G, Pinkhasov G, Badillo C, Sultan RC. Secure patient positioning using Badillo/Trendelenburg restraint strap during robotic surgery. *J Robot Surg*. 2014;8(3):239–243. <https://doi.org/10.1007/s11701-014-0459-y>.