



Endourology

Spontaneous Perforation of the UPJ: A Case Report and Review of the Literature



K. Searvance, J. Jackson*, N. Schenkman

University of Virginia, P.O. Box 800422, Charlottesville, VA 22908, USA

ARTICLE INFO

Article history:

Received 27 October 2016

Accepted 3 November 2016

Keywords:

Spontaneous ureteral rupture

Ureteropelvic junction

Urinary retention

ABSTRACT

Spontaneous rupture of the ureter is an uncommon condition defined by non-traumatic extravasation of urine. Causative factors leading to rupture include urinary calculi, malignancies, instrumentation or trauma. Ureteral rupture can lead to numerous complications, including abscess formation, urinomas, and urosepsis. Minimal literature is available regarding spontaneous ureteral perforation, especially at the ureteropelvic junction. We present a rare case of spontaneous perforation of the ureter at the ureteropelvic junction caused by an undiagnosed non-compliant bladder. This case illustrates a previously undescribed cause of spontaneous ureteral perforation and the importance of prompt identification and treatment.

© 2016 The Authors. Published by Elsevier Inc. This is an open access article under the CC BY-NC-ND license (<http://creativecommons.org/licenses/by-nc-nd/4.0/>).

Introduction

Spontaneous rupture of the ureter is rare, with location of rupture at the ureteropelvic junction among the least common sites. Previous cases of spontaneous rupture have cited urinary calculi and malignancies, however few have been attributed to a poorly compliant bladder.¹

Case presentation

A 40-year-old man was referred to the hospital by a community urologist for consultation regarding ureteral perforation, with subsequent formation of a perinephric fluid collection two months prior. The patient has a history of Down's syndrome, and was functioning independently prior to hospitalization. He had no previous urological history of kidney stones, urinary retention or incomplete bladder emptying. He presented to a community hospital with sepsis, and was found to have a large retroperitoneal fluid collection on abdominal CT imaging.

The source of the retroperitoneal fluid collection was unknown; therefore he had an exploratory laparotomy and upper endoscopy at the community facility. Upper endoscopy was negative and no other source was identified, therefore an open right retroperitoneal drain was placed. Post-operatively, the retroperitoneal drain produced clear yellow fluid, shown to be urine on a fluid creatinine assay. He then had a cystoscopy, and placement of a right ureteral stent. After a prolonged hospitalization, the drain was removed and he was discharged to a rehab facility with the ureteral stent in place. After discharge, he had another septic episode, thought to be urinary in origin, followed by a prolonged and complicated hospitalization. He was later discharged with an indwelling Foley catheter. At this time, he was referred to our institution.

On initial evaluation, we performed a video urodynamic study. At the time of the study the patient still had the right ureteral stent in place. The study revealed no sensation of bladder filling, impaired compliance at 7.7 mL/cm H₂O, acontractile detrusor and overflow incontinence. Patient had a sustained detrusor pressure of 20 cm H₂O at low volume (137 mL) despite the pressure pop off of the stented refluxing right ureter. The detrusor leak point pressure was 31 cmH₂O. Videourodynamics revealed persistent urinary leak at the ureteropelvic junction (UPJ) and a trabeculated bladder (Fig. 1).

The patient was subsequently evaluated under anesthesia with cystoscopy, retrograde pyelograms and ureteroscopy. On cystoscopy, there were no bladder abnormalities. A retrograde pyelogram was performed which demonstrated persistent extravasation of contrast

Abbreviations: CT, computerized tomography; CT IVP, computerized tomography intravenous pyelograms; UPJ, ureteropelvic junction.

Funding: This research did not receive any specific grant from funding agencies in the public, commercial, or not-for-profit sectors.

* Corresponding author.

E-mail address: jj7sb@hscmail.mcc.virginia.edu (J. Jackson).

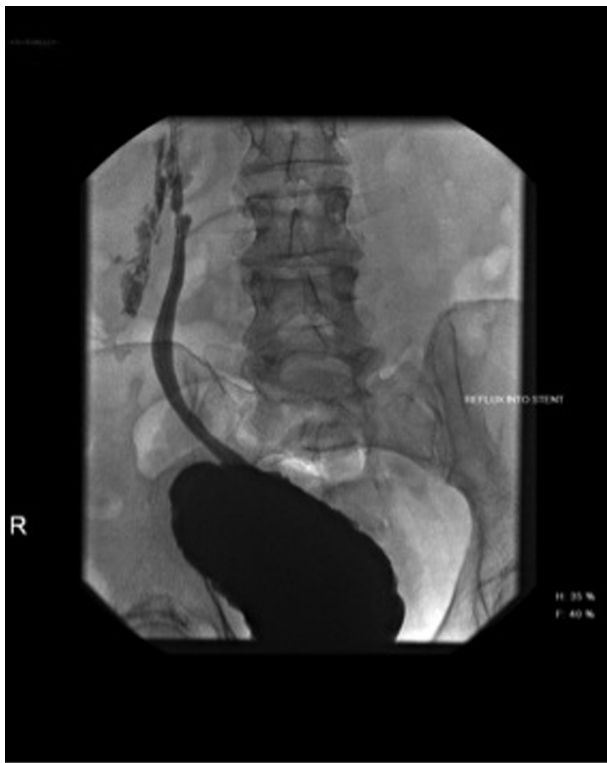

Figure 1. Fluoroscopic image obtained during video urodynamics confirming extravasation of contrast from the ureteropelvic junction.

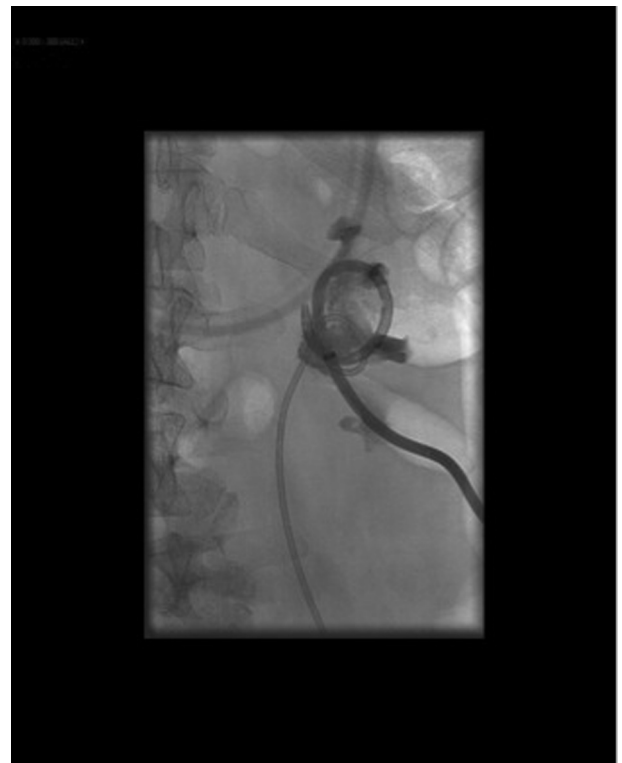

Figure 3. Fluoroscopic image obtained during antegrade pyelograms demonstrating a resolution of the injury, and no extravasation of contrast.

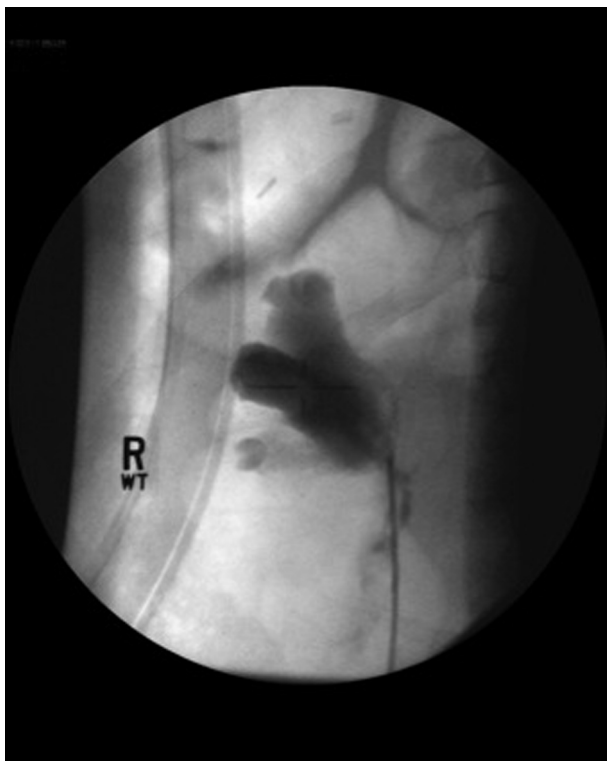


Figure 2. Fluoroscopic image obtained during retrograde pyelograms demonstrating extravasation of Contrast from the UPJ.

through the right proximal ureter at the level of the UPJ (Fig. 2). Due to his debilitated state and extensive previous surgery, the patient was given a trial of conservative management for 6 months with a ureteral stent, and Foley catheter in place. He presented three months after discharge with epigastric pain. CT IVP was performed that demonstrated a retroperitoneal abscess without evidence of ureteral extravasation of contrast. He was managed with an image guided drain placement. Drain fluid creatinine assay indicated fluid collection contained urine therefore a percutaneous nephrostomy tube was placed for complete urinary diversion. Six months after his original stent placement, the patient returned for stent exchange, antegrade and retrograde pyeloureterograms. This study demonstrated resolution of the UPJ perforation (Fig. 3). Thus the decision was made to remove the ureteral stent and percutaneous nephrostomy tube in a staged fashion. His poorly contractile bladder was managed with a suprapubic tube. He has since done well with no further concern for ongoing ureteral leakage.

Discussion

Spontaneous ureteral rupture is an uncommon condition, with few reports in the literature. The majority of cases are caused by common urinary conditions, including ureteral calculi, strictures, or tumors.¹ Out of 91 reported cases of spontaneous ureteral rupture gathered by Akpınar et al, 72 percent of cases reported stone disease as the etiology.²

Although rupture can occur at any level of the urinary system, the most commonly described rupture site is the renal fornix; rupture at the level of the UPJ is rare. Proximal ureteral ruptures due to urinary retention have been described in rare case reports. Choi et al described an upper ureter rupture at the level of L3/L4

caused by urinary retention in a female with an undiagnosed neurogenic bladder.³ Sarmah et al published an incidentally discovered proximal ureteral rupture with associated fluid collection in a 77-year-old man with an enlarged prostate who was undergoing CT urogram for evaluation of acute kidney injury.⁴

Due to the rarity of spontaneous ureteral rupture, there is no standardized management of this condition. Rupture complications such as urinomas, urosepsis, or perinephric abscess formation require prompt evaluation and intervention. Akpınar et al, described 4 cases of spontaneous ureteral rupture less than 2 cm distal to the UPJ. In 3 of the 4 cases, spontaneous healing of the rupture was documented in 7 days or less by CT scan after conservative medical management.² Starvodimos describes 5 patients with spontaneous ureteral rupture who resolved with Double J ureteral stents as management.⁵ Choi et al managed a case of upper ureter rupture with a pigtail percutaneous nephrostomy catheter, and 7 days later, demonstrated no contrast extravasation from the rupture site on antegrade pyelography.³

Conclusion

Due to the patient's debilitated state and the reported success of conservative management in the literature, our management included placement of a ureteral stent and percutaneous

nephrostomy for maximal drainage. The patient did experience several complications from his rupture, including retroperitoneal abscess formation and sepsis.

Non-traumatic rupture of the ureter is being reported more frequently in the literature. To our knowledge, this is the second reported case of a spontaneous rupture at the ureteropelvic junction caused by neurogenic bladder.

Conflict of interest

None for all authors.

References

1. Chen GH, Hsiao PJ, Chang YH, et al. Spontaneous ureteral rupture and review of the literature. *Am J Emerg Med.* 2014;32(7):772–774.
2. Akpınar H, Kural A, Turek I, et al. Spontaneous ureteral rupture: Is immediate surgical intervention always necessary? Presentation of four cases and review of the literature. *J Endourol.* 2002;16(3):179–183.
3. Choi SK, Lee S, Kim S, et al. A rare case of upper ureter rupture: Ureteral perforation caused by urinary retention. *Korean J Urol.* 2012;53(2):131–133.
4. Sarmah PB, Noah A, Kelly B, Ryan P. Asymptomatic ureteral rupture secondary to chronic urinary retention from massive prostatic enlargement. *J Surg Case Rep.* 2015;2015(11). rjv135. PMC. Web. 8 July 2016.
5. Stravodimos K, Adamakis I, Koutalellis G, et al. Spontaneous perforation of the ureter: Clinical presentation and endourologic management. *J Endourol.* 2008;22(3):479–484.