



Minimally invasive repair of pectus excavatum in adults: a review article of presentation, workup, and surgical treatment

Mohamed R. Aly, Juan M. Farina, Michael M. Botros, Dawn E. Jaroszewski

Division of Thoracic Surgery, Department of Cardiovascular and Thoracic Surgery, Mayo Clinic Arizona, Phoenix, AZ, USA

Contributions: (I) Conception and design: MR Aly, DE Jaroszewski; (II) Administrative support: MR Aly, DE Jaroszewski, JM Farina; (III) Provision of study materials or patients: MR Aly, DE Jaroszewski, MM Botros; (IV) Collection and assembly of data: MR Aly, MM Botros; (V) Data analysis and interpretation: MR Aly, DE Jaroszewski, JM Farina; (VI) Manuscript writing: All authors; (VII) Final approval of manuscript: All authors.

Correspondence to: Dawn E. Jaroszewski, MD, MBA. Professor of Surgery, Department of Cardiovascular and Thoracic Surgery, Mayo Clinic Arizona, 5777 East Mayo Boulevard, Phoenix, AZ 85054, USA. Email: jaroszewski.dawn@mayo.edu.

Abstract: Pectus excavatum (Pex) is one of the most common congenital deformities of the chest wall, with pectus constituting 90% of all chest wall deformities and excavatum being reported in almost 1:400 to 1:1,000 live births with predominant occurrence in males up to five times more than in females. Depending on the severity, presentation varies from mild cosmetic complaints to life limiting cardiopulmonary symptoms. Patients may develop symptoms as they age, and these symptoms may worsen over the years. A technique for minimally invasive repair for pectus excavatum (MIRPE) was introduced with the concept of temporarily implanting metal bars to correct the deformity. This has rapidly become the standard of care for the pediatric and adolescent patients. The use of MIRPE in adults, however, has been slower to adopt and more controversial. This is largely due to the increased calcification and rigidity of the chest wall in adults which can make the repair more complex and lead to a higher risk of complications. We present a literature review of the presentation, workup, and surgical treatment of adult patients with Pex undergoing MIRPE. Adult patients can, with advanced preoperative evaluations and technique modifications, undergo a highly successful repair resulting in symptom resolution and satisfying results.

Keywords: Minimally invasive repair for pectus excavatum (MIRPE); pectus excavatum (Pex); adults

Submitted Jan 17, 2023. Accepted for publication May 29, 2023. Published online Jun 19, 2023.

doi: 10.21037/jtd-23-87

View this article at: <https://dx.doi.org/10.21037/jtd-23-87>

Introduction

Background

Pectus comprises 90% of all chest wall deformities, with pectus excavatum (Pex) being the most common congenital deformity of the chest wall having an occurrence between 1 in 400 and 1 in 1,000 live births (1,2). Pectus deformities have been reported to occur three to five times more often in males than in females (3); however, this may be due to a failure to diagnose in females as breast tissue may conceal the severity of the defect (4-6). A recent study involving over 2,600 thoracic computed tomography imaging studies

highlights this point noting Pex being more prevalent in their female cohort (7). The deformity causes a backward displacement of the sternum compressing most commonly the right chambers of the heart, leading to reduced stroke volume and restrictive deficits (*Figure 1*) (8-11). Depending on the severity of the depression, presentation of Pex may range from a minor cosmetic issue to disabling cardiopulmonary symptoms (8,9,12). As the patient advances in age, the chest wall can become less flexible leading to progression of symptoms with patient maturing (13-15). Development of symptoms in the 4th and 5th decade was reported in nearly half of adult patients in one report,

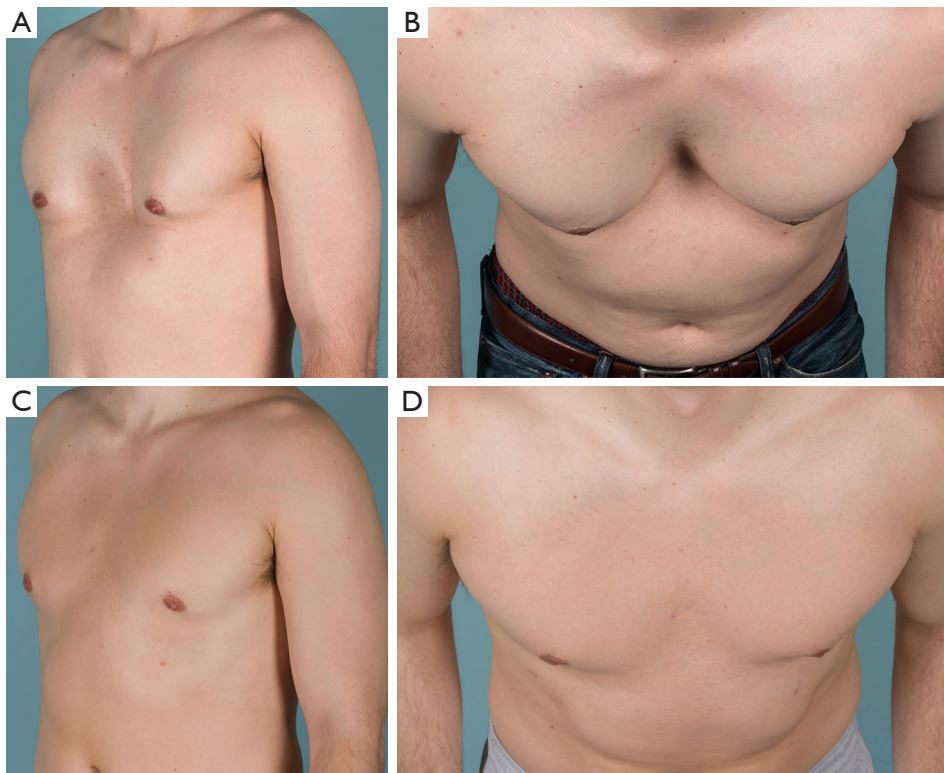


Figure 1 Real photographs of a 34-year-old male with pectus excavatum deformity before and after surgical correction. (A) Lateral view of the patient showing sunken chest and severe deformity of the sternal bone. (B) Top view of the same patient confirming severity of the deformity. Lateral (C) and top (D) view of the same patient after minimally invasive repair of pectus showing a complete correction of the deformity.

with significant improvement after surgical repair (14).

Rationale and knowledge gap

Surgical correction of the deformity with open resection of cartilage goes back in history to the 1940's with controversial outcomes especially in very young children (16). In 1998, the “Nuss” procedure or minimally invasive repair for pectus excavatum (MIRPE) was published (17). The procedure was quicker to perform with excellent cosmetic outcomes, rapidly making it the standard of care for treatment of pediatric and adolescent patients. Although the procedure has become standard of care in young patients, the use of MIRPE in adults has been slower to adopt and more controversial due to the increased difficulty of repair in this population and the higher reported rates of complications due to the less flexible mature chest wall (18-21). This is likely due to the increased calcification and

rigidity of the chest wall that occurs with aging leading to more complicated and difficult sternal elevation, greater pressure levels distributed to bars, and higher risks of bar displacement. Despite these issues in the adult population, the use of MIRPE for adult pectus repair has continued to increase. Many surgeons have modified the original Nuss techniques to allow for safe and successful adult repair even in advanced patient ages. However, no comprehensive review of the most recent techniques and their impact on outcomes and complications has been performed and this review could provide practical information for surgeons performing MIRPE on the challenging adult population.

Objective

The aim of this manuscript was to perform a review of the major articles addressing surgical techniques and outcomes of adult patients undergoing MIRPE, as well as describe our

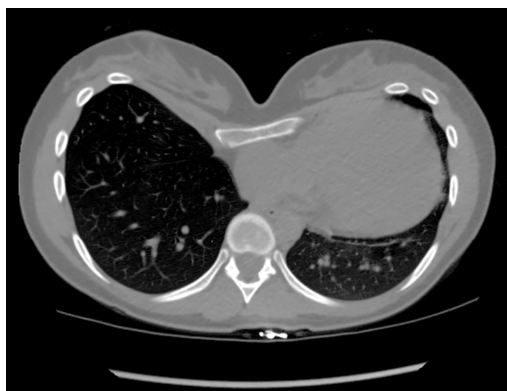


Figure 2 CT chest without contrast of a 24-year-old female patient with pectus excavatum (HI measured at 7.14). Scan shows compression of the right side of the heart (right atrium and ventricle) with displacement of the heart to the left side. CT, computerized tomography; HI, Haller index.

institution's experience.

Methods

Extensive literature review was performed including PubMed/MEDLINE publications that described surgical repair of Pex utilizing minimally invasive repair techniques in adult patients. Search terms (Nuss OR thoracoscopic pectus OR minimally invasive pectus) were utilized and the references from pulled publications were also reviewed for additional sources. Included manuscripts were both retrospective and prospective observational studies, randomized control trials, and large case series (more than 10 patients); timeframe considered was from January 2004 until March 2023. According to the objectives of this review, authors MRA and JMF selected articles discussing the preoperative evaluation (including diagnostic strategies and cardiopulmonary evaluation), modifications and updates in the surgical techniques, surgical outcomes, quality of life evaluation, and pain management. Selected articles were conferred with author DEJ and discrepancies were solved by consensus among the authors.

Adult presentation: symptoms and cardiopulmonary effects of pectus excavatum

An adult patient presenting for surgery may do so secondary to a new onset of symptoms in adulthood after having been completely asymptomatic without noticeable physiologic

effects from the defect when they were younger (22-26). Others may have had milder symptoms as an adolescent but developed definitive worsening of their symptoms with age (23). Adult symptoms most commonly include exercise intolerance, increasing levels of fatigue, dyspnea on exertion, tachycardia, and compensatory tachypnea (10,11,23,27-30). Most adult patients have lived with the cosmetic deformity for many years and the appearance of their chest generally was not the primary reason for undergoing surgical repair. Despite this, visible physical differences do increase the Pex patient's risk for body image and interpersonal difficulties and should not be discounted (29,31).

The majority of patients complain of cardiopulmonary type symptoms including exertional dyspnea, tachycardia/palpitations, and chest pain (32), yet the cardiopulmonary effects of Pex on adult patients remains a topic of debate (33-35) due to a paucity of reports evaluating adult patients (36,37). The inward deformity of the anterior chest wall causing right heart compression and displacement into the left chest to various degrees can have negative cardiopulmonary consequences on adult patients as supported by recent data (*Figure 2*) (9,25). Direct cardiac compression has been shown to not only reduce right heart chamber's dimensions, but also stroke volume, cardiac output, and diastolic and systolic function as well as strain (38). This may explain the cause of accelerated fatigue and compensatory tachycardia (9,22,39-41). Mocchegiani *et al.* (42) reported that the right ventricular outflow tract in Pex patients was significantly narrower and right ventricle end-diastolic and-systolic areas were significantly smaller. Töpper *et al.* (43) evaluated cardiovascular function of adult Pex patients using cardiac magnetic resonance and found that right ventricle ejection fraction was reduced in this population, with a significant improvement after MIRPE. Chao *et al.* (9) demonstrated an immediate improvement in right heart chambers size, and right and left ventricle systolic function (using strain techniques) after surgical repair by using intraoperative transesophageal echocardiography. Negative cardiopulmonary effects of Pex in 68% (of 392 preop patients) had significantly improved physiological benefits of MIRPE [130 patients with post op cardiopulmonary exercise testing (CPET)]. This has been demonstrated by Jaroszewski *et al.* (44) in a recent publication using CPET in adult cases. One small underpowered study (only 15 patients completed follow up) by Udholm *et al.* (10) found no significant improvement (but a trend towards improvement) at one year after MIRPE in adult patients. Sternal compression is also suspected to decrease the thoracic volume, which

can reduce the mixed venous oxygen saturation, exercise tolerance, tidal volume, and vital capacity (34,44,45). A summary of the major publications with evidence related to the effects of MIRPE on cardiopulmonary function in adult patients can be found in *Table 1*.

Diagnostic work up

The preoperative evaluation of an adult patient presenting with clinically symptomatic Pex warrants anatomical and functional workup to assess the significance of the defect and necessity for repair. Many of the presenting symptoms can be caused by a variety of cardiopulmonary diseases and a thorough workup to eliminate these causes is critical. Additional analyses based on patient comorbidities are obtained as deemed fit by the physician and symptoms dictate (32). A complete history and physical examination, including findings suggestive of connective tissue diseases such as Marfan Familial Syndrome is critical (17,23-26).

Thoracic imaging with either a non-contrast computerized tomography (CT) or magnetic resonance imaging (MRI) is critical for a radiographic evaluation of the severity and characteristics of the deformity as well as any other intrathoracic pathology (18,49). Since the deformity may significantly worsen when a patient exhales, performing the imaging during both inspiratory and expiratory phases is recommended (31). Thoracic imaging also helps show the degree of cardiac compression, cardiac displacement, and pulmonary atelectasis if present. The deformity of the bony and cartilaginous skeleton can be visualized in a three-dimensional view which also helps patients visualize the extent of their deformity and the impact it has on the mediastinal structures (50). The measurement and calculation of the Haller Index is performed from imaging, which is the ratio of the lateral diameter of the chest to the distance between the sternum and spine, at the point of maximal depression). This is often requested by insurance companies for qualification of repair even though its relevance in the adult patient is undocumented. Despite the general acceptance of HI 3.2 as the cutoff for defining severe pectus, indexes of less than 3.2 do still represent significant variants from normal and may be associated with significant cardiopulmonary disability and symptoms as well as body image problems (18,26,31,49,51,52). A Haller index (HI) <3.2 should lead to evaluation by correction index which is a much better estimation of the severity of deformity with >10% being significant enough to consider surgery if symptomatic and compression is present (53).

Adult patients commonly present with several cardiovascular conditions such as hypertension or coronary diseases. Depending on the patients' cardiovascular risk profile, a 12-lead electrocardiogram (ECG) or more complex tests could be important to rule out the presence of such conditions. Right bundle branch block and other conduction abnormalities are commonly associated with the adult Pex patient (10,23,26) thus highlighting the importance of an ECG to exclude intracardiac conduction disorders and dysrhythmias.

An echocardiogram is performed to document the effects of the depressed sternum on the right heart chambers (as they are the most anteriorly located) as well as associated interference with diastolic or systolic function (22,26,39,41,51,54). It is recommended to be performed preoperatively; however, getting accurate transthoracic views can be difficult due to the displacement of the heart from the deformity (55,56). Compression by the chest wall is mainly in the anteroposterior plane and best seen in a transverse axis (39). The apical four-chamber view can also visualize any extrinsic compression to the right ventricle. A positional echo with imaging of the right ventricle and right outflow tract to look for significant decreases in cardiac output and right-sided hemodynamics due to increased compression in position change from supine to sitting or leaning forward is available at some institutions and we find it of great value in assessing low deformities (57). In adult patients with history of connective tissue disorders (which are commonly associated with Pex deformity), an echocardiogram is also critical to assess valvular abnormalities, including mitral valve prolapse, and evaluation of the aortic root size and valvular competency. In patients requiring cardiac surgery, concurrent repair of pectus is recommended and should be considered as subsequent repair may require a redo sternotomy with a higher risk of complications (58,59). In some patients, a transesophageal view may be necessary to better evaluate the right chambers of the heart and any outflow obstruction present, as well as to exclude some potential concomitant cardiac abnormalities (39).

Although not available in all institutions, CPET is used to help quantify how Pex affects a patient's cardiopulmonary function and ability to exercise. Several studies implementing CPET measurement showed O₂ pulse (a surrogate for stroke volume) and oxygen consumption (VO₂max) significantly below predicted values in patients with Pex (7,31,34,44,45,52). More recent investigations demonstrated that almost 70% of adult Pex patients showed

Table 1 Clinical studies evaluating cardiopulmonary function of adult pectus excavatum patients before and after minimally invasive repair

Study	N	Age, year	Haller index	Test used	Cardiopulmonary outcomes
Farina <i>et al.</i> (46), 2023	127	Median 29.0 (IQR 15.4)	Median 4.2 (IQR 1.7)	Intraoperative transesophageal echocardiography	Significant improvements in right ventricular stroke volume and diastolic function as measured by hepatic vein waves velocities were seen after pectus repair (P<0.001 for all comparisons) Preoperatively, 5.5% of patients had constrictive-like physiology (end-diastolic retrograde flow) which normalized after surgical correction (P=0.016) Patients with more proximal cardiac compression had greater improvements in hepatic vein velocities after repair
Jaroszewski <i>et al.</i> (44), 2022	392 130 completed pre- and post-operative evaluation	Mean 32.4 (SD 10.0)	Mean 4.6 (SD 2.2)	Cardiopulmonary exercise testing Intraoperative transesophageal echocardiography	Post-repair tests were performed immediately before bar removal procedure A significant improvement (P<0.001) in cardiopulmonary outcomes (VO ₂ max, O ₂ pulse, anaerobic threshold, and maximal ventilation) was seen in the post-repair evaluations In a sub-analysis of 39 patients who also underwent intraoperative transesophageal echocardiography at repair and at bar removal, a significant (P<0.001) increase in RV stroke volume was found
Skoczyński <i>et al.</i> (47), 2022	55	Mean 21.1 (SD 3.0)	NA	Pulmonary function tests	Participants who underwent MIRPE had normal pulmonary function and exercise capacity 7 years after the intervention Compared with matched controls, patients who underwent MIRPE had higher RV%, TLC, and FEV1/VC ratio
Chao <i>et al.</i> (38), 2018	165	Mean 33 (range, 18–71)	Mean 5.7 (SD 3.1)	Intraoperative transesophageal echocardiography	Right heart chambers size (right atrium, tricuspid annulus, and RVOT dimensions) significantly (P<0.001) increased after surgery RV and LV systolic function (evaluated with strain techniques) significantly (P<0.001) improved immediately after surgical repair
Udholm <i>et al.</i> (10), 2016	19 15 completed follow-up	Mean 32	NA	Cardiopulmonary exercise testing	Surgical correction in adult patients did not improve the cardiopulmonary function (VO ₂ max, cardiac output, FEV1) one year after surgery
Töpper <i>et al.</i> (43), 2016	38	Mean 21 (SD 8.3)	Mean 9.64	Cardiac magnetic resonance	Pectus was associated with reduced RVEF in the preoperative tests, which significantly (P<0.001) improved after surgical correction (mean follow-up 472 days after surgery) LVEF was between normal limits before surgery, but also increased significantly after correction (P=0.016)
Chao <i>et al.</i> (9), 2015	168	Mean 33 (range, 18–71)	Mean 5.7 (SD 3.1)	Intraoperative Transesophageal Echocardiography	Surgical correction caused a significant (P<0.001) improvement in right heart chambers size (right atrium, tricuspid annulus and right ventricle outflow tract) and cardiac output immediately after surgical repair
Szydlik <i>et al.</i> (48), 2013	44	Mean 16 (range, 10–32)	NA	Pulmonary function test	A significant improvement (P<0.001) in lung function (FVC, FEV1, FEF25, and FEV1/VC ratio) was seen in patients who underwent Nuss procedure

IQR, interquartile range; SD, standard deviation; NA, not applicable; VO₂max, maximal oxygen consumption; RV, right ventricle; MIRPE, minimally invasive repair of pectus excavatum; RV%, residual volume; TLC, total lung capacity; FEV1, forced expiratory volume in 1 s; VC, vital capacity; RVOT, right ventricle outflow tract; LV, left ventricle; RVEF, right ventricle ejection fraction; LVEF, LV ejection fraction; FVC, forced vital capacity; FEF25, forced expiratory flow for 25%.

preoperative abnormal oxygen consumption as assessed by CPET. The statistically significant improvement seen in patients CPET after surgical correction, makes this test an important indicator for strongly supporting the need for surgery in this population (44). A normal VO_{2max} should not preclude repair as this study also noted significant improvement in patients that had normal (>80%) preoperative VO_{2max} values.

Pulmonary function tests (PFT) could help detect restrictive respiratory impairment due to the reduction of internal thoracic volume caused by the deformity (1). In general, PFTs should be obtained in adult patients with symptoms of significant dyspnea or history of asthma or smoking to rule out underlying emphysema (50). Most Pex patients are expected to have normal or low normal PFTs (26,51).

Indications for surgery

The indications for intervention are not fully standardized in the adult population, yet from our experience and from other experts in the field, corrective surgery should be considered in patients with two or more of the following criteria. Individual insurance companies have different criteria for coverage and should be reviewed:

- (I) Haller index of 3.2 or greater or Correction index of 10% or greater (53,60);
- (II) Cardiac compression, displacement, mitral valve prolapse, or conduction abnormalities (16);
- (III) Pulmonary function testing showing restrictive respiratory disease (61);
- (IV) Cardiopulmonary deficits assessed by CPET;
- (V) Symptoms, especially progression;
- (VI) Psychosocial effects (12,14,62).

In summary, consideration of surgical treatment of the adult Pex patient should be given for severe anatomic deformities and patients with symptoms or cardiopulmonary deficits attributable to the deformity. As more experience with adult pectus repair accumulates, criteria for repair are likely to evolve.

Preparation for surgery

For our patient cohort, posture training exercises are highly recommended preoperatively. These exercises aim to strengthen the upper back muscle groups including latissimus dorsi, trapezius, and rhomboids. As for the front of the chest, we encourage patients to stretch using a

foam thoracic spine roller which helps to open and loosen the chest as much as possible. After pectus surgery, back spasms and pain are common and these measurements can be helpful when done in the weeks to months prior to surgery. In addition, selective testing for metal allergy could be performed preoperatively based on personal or family history. In our cohort, adults have better history as to their known allergies and exposure to metal and jewelry. Implementing this method in our practice has been sufficient and we had no problems with allergy thus far. Other institutions have started utilizing selective testing with the aim of using titanium bars in patients with allergies (63). We also utilize titanium bars selectively in patients that weigh >85–90 kgs or have a rigid chest with a diameter wider than 14.5–15 inches to allow for greater support.

Pectus excavatum repair techniques

Over the years, a variety of techniques for surgical repair of Pex have been used on patients of all ages. The two most common methods used today for repair of the adult include modifications of the open Ravitch approach and the MIRPE.

The original open procedure was described by Ravitch in the 1940's. The modified open technique has been used for several decades and is still in use to this day. It involves resection of the deformed costal cartilage to allow the return of the sternum to its normal position with or without sternal osteotomy (23,64–66). There are a variety of modifications reported including the use of mesh, others include placement of a metal strut, and plating to support the sternum which may be left in place for 6 months to 1 year (67,68). The open technique may be for some surgeons better suited for patients who have a combination of Pex with pectus carinatum, significant asymmetry, or extensive defects involving the uppermost ribs and cartilage. Recurrence rates after repair of Pex using the open technique have been reported in 2–10% of patients (23,64,69).

The MIRPE was published in 1998 by Nuss and has since been implemented by most pediatric surgeons treating the pectus deformity. In the MIRPE technique, a plane is created behind the sternum with the help of thoracoscopy, and curved bars are inserted and rotated such that its curve elevates the area of deformity. The bars are secured to the chest wall and removed in 2–3 years after the chest wall cartilage have remodeled. This technique has gained widespread popularity because of its minimally invasive

approach, as evidenced by small skin incisions, no need for cartilage resection, short operative time, minimal blood loss (70) and comparable postoperative morbidity (71) with respect to the modified Ravitch procedure (18). The advantages of MIRPE include avoidance of rib cartilage resections, sternal osteotomies, conspicuous mid-chest scars, less blood loss, and an overall shorter operative time. Even adult patients with significant asymmetry associated with their deformity may benefit from MIRPE correction.

Since the original publication of the Nuss procedure, several modifications have been made to the MIRPE technique (72–80) (Table 2). Modifications involved various aspects of the surgery including use of thoracoscopy, patient positioning and location of incisions, methods of passing the bars across the chest and their guidance, details of the bars placed (size, shape, positioning, and number), and methods of bar fixation and stabilization (80). In our practice we have utilized several modifications which have allowed for successful extension of the procedure into even advanced aged adult patients. These modifications include (but are not limited to) use of multiple support bars, forced sternal elevation, reinforcement of intercostal spaces, and multi point fixation to secure the bars. With these technique modifications, successful MIRPE has been reported in adults up to the age of 72 years old (32), with surgery resulting in resolution of symptoms, improved quality of life, and satisfying results (59,80,103).

MIRPE technique for adult cases

In the adult patient, critical issues with MIRPE include safe dissection across the anterior mediastinum without inducing pericardial inflammation. Thoracoscopy via the right chest should be used in all cases. As discussed in Table 2, forced sternal elevation allows better visualization, which increases the safety of the procedure and decreases the force required to enter and rotate bars in the less flexible adult chest wall (80). We utilize a Rultract retractor (Rultract Inc., Cleveland, OH, USA) with an extension arm attached to the left side of the operating table at the level of the clavicle. Stab incisions are placed on the sternal defect a few cm apart and the tips of a perforating clamp (we utilize the Lewin Spinal Perforating Forceps, V. Mueller NL6960; CareFusion, Inc., San Diego, CA, USA) are manipulated into the anterior table of the sternum. The cable connector is then attached to the clamp and the sternum elevated (Figure 3). Other methods of sternal elevation have been described in Table 2.

It is critical that the bars enter and exit the thorax medially otherwise the defect and sternum will not be pushed anteriorly (Figure 4A,4B). The bar should be positioned approximately 1–1.5 cm lateral to the internal mammary artery (IMA). If it is not, the bar will not push the defect anteriorly, and the deformity will not be corrected. We routinely reinforce the intercostal spaces that will hold the bar with a figure-of-eight FiberWire “hammock” (Figure 5) which incorporates the rib above and below the interspace. The hammock is placed slightly lateral to the bar exit site to prevent the intercostal muscle stripping and the ribs and interspace from widening out and it allows the weight of the bar to rest on the suture versus the intercostal muscles as it exits the chest. A stabilizer could also be utilized medially (medial stabilizer) if deemed necessary. It is usually used in the low bars which are at a higher risk of displacement (Figure 6).

We place 2–3 bars to achieve complete correction. Bars should not be too long as to cross beyond the mid axillary line. Bars can be placed in multiple configurations. Cross bars are used by some surgeons; however, they have been reported to have an increased risk of pleural effusions (99). Over time and experience, we have increased the frequency of placing 3 bars (Figure 6). We have also noted an increase in the incidence of pleural effusions as our percentage of 3 bar cases has grown to >55% and routinely leave a chest tube thru the camera port site. Others have reported higher effusions in adult patients and there may be an increased inflammatory response (104). Multiple bars distribute the sternal pressure over a broader area and allow more complete correction in the adult patient. Using multiple bars may also decrease the risk of displacement (21,30,80). Placement of a second or even third bar is often necessary and desirable to achieve optimal cosmetic results and to fully elevate the chest in the adult patient (11,24,25,28,30,69,70,80). In our experience, indications for two or more bars in the adult included a depressed area >3 intercostal spaces and a HI greater than 3.5.

Both IMA may be occluded out by the Nuss bars especially on an asymmetric side. This is a risk factor that should be explained to the patient and is part of the consent process. In patients with strong family history of coronary artery disease, we stress this and the potential that the vessel will likely not be usable in the future should they require a coronary artery bypass graft. Robotic takedown of a section of the IMA could be utilized to diminish the risk of injuring the artery (105) which was reported in 40% of patients by Yüksel *et al.* (106).

Table 2 Surgical modifications that were implemented in MIRPE across the years

Surgical modification	Study	Description
Forced sternal elevation		
Crane technique	Park <i>et al.</i> (81), 2008, Kelly <i>et al.</i> (63), 2022	A percutaneous wire is passed through the bony tissue of the sternum and the wire is connected to a table-mounted crane system. This alleviates pressure on the hinge points which prevents tearing/stripping of intercostal muscles. The bar displacement rate, major complication rates and reoperation rates all decreased after implementing this new approach
Two Langenbeck handheld retractors	Tedde <i>et al.</i> (82), 2012	Incision made in the intercostal space adjacent to the sternum at the deepest portion of the defect. Enters the hemithorax from the left side first, position 1 st retractor at the hinge point, followed by entering the right hemithorax to introduce a camera and 2 nd retractor allowing safe retrosternal instrumentation
Horseshoe-shaped sternal elevator	Takagi <i>et al.</i> (83), 2012	No extra skin incision is needed for the elevator, its usage enlarges the retrosternal space for safer passage of thoracoscopically guided introducer and allows visualization of substernal tunneling
Vacuum bell	Haecker <i>et al.</i> (84), 2012	Vacuum Bell is placed on the defect and suction is initiated to reduce defect. Applicable only to young and elastic chest wall defects
Subxiphoid incision/sternal lift + anchor	Johnson <i>et al.</i> (85), 2013	A subxiphoid incision is made and a retractor is placed under the sternum to assist with elevation of sternum Subxiphoid incision allows access to create a plane between the posterior sternum and pericardium. Lift is inserted beneath the sternum, allowing sternal elevation and locked in place by anchor
Bone clamp and Rultract retractor	Jaroszewski <i>et al.</i> (79), 2014	Incisions made either parallel or perpendicular to sternum, tips of bone clamp placed into anterior table of the sternum and attached to the cable coming off a table mounted Rultract retractor. This reduces risk of intercostal muscles stripping and reduces stress on intercostal spaces during bars insertion and rotation
T-fastener suture technique	Kim <i>et al.</i> (86), 2014	Chest incisions are made lateral to the sternum, sutures are delivered outside the lateral chest and tied to a metal plate with 3 holes. T-fastener sutures are used to elevate the anterior chest from both sides of the sternum by tying them to a crank attached to a cross bar. No specialized equipment is required (metal plate commonly used in orthopedic practice), no incisions need to be made (needle holes created require no suture closures), and no fracture or tear occur to anterior chest. Metal plate must be retrieved at the end which presents difficulty after bars are positioned
Bar stabilization technique		
Five-point fixation (multipoint suture fixation MPF), stabilizers, CFT and HP, and bridge technique	Park <i>et al.</i> (78), 2004, (81), 2008, (87), 2011, (88,89), 2015	MPF offered bar fixation to upper and lower ribs at the ends of the bar and a fifth wire at the hinge point medially with all sutures done through a single incision on each side. Attachment of stabilizers to both ends of the pectus bar to prevent bar flipping. CFT holds the bar to a rib by hooking it with a metal blade. HP reinforced the hinge points (the entrance points of the bar to the thoracic cavity) with a metal plate. Combining HP and CFT in adults: after bars insertion lifts the chest wall depression, both bar ends were fixed together by bridge plates and screws which enhances stability of the bars and eliminates need for suturing
Third point of fixation	Hebra <i>et al.</i> (73), 2006	Alongside crossbars/lateral stabilizers, a third point of fixation consisting of absorbable suture is placed around the bar and around an anterior rib next to the right side of the sternum
Medial stabilizers and multiple PDS sutures	Pilegaard <i>et al.</i> (90), 2008, Pio <i>et al.</i> (91), 2016	Stabilizer placed closer to the entrance of the bar into the thoracic cavity, thereby decreasing the risk of rotation/displacement as the stabilizer functions as a hinge

Table 2 (continued)

Table 2 (continued)

Surgical modification	Study	Description
Unilateral stabilizer and multiple PDS sutures	Kelly <i>et al.</i> (92), 2010	Attaching a metal stabilizer on the left and placing multiple pericostal PDS sutures around the bar and underlying ribs
FiberWire multiple points fixations of bars circumferentially and bilaterally	McMahon <i>et al.</i> (75), 2014	Multipoint fixation with FiberWire that are secured around ribs (lateral and medial), fixation on both sides of the bar, and utilizes the bar's lateral holes to minimize lateral dislocation
Figure-of-eight FiberWire reinforcement, FiberWire multipoint fixation and sternal fixation	Jaroszewski <i>et al.</i> (72), 2016	"Hammock" Figure-of-Eight FiberWire tie that incorporates the rib above and below the interspace that the bar will be placed in to reinforce and prevent lateral posterior bar migration and intercostal muscle stripping. FiberWire multipoint fixation around ribs and bars medial and lateral, sternal holes drilled for suture that incorporates bar and sternal bone for medial fixation
Stabilizer secured with wire/ FiberWire + several pericostal PDS sutures	Nuss <i>et al.</i> (17), 1998	Stabilizer is attached and secured to the bar with non-absorbable sutures on the left side + multiple PDS sutures placed around the bar and the underlying rib on the right side
Bars configuration		
Compound	Park <i>et al.</i> (78), 2004, Yoon <i>et al.</i> (93), 2010	The compound bar presents a concept of exaggerated convexity in the center of the bar, with a smaller central arc between the hinge point and adjoining at either side by two larger arcs. The smaller central arc makes the bar convex enough to elevate the depression and the larger lateral arcs can adjust the width of the bar easily to fit the size of the chest
Multiple bars	Nuss (94), 2008, Pilegaard <i>et al.</i> (90), 2008, Nagaso <i>et al.</i> (95), 2010, Stanfill <i>et al.</i> (96), 2012	Using 2 bars have been implemented by surgeons treating adults with Pex to fully correct the deformity and decrease rate of recurrence/requirement of revision. Multiple bars allow for better distribution of pressure (decreasing risk of bar migration) and may also decrease the pain
	Jaroszewski <i>et al.</i> (72), 2016	>40% of patients required 3 bars to fully correct the deformity
New steel bar	Li <i>et al.</i> (97), 2015	Introduced new steel bar through bilateral thoracic minimally invasive incisions using a thoracoscope for guidance. The bar was installed or removed by pushing and pulling without flipping it
Cross bar technique	Park <i>et al.</i> (98), 2016, Sayan <i>et al.</i> (99), 2021	Cross bars cover the promontory of the depression and the whole anterior chest wall (including lateral parts) by avoiding hinge compressions and residual depressions
Introducer bar complex	Wang <i>et al.</i> (100), 2021	New kind of steel bar curved according to normal structure of the human anterior chest wall and includes 15 different specifications. One end designed to connect to introducer/stabilizer. Connecting the bar to the stabilizer creates the introducer-bar complex which doesn't require rotation or turning, it is pushed in our pulled out
Thoracoscopy		
Unilateral thoracoscopy	Croitoru <i>et al.</i> (101), 2002	Direct visualization of the mediastinal structures using right thoracoscopy via an additional small incision for thoracoscopic observation in the right pleural cavity under insufflation of CO ₂ made the procedure much safer
Bilateral thoracoscopy	Cheng <i>et al.</i> (102), 2008	The modified bilateral thoracoscopy is utilized via the wound made for bar insertion without extra incisions for the thoracoscope. It allows for excellent visualization over each pleural cavity. It could eliminate the risk of cardiopulmonary injuries as it allows direct bilateral inspection of mediastinum and facilitate mediastinal dissection
Pectoscopy	Park <i>et al.</i> (74), 2010	A specially designed video-scope approach to guide the introducer or the pectus clamp as it is passed through the mediastinum

MIRPE, minimally invasive repair for pectus excavatum; MPF, multipoint fixation; CFT, claw fixator; HP, hinge plate; PDS, polydioxanone; Pex, pectus excavatum.

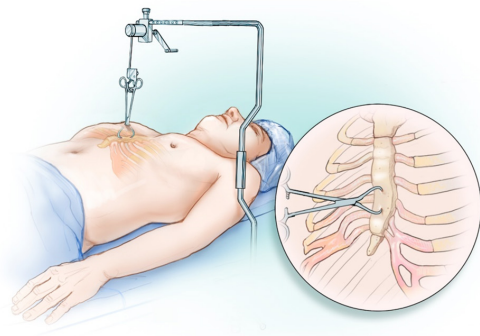


Figure 3 Forced sternal elevation applied via the use of a Rultract retractor positioned on the left side of the patient with the Lewin bone clamp attached to the sternum.

Premature removal of bars has shown a high incidence of recurrence in the adult population and a time frame between 2–3 years has been recommended for the adult patient by at least two publications; however, we have increased our recommended time for bars in the adults to 3–3.5 years due to the more rigid chest wall and significant pressure that is on the bars (11,24). Recurrence rates as low as 2–5% have been reported for the MIRPE adult patients. However, follow-up is on a small number of patients for limited time periods (11,25,30,69,80).

Postoperatively, stretching is paramount in the early period starting on the second week. Initially, this can be accomplished by patients raising their arms above their heads and climbing the wall with full arm extension. Patients can anticipate return to full activity around 6–8 weeks. There should be no heavy lifting for at least 6 weeks (nothing greater than 10 pounds) and only after our team reviews the patients 6 weeks postoperative chest X-ray.

MIRPE outcomes

Concerns have been raised regarding a higher incidence of complications following the more complex MIRPE procedure in adults. Data regarding a direct comparison of complications between adult and pediatric population are not abundant and many of these reports are from early in the learning period of the procedure (72,107,108). Kim *et al.* documented a difference in their post operative complications with MIRPE in adults versus children of 58.3% *vs.* 11.1% with bar displacement in up to 1/3rd of adult patients (109). These complications include an increased risk of bleeding, cardiac perforation, longer

hospitalizations, greater postoperative pain, significant rates of bar migration, and a higher overall recurrence rate. The modifications of the procedure by different surgeons over the years (*Table 2*) have helped to reduce the rate of complications both in pediatrics and in adult cases. Complications and improvement in outcomes have been a large driving force for implementation of these modifications.

Understandably, experience weighs heavily on surgeon's complication rates and much of the early reports on the Nuss procedures reported high rates of complications, including bar rotation. These outcomes have subsequently improved significantly in experienced hands; therefore, it is important when reviewing data to note the date range and the center the publication includes. There is a significant learned curve with the MIRPE (at least 25 pediatric cases and likely double for adults) (110) and with surgeon experience increased, the MIRPE has become a common procedure with life threatening complications occurring in less than 0.1% of cases (21,111). *Table 3* reviews the outcomes in recent studies from 2010 onwards after MIRPE in larger studies of adult Pex patients.

Most recent publications by experienced centers have shown that MIRPE is safely performed in adult patients with minimal blood loss, shorter operating times, and relatively few postoperative complications (11,22,24,25,28,30,69,70,92). Pleural effusions were a common complication in most adult series (3–17%) with a number requiring thoracentesis or chest tube placement postoperatively (11,24,25,66,69,70,92).

Quality of life and patient satisfaction

The exercise limitations caused by the deformity along with the cosmetic disfigurement may cause a decrease in quality of life and alteration of patients' social behavior (40,118–122). Lack of self-confidence, poor body-image, avoidance of social activities, and emotional difficulties are noted in Pex patients. Feelings of anxiety, depression, sadness, and frustration have also been reported (119). The importance of corrective surgery for improvement in psychological distress, quality of life, and exercise tolerance has been documented in the literature. The majority of these studies report a mixed population of children and adolescents with few adults; therefore, it is difficult to make broad based assumptions as to their application to the adult population (117,121,123,124).

Krasopoulos *et al.* (121) proposed the two-step Nuss




Figure 4 An illustration depicting both the correct and incorrect positions of the Nuss bars in a pectus patient undergoing surgical repair. (A) Shows a Nuss bar that enters and exits the interspace laterally either due to stripping of the intercostal muscles or placement was too lateral. Bars in this position will not have anterior contact with the sternum and will thus fail to elevate the pectus excavatum deformity. (B) The correct position of the Nuss bar entering and exiting the interspace medially approximately 1–1.5 cm from the internal mammary artery and sternum with excellent elevation of the sternum and pectus deformity.

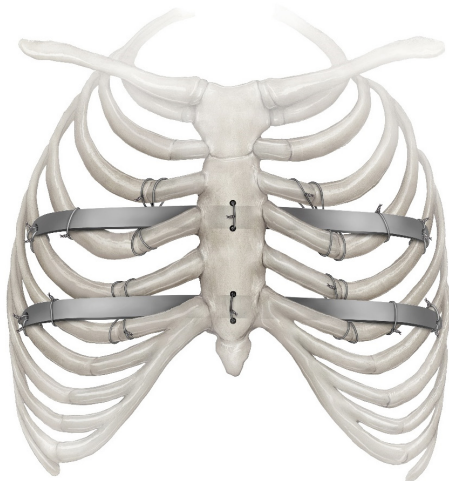


Figure 5 Figure-of-eight FiberWire incorporates the ribs above and below the interspace to provide reinforcement and prevents the displacement of the bar. FiberWire multipoint fixation are applied around ribs and bars (both medial and lateral). Sternal holes drilled for FiberWire suturing that incorporates bar and sternal bone for medial fixation.

Questionnaire modified for Adults (NQ-mA) and a Single Step Questionnaire (SSQ). These questionnaires measured the disease-specific quality-of-life changes after surgery and assessed the impact of surgery on the physical and psychological well-being of postoperative patients. They noted a significant improvement in self-

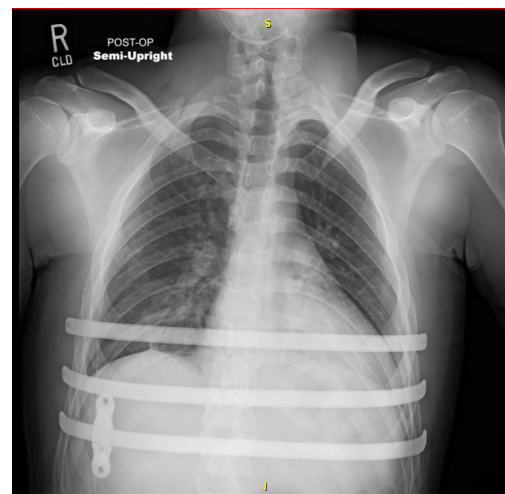


Figure 6 Anteroposterior chest X-ray of a patient with 3 bars in place to ensure proper correction of the deformity and medial stabilizer on the lower bar.

esteem, social functioning, and a high level of satisfaction following surgery. Their questionnaire also included the impact of surgical wounds/scars on the overall cosmetic result, consciousness of the presence of metallic bar, the decision to have the operation again and questions about postoperative pain which may have limited the patient satisfaction after surgery. Most of the patients were very satisfied with their scars, almost all of them were conscious of the presence of bar, but none of them considered that to be a major inconvenience. Pain was a significant concern

Table 3 Surgical outcomes of the major publications regarding MIRPE in adults

Study	N	Age, year	Haller index	Complications	Results
Viggiano <i>et al.</i> (112), 2022	93 patients	Median 23 (range, 18–42)	Mean 5.1 (range, 2.3–12.6)	Overall 12.9% • Seroma/hematoma (2.1%) • Wound infection (2.1%) • Hemothorax (1.1%) • Pneumothorax requiring chest tube (4.3%) • Bar displacement (4.3%)	• All 93 patients were evaluated in follow-up at 3, 12, and 24 months after MIRPE and 6 months after bar removal • No operative/perioperative mortalities, no life-threatening complications • Better or much better quality of life after operation was reported in 94.7% of patients after 6 months of bar removal • 97.8% of patients were satisfied or very/extremely satisfied with cosmetic appearance 3 months after MIRPE and 6 months after bar removal
De Loos <i>et al.</i> (18), 2021	327 patients (272 in young group range, 11–24 years and 55 in adults group range, 25–47 years)	Young group median 16 Adult group median 32	Young group median 3.7 Adult group median 3.6	• Young group vs. adult group respectively: • Bar displacement requiring intervention 3% vs. 4% • Bar removal within 3 years for chronic pain 2% vs. 7% • Pneumothorax (requiring chest tube) 0.4% vs. 0% • Reoperation for bleeding, 0.4% vs. 0% • Empyema 0.4% vs. 0% • Pneumonia 1% vs. 4% • Wound infection 2% vs. 0% • Chronic pain without bar removal 1% vs. 7%	• Median follow-up was 34 months for the young group and 36 months for the adults • Operation in adults was longer than in young group (35 vs. 30 minutes respectively, P=0.004) • Minor complications occurred more often in the adults group (young 4% vs. adult 11%, P=0.002), yet both groups had the same length of hospital stay duration

Table 3 (continued)

Table 3 (continued)

Study	N	Age, year	Haller index	Complications	Results
Pilegaard (107), 2016	1,713 patients (604 > 18 years)	Median 16 (range, 7–58)	NA	Overall 7.6% <ul style="list-style-type: none"> • Bar rotation (1.2%) and dislocation (0.8%) • Pneumothorax (1.1%) • Deep infection (0.9%) • Pneumonia (0.6%) • Seroma (0.4%) • Pleural effusion (0.3%) • Sternotomy (0.1%) • Sternal fracture (0.06%) • Removal of bar before time (0.4%) • Removal of stabilizer due to pain (1.4%) • Bar end dropped into chest cavity (0.2%) • Bleeding requiring intervention (0.1%) 	<ul style="list-style-type: none"> • During the study period, an increase in the number of bars used and an increase in proportion of older patients undergoing MIRPE. A decrease in bar length and a decrease in length of hospital stay were also noted • No mortalities took place
Pilegaard (113), 2011	52 patients	Median 37 (range, 30–53)		<ul style="list-style-type: none"> • Pneumothorax (48%) all resolved spontaneously except for 1 patient • Bar removal prematurely (3.8%) • Bar migration requiring intervention (1.9%) • Deep infection (1.9%) 	<ul style="list-style-type: none"> • 70% needed two bars or more for satisfactory corrective results • No operative deaths

Table 3 (continued)

Table 3 (continued)

Study	N	Age, year	Haller index	Complications	Results
Jaroszewski et al. (72), 2016	266 patients (compared 18–29 years cohort vs. 30–72 years cohort)	115 patients mean 23.7 (range, 18–29) 151 patients mean 40.4 (range, 30–72)	Mean 5.6 (range, 2.5–26.7, mean 5.8 (range, 2.5–24.9)	18–29 y cohort vs. 30–72 respectively: • Bar rotation 1.7% vs. 6.6% • Infection 0.9% vs. 1.3% • Pleural effusion 2.6% vs. 6% • Pneumothorax (requiring chest tube) 0.9% vs. 0.7% • Pulmonary embolism 0% vs. 1.3% • Bleeding requiring transfusion 0% vs. 0.7% • Reoperation for bleeding, 1.7% vs. 0.7% • Pneumonia 0% vs. 4% • Urinary tract infection 0% vs. 4% • Urinary retention requiring catheterization 7.8% vs. 8.6% • Readmission for pain control 0% vs. 2%	• MIRPE was successfully performed in 96.5% of patients 18–29 years and in 88.7% of patients 30–72 years • For 30–72 years patients, open cartilage resection or sternal osteotomy were more commonly performed • Three bars were required in >40% of patients for complete correction • Frequency of bar rotation requiring reoperation was not statistically significant between the two groups (P=0.74) • No recurrences reported

Table 3 (continued)

Table 3 (continued)

Study	N	Age, year	Haller index	Complications	Results
Pawlak et al. (114), 2016	680 patients (group A range, 7–14 years =156), (group B range, 15–20 years =328), (group C range, 21–49 years =196)	Mean 18.2±5.4 (range, 7–49) Group A: mean 12.2±2.0 Group B: 17.2±1.6 Group C: 25.2±4.8	Group A: 3.83 (2.44–10.7) Group B: 3.72 (2.20–6.69) Group C: 3.59 (1.94–5.16)	Overall 35% • Pneumothorax (A =14.7%, B =27.1%, C =22.4%). Requiring drainage (A =26.1%, B =27%, C =50%) • Pleural effusion (A =5.7%, B =6.4%, C =11.2%). • Pleural hematoma (A =0.6%, B =0.9%, C =0.5%) • Bar rotation (A =0.6%, B =3.6%, C =2%) • Fever (A =1.9%, B =3.6%, C =4.6%) Recurrence (A =3.2%, B =1.2%, C =1.5%) • Bar displacement (5%)	• From all age groups, good and very good cosmetic effects were achieved in 97.7% • Recurrence was observed more often in younger patients although they had the lowest surgical morbidity • Although complications rate was high, it didn't interfere with satisfactory outcome of the surgical repair
Erşen et al. (115), 2016	836 patients (236 >18 years)	Mean 16.8 (range, 2–45) Adults mean 23.2 (range, 18–45)	4.4 (3.3–11)	• Pneumothorax (2%) • Cardiac injury – small ventricular defect (0.4%) • Wound infection (1%) • Prolonged pain (1%) • Pleural effusion (0.8%) • Pneumonia (0.4%) • Sternotomy (0.4%) • Thoracic outlet syndrome (0.4%)	• Complications overall rates among the adults and younger patients were 26.2% and 11.8% respectively (P=0.007). Although complications rate was higher, adults did not have a longer length of hospital stay when compared to younger patients • Patients with >1 bar had less pain in the adult group

Table 3 (continued)

Table 3 (continued)

Study	N	Age, year	Haller index	Complications	Results
Sacco Casamassima <i>et al.</i> (116), 2016	98 patients participated in the survey	Median 30.9 (range, 21.8–55.1)	Mean 4.3±1.3	<ul style="list-style-type: none"> • Prolonged chest pain (12.2%) • Pneumothorax (11.2%) • Wound infection (10.2%) • Pleural effusion (8.2%), pleural effusion requiring chest tube (1%) • Reoperation for bar displacement (4.1%) • Seroma (3.1%) • Hemothorax (2%) • Pneumonia (2%) • Pulmonary embolism (1%) 	<ul style="list-style-type: none"> • 1 bar was placed in 89.7% of patients • 2 patients required reoperation for recurrence • 94.4% of patients reported satisfactory overall results • 79.5% of patients would have the operation again
Hoksch <i>et al.</i> (117), 2016	129 patients (19 patients followed >10 years)	Median 21 (range, 13–56)	Median 4.8 (range, 2.4–11.7)	<ul style="list-style-type: none"> • Overall 14.7% • Bar displacement (7%) • Dressler syndrome (2.3%) • Hemothorax (1.6%) • Seroma/hematoma (1.6%) • Pneumothorax (0.8%) • Wound infection (0.8%) • Dislocation of stabilizer (0.8%) 	<ul style="list-style-type: none"> • There was no mortality and no severe injury of any anatomical structure during MIRPE or during bar removal • Patients were followed up at 3, 12, and 36 months • After long-term observation, >90% of patients reported their quality of life after the operation as better or much better • >10 years follow-up patients reported 84.2% of very high satisfaction with cosmetic results and 94.7% of patients would have the operation again

Table 3 (continued)

Table 3 (continued)

Study	N	Age, year	Haller index	Complications	Results
Hanna et al. (118), 2013	73 patients (51 participated in survey)	Median 20 (range, 16–51)	NA	<ul style="list-style-type: none"> Overall 15.1% Pneumothorax (4.1%) Bar displacement (2.7%) Poor cosmesis (2.7%) Bar infection (1.4%) Bruising (1.4%) Ileus (1.4%) Pericarditis (1.4%) 	<ul style="list-style-type: none"> 81% of patients had 1 bar placed 4 reoperations took place, 2 for bar displacement and 2 for poor cosmesis (all operations done thoroscopically) Majority of respondents believe their overall health and exercise tolerance improved after MIRPE 92.1% reported subjective improvement in their chest wall appearance 80% of patients were satisfied with the cosmetic result 96% of patients would have the operation again
Park et al. (87), 2011	102 patients (H group used hinge plate =27, N group did not use hinge plate =75)	Mean 19.4 [15–35]	NA	<ul style="list-style-type: none"> Overall 20% Pleural effusion (9%) Bar dislocation (3%) Pneumothorax (3%) Seroma (3%) Hemothorax (2%) 	<ul style="list-style-type: none"> Reoperation were done in four patients, three patients due to bar dislocation and one patient for hemothorax No bar displacement occurred in the H group patients (those with hinge plate)

MIRPE, minimally invasive repair for pectus excavatum; NA, not available.

Standardized Protocol Pain Medications	
Perioperative:	
•	Gabapentin, 600 mg oral
•	Celecoxib, 400 mg oral
•	Acetaminophen, 1000 mg oral
•	Dexamethasone, 8 mg intravenous
•	Methadone, 0.2-0.35 mg/kg intravenous
•	General anesthesia induced: single dose of intravenous fentanyl 0.5-2 mcg/kg, lidocaine 1-2 mg/kg, and propofol 2-4 mg/kg
Postoperative day 0:	
•	Ketorolac, 30 mg, intravenous every 8 hours
•	Gabapentin, 600 mg, oral, every 8 hours
•	Acetaminophen, 1000 mg, oral, every 6 hours
Postoperative day 1- discharge medications:	
•	Ketorolac discontinued; ibuprofen started, 600 mg, every 8 hours
•	Gabapentin, 300 mg, oral, every 8 hours
•	Acetaminophen, 1000 mg, oral, every 6 hours
•	Tramadol, 50-100 mg, oral, every 3-4 hours as needed

Figure 7 Pain control regimen used by our group.

in the immediate postoperative period which decreased significantly after several weeks and none of their patients were on analgesics 4–5 months after surgery. Other surgeons have subsequently utilized this modified survey for postoperative assessment (116,117,123) (*Table 3*).

Pain control methods

Postoperative pain remains an ongoing concern for adults undergoing MIRPE (125). Many analgesic approaches have been implemented to minimize postoperative pain and decrease use of opioids. These approaches include thoracic epidural, patient-controlled analgesia (PCA), subcutaneous catheters and most recently cryoablation therapy, all which reported successful pain control in the immediate postoperative period (126-130). Current techniques are successfully managing perioperative pain with the majority of patients reporting resolution of significant pain one month after surgery (49). In our experience (*Figure 7*), a standardized protocol achieved good pain control and included gabapentin, ibuprofen, acetaminophen, and narcotics with local anesthesia through the use of cryoablation in the most recent years (21,119,123). Over the course of 11 years at our institution, we utilized epidural (90 patients), subcutaneous catheter (428 patients), and cryoablation (211 patients). All three groups compared

together, patients who underwent cryoablation had the shortest length of hospital stay (1.9 ± 1.5 days) and utilized the least amount of morphine equivalents. Neuropathic pain following cryoablation has been reported and is expected to emerge around 8 weeks postoperatively. In our experience, it would be difficult to distinguish the source of neuropathic pain whether it is from the cryoablation or secondary to the bars placed (131). There were minimal patients that experienced pain during this time frame and the cryoablation group was lower than other cohorts. At occasions, adjuvant medications for postoperative pain management have been deployed to help control the pain if continued to bother our patients, including the use of ketorolac, diazepam, and gabapentin (127,128). A randomized clinical trial including adult Pex patients (mean age 20.9 years) showed a decrease in hospital length of stay and opioids requirement in the Cryoablation group versus thoracic epidural analgesia, while offering equivalent pain control (132).

Conclusions

Minimally invasive repair of pectus excavatum in adult patients showed increased difficulty and higher complication rates when compared to pediatric and adolescent populations. Skilled surgeons with experience can perform the procedure safely and successfully using

technique modifications to the original Nuss procedure. The published data supports the cardiopulmonary benefits of MIRPE repair in adults with Pex. Patients who have undergone surgery show good satisfaction, a significant improvement in self-image, and report surgery to have had a positive impact on their wellbeing and ability to exercise.

Acknowledgments

Funding: None.

Footnote

Provenance and Peer Review: This article was commissioned by the Guest Editors (Erik R. de Loos, Jean H. T. Daemen and Frank-Martin Haecker) for the series “Minimally Invasive Treatment of Pectus Deformities” published in *Journal of Thoracic Disease*. The article has undergone external peer review.

Peer Review File: Available at <https://jtd.amegroups.com/article/view/10.21037/jtd-23-87/prf>

Conflicts of Interest: All authors have completed the ICMJE uniform disclosure form (available at <https://jtd.amegroups.com/article/view/10.21037/jtd-23-87/coif>). The series “Minimally Invasive Treatment of Pectus Deformities” was commissioned by the editorial office without any funding or sponsorship. DEJ is involved in development projects and intellectual property with ZimmerBiomet thru Mayo Clinic Ventures. The authors have no other conflicts of interest to declare.

Ethical Statement: The authors are accountable for all aspects of the work in ensuring that questions related to the accuracy or integrity of any part of the work are appropriately investigated and resolved. All images are published with the participant’s consent.

Open Access Statement: This is an Open Access article distributed in accordance with the Creative Commons Attribution-NonCommercial-NoDerivs 4.0 International License (CC BY-NC-ND 4.0), which permits the non-commercial replication and distribution of the article with the strict proviso that no changes or edits are made and the original work is properly cited (including links to both the formal publication through the relevant DOI and the license). See: <https://creativecommons.org/licenses/by-nc-nd/4.0/>.

References

1. Fokin AA, Steuerwald NM, Ahrens WA, et al. Anatomical, histologic, and genetic characteristics of congenital chest wall deformities. *Semin Thorac Cardiovasc Surg* 2009;21:44-57.
2. Cobben JM, Oostra RJ, van Dijk FS. Pectus excavatum and carinatum. *Eur J Med Genet* 2014;57:414-7.
3. Beier JP, Weber PG, Reingruber B, et al. Aesthetic and functional correction of female, asymmetric funnel chest - a combined approach. *Breast* 2009;18:60-5.
4. Fonkalsrud EW. Management of pectus chest deformities in female patients. *Am J Surg* 2004;187:192-7.
5. Ma IT, Rebecca AM, Notrica DM, et al. Pectus excavatum in adult women: repair and the impact of prior or concurrent breast augmentation. *Plast Reconstr Surg* 2015;135:303e-12e.
6. Park HJ, Gu JH, Jang JC, et al. Correction of pectus excavatum with breast hypoplasia using simultaneous pectus bar procedure and augmentation mammoplasty. *Ann Plast Surg* 2014;73:190-5.
7. Biavati M, Kozlitina J, Alder AC, et al. Prevalence of pectus excavatum in an adult population-based cohort estimated from radiographic indices of chest wall shape. *PLoS One* 2020;15:e0232575.
8. Sigalet DL, Montgomery M, Harder J, et al. Long term cardiopulmonary effects of closed repair of pectus excavatum. *Pediatr Surg Int* 2007;23:493-7.
9. Chao CJ, Jaroszewski DE, Kumar PN, et al. Surgical repair of pectus excavatum relieves right heart chamber compression and improves cardiac output in adult patients - an intraoperative transesophageal echocardiographic study. *Am J Surg* 2015;210:1118-24; discussion 1124-5.
10. Udholm S, Maagaard M, Pilegaard H, et al. Cardiac function in adults following minimally invasive repair of pectus excavatum. *Interact Cardiovasc Thorac Surg* 2016;22:525-9.
11. Del Frari B, Blank C, Sigl S, et al. The questionable benefit of pectus excavatum repair on cardiopulmonary function: a prospective study. *Eur J Cardiothorac Surg* 2021;61:75-82.
12. Kelly RE Jr, Cash TF, Shamberger RC, et al. Surgical repair of pectus excavatum markedly improves body image and perceived ability for physical activity: multicenter study. *Pediatrics* 2008;122:1218-22.
13. Jaroszewski DE, Fonkalsrud EW. Repair of pectus chest deformities in 320 adult patients: 21 year experience. *Ann Thorac Surg* 2007;84:429-33.

14. Kragten HA, Siebenga J, Höppener PF, et al. Symptomatic pectus excavatum in seniors (SPES): a cardiovascular problem?: A prospective cardiological study of 42 senior patients with a symptomatic pectus excavatum. *Neth Heart J* 2011;19:73-8.
15. Jaroszewski D, Steidley E, Galindo A, et al. Treating heart failure and dyspnea in a 78-year-old man with surgical correction of pectus excavatum. *Ann Thorac Surg* 2009;88:1008-10.
16. Nuss D, Obermeyer RJ, Kelly RE. Nuss bar procedure: past, present and future. *Ann Cardiothorac Surg* 2016;5:422-33.
17. Nuss D, Kelly RE Jr, Croitoru DP, et al. A 10-year review of a minimally invasive technique for the correction of pectus excavatum. *J Pediatr Surg* 1998;33:545-52.
18. de Loos ER, Pennings AJ, van Roozendaal LM, et al. Nuss Procedure for Pectus Excavatum: A Comparison of Complications Between Young and Adult Patients. *Ann Thorac Surg* 2021;112:905-11.
19. Johnson WR, Fedor D, Singhal S. Systematic review of surgical treatment techniques for adult and pediatric patients with pectus excavatum. *J Cardiothorac Surg* 2014;9:25.
20. Hebra A, Swoveland B, Egbert M, et al. Outcome analysis of minimally invasive repair of pectus excavatum: review of 251 cases. *J Pediatr Surg* 2000;35:252-7; discussion 257-8.
21. Kanagaratnam A, Phan S, Tchanchaleishvili V, et al. Ravitch versus Nuss procedure for pectus excavatum: systematic review and meta-analysis. *Ann Cardiothorac Surg* 2016;5:409-21.
22. Casar Berazaluce AM, Jenkins TM, Garrison AP, et al. The chest wall gender divide: females have better cardiopulmonary function and exercise tolerance despite worse deformity in pectus excavatum. *Pediatr Surg Int* 2020;36:1281-6.
23. Shamberger RC, Welch KJ, Castaneda AR, et al. Anterior chest wall deformities and congenital heart disease. *J Thorac Cardiovasc Surg* 1988;96:427-32.
24. Li S, Tang ST, Tong Q, et al. Nuss repair of pectus excavatum after surgery for congenital heart disease: experience from a single institution. *J Thorac Cardiovasc Surg* 2014;148:657-61.
25. Gürkan U, Aydemir B, Aksoy S, et al. Echocardiographic assessment of right ventricular function before and after surgery in patients with pectus excavatum and right ventricular compression. *Thorac Cardiovasc Surg* 2014;62:231-5.
26. Das BB, Recto MR, Yeh T. Improvement of cardiopulmonary function after minimally invasive surgical repair of pectus excavatum (Nuss procedure) in children. *Ann Pediatr Cardiol* 2019;12:77-82.
27. Cartoski MJ, Nuss D, Goretsky MJ, et al. Classification of the dysmorphology of pectus excavatum. *J Pediatr Surg* 2006;41:1573-81.
28. Maagaard M, Tang M, Ringgaard S, et al. Normalized cardiopulmonary exercise function in patients with pectus excavatum three years after operation. *Ann Thorac Surg* 2013;96:272-8.
29. Hu T, Feng J, Liu W, et al. Modified sternal elevation for children with pectus excavatum. *Chin Med J (Engl)* 2000;113:451-4.
30. Castellani C, Windhaber J, Schober PH, et al. Exercise performance testing in patients with pectus excavatum before and after Nuss procedure. *Pediatr Surg Int* 2010;26:659-63.
31. Coln E, Carrasco J, Coln D. Demonstrating relief of cardiac compression with the Nuss minimally invasive repair for pectus excavatum. *J Pediatr Surg* 2006;41:683-6; discussion 683-6.
32. Velazco CS, Arsanjani R, Jaroszewski DE. Nuss procedure in the adult population for correction of pectus excavatum. *Semin Pediatr Surg* 2018;27:161-9.
33. Kaguraoka H, Ohnuki T, Itaoka T, et al. Degree of severity of pectus excavatum and pulmonary function in preoperative and postoperative periods. *J Thorac Cardiovasc Surg* 1992;104:1483-8.
34. Morshuis WJ, Folgering HT, Barentsz JO, et al. Exercise cardiorespiratory function before and one year after operation for pectus excavatum. *J Thorac Cardiovasc Surg* 1994;107:1403-9.
35. Haller JA Jr, Loughlin GM. Cardiorespiratory function is significantly improved following corrective surgery for severe pectus excavatum. Proposed treatment guidelines. *J Cardiovasc Surg (Torino)* 2000;41:125-30.
36. Nevieri R, Moutaigne D, Benhamed L, et al. Cardiopulmonary response following surgical repair of pectus excavatum in adult patients. *Eur J Cardiothorac Surg* 2011;40:e77-82.
37. Malek MH, Fonkalsrud EW, Cooper CB. Ventilatory and cardiovascular responses to exercise in patients with pectus excavatum. *Chest* 2003;124:870-82.
38. Chao CJ, Jaroszewski D, Gotway M, et al. Effects of Pectus Excavatum Repair on Right and Left Ventricular Strain. *Ann Thorac Surg* 2018;105:294-301.
39. Ravanbakhsh S, Farina JM, Bostoros P, et al. Sex Differences in Objective Measures of Adult Patients

- Presenting for Pectus Excavatum Repair. *Ann Thorac Surg* 2022;114:1159-67.
40. O'Keefe J, Byrne R, Montgomery M, et al. Longer term effects of closed repair of pectus excavatum on cardiopulmonary status. *J Pediatr Surg* 2013;48:1049-54.
 41. Willekes CL, Backer CL, Mavroudis C. A 26-year review of pectus deformity repairs, including simultaneous intracardiac repair. *Ann Thorac Surg* 1999;67:511-8.
 42. Mocchegiani R, Badano L, Lestuzzi C, et al. Relation of right ventricular morphology and function in pectus excavatum to the severity of the chest wall deformity. *Am J Cardiol* 1995;76:941-6.
 43. Töpper A, Polleichtner S, Zagrosek A, et al. Impact of surgical correction of pectus excavatum on cardiac function: insights on the right ventricle. A cardiovascular magnetic resonance study†. *Interact Cardiovasc Thorac Surg* 2016;22:38-46.
 44. Jaroszewski DE, Farina JM, Gotway MB, et al. Cardiopulmonary Outcomes After the Nuss Procedure in Pectus Excavatum. *J Am Heart Assoc* 2022;11:e022149.
 45. Kelly RE Jr, Mellins RB, Shamberger RC, et al. Multicenter study of pectus excavatum, final report: complications, static/exercise pulmonary function, and anatomic outcomes. *J Am Coll Surg* 2013;217:1080-9.
 46. Farina JM, Jaroszewski DE, Arsanjani R, et al. Improved Right Ventricular Diastolic Function Assessed by Hepatic Vein Flow After Pectus Excavatum Repair. *Annals of Thoracic Surgery Short Reports*. 2023. (In press). <https://doi.org/10.1016/j.atsr.2023.02.009>.
 47. Skoczyński S, Kudela G, Brożek G, et al. Pulmonary function, exercise capacity and dyspnea in patients 7 years after Nuss surgery. *Adv Med Sci* 2022;67:179-86.
 48. Szydlík S, Jankowska-Szydlík J, Zwaruń D, et al. An effect of Nuss Procedure on lung function among patients with pectus excavatum. *Pol Przegl Chir* 2013;85:1-5.
 49. Kelly RE Jr, Shamberger RC, Mellins RB, et al. Prospective multicenter study of surgical correction of pectus excavatum: design, perioperative complications, pain, and baseline pulmonary function facilitated by internet-based data collection. *J Am Coll Surg* 2007;205:205-16.
 50. Kelly RE Jr. Pectus excavatum: historical background, clinical picture, preoperative evaluation and criteria for operation. *Semin Pediatr Surg* 2008;17:181-93.
 51. Westphal FL, Lima LC, Lima Neto JC, et al. Prevalence of pectus carinatum and pectus excavatum in students in the city of Manaus, Brazil. *J Bras Pneumol* 2009;35:221-6.
 52. Pyeritz RE, McKusick VA. The Marfan syndrome: diagnosis and management. *N Engl J Med* 1979;300:772-7.
 53. St Peter SD, Juang D, Garey CL, et al. A novel measure for pectus excavatum: the correction index. *J Pediatr Surg* 2011;46:2270-3.
 54. Obermeyer RJ, Cohen NS, Jaroszewski DE. The physiologic impact of pectus excavatum repair. *Semin Pediatr Surg* 2018;27:127-32.
 55. Raggio IM, Martínez-Ferro M, Bellía-Munzón G, et al. Diastolic and Systolic Cardiac Dysfunction in Pectus Excavatum: Relationship to Exercise and Malformation Severity. *Radiol Cardiothorac Imaging* 2020;2:e200011.
 56. Rodriguez-Granillo GA, Toselli L, Farina J, et al. Usefulness of strain cardiac magnetic resonance for the exposure of mild left ventricular systolic abnormalities in pectus excavatum. *J Pediatr Surg* 2022;57:319-24.
 57. Pulivarthi V, Jaroszewski D, Arsanjani R, Abstract 16999: Effect of Positional Echocardiogram on Right Sided Hemodynamics in Pectus Excavatum Patients vs. Healthy Adults. [online] *Circulation*. Available online: https://www.ahajournals.org/doi/10.1161/circ.138.suppl_1.16999
 58. Stephens EH, Dearani JA, Jaroszewski DE. Pectus Excavatum in Cardiac Surgery Patients. *Ann Thorac Surg* 2023;115:1312-21.
 59. Jaroszewski DE, Gustin PJ, Haecker FM, et al. Pectus excavatum repair after sternotomy: the Chest Wall International Group experience with substernal Nuss bars. *Eur J Cardiothorac Surg* 2017;52:710-7.
 60. Poston PM, Patel SS, Rajput M, et al. The correction index: setting the standard for recommending operative repair of pectus excavatum. *Ann Thorac Surg* 2014;97:1176-9; discussion 1179-80.
 61. Goretsky MJ, Kelly RE Jr, Croitoru D, et al. Chest wall anomalies: pectus excavatum and pectus carinatum. *Adolesc Med Clin* 2004;15:455-71.
 62. Frantz FW. Indications and guidelines for pectus excavatum repair. *Curr Opin Pediatr* 2011;23:486-91.
 63. Kelly RE Jr, Obermeyer RJ, Goretsky MJ, et al. Recent Modifications of the Nuss Procedure: The Pursuit of Safety During the Minimally Invasive Repair of Pectus Excavatum. *Ann Surg* 2022;275:e496-502.
 64. Dzielicki J, Korlacki W, Janicka I, et al. Difficulties and limitations in minimally invasive repair of pectus excavatum--6 years experiences with Nuss technique. *Eur J Cardiothorac Surg* 2006;30:801-4.
 65. Chen Z, Amos EB, Luo H, et al. Comparative pulmonary functional recovery after Nuss and Ravitch procedures for

- pectus excavatum repair: a meta-analysis. *J Cardiothorac Surg* 2012;7:101.
66. Johnson JN, Hartman TK, Pianosi PT, et al. Cardiorespiratory function after operation for pectus excavatum. *J Pediatr* 2008;153:359-64.
 67. Fonkalsrud EW, Salman T, Guo W, et al. Repair of pectus deformities with sternal support. *J Thorac Cardiovasc Surg* 1994;107:37-42.
 68. Buchwald J, Ligarski D, Polewczyk T. Long-term results after the modified Ravitch procedure performed in children and adolescents - a one-time procedure without the need to use additional support of the sternum. A retrospective study. *Kardiochir Torakochirurgia Pol* 2020;17:173-7.
 69. Tikka T, Kalkat MS, Bishay E, et al. A 20-year review of pectus surgery: an analysis of factors predictive of recurrence and outcomes. *Interact Cardiovasc Thorac Surg* 2016;23:908-13.
 70. Mao YZ, Tang S, Li S. Comparison of the Nuss versus Ravitch procedure for pectus excavatum repair: an updated meta-analysis. *J Pediatr Surg* 2017;52:1545-52.
 71. Lam MW, Klassen AF, Montgomery CJ, et al. Quality-of-life outcomes after surgical correction of pectus excavatum: a comparison of the Ravitch and Nuss procedures. *J Pediatr Surg* 2008;43:819-25.
 72. Jaroszewski DE, Ewais MM, Chao CJ, et al. Success of Minimally Invasive Pectus Excavatum Procedures (Modified Nuss) in Adult Patients (≥ 30 Years). *Ann Thorac Surg* 2016;102:993-1003.
 73. Hebra A, Jacobs JP, Feliz A, et al. Minimally invasive repair of pectus excavatum in adult patients. *Am Surg* 2006;72:837-42.
 74. Park HJ, Jeong JY, Jo WM, et al. Minimally invasive repair of pectus excavatum: a novel morphology-tailored, patient-specific approach. *J Thorac Cardiovasc Surg* 2010;139:379-86.
 75. McMahon LE, Johnson KN, Jaroszewski DE, et al. Experience with FiberWire for pectus bar attachment. *J Pediatr Surg* 2014;49:1259-63.
 76. Pilegaard HK. Nuss technique in pectus excavatum: a mono-institutional experience. *J Thorac Dis* 2015;7:S172-6.
 77. Molik KA, Engum SA, Rescorla FJ, et al. Pectus excavatum repair: experience with standard and minimal invasive techniques. *J Pediatr Surg* 2001;36:324-8.
 78. Park HJ, Lee SY, Lee CS, et al. The Nuss procedure for pectus excavatum: evolution of techniques and early results on 322 patients. *Ann Thorac Surg* 2004;77:289-95.
 79. Jaroszewski DE, Johnson K, McMahon L, et al. Sternal elevation before passing bars: a technique for improving visualization and facilitating minimally invasive pectus excavatum repair in adult patients. *J Thorac Cardiovasc Surg* 2014;147:1093-5.
 80. Notrica DM. Modifications to the Nuss procedure for pectus excavatum repair: A 20-year review. *Semin Pediatr Surg* 2018;27:133-50.
 81. Park HJ, Chung WJ, Lee IS, et al. Mechanism of bar displacement and corresponding bar fixation techniques in minimally invasive repair of pectus excavatum. *J Pediatr Surg* 2008;43:74-8.
 82. Tedde ML, de Campos JR, Wihlm JM, et al. The Nuss procedure made safer: an effective and simple sternal elevation manoeuvre. *Eur J Cardiothorac Surg* 2012;42:890-1.
 83. Takagi S, Oyama T, Tomokazu N, et al. A new sternum elevator reduces severe complications during minimally invasive repair of the pectus excavatum. *Pediatr Surg Int* 2012;28:623-6.
 84. Haecker FM, Sesia SB. Intraoperative use of the vacuum bell for elevating the sternum during the Nuss procedure. *J Laparoendosc Adv Surg Tech A* 2012;22:934-6.
 85. Johnson WR, Fedor D, Singhal S. A novel approach to eliminate cardiac perforation in the nuss procedure. *Ann Thorac Surg* 2013;95:1109-11.
 86. Kim D, Idowu O, Palmer B, et al. Anterior chest wall elevation using a T-fastener suture technique during a Nuss procedure. *Ann Thorac Surg* 2014;98:734-6.
 87. Park HJ, Jeong JY, Kim KT, et al. Hinge reinforcement plate for adult pectus excavatum repair: a novel tool for the prevention of intercostal muscle strip. *Interact Cardiovasc Thorac Surg* 2011;12:687-91.
 88. Park HJ, Kim KS, Lee S, et al. A next-generation pectus excavatum repair technique: new devices make a difference. *Ann Thorac Surg* 2015;99:455-61.
 89. Park HJ, Kim KS, Moon YK, et al. The bridge technique for pectus bar fixation: a method to make the bar unrotatable. *J Pediatr Surg* 2015;50:1320-2.
 90. Pilegaard HK, Licht PB. Routine use of minimally invasive surgery for pectus excavatum in adults. *Ann Thorac Surg* 2008;86:952-6.
 91. Pio L, Carlucci M, Leonelli L, et al. Minimally Invasive Repair of Pectus Excavatum Without Bar Stabilizers Using Endo Close. *J Laparoendosc Adv Surg Tech A* 2016;26:148-52.
 92. Kelly RE, Goretsky MJ, Obermeyer R, et al. Twenty-one years of experience with minimally invasive repair of

- pectus excavatum by the Nuss procedure in 1215 patients. *Ann Surg* 2010;252:1072-81.
93. Yoon YS, Kim HK, Choi YS, et al. A modified Nuss procedure for late adolescent and adult pectus excavatum. *World J Surg* 2010;34:1475-80.
 94. Nuss D. Minimally invasive surgical repair of pectus excavatum. *Semin Pediatr Surg* 2008;17:209-17.
 95. Nagaso T, Miyamoto J, Kokaji K, et al. Double-bar application decreases postoperative pain after the Nuss procedure. *J Thorac Cardiovasc Surg* 2010;140:39-44, 44.e1-2.
 96. Stanfill AB, DiSomma N, Henriques SM, et al. Nuss procedure: decrease in bar movement requiring reoperation with primary placement of two bars. *J Laparoendosc Adv Surg Tech A* 2012;22:412-5.
 97. Li G, Jiang Z, Xiao H, et al. A novel modified Nuss procedure for pectus excavatum: a new steel bar. *Ann Thorac Surg* 2015;99:1788-92.
 98. Park HJ. A technique for complex pectus excavatum repair: the cross-bar technique for grand canyon type deformity (Park classification). *Ann Cardiothorac Surg* 2016;5:526-7.
 99. Sayan B, Bekiroglu N, Yuksel M. Pectus cross bars increase hospital readmission rates due to serous pleural effusion. *Gen Thorac Cardiovasc Surg* 2022;70:352-8.
 100. Wang L, Liu J, Li Y, et al. Modified Nuss operation using introducer-bar complex for pectus excavatum in adults: a retrospective study. *J Cardiothorac Surg* 2021;16:267.
 101. Croitoru DP, Kelly RE Jr, Goretsky MJ, et al. Experience and modification update for the minimally invasive Nuss technique for pectus excavatum repair in 303 patients. *J Pediatr Surg* 2002;37:437-45.
 102. Cheng YL, Lee SC, Huang TW, et al. Efficacy and safety of modified bilateral thoracoscopy-assisted Nuss procedure in adult patients with pectus excavatum. *Eur J Cardiothorac Surg* 2008;34:1057-61.
 103. Ewais MM, Chaparala S, Uhl R, et al. Outcomes in adult pectus excavatum patients undergoing Nuss repair. *Patient Relat Outcome Meas* 2018;9:65-90.
 104. Cheng YL, Lin CT, Wang HB, et al. Pleural effusion complicating after Nuss procedure for pectus excavatum. *Ann Thorac Cardiovasc Surg* 2014;20:6-11.
 105. Cabrera A, Pulivarthi VSKK, Lacky J, et al. Robotic Takedown of Internal Mammary Artery to Prevent Occlusion From Bars During Nuss Pectus Repair. *Ann Thorac Surg* 2020;109:e423-4.
 106. Yüksel M, Özalper MH, Bostanci K, et al. Do Nuss bars compromise the blood flow of the internal mammary arteries? *Interact Cardiovasc Thorac Surg* 2013;17:571-5.
 107. Pilegaard HK. Single centre experience on short bar technique for pectus excavatum. *Ann Cardiothorac Surg* 2016;5:450-5.
 108. Aronson DC, Bosgraaf RP, van der Horst C, et al. Nuss procedure: pediatric surgical solution for adults with pectus excavatum. *World J Surg* 2007;31:26-9; discussion 30.
 109. Kim DH, Hwang JJ, Lee MK, et al. Analysis of the Nuss procedure for pectus excavatum in different age groups. *Ann Thorac Surg* 2005;80:1073-7.
 110. Ong CC, Choo K, Morreau P, et al. The learning curve in learning the curve: a review of Nuss procedure in teenagers. *ANZ J Surg* 2005;75:421-4.
 111. Hebra A, Kelly RE, Ferro MM, et al. Life-threatening complications and mortality of minimally invasive pectus surgery. *J Pediatr Surg* 2018;53:728-32.
 112. Viggiano D, Bongiolatti S, Borgianni S, et al. Nuss Technique for Pectus Excavatum in Adult Patients: Cosmetic Satisfaction and Improvement of Quality of Life in a Single-Center Experience. *Front Surg* 2022;9:903791.
 113. Pilegaard HK. Extending the use of Nuss procedure in patients older than 30 years. *Eur J Cardiothorac Surg* 2011;40:334-7.
 114. Pawlak K, Gaşiorowski Ł, Gabryel P, et al. Early and Late Results of the Nuss Procedure in Surgical Treatment of Pectus Excavatum in Different Age Groups. *Ann Thorac Surg* 2016;102:1711-6.
 115. Erşen E, Demirkaya A, Kılıç B, et al. Minimally invasive repair of pectus excavatum (MIRPE) in adults: is it a proper choice? *Wideochir Inne Tech Maloinwazyjne* 2016;11:98-104.
 116. Sacco Casamassima MG, Gause C, Goldstein SD, et al. Patient Satisfaction After Minimally Invasive Repair of Pectus Excavatum in Adults: Long-Term Results of Nuss Procedure in Adults. *Ann Thorac Surg* 2016;101:1338-45.
 117. Hokschi B, Kocher G, Vollmar P, et al. Nuss procedure for pectus excavatum in adults: long-term results in a prospective observational study. *Eur J Cardiothorac Surg* 2016;50:934-9.
 118. Hanna WC, Ko MA, Blitz M, et al. Thoracoscopic Nuss procedure for young adults with pectus excavatum: excellent midterm results and patient satisfaction. *Ann Thorac Surg* 2013;96:1033-6; discussion 1037-8.
 119. Jaroszewski D, Notrica D, McMahan L, et al. Current management of pectus excavatum: a review and update of therapy and treatment recommendations. *J Am Board Fam Med* 2010;23:230-9.
 120. Jacobsen EB, Thastum M, Jeppesen JH, et al. Health-related quality of life in children and adolescents

- undergoing surgery for pectus excavatum. *Eur J Pediatr Surg* 2010;20:85-91.
121. Krasopoulos G, Dusmet M, Ladas G, et al. Nuss procedure improves the quality of life in young male adults with pectus excavatum deformity. *Eur J Cardiothorac Surg* 2006;29:1-5.
122. Kuru P, Bostanci K, Ermerak NO, et al. Quality of life improves after minimally invasive repair of pectus excavatum. *Asian Cardiovasc Thorac Ann* 2015;23:302-7.
123. Metzelder ML, Kuebler JF, Leonhardt J, et al. Self and parental assessment after minimally invasive repair of pectus excavatum: lasting satisfaction after bar removal. *Ann Thorac Surg* 2007;83:1844-9.
124. Lomholt JJ, Jacobsen EB, Thastum M, et al. A prospective study on quality of life in youths after pectus excavatum correction. *Ann Cardiothorac Surg* 2016;5:456-65.
125. Papic JC, Finnell SM, Howenstein AM, et al. Postoperative opioid analgesic use after Nuss versus Ravitch pectus excavatum repair. *J Pediatr Surg* 2014;49:919-23; discussion 923.
126. Jaroszewski DE, Temkit M, Ewais MM, et al. Randomized trial of epidural vs. subcutaneous catheters for managing pain after modified Nuss in adults. *J Thorac Dis* 2016;8:2102-10.
127. Gebhardt R, Mehran RJ, Soliz J, et al. Epidural versus ON-Q local anesthetic-infiltrating catheter for post-thoracotomy pain control. *J Cardiothorac Vasc Anesth* 2013;27:423-6.
128. Ried M, Schilling C, Potzger T, et al. Prospective, comparative study of the On-Q® PainBuster® postoperative pain relief system and thoracic epidural analgesia after thoracic surgery. *J Cardiothorac Vasc Anesth* 2014;28:973-8.
129. Weber T, Mätzl J, Rokitansky A, et al. Superior postoperative pain relief with thoracic epidural analgesia versus intravenous patient-controlled analgesia after minimally invasive pectus excavatum repair. *J Thorac Cardiovasc Surg* 2007;134:865-70.
130. Futagawa K, Suwa I, Okuda T, et al. Anesthetic management for the minimally invasive Nuss procedure in 21 patients with pectus excavatum. *J Anesth* 2006;20:48-50.
131. Jaroszewski D, Bostoros P, Farina JM et al. Evolution of Pain Control for Adult Pectus Excavatum Repair. *Annals of thoracic surgery*. 2023 (in press - accepted for publication).
132. Graves CE, Moyer J, Zobel MJ, et al. Intraoperative intercostal nerve cryoablation During the Nuss procedure reduces length of stay and opioid requirement: A randomized clinical trial. *J Pediatr Surg* 2019;54:2250-6.

Cite this article as: Aly MR, Farina JM, Botros MM, Jaroszewski DE. Minimally invasive repair of pectus excavatum in adults: a review article of presentation, workup, and surgical treatment. *J Thorac Dis* 2023;15(9):5150-5173. doi: 10.21037/jtd-23-87