

The Value of Restaging With Chest and Abdominal CT/MRI Scan After Neoadjuvant Chemoradiotherapy for Locally Advanced Rectal Cancer

Guo-Chen Liu, MD, Xu Zhang, MD, E. Xie, Xin An, MD, Pei-Qiang Cai, MD, Ying Zhu, MD, Jing-Hua Tang, MD, Ling-Heng Kong, MD, Jun-Zhong Lin, MD, Zhi-Zhong Pan, MD, and Pei-Rong Ding, MD

Abstract: Little was known with regard to the value of preoperative systemic restaging for patients with locally advanced rectal cancer (LARC) treated with neoadjuvant chemoradiotherapy (CRT). This study was designed to evaluate the role of chest and abdominal computed tomography (CT) scan or magnetic resonance imaging (MRI) on preoperative restaging in LARC after neoadjuvant CRT and to assess the impact on treatment strategy.

Between January 2007 and April 2013, 386 newly diagnosed consecutive patients with LARC who underwent neoadjuvant CRT and received restaging with chest and abdominal CT/MRI scan were included. Imaging results before and after CRT were analyzed.

Twelve patients (3.1%) (6 liver lesions, 2 peritoneal lesions, 2 distant lymph node lesions, 1 lung lesions, 1 liver and lung lesions) were diagnosed as suspicious metastases on the restaging scan after radiotherapy. Seven patients (1.8%) were confirmed as metastases by pathology or long-term follow-up. The treatment strategy was changed in 5 of the 12 patients as a result of restaging CT/MRI findings. Another 10 patients (2.6%) who present with normal restaging imaging findings were diagnosed as metastases intra-operatively. The sensitivity, specificity accuracy, negative predictive value, and positive predictive values of restaging CT/MRI was 41.4%, 98.6%, 58.3%, and 97.3%, respectively.

The low incidence of metastases and minimal consequences for the treatment plan question the clinical value of routine restaging of chest and abdomen after neoadjuvant CRT. Based on this study, a routine restaging CT/MRI of chest and abdomen in patients with rectal cancer after

neoadjuvant CRT is not advocated, carcino-embryonic antigen (CEA)-guided CT/MRI restaging might be an alternative.

(*Medicine* 94(47):e2074)

Abbreviations: CEA = carcino-embryonic antigen, CRT = chemoradiotherapy, CT = computed tomography, FDG-PET = ¹⁸F-fluorodeoxyglucose positron emission tomography, IQR = interquartile range, LAR = low anterior resection, LARC = locally advanced rectal cancer, MRI = magnetic resonance imaging, RFA = radiofrequency ablation.

INTRODUCTION

Although neoadjuvant chemoradiotherapy (CRT) significantly reduces the risk of local recurrence in locally advanced rectal cancer (LARC), the risk of distant metastases has not been effectively controlled. As a result, systemic recurrence remains the predominant pattern of treatment failure.

One of the concerns of long course CRT (~3 months) is the risk of tumor progress during treatment, which might have an impact on the strategy of treatment. For example, resectable metastases, if detected before surgery, could be salvaged in time. On the other hand, unresectable metastases, if detected before surgery, might preclude patients from unnecessary surgery.

Phase III clinical trials on neoadjuvant CRT demonstrate that the incidence of intraoperative metastases is 1.0% to 4.2%, supporting the concern of disease progress during neoadjuvant treatment.^{1–3} However, whether metastases is limited to this subset of patients and whether this subset of patients could be detected by preoperative restaging remain unknown.

Up to date, there was few studies evaluating the value of systemic restaging with chest and abdominal CT/MRI scan after CRT.⁴ Furthermore, the data was mixed with metastatic patients and both the patients and the treatment strategies were heterogeneous, which make the results difficult to interpret. The aim of the present study was to evaluate the value of systemic restaging in a pure population of LARC treated with neoadjuvant CRT.

PATIENTS AND METHODS

Data Source

The hospital information system and the colorectal surgery database were searched to obtain the following information: age, gender, radiation time and dose, simultaneous chemotherapy, CEA levels, pathological staging, type of surgery, and histopathological characteristics, outcome, and follow-up. For analysis of pre- and postradiotherapy imaging results and we reviewed all the CT images and reports on a picture archiving and communication system (PACS).

Editor: Patrick Wall.

Received: February 3, 2015; revised: October 16, 2015; accepted: October 23, 2015.

From the State Key Laboratory of Oncology in South China; Collaborative Innovation Center for Cancer Medicine (G-CL, XZ, EX, XA, P-QC, YZ, J-HT, L-HK, J-ZL, Z-ZP, P-RD); Departments of Colorectal Surgery, Sun Yat-sen University Cancer Center (G-CL, YZ, J-HT, L-HK, J-ZL, Z-ZP, P-RD); Departments of Thoracic Surgery, Sun Yat-sen University Cancer Center (XZ); Departments of Medical Oncology, Sun Yat-sen University Cancer Center (XA); Departments of Medical Imaging & Interventional Radiology, Sun Yat-sen University Cancer Center, Guangzhou, P. R. China (P-QC); and Departments of Gastrointestinal Surgery, Shantou Central Hospital, Shantou, P. R. China (EX).

Correspondence: Pei-Rong Ding and Zhi-Zhong Pan, Cancer Center, Sun Yat-sen University, Guangzhou, Guangdong, China (e-mail: dingpr@mail.sysu.edu.cn).

G-CL, XZ, EX, and XA equally contributed to this study.

Z-ZP and P-RD equally contributed to this study.

Funding: this work was supported by Nature Science Foundation of China (Grant number: 81101591).

The authors have no conflicts of interest to disclose.

Copyright © 2015 Wolters Kluwer Health, Inc. All rights reserved.

This is an open access article distributed under the terms of the Creative Commons Attribution-NonCommercial-ShareAlike 4.0 License, which allows others to remix, tweak, and build upon the work non-commercially, as long as the author is credited and the new creations are licensed under the identical terms.

ISSN: 0025-7974

DOI: 10.1097/MD.0000000000002074

Study Design

We retrospectively collected pre- and postradiotherapy imaging results, surgery, and follow-up findings of patients with LARC. To evaluate the sensitivity, specificity, and impact on treatment strategies of systemic restaging after neoadjuvant CRT, a cost benefit study was carried out to assess direct costs and benefits.

Setting and Participants

Between January 2007 and April 2013, 414 newly diagnosed patients with histologically confirmed LARC (cT3–4 or cN+ by endorectal ultrasonography, and/or MRI) who underwent neoadjuvant CRT at our cancer center were included. We excluded 20 patients with metastasis, suspicious metastasis, or indeterminate lesions before neoadjuvant therapy; and 8 patients who did not receive restaging with chest and abdominal computed tomography (CT) or magnetic resonance imaging (MRI). Data including age, gender, radiation time and dose, simultaneous chemotherapy, pre- and postradiotherapy imaging results and CEA levels, pathological staging, type of surgery, and histopathological characteristics, outcome, and follow-up were queried from colorectal surgery database.

MRI and/or endorectal ultrasound was used for local staging before and after radiotherapy. Restaging of chest and abdomen is performed ~5 weeks after radiotherapy with a chest CT and an abdominal and pelvic CT or MRI. Whenever there was any doubt, the case would be presented to a multidisciplinary team that consisted of colorectal surgeons, hepatobiliary surgeons, radiation oncologists, and radiologists.

Patients were treated with a long course of CRT. The total dosage was 46 Gy consisted of 23 fractions of 2 Gy to clinical target volume without a boost dose before 2012, and with the boost 4 Gy consisted of 2 fractions of 2 Gy to gross tumor volume as the total dosage was 50 Gy from 2012. Chemotherapy was delivered concomitant to radiotherapy with the modified XELOX regimen (Oxaliplatin 100 mg/m² d1, d22, Capecitabine 1000 mg/m² bid, d1–14, d22–35). Patients received surgery 6 to 10 weeks after completion of radiotherapy.

CT/MRI Imaging Protocol

CT

All the included patients underwent nonenhanced and enhanced CT scan at the same time. Using a BrillianceTM16 (Philips Medical Systems, Best, The Netherlands) helical scanner, CT imaging was carried out with the following parameters: 5 mm slice thickness, 120 kV voltage, 200 mA current, and 256 × 256 matrix. An intravenous bolus dose of 100 mL of a nonionic iodinated contrast agent (iopromide; Ultravist; Schering) was administered at a rate of 2.5 mL/s for the patients after nonenhanced CT imaging. Enhanced CT images were acquired at 60 s following the contrast agent injection. (Detailed in our colleagues' previous work.⁵)

MR Imaging

All the patients underwent MRI of the liver with a 3.0 T system (Trio Tim; Siemens Medical Systems, Germany) using an 8-channel torso matrix coil and an eightchannel spine coil array. The abdominal MRI protocol included unenhanced axial and coronal T1-weighted sequences; axial T2-weighted sequences; and contrast-enhanced axial and coronal T1-weighted sequences. The sequence parameters for these sequences were as follows: T1-weighted flash transversal sequence (TR/TE, 140/2.5 ms;

slice thickness, 5.0 mm with a 20% interslice gap; FOV, 328 × 420 mm; matrix scan, 225 × 320) and T2-weighted turbo-spin echo sequence (TR/TE, 3,000/96 ms; slice thickness, 5.0 mm with a 20% interslice gap; FOV, 315 × 420 mm; matrix scan, 225 × 320). An intravenous dose of 0.1 mmol/kg of contrast agent (Gadolinium-DTPA, magnevist; Schering) at a speed of 3 mL/s had been administered to the patients undergoing contrast-enhanced MR scanning.

Cost Benefit Analysis

We conducted a cost-benefit study to assess the costs and benefits of the process to restage LARC patients with CT/MRI.⁶ For patients who eventually avoided resections because of metastasis diagnosed by CT/MRI, we presumed that the saved expenses were attributed by CT/MRI. Direct cost of restaging with CT/MRI and operation spend were included in cost analysis. Cost data from our accounting department reflected the actual charge, including inpatient and outpatient costs, such as costs of the surgery, ICU, complications (eg anastomotic leakage, wound infection, and intestinal obstruction), diagnostic tests and medicines. Spend of palliative or adjuvant chemotherapy was not included due to limited follow-up at the time of analysis. Cost are expressed in US dollars.

Statistical Analysis

SPSS statistical software (SPSS Inc., Chicago, IL, version 15) were used for data analysis. Continuous variables were presented as means with standard deviations or medians with ranges, categorical variables were demonstrated as frequencies (percentages), and descriptive statistics were illustrated as median or interquartile range (IQR).

ETHICS

The study was performed following approval by the ethic committee of Sun Yat-sen University Cancer Center. The process of the whole study is noninvasive, and without any patients' benefits hurt. Each patient has signed the informed consent form for their clinical records to be used in this study before neoadjuvant CRT. Ethics committees approved this consent procedure. All the patients' information was anonymized and de-identified prior to analysis.

RESULTS

Clinicopathological Characteristics

The median time between the first staging scan and the start of radiotherapy was 4 weeks (IQR 3–5). The time between end of radiotherapy and the restaging scan was 5 weeks (IQR 4–6). The median time between the 2 scans was 14 weeks (IQR 12–17). The median time between the end of radiotherapy and surgery was 7.5 weeks (IQR 6.5–8.5). (Figure 1).

The 386 patients who underwent neoadjuvant CRT were included between January 2007 and April 2013. Clinicopathological features of the patients included in this study are summarized in Table 1. All the patients received a chest CT scan, an abdominal and pelvic CT/MRI before and after CRT.

Imaging Findings

Twelve patients (3.1%) had newly emerging lesions on the restaging scan after radiotherapy, 7 of whom were diagnosed as metastasizes by CT/MRI and confirmed by pathology or follow-up later (1 peritoneal carcinomatosis, 4 liver metastases, 1 liver and

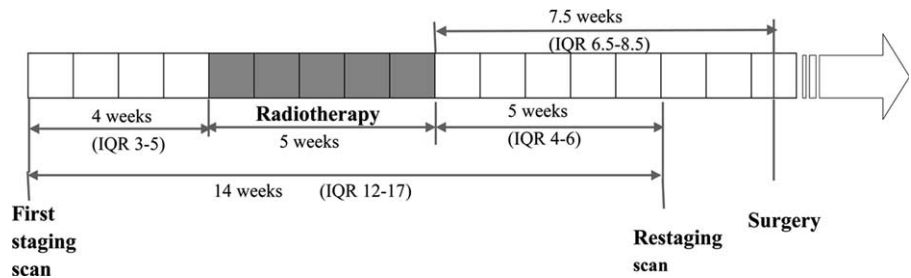


FIGURE 1. Timeline.

lung metastasis, and 1 supraclavicular lymph node metastasis). The treatment strategies were adjusted accordingly in 5 patients, among whom laparotomy was avoided in 3 patients and synchronous metastasectomy was performed in another 2 patients. Treatment strategies were not changed in the rest 7 patients (Figure 2). One patient with suspicious liver metastasis received laparotomy and found that the primary tumor was unresectable. One patient with undetermined supraclavicular lymph nodes underwent resection of primary tumor. The supraclavicular lymph nodes were confirmed as metastases by follow-up.

Five patients who were diagnosed as distant metastases were not confirmed by surgery or long-term follow-up. Among

the 5 patients, 1 with suspicious liver metastasis underwent surgery of rectal cancer followed by chemotherapy. The liver lesion enlarged at the re-evaluation scan and then received hepatectomy. The final pathology was confirmed as primary hepatocellular carcinoma. All the 5 patients are alive with no evidence of disease (Table 2).

Surgical Findings

Ten patients were diagnosed as metastases intra-operatively (5 peritoneal metastasis, 2 peritoneal and ovary metastasis, 2 liver metastasis, 1 retroperitoneal lymph node metastasis), all of whom failed to be detected by restaging CT/MRI. The treatment strategies were adjusted in all the patients accordingly (Table 3).

TABLE 1. Demographic and Clinicopathologic Characteristics

Variable*	
Total no. of patients	386
Gender, no. (%)	
Male	267 (69.2)
Female	119 (30.8)
Median age at diagnosis (range)	56 (15~84)
Distance to anal verge – no. (%)	
0–5 cm	225 (58.3)
6–10 cm	153 (39.6)
>10 cm	8 (2.1)
Clinical tumor staging – no. (%)#	
T3N0	227 (58.8)
T4N0	64 (16.6)
TxN1–2	95 (24.6)
Tumor differentiation – no. (%)	
Well differentiated	48 (12.4)
Moderately differentiated	255 (66.1)
Poorly differentiated	66 (17.1)
Not stated	17 (4.4)
Pathology	
ypT stage no. (%)	
0	80 (21.7)
1–2	117 (31.7)
3	99 (26.8)
4	73 (19.8)
ypN stage no. (%)	
0	276 (74.8)
1–2	93 (25.2)

* Percentages may not sum to 100 because of rounding.
Local tumor staging was determined by endorectal ultrasonograph or MRI.

Treatment and Outcome for Patients With Metastases

Among the 7 patients diagnosed as metastases by restaging CT/MRI and confirmed by surgery or follow-up, 5 patients received palliative chemotherapy with or without palliative surgery and died of disease progress. Two patients received low anterior resection (LAR) and liver resection with or without percutaneous radiofrequency ablation (RFA) for liver metastasis with curative intent; till the latest follow-up (5 and 12 months after surgery), they were alive with no evidence of disease. The median overall survival of the 7 patients confirmed as metastases from rectal cancer is 14 months.

For the 10 patients with metastasis detected intra-operatively, 2 patients with liver metastasis received LAR and liver resection with curative intent, 1 of whom died of cancer progress with an overall survival of 13 months, whereas the other was still alive with no evidence of disease till the last follow-up. The other 8 patients received palliative surgery and chemotherapy. Till the last follow-up, 6 of them died of cancer progress, and 2 were still alive with the disease. The median overall survival time of the 10 patients were 15.5 months (Table 3).

Cost Benefit Analysis

The median length of hospital stay was 12 days (range, 9–25 days). The cost analysis of operations for LARC at our hospital indicated mean costs of \$2881 (range, \$981–\$8981) per case; thus each day on the floor accounted for \$473 (range, \$191–\$1375). Costs of chest and abdominal CT amounted to \$326 (\$109 for chest CT, \$217 for abdominal CT), whereas the charge of chest CT and abdominal MRI is \$509 (\$109 for chest CT, \$400 for abdominal MRI). In the light of our series of 386 patients with LARC, 3 patients avoided surgery because of metastasis diagnosed by CT/MRI, \$25671 could be saved by

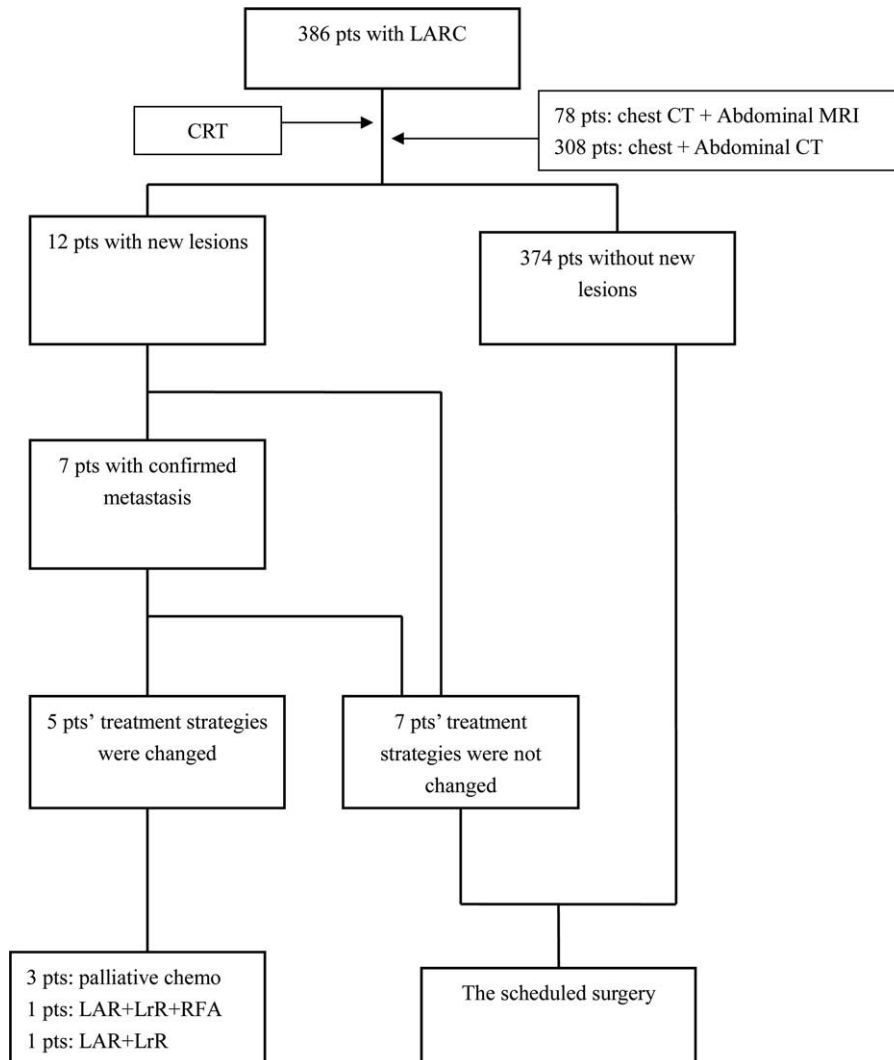


FIGURE 2. The treatment process. CRT=chemoradiotherapy, LAR=low anterior resection, LrR=liver resection, pts=patients, RFA=radiofrequency ablation.

TABLE 2. Details of Patients Diagnosed as Metastases by CT/MRI After Chemoradiation

No	Image Before CRT	Image After CRT	Confirmed by Surgery or F/U	Adjustment of Treatment	Time and Result of F/U	Treatment	OS (months)
1	Ascites, small volume	Ascites, peritoneal carcinomatosis	Yes	Yes	DOD	Palliative chemo	14
2	Neg.	LrM + LnM	Yes	Yes	DOD	Palliative chemo	16
3	Neg.	LrM	Yes	Yes	DOD	Palliative chemo	8
4	Liver nodule, not reported	LrM	Yes	Yes	NED	LAR + liver resection	12
5	Neg.	LrM	Yes	Yes	NED	LAR + liver resection + RFA	5
6	Neg.	Suspicious of LrM	Yes	No	DOD	Laparotomy+ chemo	22
7	Neg.	Supraclavicular LNM	Yes	No	DOD	LAR+palliative chemo	27
8	Neg.	Suspicious of LrM	No, HCC	No	NED	LAR, liver resection later	>60
9	Neg.	Suspicious of LrM	No	No	5 yr, NED	LAR	>60
10	Neg.	Suspicious of pelvis metastasis	No	No	5 yr, NED	LAR	>60
11	Neg.	Suspicious of adrenal and inguinal LNM	No	No	2 yr, NED	LAR	24
12	Neg.	New lung nodule	No	No	5 yr, NED	APR	36

DOD = die of disease, F/U = follow up, HCC = hepatic cell carcinoma, LAR = low anterior resection, LnM = lung metastasis, LNM = lymph node metastasis, LrM = liver metastasis, NED = no evidence of disease, Neg = negative.

TABLE 3. Details of Patients Diagnosed as Metastases Intra-Operatively But Not Detected by Restaging CT/MRI Before Surgery

No.	Image Before CRT	Image After CRT	Site of Metastasis	Adjustment of Treatment	Treatment	Outcome at Last Surveillance	OS (Months)
1	Neg.	Neg.	Retroperitoneal LNM	Yes	Palliative surgery and chemo	AWD	18
2	Neg.	Neg.	Peritoneal metastasis	Yes	Palliative surgery and chemo	AWD	10
3	Neg.	Neg.	Peritoneal metastasis	Yes	Palliative surgery and chemo	DOD	12
4	Neg.	Neg.	LrM	Yes	LAR+liver resection	NED	25
5	Neg.	Neg.	Peritoneal & ovary metastasis	Yes	Palliative surgery and chemo	AWD	21
6	Neg.	Neg.	Peritoneal & ovary metastasis	Yes	Palliative surgery and chemo	DOD	46
7	Neg.	Neg.	Peritoneal (omentum) metastasis	Yes	Palliative surgery and chemo	DOD	13
8	Neg.	Neg.	Peritoneal metastasis	Yes	Palliative surgery and chemo	DOD	10
9	Neg.	Neg.	LrM	Yes	LAR+liver resection	DOD	13
10	Neg.	Neg.	Peritoneal metastasis	Yes	Palliative surgery and chemo	DOD	19

AWD=alive with disease, Chemo=chemotherapy, DOD=die of disease, LNM=lymph node metastasis, LrM=liver metastasis, NED=no evidence of disease, Neg=negative.

preventing 3 resections. Total cost of CT/MRI for all 386 patients amounted to \$140110. The amount of \$114439 was finally wasted by the additional use of CT/MRI, which accounts for \$296 per patient. The savings-to-cost ratio is 0.18 for restaging with chest and abdominal CT/MRI scan after neoadjuvant CRT (Table 4).

CEA and Imaging Results

Twenty patients had abnormal and elevated (compared to the CEA levels before CRT) CEA levels, 11 of them (5 liver metastases, 1 supraclavicular lymph node metastasis, 4 peritoneal metastasis, 1 peritoneal and ovary metastasis) were confirmed by pathology or follow-up later. The sensitivity, specificity accuracy, negative predictive value, positive predictive values, and Youden index of CEA and CT/MRI were (64.7%, 41.1%), (97.5%, 98.6%), (55%, 58.3%), (98.3%, 97.3%), (0.622, 0.397), respectively (Table 5). Although not statistically significant, CEA was more sensitive in detecting metastasis ($P=0.516$), but with lower specificity accuracy compared to CT/MRI ($P=0.117$).

DISCUSSION

One of the concerns of long course CRT (~3 months) is the risk of tumor progress during treatment, as the current regimens of CRT function mainly on local but not systemic control. Restaging patients with LARC after neoadjuvant CRT has the potential advantage of early detection of metastases and altering treatment strategies.

The clinical value of systemic restaging after CRT is highly dependent on the consequences of the treatment strategy

when there are additional diagnostic findings by restaging. In the present study, a relatively low incidence (3.1%) of metastases was found after CRT. Only 7 patients were finally confirmed as metastases by surgery of long-term follow-up, among whom only 5 patients' treatment strategies were changed. Moreover, the restaging CT/MRI is not sensitive enough to detect peritoneal metastases or metastases of small size. Ten patients (2.6%) with peritoneal metastases or small metastases failed to be detected by restaging CT/MRI. The low yield and false negative of restaging strategy question the value of systemic restaging after neoadjuvant CRT.

Also, restaging strategies were found to be not cost-effective in 1 study. In our series of 386 patients with LARC, the savings-to-cost ratio was only 0.18, the saving of excluding patients from resection because of detection of metastasis does not come up to the cost of restaging CT/MRI of chest and abdomen. The changes of the 5 patients' treatment strategies did not result in reduction of treatment cost. Neither shortening the length of hospital stay nor the avoidance of surgery reversed the cost-effectiveness, indicating the limited value of restaging CT/MRI.

Abnormal and elevated (compared to the CEA levels before CRT) CEA level was not enough to change treatment strategy. However, the CEA-guided CT/MRI restaging seems to be promising. If restaging was applied to patients with abnormal and elevated CEA levels, 366 patients would avoid unnecessary CT/MRI test, although 2 patients would be missed.

Of note, the prognosis of patients developing metastases during CRT is poor. The median overall survival of the 7 patients with metastasis detected by restaging CT/MRI is only 14 months. This is probably due to the bad tumor biology. As

TABLE 4. Cost Savings Associated With Use of CT/MRI

	Chest and Abdominal CT	Chest CT and Abdominal MRI	Total
Number of patients	308	78	386
Cost of procedures avoided	\$17114	\$8557	\$25671
Cost of CT/MRI	\$100408	\$39702	\$140110
Savings/cost ratio	0.17	0.22	0.18

CT=computed tomography, MRT=magnetic resonance imaging.

TABLE 5. CEA and Restaging CT/MRI Findings**(A) For all patients**

Metastasis	CEA		CT/MRI		Total
	+ [‡]	— [§]	+	— [¶]	
+ [*]	11	6	7	10	386
— [†]	9	360	5	364	
Total	20	366	12	374	

(B) For the 17 patients with metastasis

CT/MRI	CEA		Total
	+ [‡]	— [§]	
+	5	2	7
— [¶]	6	4	10
Total	11	6	17

(C) For the 369 patients without metastasis

CT/MRI	CEA		Total
	+ [‡]	— [§]	
+	1	4	5
— [¶]	8	356	364
Total	9	360	369

CEA = carcino-embryonic antigen, CT = computed tomography, MRT = magnetic resonance imaging.

* Patients with metastasis confirmed by pathology or follow-up later.

† Patients without metastasis.

‡ Patients with abnormal and elevated CEA levels.

§ Patients with normal or descending CEA levels.

|| Patients with newly emerging lesions detected by restaging CT/MRI.

¶ Patients with normal restaging CT/MRI.

demonstrated in the previous study, tumor progress while on chemotherapy is associated with poor prognosis and represents a contraindication to surgery. The 5-year overall survival in liver resection for multiple colorectal metastases is only 8% in patients who progress during chemotherapy compared to 37% in those whose diseases are controlled by chemotherapy.⁷ Furthermore, patients who develop early recurrence after adjuvant chemotherapy is also linked with poor prognosis. Although early surveillance might detect the recurrences, the long-term outcome was not improved.⁸ The poor prognosis in patients developing metastases during CRT also questions the value of systemic restaging after neoadjuvant CRT.

The current study detects a far lower incidence of metastases in systemic restaging CT/MRI than the previous report.⁵ The discrepancy probably due to the following facts. First, the study includes patients with metastasis or indeterminate lesions before neoadjuvant treatment. As the rate of progressive disease in metastatic colorectal cancer treated with fluoropyrimidine alone is as high as 16.2% to 55.3%,^{9–11} the inappropriate inclusion of metastasis or indeterminate lesions would inevitably result in more restaging findings. Second, the regimens of neoadjuvant treatment are quite heterogeneous. Some patients received CRT, whereas others received radiotherapy only. As radiotherapy is less effective in systemic control, the risk of distant metastases is much higher. As a result, the conclusion of restaging in patients treated with radiotherapy might not be suitable for patients treated with CRT. Third, the time span of the study is as long as 11 years (between January 2000 and

December 2010), and above all, it is not a consecutive series which might be subject to the selection bias. Finally, about one-fourth of patients received a chest x-ray before CRT, while received a chest CT scan after CRT. As is widely accepted that chest x-ray is far less sensitive for the diagnosis of pulmonary metastases compared to chest CT, the inconsistency in the diagnostic methods might also result in more restaging findings.¹²

Unlike colon cancer, LARC has a higher risk of developing lung metastases instead of liver metastases.^{13–16} However, in the present study and Ninos Ayez's study, liver metastases was the majority. There are several possible reasons for this. First of all, definite pulmonary metastasis usually requires consecutive imagings because metastases are often too small to be determined initially. Therefore, the time span from detection to confirmation of lung metastasis is longer than it is for extrapulmonary relapse.¹⁷ Furthermore, CEA, with reported sensitivity of >80% in hepatic metastasis,¹⁸ is of little value in determining pulmonary metastasis (with reported sensitivity of 15%).¹³ Therefore, pulmonary metastases may have been missed by screening with CEA. The recurrence patterns of LARC also question the value of systemic restaging in a short interval.

Besides CT/MRI, there are also several other imaging techniques which might serve for restaging. As a technique based on metabolic changes instead of anatomical and structural changes, ¹⁸F-urideoxyglucose positron emission tomography (FDG-PET) has the potential to show tumor activity ahead of CT or MRI.¹⁹ Previous studies have shown that PET is more sensitive than CT for recurrence.^{20,21} However, at present there

is no defined role for routine FDG-PET in the preoperative evaluation of nonmetastatic rectal cancer after neoadjuvant CRT. Ruby et al found assessment of rectal cancer response to neoadjuvant CRT by FDG-PET provides no prognostic information.²² Meanwhile, a systematic review conducted by Brush et al concluded that FDG PET/CT is cost-effective in the pre-operative staging of recurrent rectal and metastatic disease but not in primary rectal cancers.²³ Ultrasonography might also be used for restaging. In the current cohort, most of the confirmed metastases locating in liver and might be detected by ultrasonography. As ultrasonography is less expensive and with less radiation exposure, it would be more reasonable to use ultrasonography as a method of restaging if restaging strategy is considered.

Restaging with CT/MRI may cause a prolonged period of uncertainty, unnecessary anxiety for patients and families, possibly delaying surgical treatment, and moreover, summative radiation exposure and costs. Cumulative CT radiation exposure added incrementally to baseline cancer risk. In a study by Aaron Sodickson, CT exposures were estimated to produce 0.7% of total expected baseline cancer incidence and 1% of total cancer mortality.²⁴

We are aware, however, of some other limitations in this study. First, this study was performed in a single-institution retrospective manner. Second, this is not a randomized control trial, which make the result not so strong. However, since the incidence of metastases is very low, the number of patients required for a randomized clinical trial would be very large. As a result, the design of such a trial is not practical. In addition, we are aware that not restaging all patients may harm a few, for example, patients with indeterminate lesions. It would be desirable to have some clinical features (such as T stage, N stage, CEA value, the time span between CRT and surgery) that could potentially help us identify patients with high risk of progress after CRT.

In summary, the present study shows a limited clinical value of a routine preoperative restaging of chest and abdomen with CT/MR in patients with LARC after neoadjuvant CRT because of the low incidence and false negative. According to our results, routine restaging with chest and abdominal CT/MRI should not be proposed for patients after neoadjuvant CRT. Alternative restaging strategies such as CEA-guided restaging need to be explored.

ACKNOWLEDGMENTS

We acknowledge Jumping Yan for her input on statistical analysis.

REFERENCES

- Bosset JF, Collette L, Calais G, et al. Chemotherapy with preoperative radiotherapy in rectal cancer. *N Engl J Med*. 2006;355:1114–1123.
- Gerard JP, Azria D, Gourgou-Bourgade S, et al. Comparison of two neoadjuvant chemoradiotherapy regimens for locally advanced rectal cancer: results of the phase III trial ACCORD 12/0405-Prodige 2. *J Clin Oncol*. 2010;28:1638–1644.
- Marsh PJ, James RD, Schofield PF. Adjuvant preoperative radiotherapy for locally advanced rectal carcinoma. Results of a prospective, randomized trial. *Dis Colon Rectum*. 1994;37:1205–1214.
- Tian L, Liu LZ, Cui CY, et al. CT findings of primary non-teratoma germ cell tumors of the mediastinum—a report of 15 cases. *Eur J Radiol*. 2012;81:1057–1061.
- Ayez N, Alberda WJ, Burger JW, et al. Is restaging with chest and abdominal CT scan after neoadjuvant chemoradiotherapy for locally advanced rectal cancer necessary? *Ann Surg Oncol*. 2013;20:155–160.
- Siegel JE, Weinstein MC, Russell LB, et al. Recommendations for reporting cost-effectiveness analyses. Panel on cost-effectiveness in health and medicine. *JAMA*. 1996;276:1339–1341.
- Adam R, Pascal G, Castaing D, et al. Tumor progression while on chemotherapy: a contraindication to liver resection for multiple colorectal metastases? *Ann Surg*. 2004;240:1052–1061 discussion 1061–1054.
- Liu GC, Tang JH, Wen SJ, et al. Is early surveillance with CT scan necessary in patients with stage II/III colorectal cancer: a retrospective study. *J Surg Oncol*. 2013;108:568–571.
- de Gramont A, Figuer A, Seymour M, et al. Leucovorin and fluorouracil with or without oxaliplatin as first-line treatment in advanced colorectal cancer. *J Clin Oncol*. 2000;18:2938–2947.
- Hanna CL, McKinna FE, Williams LB, et al. High-dose folinic acid and 5-fluorouracil bolus and continuous infusion in advanced colorectal cancer: poor response rate in unselected patients. *Br J Cancer*. 1995;72:774–776.
- Hoff PM, Ansari R, Batist G, et al. Comparison of oral capecitabine versus intravenous fluorouracil plus leucovorin as first-line treatment in 605 patients with metastatic colorectal cancer: results of a randomized phase III study. *J Clin Oncol*. 2001;19:2282–2292.
- Engstrom PF, Arnoletti JP, Benson AB, et al. NCCN Clinical Practice Guidelines in Oncology: colon cancer. *J National Comprehensive Cancer Network*. 2009;7:778–8313rd.
- Ding P, Liska D, Tang P, et al. Pulmonary recurrence predominates after combined modality therapy for rectal cancer: an original retrospective study. *Ann Surg*. 2012;256:111–116.
- Kao PS, Chang SC, Wang LW, et al. The impact of preoperative chemoradiotherapy on advanced low rectal cancer. *J Surg Oncol*. 2010;102:771–777.
- Mitry E, Fields AL, Bleiberg H, et al. Adjuvant chemotherapy after potentially curative resection of metastases from colorectal cancer: a pooled analysis of two randomized trials. *J Clin Oncol*. 2008;26:4906–4911.
- Tjandra JJ, Kilkenny JW, Buie WD, et al. Practice parameters for the management of rectal cancer (revised). *Dis Colon Rectum*. 2005;48:411–423.
- MacMahon H, Austin JH, Gamsu G, et al. Guidelines for management of small pulmonary nodules detected on CT scans: a statement from the Fleischner Society. *Radiology*. 2005;237:395–400.
- McCall JL, Black RB, Rich CA, et al. The value of serum carcinoembryonic antigen in predicting recurrent disease following curative resection of colorectal cancer. *Dis Colon Rectum*. 1994;37:875–881.
- Langenhoff BS, Oyen WJ, Jager GJ, et al. Efficacy of fluorine-18-deoxyglucose positron emission tomography in detecting tumor recurrence after local ablative therapy for liver metastases: a prospective study. *J Clin Oncol*. 2002;20:4453–4458.
- Huebner RH, Park KC, Shepherd JE, et al. A meta-analysis of the literature for whole-body FDG PET detection of recurrent colorectal cancer. *Journal of nuclear medicine: official publication. Soc Nucl Med*. 2000;41:1177–1189.
- Valk PE, Abella-Columa E, Haseman MK, et al. Whole-body PET imaging with [18F]fluorodeoxyglucose in management of recurrent colorectal cancer. *Arch Surg*. 1999;134:503–511 discussion.

22. Ruby JA, Leibold T, Akhurst TJ, et al. FDG-PET assessment of rectal cancer response to neoadjuvant chemoradiotherapy is not associated with long-term prognosis: a prospective evaluation. *Dis Colon Rectum*. 2012;554:378–386.
23. Brush J, Boyd K, Chappell F, et al. The value of FDG positron emission tomography/computerised tomography (PET/CT) in pre-operative staging of colorectal cancer: a systematic review and economic evaluation. *Health Technol Assess*. 2011;1535: 1–192. iii- iv.
24. Sodickson A, Baeyens PF, Andriole KP, et al. Recurrent CT, cumulative radiation exposure, and associated radiation-induced cancer risks from CT of adults. *Radiology*. 2009;2511:175–184.