



Case Series

Amyand's hernia- outcome of nylon darn repairs after complicated appendix surgeries in a district hospital: case series

Mahamudu Ayamba Ali^{a,*}, Israel Hagbevor^b, Mathew Yamoah Kyei^c, Salifu Nanga^d^a Department of Surgery, School of Medicine, University of Health and Allied Science. Ho, Volta Region, Ghana^b Surgical Unit, Margaret Marquart Catholic Hospital, Kpando, Volta region, Ghana^c Department of Surgery, University of Ghana Medical School, Accra, Ghana^d Department of Basic Science, School of Basic and Biomedical Science, University of Health and Allied Science. Ho - Volta Region, Ghana

ARTICLE INFO

Keywords:

Complicated amyand hernia

Complicated appendix

Nylon darn

Surgical site infection

Appendectomy

Emergency inguinal hernia

ABSTRACT

Introduction: Complicated appendix is a least expected sac content of inguinal hernias that always require appendix surgery and hernia repair. The current recommendations for posterior wall repairs however, continue to attract conflicting views as to which modality gives the best outcome in infected surgical wounds. New posterior wall repair methods with properties to withstand surgical site infections, minimise hernia recurrence, affordable and easy skill to acquire with a potential to be widely adopted are continuously sort.

Aim: To determine the surgical outcomes of complicated Amyand Hernias repaired using the open tissue base Nylon Darn posterior wall re-enforcement method.

Method: A retrospective review of medical records of patients who had surgery for emergency inguinal hernia with intra-operative confirmation of complicated appendix in the hernia sac from January 2015 to December 2020 at the Margaret Marquart Catholic Hospital, Kpando were included. Data on age, sex, clinical presentation, surgical procedure, intra-operative findings, post operative complications were captured and presented as descriptive statistics.

Results: Twelve out of 286(4.6%) repairs were complicated Amyand Hernias in patients aged 6weeks to 76-years {median age 54.5-years}. Most of them were adults, long-standing hernias. All diagnosis were made on-table. Surgical site infections was the most frequent complication in types III and IV AHs which resolved with anti-biotic treatment.

Conclusion: The incidence of complicated AHs is higher and should be anticipated in surgeries for long-standing complicated inguinal hernias. Even though complications were significantly associated with longer hospital stay, no second procedure or mortality was recorded.

1. Introduction

Complicated inguinal hernia is a common pathology for which surgery is frequently carried out base on only clinical diagnosis. The bowel and omentum are the usual expected sac contents. An unexpected normal or pathological appendix, reproductive organs (ovaries and tubes) or bladder may be encountered. An Amyand Hernia (AH) is a term used to describe the presence of an appendix in the sac of an inguinal hernia [1]. In 1735, Cladius Amyand, King George II surgeon reported the presence of a perforated appendix in the sac of an 11-year old boy's hernia [1]. This was an incidental intra-operative finding even though an enterocutaneous fistula had developed prior to presentation. AH is

reported in about 1.0% of inguinal hernias with pathological appendix detected in 0.10–0.13% [1–4]. Most AHs described in current literature are on table diagnosis with few reports of pre-operative imaging and postmortem detections [3–5]. AH is believed to be three-fold higher in children than adults and more prevalent in male as well as right-sided hernias [6–8]. Left-sided AHs are however frequent in individuals with situs inversus, intestinal malrotation, loose redundant caecum and large or long appendices [8].

Complicated AHs often present with an irreducible painful groin swelling which is difficult to differentiate from complicated inguinal hernia clinically [2,8]. Continuous bowel movement in patients with complicated AHs have often led to delayed presentation or diagnosis with

* Corresponding author.

E-mail addresses: aayamba@uhas.edu.gh (M.A. Ali), futagbiisrael@yahoo.com (I. Hagbevor), matkyei@yahoo.com (M.Y. Kyei), snanga@uhas.edu.gh (S. Nanga).<https://doi.org/10.1016/j.amsu.2021.102964>

Received 7 September 2021; Received in revised form 14 October 2021; Accepted 14 October 2021

Available online 16 October 2021

2049-0801/© 2021 The Authors. Published by Elsevier Ltd on behalf of IJS Publishing Group Ltd. This is an open access article under the CC BY-NC-ND license

<http://creativecommons.org/licenses/by-nc-nd/4.0/>.

poorer outcome [8]. The decision to preserve a normal appendix during AH repair is currently personalised. The decisions are partly based on the surgeon's competence to perform appendectomy without complications, future occurrence of appendiceal disease and the usefulness of a preserved appendix for future conduit surgeries. In a diseased appendix (eg. inflamed, perforation, abscess), appendectomy with administration of antibiotics and abscess drainage is a standard treatment to mitigate the potential of developing surgical site infection [2,9,10]. However, the debate on the best way to strengthen the posterior wall continues with conventional open tissue repair method offered widely despite the higher recurrence rates compared to open or laparoscopic mesh repairs. The risk of mesh infection in peritonitis, foecal leakage or bacteria spread and the need for its removal is arguably the major influential factor most surgeons avoid the standard open or laparoscopic mesh repairs [2,9,10]. Surgical site infections occurs in 5.5–50% with related mortality between 5.5% and 30% among repairs in patients with AHs which is feared to be higher in the subset with complicated appendices [2,11,12]. Losanoff JE and Basson MD, 2007 [13] classification scale of identifying AHs and specific treatment recommendations for various categories are currently evolving with large amount of literature on Bassini suture and open mesh repairs [14]. Reports on the outcomes of complicated AHs repaired using nylon darn method remains scant even though in theory, nylon monofilament suture is capable of maintaining a longer tensile strength which is required under infectious conditions. This hernia repair method is also widely used in low resource facilities particularly in Africa [15]. Nylon darn which is an open tension-free woven-mesh re-enforcement of the posterior wall using nylon suture to approximate the conjoint tendon to the inguinal ligament as described by Hagbevor et al., 2021 [15] is affordable and easy to perform. This study apart from exploring the usefulness of nylon darn in an infected surgical wound, will expand our knowledge on the prevalence of complicated AHs in emergency inguinal hernia surgeries complications which to the best of our knowledge have not been reported in any large series.

We present 12 cases of AH in emergency setting, seen and managed in relation to their presentation, surgical findings, and complications.

2. Patients and method

2.1. Study patients selection

This was a retrospective cross-sectional study in which we retrieved and reviewed consecutive records of 286 emergency inguinal hernia repaired at the Margaret Marquart Catholic Hospital (MMCH) between 2015 and 2020. MMCH is a district level hospital at Kpando in the Volta region of Ghana with the 4 main clinical disciplines. Its medical/surgical emergency and surgical units has 12 and 30 beds respectively where all the patients except the baby were attended.

A 2-step criteria was followed to identify records included in this study. All records of admitted emergency inguinal hernia operated were confirmed from both the admission and theatre registers. Complicated AHs were then identified from operation notes and histopathological confirmation.

Emergency cases were defined as inguinal hernias admitted through the emergency unit with any of the following and had surgery within 6-hours:

1. Pains at a swollen inguinal hernia
2. Incarcerated inguinal hernia
3. Intestinal obstruction resulting from irreducible inguinal hernia
4. Peritonitis resulting from inguinal hernia

Complicated Amyand Hernia included any of the following in the hernia sac:

1. An inflamed appendix

2. A perforated appendix
3. A gangrenous appendix
4. Pusy and or organised appendix mass

A total of 12 patients records satisfied the above criteria and were included in our series.

2.1.1. Preoperative treatment/optimisation

All adults and adolescents patients were preoperative given the following: Intravenous fluid (0.9% normal saline or Ringers lactate), Intravenous antibiotics at emergency room and on table (ciprofloxacin 400mg/12-hourly and metronidazole 500mg/8-hourly), analgesia (intramuscular pethidine or intravenous paracetamol) and intranasal oxygen administered. The child received 0.45% dextrose saline and cefuroxime. Nasogastric tube and urethral catheters were passed in all patients. They were no preoperative blood transfusions, intensive care units admissions or the use of inotropic agents.

2.1.2. Investigations

There was no diagnostic imaging for any patient. Blood samples for supportive investigations:-full blood count for haemoglobin levels, white blood cell count and platelets level, Blood urea nitrogen and creatinine level, liver function and proteins level were optimal for surgery. They were counselled and both verbal and written consent obtained either from patients directly or parents in those below 18 years.

2.1.3. Surgery

Six patients had general anaesthesia, intubated and cuffed which included five adults with symptoms of peritonitis and the neonate. The rest had regional anaesthesia (spinal).

All the adults and adolescents patients had nylon darn repairs through the oblique groin incisions made medial to the imaginary line of the inguinal ligament over internal ring. Nylon 2 suture was used for herniorrhaphy after herniotomy. Six patients had appendectomy through the same groin incisions. The neonate also had appendectomy and division of the patent processus vaginalis through the same incision.

Five patients suspected of peritonitis had midline abdominal incisions. Two with healthy bowels had only appendectomies and 3 had bowel resection for associated gangrene or perforation with end to end anastomosis. The resections were 2 large bowel and a small bowel with end to end anastomosis. All surgical procedures were performed by a trained urological surgeon.

2.1.4. Post-operatively

Post-operatively, all patients received intravenous fluid and antibiotic ranging from 24-hours for class II to 72-hours for Class III, IV (Table 1) and adequate analgesia before resumption of oral feeds and commencement of oral antibiotics for 5–7 days. The child received cefuroxime, 0.45% dextrose saline, 100 ml/kg in 24-h and suppository acetaminophen 100mg/8-hourly. Two patients (5 & 12 from Table 1) were administered inotropics (adrenaline in infusion) to maintain blood pressure.

Surgical wounds were exposed between post operative day 2–3. wounds were cleaned with normal saline, dressed and covered with povidone soaked gauze till stitches were removed.

Documentation of the following were sort for as complications post-operatively:

1. Discharging, oedematous wound to be infected wound
2. Swelling of the scrotum to denote scrotal collection
3. Acute retention of urine
4. Wound bleeding
5. Recurrence of swelling
6. Pains at incision site after discharge
7. Fever related to the wound or surgery

Table 1

Demographic characteristics, presentation, treatment, complications and duration of hospital stay in complicated Amyand's hernia repair in MMCH, Kpando.

SN	Age	Sex	duration of hernia	Duration of sympt	Laterality of hernia	Hernia sac content	surgical intervention	Losanoff & Basson class	Duration of hosp. stay	Complications
1	46 y	F	1 year	4 days	RIH	Viable terminal ileum & perforated Appendix in labia majus	Appendectomy Nylon darn	III	32 days	SSI
2	53 y	M	1 year	2 days	RIH	Viable caecum & perforated appendix	Appendectomy nylon darn	III	38 days	SH, SSI and right groin pain
3	26 y	M	5 mon	2 days	RISH	Viable large bowel Inflamed appendix	Appendectomy & Nylon darn	II	5 days	SH
4	6 wks	M	1 day	1 day	RISH	Viable small bowel & Inflamed appendix	Appendectomy & division of PPV	II	4 days	Nil
5	63 y	M	20 years	1 mon	RIH	Gangrenous large bowel And inflamed appendix	Lap. Resection & anastomosis, Nylon Darn	IV	30 day	SSI,SH
6	56 y	M	3 mon	3 days	RISH	Gangrenous caecum & Small bowel, inflamed Appendix	Lap.Resection & anastomosis, Nylon darn	IV	9 days	ileus
7	65 y	M	3 years	3 days	RISH	Viable large and small Bowel, inflamed appendix	Appendectomy & Nylon darn	II	4 days	Nil
8	45 y	M	1 year	1 day	RISH	Viable caecum and Inflamed appendix	Appendectomy & Nylon darn	II	4 das	Nil
9	69 y	M	1 year	21 days	LISH	Viable large bowel, Urinary bladder and Inflamed appendix	Appendectomy & Nylon darn	II	5 days	Nil
10	17 y	M	1 year	4 days	RISH	Gangrenous small bowel Inflamed appendix	Lap. Resection & anastomosis, Nylon darn	IV	4 day	Nil
11	60 y	M	1 year	5 days	RISH	Viable caecum and Inflamed appendix	Appendectomy & Nylon darn	II	3 days	Nil
12	76 y	F	5 years	7 days	LIH	inflamed appendix in Left hernia sac	Appendectomy & Nylon darn	II	8 days	ileus

M – Male, F – Female, y – year, mon – Month, wks – weeks, RIH: Right inguinal hernia, LIH-Left Inguinal Hernia, RISH – right inguinoscrotal hernia, LISH – left inguinoscrotal hernia, SSI – surgical site infection, SH – scrotal haematoma, Obst – obstructed, sympt – symptom. POD6-post operative day 6, PPV-patent processus vaginalis, Lap. Resection & anastomosis-Laparotomy, gangrenous bowel resection with end-to-end anastomosis

2.2. Data extraction

Patients age, gender, clinical presentations, preoperative diagnosis, surgical findings, treatment techniques and postoperative outcome were analysed. Patient information was presented in a table form. Descriptive statistics was employed to describe the features of the data. Descriptive analysis was carried out to summarize the characteristics of the subjects base on tables, frequency distribution tables, percentages, bar charts and stacked bar charts. The non-parametric Kruskal test was carried out to ascertain whether significant difference existed between the categories of pathology identified and average durations of symptoms before hospital admission and hospital stay. The non-parametric Fisher exact test of association was also employed to determine relationships between pathology identified and surgical intervention.

This study is registered as required by the Helsinki declaration 2013 involving data from human participants with unique number Researchregistry7082- www.researchregistry.com [16]. Ethical clearance was obtained from the University for Health and Allied Sciences Ethical Review Committee Ref: UHAS-REC A.417119-20. In addition, permission of the hospital administration was obtained for the study. The reporting of this study was in line with the Proceed criteria by Agha et al., 2020 [17].

3. Results

Of the 286 emergency hernias repaired over the six year period, twelve (4.2%) were complicated Amyand's hernias. Patients age range was between 6weeks and 76 years (median age 54.5-years). The ratios of male to female, right to left-sided AHs and adults to under 18-years were each 5:1. Hernia duration prior to complication varied from congenital (noticed at birth) to 20 years with majority (75%) of the hernias longer than a year.

All patients presented with irreducible groin swelling varying from a day to 30days after onset of symptoms with no significance difference (p-value > 0.05) between various pathologic categories (Table 2). Other clinical symptoms and signs presented also included pain and tender of groin swelling, vomiting, constipation, abdominal distension and generalised malaise. Seven patient had fever with temperatures >37.5 °C, 5 patient dehydrated, 2 patients were hypertensive and 1 case had bilateral inguinal hernias with incisional ventral hernia.

Contents of the hernia sac: In 75% of the patients, the appendix herniated with bowel with 50% (6/12) being large bowel and 25% (3/12) small bowel. Two (2/12) patients had a combination of both large and small bowel and one person had the urinary bladder and large bowel with the appendix. We found 7 inflamed appendices of which 2 were adhered to the caecum. Three appendices were with gangrenous bowel and 2 perforated (Table 2).

All patients had open procedure to remove the appendix and nylon darn repair of the posterior wall through groin incisions. Five patients in addition, had extended midline laparotomy incisions of which 2 had large bowel resections and one had small bowel resections with ileocolic

Table 2

Intra-operative pathology and post-operative outcome in hospital.

AH class	Pathology identified	n	Symptom duration range pre-hospital & (average)/days	SSI	SC	Days of hospital stay & (average)/days
II	Inflamed	7	1-21 (5.7)	nil	1	3 - 8(4.7)
III	Perforated	2	2 - 4 (3)	2	1	30,38(34.0)
IV	Gangrene +	3	3 - 30 (12.3)	1	1	4 - 30(14.3)
<i>P-value:</i>			>0.05	0.015		< 0.05

AH-Amyand Hernia, SSI-Surgical Site Infection, SC-Scrotal Collection, n-number of patients in the category base on Loffner and Banson 2007 classification.

end-to-end anastomosis. In the 7 persons with inflamed appendix, appendectomy and nylon darn repair or division of patent processus vaginalis(neonate) done through the groin incision (Fig. 1). There was no mortality recorded. The post operative hospital stay ranged from 3 days to 38 days with significant difference (P-value < 0.5) between the pathological categories (Table 2).

Patients developed SSI were 25% (3/12) and mainly with perforated and gangrenous pathology (Fig. 2) and 25% (3/12) with none recorded in the class II or inflamed appendices with a significant difference (Table 2). Other complications were scrotal collection 30%(3/10) of the men, paralytic ileus and groin pains (Fig. 2).

4. Discussion

Inguinal hernia with complicated appendicitis remains a rarely reported encounter in surgical practice with an incidence of about 0.07–0.1% [2,4–6,12]. In this series however, the recorded 4.2% in complicated inguinal hernias is among the highest [3–5]. This high incidence may be partly related to the high incidence of complicated hernias which are often long standing (>1 year) in health deprived communities and high mobility from loose redundant caecum which is associated with diet in Africa or guts malformation manifesting in adults [3]. Adults constituted 75%, a finding that supports our believe that emergency obstruction, long standing hernias and diet is associated, contrary to published literature where the pathology is more prevalent in children [6,7,18]. In addition, majority of the patients 91.7% (11/12) were out of the age bracket 12–20 years that are predominantly seen with acute appendicitis [8]. The pathogenesis of acute appendicitis is generally related to luminal obstruction from faecolith and lymphoid hyperplasia [11,18]. However, the compression of the bowel wall, blood vessels and the appendix during intestinal obstruction or strangulation is theorised to traumatise the appendix, causes thrombosis of the appendiceal vessels or stasis of luminal content [19]. This, we believe predisposed majority of our cases to irreversible ischemia and infection since there were no identifiable risk factors to explain the pathogenesis except the presence of obstruction in these hernia cases. The ratio of 5:1 right-side to left AHs is consistent with other studies [8]. we however noticed a late reporting of symptoms with the left complicated AHs in this series (Table 1).

Clinical presentation of appendix pathology is dependant on the type of complication(inflammation, perforation, abscess or mass) and the progression. These inflammatory process are classically different from abdominal viscous protrusion through the anterior abdominal wall

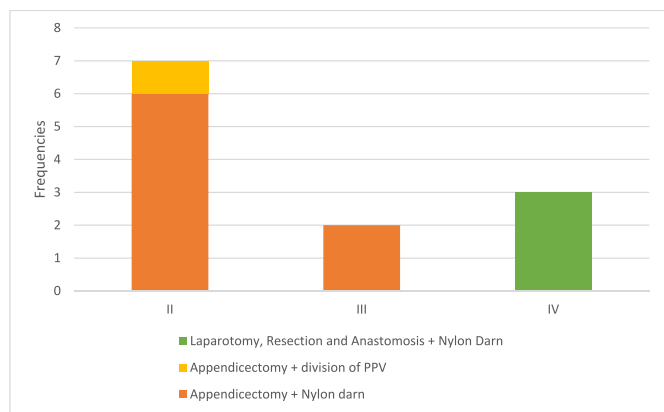


Fig. 1. Surgical procedures for categories of complicated Amyand Hernias. Category II-appendectomy and Nylon darn repair/division of patent processus vaginalis for child. III- Laparotomy + appendectomy + nylon darn. IV- laparotomy + appendectomy + bowel resection and anastomosis + nylon darn.

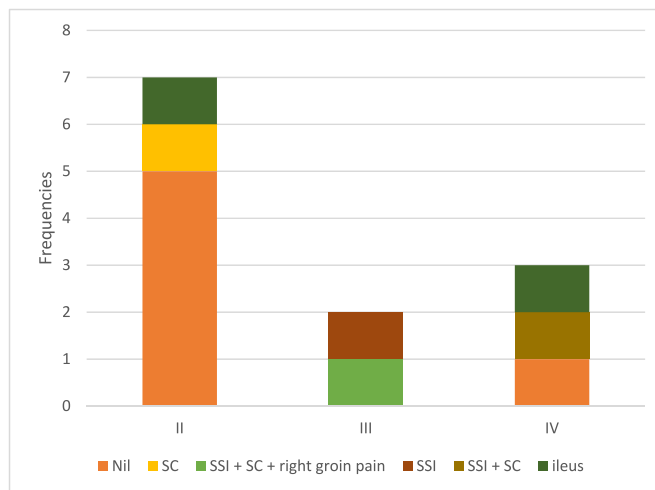


Fig. 2. Complications by categories of complicated appendix following surgery.

which denotes hernia. Common sac contents in hernia are bowel and omentum. However, the urinary bladder, female reproductive organs, Meckel’s diverticulum (Littre’s hernia) and the appendix are occasionally seen [15,19–21]. The protrusion is often prominent to patients and clinicians during physical examination which makes the diagnosis of complicated hernia most likely. In this study, the appendices co-herniated commonly with bowel in 75% of the patients and urinary bladder in one. Diagnosis were made intra-operative which has been the trend in reported cases of complicated AH. Even though the type of appendiceal complication or hernia often pre-determine the incision and treatment modality, surgeon skills in these unexpected cases influences the choice of open repair verse laparoscopic intervention, and mesh verses tissue repair of posterior wall. In this series, appendectomy through groin incision with nylon darn was performed for acute inflammation while lower midline laparotomy incision was performed for suspected perforated or gangrenous bowel based on our skill and hospital set-up. Complications were significantly different in the various intra-operative findings (p-value 0.015) which could influence the choice of mesh for posterior wall repairs (Table 2). The SSI,scrotal collections which were recorded resolved with antibiotics without clinical problems. Although laparoscopic surgical intervention has been reported in some studies with advantages, the practice is not widely used in Africa and other deprived communities [22]. In the classification scale designed by Losanoff JE and Basson MD 2007, to identify and treat AHs, Seven (58.3%) were acute appendicitis(type 2) and had appendectomy of which the six adults had nylon darn repair through groin incision. The type III & IV categories were treated with laparotomy and appendectomy or bowel resection respectively and nylon darn through groin incision. The baby was treated with appendectomy and division of patent processus vaginalis (Fig. 2). These treatment combinations are consistent with the tissue repair proposed with added advantages from the nylon suture used. Surgical site infection was 25%(3/12) compared to recent reports by Cai et al., 2018 [23], however patients responded satisfactorily with antibiotics. There was no recurrence immediate or 1-year average follow-up which could be considered a better benchmark for good repair. None of the complicated cases required a second procedure or removal of repair material and no mortality. Ileus, scrotal collection resolved spontaneously while a single patient was managed with chronic pains on follow-up.

5. Conclusion

This preliminary study showed that the incidence of complicated AHs 4.2% in surgeries for complicated IH is higher than previous thought with late presentation noticed among left-sided AH patients.

Complicated AHs should therefore be anticipated in any adult with an emergency from long-standing inguinal hernias. Although nylon darn repairs after visceral surgery for types III and IV AHs was significant associated with SSI, standard antibiotic treatment resulted in satisfactory outcome with no recurrence, mortality or need to reintervene. This modality we consider a good alternative treatment in complicated AH especially in resource deprived facilities.

5.1. Limitations

This was a preliminary study and retrospective with often limited and uncontrolled variables that maybe analysed and a rather smaller study sample size.

5.2. Recommendations

We recommend a prospective, large and multi-centre studies with controlled variables and patient selection.

Ethical clearance and consent to participate

Clearance was obtained from the university for health and Allied Sciences review committee Ref: UHAS-REC A.417119-20.

Consent to publish

Consent to publish is not required since it was a retrospective study. Permission of the hospital administration was obtained for publication of the study and all authors read and approved this manuscript for publication.

Availability of material

The data is available with the corresponding author and will be release on request.

Funding

None.

Authors contributions

M A A- Patients Care, Research concept, manuscript writing, data gathering, data analysis and presentation, corresponding authorship. I H- Patients Care, Data gathering, data analysis. M Y K- Manuscript writing, Data analysis. S N- data analysis, graphical presentation.

Acknowledgement

We acknowledge the medical director Dr. Gyamfi for his continues support of this research work.

Provenance and peer review Not commissioned, externally peer-reviewed.

Declaration of competing interest

None to declare.

Abbreviation

AH	Amyand Hernia
SSI	Surgical Site Infection
MMCH	Margaret Marquart Catholic Hospital
M	Male
F	Female
y	year

mon	Month
wks	weeks
RIH	Right inguinal hernia
RISH	right inguinoscrotal hernia
LISH	left inguinoscrotal hernia
SH	scrotal haematoma
Obst	obstructed
sympt	symptom
POD6	post operative day 6
	PPV patent processus vaginalis

Appendix A. Supplementary data

Supplementary data to this article can be found online at <https://doi.org/10.1016/j.amsu.2021.102964>.

References

- [1] S.M. Ali, K.A. Malik, H. Al-Qadhi, Amyand's hernia: study of four cases and literature review, *SQU Medical Journal* 12 (2012) 232–236.
- [2] H. Sharma, A. Gupta, N.S. Shekhawat, B. Memon, M.A. Memon, Amyand's hernia: a report of 18 consecutive patients over a 15-year period, *Hernia* 11 (1) (2007 Feb) 31–35.
- [3] A. Gurer, M. Ozdogan, N. Ozlem, A. Yildirim, H. Kulacoglu, R. Aydin, Uncommon content in groin hernia sac, *Hernia* 10 (2) (2006 Apr) 152–155, <https://doi.org/10.1007/s10029-005-0036-4>.
- [4] W.K. Tsang, K.L. Lee, K.F. Tam, S.F. Lee, Acute appendicitis complicating Amyand's hernia: imaging features and literature review, *Hong Kong Med. J.* 20 (3) (2014 Jun) 255–257, <https://doi.org/10.12809/hkmj133971>. PMID: 24914078.
- [5] G. Ivanschuk, A. Cesmebasi, E.P. Sorenson, C. Blaak, M. Loukas, S.R. Tubbs, Amyand's hernia: a review, *Med. Sci. Mon. Int. Med. J. Exp. Clin. Res.* 20 (2014 Jan 28) 140–146, <https://doi.org/10.12659/MSM.889873>. PMID: 24473371; PMCID: PMC3915004.
- [6] H.A. Almetaher, M.A. Mansour, M.A. Arafa, Management of Amyand's hernia in children: should appendectomy be mandatory or not? *Ann Pediatr Surg* 16 (2020) 14, <https://doi.org/10.1186/s43159-020-00021-3>.
- [7] A. Kaymakci, I. Akillioglu, I. Akkoyun, S. Guven, A. Ozdemir, S. Gulen, Amyand's hernia: a series of 30 cases in children, *Hernia* 13 (6) (2009 Dec) 609–612, <https://doi.org/10.1007/s10029-009-0528-8>. PMID: 19626272.
- [8] S. Gupta, R. Sharma, R. Kaushik, Left-sided Amyand's hernia, *Singap. Med. J.* 46 (2005) 424–425.
- [9] M.T. Logan, J.M. Nottingham, Amyand's hernia: a case report of an incarcerated and perforated appendix within an inguinal hernia and review of the literature, *Am. Surg.* 67 (7) (2001 Jul) 628–629. PMID: 11450774.
- [10] K. Holmes, J.E. Guinn, Amyand hernia repair with mesh and appendectomy, *Surg Case Rep* 5 (1) (2019) 42, <https://doi.org/10.1186/s40792-019-0600-2>. Published 2019 Mar 15.
- [11] E. Kose, A. Sisik, M. Hasbahceci, Mesh inguinal hernia repair and appendectomy in the treatment of Amyand's hernia with non-inflamed appendices, *Surg Res Pract* (2017), 7696385, 2017.
- [12] C. D'Alia, M.G. Lo Schiavo, A. Tonante, F. Taranto, E. Gagliano, L. Bonanno, G. Di Giuseppe, D. Pagano, G. Sturniolo, Amyand's hernia: case report and review of the literature, *Hernia* 7 (2) (2003 Jun) 89–91.
- [13] J.E. Losanoff, M.D. Basson, Amyand hernia: what lies beneath - a proposed classification scheme to determine management Amyand hernia, *Am. Surg.* 73 (January 2008) (2007) 1288.
- [14] K. Psarras, M. Lalountas, M. Baltatzis, E. Pavlidis, A. Tsitlakidis, N. Symeonidis, K. Ballas, T. Pavlidis, A. Sakantamis, Amyand's hernia-a vermiform appendix presenting in an inguinal hernia: a case series, *J. Med. Case Rep.* 5 (2011 Sep 19) 463, <https://doi.org/10.1186/1752-1947-5-463>. PMID: 21929777; PMCID: PMC3185278.
- [15] I. Hagbevor, M.A. Ali, G.A. Awuku, Closed non-suction drain placement as haematoma and seroma formation preventive measure post-nylon darn surgery for inguinoscrotal hernias in adults, *Hernia* (2021), <https://doi.org/10.1007/s10029-021-02430-8>.
- [16] Note to the Editor, AMYAND'S HERNIA- OUTCOME OF NYLON DARN REPAIR AFTER APPENDICECTOMY IN A DISTRICT HOSPITAL: CASE SERIES, *Researchregistry7082*, www.researchregistry.com, 2021.
- [17] R.A. Agha, C. Sohrabi, G. Mathew, T. Franchi, A. Kerwan, O'Neill N for the PROCESS Group, The PROCESS 2020 guideline: updating consensus preferred reporting of CasE series in surgery (PROCESS) guidelines, *Int. J. Surg.* 84 (2020) 231–235.
- [18] A. Michalinos, D. Moris, S. Vernadakis, Amyand's hernia: a review, *Am. J. Surg.* 207 (6) (2014) 989–995.
- [19] N. Drinković, Dobna ucestalost i klinicke karakteristike akutnog apendicitisa [Age distribution and clinical characteristics in acute appendicitis], *Vojnosanit. Pregl.* 48 (2) (1991 Mar-Apr) 115–119.
- [20] M.N. Srouji, B.E. Buck, Neonatal appendicitis: ischemic infarction in incarcerated inguinal hernia, *J. Pediatr. Surg.* 13 (2) (1978) 177–179.

- [21] S. Goyal, M. Shrivastva, R.K. Verma, S. Goyal, Uncommon contents of inguinal hernial sac": a surgical dilemma, *Indian J. Surg.* 77 (Suppl 2) (2015) 305–309, <https://doi.org/10.1007/s12262-013-0806-7>.
- [22] S.K. Sarker, K. Jackson, Laparoscopic extraperitoneal repair of Amyand's inguinal hernia, *J. Soc. Laparoendosc. Surg.* 10 (2006) 528–530.
- [23] L.Z. Cai, D. Foster, W.C. Kethman, T.G. Weiser, J.D. Forrester, Surgical site infections after inguinal hernia repairs performed in low and middle human development index countries: a systematic review, *Surg. Infect.* 19 (1) (2018 Jan) 11–20, <https://doi.org/10.1089/sur.2017.154>. Epub 2017 Oct 19. PMID: 29048997.