

## Intravenous regional anesthesia as an anesthetic technique for a patient with ventricular bigeminy

The Editor,

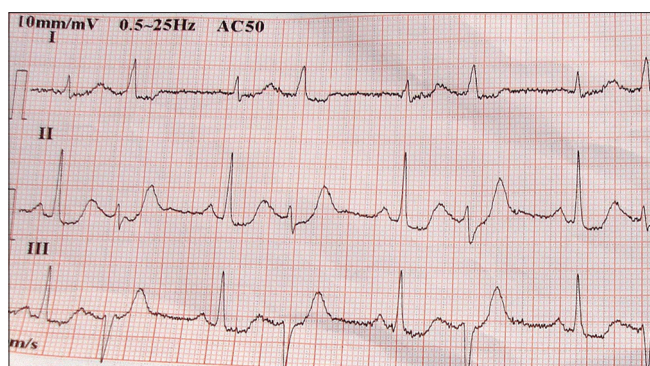
Intravenous regional anesthesia (IVRA) or Bier Block has seen renewed interest due to availability of better quality tourniquet systems and prolongation of anesthesia with the use of adjuvant.

An elderly man weighing 45 kg with hypertension, type II diabetes mellitus, coronary artery disease and chronic kidney disease who had undergone coronary angioplasty was posted for emergency excision of infected pseudoaneurysm of right radial artery arteriovenous (AV) fistula with impending rupture under tourniquet. He had been managed for his chronic kidney disease with medical management and creation of AV fistula. He had been initiated for the first time on hemodialysis (HD) for azotemia and uremic encephalopathy just 2 days prior to presenting for surgery. His previous electrocardiogram (ECG) showed evidence of left ventricular hypertrophy and echocardiography revealed left ventricular ejection fraction of 60% and no regional wall motion abnormality. The blood urea was 149 mg%, serum creatinine 4.8 mg%, serum potassium 4.6 mEq/L and serum sodium 138 mEq/L. In the operation theatre, ECG monitoring revealed a heart rate of 120 beats/min, ventricular bigeminy and the multiple left posterior fasciculus ventricular premature complexes (VPCs) [Figure 1]. His noninvasive blood pressure (NIBP) was 170/90 mmHg. A bolus of preservative free injection lignocaine (Loxicard, Neon Laboratories, Mumbai, India) 40 mg intravenously was given which succeeded in converting the rhythm to normal sinus rhythm but the ventricular bigeminy reappeared after 10 min. After considering comorbidities, return of bigeminy after lignocaine bolus, risk of worsening ventricular arrhythmias due to

stress of laryngoscopy and volatile anesthetics, general anesthesia was avoided. The technique of brachial plexus block with local anesthetic 0.5% bupivacaine plain also had the potential of increased risk of ventricular tachyarrhythmias due to cardiac toxicity. Due to the need for urgent surgery under tourniquet because of impending rupture, an IVRA technique was planned. Since the ventricular bigeminy of the patient had earlier responded to intravenous lignocaine, IVRA with lignocaine was likely to be safe even in case of systemic absorption.

After application of a double tourniquet, 90 mg preservative free lignocaine diluted in 40 ml saline with 10 mcg dexmedetomidine was injected on the dorsal vein of the hand. The safe dose of lignocaine was calculated as 3 mg/kg body weight, which included 40 mgs of lignocaine injected initially. ECG, pulse oximetry and NIBP were closely monitored. Ventricular bigeminy persisted throughout the surgery but was not treated with antiarrhythmic agents as it did not cause hemodynamic instability and alteration in mental status. The surgery lasted for 90 min and was uneventful. After the release of the second tourniquet, the patient was observed closely for further arrhythmogenic effects of the metabolites on release of the tourniquet. His rhythm however reverted to normal sinus rhythm spontaneously a few hours after surgery.

Electrocardiogram abnormalities frequently develop in patients undergoing HD, with the incidence being higher in males, elderly, hypertensive and diabetic patients. The prevalence of ECG changes correlates inversely with a duration of HD and VPCs can even appear several hours after HD.<sup>[1]</sup> Potassium and magnesium imbalances after HD are two important factors for the electrical instability of the myocardium, which was the most likely cause of VPCs in this case. Monitoring of



**Figure 1:** Electrocardiogram showing ventricular bigeminy and left posterior fascicular ventricular premature complexes

prolonged QT interval and dispersion of corrected QT interval is a good indicator for predicting progression to ventricular tachycardia and ventricular fibrillation in these cases.<sup>[2]</sup> Digitalis toxicity, calcium channel blocker therapy, beta blocker therapy and inhalational anesthesia are known to precipitate ventricular bigeminy.<sup>[3]</sup> The presence of more than five VPCs in 1-min is said to increase cardiac risk in the perioperative period.<sup>[4]</sup> However studies show that nearly half of all high-risk patients undergoing noncardiac surgery have frequent VPCs or asymptomatic nonsustained ventricular tachycardia, but the presence of these ventricular arrhythmias is not associated with an increase in nonfatal myocardial infarction or cardiac death.<sup>[5]</sup> VPCs may be abolished by the administration of 0.5–1 mg/kg lignocaine intravenously as was done in this case or intravenous amiodarone 300 mg given over 10 min.

Intravenous regional anesthesia acts by diffusion of local anesthetic into the small veins surrounding the nerves, leading to a centrifugal conduction block in the nerves involved. Around 30% of the injected drug is fixed within the tissues within 20 min and is unavailable for immediate release into the systemic circulation and hence the cuff should not be deflated for at least 20 min. Lignocaine 0.225% solution (90 mg of lignocaine in 40 ml normal saline) used in this case provided sufficient anesthesia for surgery on the upper limb. In this case, prolonged anesthesia time of 90 min was obtained by addition of 10 mcg of dexmedetomidine. Dexmedetomidine, an alpha-2 agonist has been used as an adjunct to local anesthetics

to prolong the duration of analgesia because of its local action on nerve endings.<sup>[6]</sup>

Intravenous regional anesthesia with use of adjuvant is a safe option by adhering to dosage of lignocaine, use of double tourniquets and close monitoring and hence is a useful tool in the armamentarium of anesthesiologists.

**S. Eapen, C. S. Ahluwalia, V. Chopra, S. Kiran**


Department of Anaesthesiology and Critical Care, Command Hospital (EC), Alipore, Kolkata, West Bengal, India

**Address for correspondence:**

Dr. S. Kiran,  
Department of Anaesthesiology and Critical Care,  
Command Hospital (EC), Alipore,  
Kolkata - 700 027, West Bengal, India.  
E-mail: drkirans@yahoo.com

## REFERENCES

1. Abe S, Yoshizawa M, Nakanishi N, Yazawa T, Yokota K, Honda M, *et al.* Electrocardiographic abnormalities in patients receiving hemodialysis. *Am Heart J* 1996;131:1137-44.
2. Day CP, McComb JM, Campbell RW. QT dispersion: An indication of arrhythmia risk in patients with long QT intervals. *Br Heart J* 1990;63:342-4.
3. Anand N, Anand M, Mathur AV, Malettha M, Ghildyal SK. Intra-operative ventricular bigeminy: Can retractor be a cause. *J Anaesthesiol Clin Pharmacol* 2010;26:569-70.
4. Goldman L, Caldera DL, Nussbaum SR, Southwick FS, Krogstad D, Murray B, *et al.* Multifactorial index of cardiac risk in noncardiac surgical procedures. *N Engl J Med* 1977;297:845-50.
5. O'Kelly B, Browner WS, Massie B, Tubau J, Ngo L, Mangano DT. Ventricular arrhythmias in patients undergoing noncardiac surgery. The Study of Perioperative Ischemia Research Group. *J Am Med Assoc* 1992;268:217-21.
6. Memis D, Turan A, Karamanlioglu B, Pamukcu Z, Kurt I. Adding dexmedetomidine to lidocaine for intravenous regional anesthesia. *Anesth Analg* 2004;98:835-40.

Access this article online	
Quick Response Code:	Website: www.annals.in
	DOI: 10.4103/0971-9784.154500