

Uterine Arteriovenous Malformation Treated by Hysteroscopic Excision

Tae Hee Kim¹, Nam Kyeong Kim¹, Seul Ki Kim^{1,2*}, Jung Ryeol Lee^{1,2}, Byung Chul Jee^{1,2}, Yong Beom Kim^{1,2}, Seok Hyun Kim^{2,3}

¹Department of Obstetrics and Gynecology, Seoul National University Bundang Hospital, Gyeonggi-do, ²Department of Obstetrics and Gynecology, Seoul National University College of Medicine, ³Department of Obstetrics and Gynecology, Seoul National University Hospital, Seoul, Korea

Abstract

Uterine arteriovenous malformation (AVM) is a vascular hamartoma of the myometrium that mostly results from uterine tissue damage. Herein, we report a case of uterine AVM managed successfully by hysteroscopy. The patient had an induced abortion and subsequent persistent vaginal spotting and irregular active vaginal bleeding. Ultrasonography showed a 3.5 cm × 2.9 cm heterogeneous lesion in the endometrial cavity with increased vascularity. Symptoms were monitored without uterine artery embolization to avoid complications that may affect a future pregnancy. However, 10 days later, she presented with active vaginal bleeding. Hysteroscopic endometrial mass excision was performed. Her postoperative hemoglobin level and vital signs were stable. Biopsy of the excised mass revealed AVM. Her postoperative vaginal bleeding decreased significantly, and outpatient ultrasonography 1 month later showed no abnormal findings. This case confirms the feasibility and safety of hysteroscopic management of uterine AVMs. The hysteroscopic technique should be prioritized for managing uterine AVMs.

Keywords: Arteriovenous malformation, endometrium, hysteroscopy, uterine artery, uterine hemorrhage

INTRODUCTION

Uterine arteriovenous malformation (AVM) is a vascular hamartoma of the myometrium. Most AVMs result from damage to uterine tissue. At present, there is no clear consensus on the best treatment for uterine AVM. The treatment depends on the degree of bleeding. In mild cases, when the patient is hemodynamically stable, the first line of therapy would be conservative medical management. When conservative management fails, uterine artery embolization (UAE) should be considered. Embolization is effective in 57% of cases. However, a second embolization may be necessary in up to 32% of these patients recurrent bleeding.^[1] Furthermore, UAE can cause postembolization syndrome, transient or permanent amenorrhea, and radiation exposure.^[2] The pregnancy rate after the treatment of AVM

using UAE varies in published reports, ranging from 17.4% in observational studies to 27% in case reports.^[3]

Conversely, hysteroscopic management of uterine AVMs yielded pregnancy rates as high as 55%, which are much higher than the pregnancy rates after UAE.^[4] Therefore, hysteroscopic management of uterine AVM should be considered in women of reproductive age. Herein, we present the case of a 20-year-old woman in whom we successfully performed hysteroscopy for uterine AVM, no complications or recurrence after the procedure.

CASE REPORT

In January 2018, a 20-year-old female, gravida 1, para 0-0-1-0, was admitted to the university hospital for irregular

Address for correspondence: Dr. Seul Ki Kim,
Department of Obstetrics and Gynecology, Seoul National University
Bundang Hospital, 82 Gumi-Ro, 173 Beon-Gil, Bundang-Gu,
Seongnam-Si, Gyeonggi-do, Korea.
E-mail: drksk80@gmail.com

Article History:

Received 7 November 2018
Received in revised form 7 March 2019
Accepted 18 March 2019
Available online 29 August 2019

Access this article online

Quick Response Code:



Website:
www.e-gmit.com

DOI:
10.4103/GMIT.GMIT_114_18

This is an open access journal, and articles are distributed under the terms of the Creative Commons Attribution-NonCommercial-ShareAlike 4.0 License, which allows others to remix, tweak, and build upon the work non-commercially, as long as appropriate credit is given and the new creations are licensed under the identical terms.

For reprints contact: reprints@medknow.com

How to cite this article: Kim TH, Kim NK, Kim SK, Lee JR, Jee BC, Kim YB, *et al.* Uterine arteriovenous malformation treated by hysteroscopic excision. *Gynecol Minim Invasive Ther* 2019;8:132-4.

but profuse vaginal bleeding. She had an induced abortion in November 2017 with curettage for a 13-week-sized fetus. After artificial abortion, she developed persistent vaginal spotting and intermittent active vaginal bleeding. She visited another university-based hospital for the recurrent active vaginal bleeding and was referred to our hospital because the local hospital's location was unfamiliar to her. When she presented to our hospital, her hemoglobin level was 8.1 g/dl, and a transvaginal ultrasound showed a 3.5 cm × 2.9 cm heterogeneous lesion in the endometrial cavity with florid vascularity [Figure 1a]. On pelvic examination, the vaginal bleeding was not active. A pelvic magnetic resonance imaging (MRI) was performed for further evaluation. The pelvic MRI and transvaginal ultrasonography both revealed this lesion to be an AVM. Pelvic MRI showed a 2.9 cm-sized low-signal-intensity mass with signal void vasculature [Figure 1b]. As she was a single woman and the vaginal bleeding was not active, we decided not to perform immediate intervention but opted to monitor her symptoms carefully. However, she presented to the hospital again 10 days later with active vaginal bleeding. Her hemoglobin level at that time was 8.0 g/dl. She was transfused with three units of blood. She was informed of the possibility of an emergency UAE. We also explained that, in severe cases, which are very rare, a hysterectomy might be required. Subsequently, hysteroscopy was performed. Five days later, elective hysteroscopic endometrial mass excision was performed. While removing the lesion, bleeding also needed to be controlled [Figure 2]. The total time duration to remove the lesion completely was approximately 1 h and 20 min. During the operation, the hysteroscopic fluid input/output was 11,400/8900 ml, and the estimated blood loss was 350 ml. After mass excision, a Foley catheter was inserted into the

uterus through the vagina. On postoperative day 1, the Foley catheter was removed after confirming the absence of active bleeding. Her hemoglobin levels on postoperative days 0 and 1 were both 8.5 g/dl. Her vital signs were also stable. She was discharged and followed up at the outpatient clinic 1 week later. The biopsy result indicated an increase in thick-walled vasculature in the myometrium, with irregular dilatations, suggestive of AVM. Her vaginal bleeding decreased to needing one menstrual pad per day. Outpatient ultrasound 1 month later showed no abnormal findings.

DISCUSSION

The treatment for uterine AVM is based on the severity of uterine bleeding and can include conservative medical approaches or embolization of affected arteries.^[4] Conservative treatment consists of medical therapy with methylergonovine maleate, danazol, and GnRH agonists and is associated with a high rate of failure and persistent bleeding.^[5]

When conservative treatment fails, the designated treatment is UAE or iliac/uterine artery ligation.^[6,7] UAE is the most frequently used treatment modality (59%) in cases of uterine AVMs.^[3] If embolization fails repetitively, a hysterectomy will be necessary.^[8] Uterine embolization through laparotomy and AVM excision is alternative treatments that are rarely used.^[9] Laparoscopic uterine artery ligation with AVM excision, a minimally invasive procedure, has been described as an alternative to laparotomy, but this procedure still confers the risks of major surgery under general anesthesia. The published case reports on this procedure are very limited to provide evidence for its applicability. The current conservative treatments cannot control moderate cases of AVM, and UAE is associated with both fertility and obstetric complications.

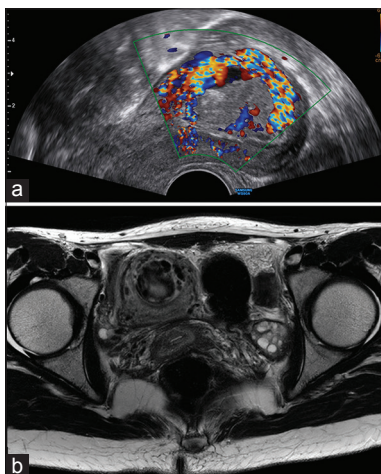


Figure 1: Representative images of arteriovenous malformation. (a) Visualization of the arteriovenous malformation by transvaginal ultrasonography with color Doppler. (b) Visualization with pelvic magnetic resonance imaging

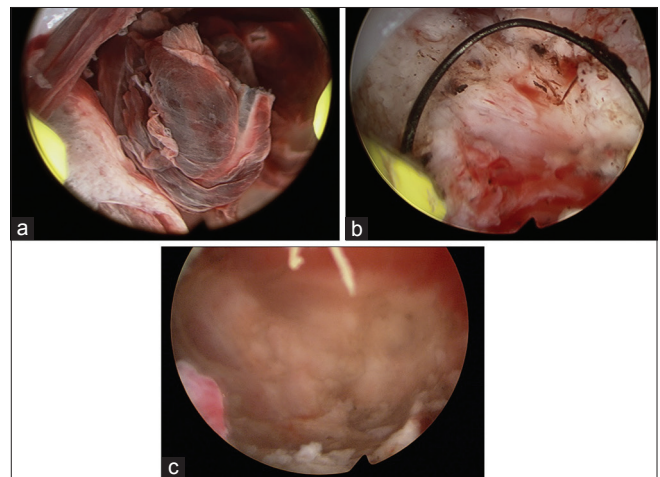


Figure 2: Representative images taken during hysteroscopy. (a) Visualization of the arteriovenous malformation in the uterine cavity. (b) Hysteroscopic resection of the lesion. (c) Appearance of the uterine cavity after complete resection of the arteriovenous malformation

The pregnancy rate after treatment of AVM using UAE varies in published reports, ranging from 17.4% in observational studies to 27% in case reports.^[3] Pregnancies after UAE may be complicated by spontaneous abortion, placenta previa or accreta, postpartum hemorrhage, and a higher cesarean section rate than in the general population.^[9]

AVMs occur at a median age of 30 years when the patient's fertility is critical.^[4] Therefore, hysteroscopic, minimally invasive management of uterine AVMs is considered to preserve fertility and minimize complications. A retrospective case series study showed that hysteroscopic management of uterine AVMs is favorable for postsurgical fertility rates.^[5] All cases were treated successfully in a single session of surgical hysteroscopy with no recurrence during the follow-up. There were no complications during the surgery or throughout the follow-up. Peak systolic velocity was used to determine the necessity of hysteroscopic treatment in the previous study.^[4] Studies on the parameters for performing hysteroscopic operation and particular maneuvers for resection should be carried out in the future.

The presented case confirms the feasibility and safety of hysteroscopic management of uterine AVMs, which is associated with a reduced risk of infertility compared to that with UAE. Therefore, it is imperative to consider the hysteroscopic technique as priority in the management of uterine AVMs in women of reproductive age.

Ethical approval

This study was approved by Seoul National University Bundang Hospital institution review board and the IRB No.B-1812/513-701 was obtained on 6th December in 2018.

Declaration of patient consent

The authors certify that they have obtained all appropriate patient consent forms. In the form the patient(s) has/have

given his/her/their consent for his/her/their images and other clinical information to be reported in the journal. The patients understand that their names and initials will not be published and due efforts will be made to conceal their identity, but anonymity cannot be guaranteed.

Financial support and sponsorship

Nil.

Conflicts of interest

There are no conflicts of interest

REFERENCES

1. Sanguin S, Lanta-Delmas S, Le Blanche A, Grardel-Chambenoit E, Merviel P, Gondry J, *et al.* Uterine arteriovenous malformations: Diagnosis and treatment in 2011. *Gynecol Obstet Fertil* 2011;39:722-7.
2. Wu YC, Liu WM, Yuan CC, Ng HT. Successful treatment of symptomatic arteriovenous malformation of the uterus using laparoscopic bipolar coagulation of uterine vessels. *Fertil Steril* 2001;76:1270-1.
3. Peitsidis P, Manolagos E, Tsekoura V, Kreienberg R, Schwentner L. Uterine arteriovenous malformations induced after diagnostic curettage: A systematic review. *Arch Gynecol Obstet* 2011;284:1137-51.
4. Calzolari S, Cozzolino M, Castellacci E, Dubini V, Farruggia A, Sisti G, *et al.* Hysteroscopic management of uterine arteriovenous malformation. *JLS* 2017;21. pii: e2016.00109.
5. Nonaka T, Yahata T, Kashima K, Tanaka K. Resolution of uterine arteriovenous malformation and successful pregnancy after treatment with a gonadotropin-releasing hormone agonist. *Obstet Gynecol* 2011;117:452-5.
6. Patton EW, Moy I, Milad MP, Vogezeang R. Fertility-preserving management of a uterine arteriovenous malformation: A case report of uterine artery embolization (UAE) followed by laparoscopic resection. *J Minim Invasive Gynecol* 2015;22:137-41.
7. O'Brien P, Neyastani A, Buckley AR, Chang SD, Legiehn GM. Uterine arteriovenous malformations: From diagnosis to treatment. *J Ultrasound Med* 2006;25:1387-92.
8. Grivell RM, Reid KM, Mellor A. Uterine arteriovenous malformations: A review of the current literature. *Obstet Gynecol Surv* 2005;60:761-7.
9. Delotte J, Chevallier P, Benoit B, Castillon JM, Bongain A. Pregnancy after embolization therapy for uterine arteriovenous malformation. *Fertil Steril* 2006;85:228.