

This is an Open Access article licensed under the terms of the Creative Commons Attribution-NonCommercial-NoDerivs 3.0 License (www.karger.com/OA-license), applicable to the online version of the article only. Distribution for non-commercial purposes only.

Acute Pancreatitis Secondary to Duodenoduodenal Intussusception in Duodenal Adenoma

Fumiaki Watanabe Hiroshi Noda Jun Okamura
Nobuyuki Toyama Fumio Konishi

Department of Surgery, Saitama Medical Center, Jichi Medical University,
Saitama, Japan

Key Words

Tubulovillous adenoma · Invagination · Epigastric pain

Abstract

Duodenoduodenal intussusception is a rare condition that is in general caused by a tumor. We describe duodenoduodenal intussusception secondary to a tubulovillous adenoma that caused acute pancreatitis in a 31-year-old female. We resected a duodenal tumor from the submucosal layer and then simply closed the duodenal wall. To the best of our knowledge, this is the first description of acute pancreatitis secondary to duodenoduodenal intussusception by tubulovillous adenoma in the second part of the duodenum in an adult.

Introduction

Intussusception is the invagination of one segment of the intestine into another and although common among children, it is rare in adults [1]. Ileocolic intussusception is the most common type. Duodenoduodenal intussusception is unusual because the duodenum is fixed in the retroperitoneal position [2], but its occurrence is usually secondary to tumors, lipoma, Brunner's gland hamartomatous polyps or adenomas [3]. Adenoma in the lower duodenum presenting as acute pancreatitis secondary to duodenoduodenal intussusception in an adult female has not been reported. We describe an adult female in whom duodenoduodenal intussusception arising because of a duodenal adenoma was accompanied by acute pancreatitis.

Case Report

A 31-year-old female had endured recurrent intermittent abdominal pain for 2 years. She had been admitted to a local hospital 2 months previously and acute pancreatitis was indicated based on elevated amylase levels (492 IU/l, normal range 37–160 IU/l). All other blood chemistry parameters including bilirubin were within normal limits. One month later, she was admitted to the same hospital for recurrent abdominal pain and referred to us for more detailed assessment.

CT examination at the previous hospital had revealed a diffusely swollen pancreas along with slightly dilated main pancreatic duct ([fig. 1](#)). The upper abdomen was not tender. Contrast-enhanced CT revealed no diffuse swelling of the pancreas and no dilation of the main pancreatic duct. However, a ‘target’ appearing in a region of the duodenum confirmed a diagnosis of duodenoduodenal intussusception ([fig. 2](#)). The stomach was not distended and the common bile duct was not dilated. Upper gastrointestinal endoscopy revealed an elevated 3-cm tumor near the ampulla of Vater in the second part of the duodenum ([fig. 3a](#)). Biopsies from the tumor confirmed that the tumor was an adenoma. Gastroduodenography revealed an elevated lesion in the second part of the duodenum. Upper gastrointestinal endoscopy and upper gastroduodenography showed no obstruction. Endoscopic ultrasonography showed the 31-mm low-echoic and well-vascularized tumor originating from the mucosa ([fig. 3b](#)). We diagnosed duodenoduodenal intussusception caused by this tumor acting as the lead point.

Endoscopic mucosal resection of the tumor was initially planned, but the tumor was highly vascularized and thus the risk of bleeding was high. Therefore we planned to resect the duodenal adenoma via laparotomy. An incision of about 10 cm was made on the upper abdomen. We performed Kocher’s maneuver and detected a mass inside the second part of the duodenum. The anterior wall of the second part of the duodenum was cut and the tumor was resected from the submucosal layer. The anterior wall of the duodenum was closed using Gambee’s method. The postoperative course was uneventful. Enteral feeding was started on postoperative day 4 and the patient was discharged on postoperative day 12. Histology confirmed a 40 × 33 × 26 mm tubulovillous adenoma with foci of severe dysplasia but no malignancy.

Discussion

Duodenoduodenal or duodenojejunal intussusception is very rare in adults because the duodenum is fixed in the retroperitoneum. Duodenoduodenal or duodenojejunal intussusception is almost always associated with a lead point such as a lipoma [2], hamartomatous polyp [1], Brunner’s gland hamartoma [4] or hyperplasia [5]. Galandiuk et al. [6] reported that 88% of duodenal adenomas were located in the second part of the duodenum. Duodenoduodenal intussusception in this patient was associated with tubulovillous adenoma as the lead point. The clinical symptoms of duodenoduodenal or duodenojejunal intussusception are not specific and may easily be misinterpreted. Epigastric pain, abdominal mass, gastrointestinal bleeding and enteral obstruction may be present. The biliary and pancreatic systems are not generally involved. However, McGrath et al. [2] and Chalmers et al. [7] encountered duodenal tumors causing duodenojejunal intussusceptions and found dilated extrahepatic bile and pancreatic ducts in these patients, but whether the biliary obstruction was caused by the duodenal tumor or by the intussusception was not specified. Uggowitz et al. [3] described a duodenojejunal intussusception that manifested as biliary obstruction and pancreatic atrophy secondary to a hamartomatous polyp in an adult.

The chief complaint of our patient was recurrent abdominal pain for about 2 years. Two months previously, she had been diagnosed with acute pancreatitis based on abdominal pain, elevated serum amylase and abdominal CT imaging findings at a local hospital. Enteral obstruction, bleeding and jaundice were absent. Contrast-enhanced CT

imaging at our hospital revealed neither diffuse swelling of the pancreas nor dilation of the main pancreatic duct, but a ‘target’ appearance in the second part of the duodenum confirmed the diagnosis of duodenoduodenal intussusception.

Pancreatitis secondary to duodenojejunal intussusception is highly unusual. A search of the PubMed database identified only two reports describing pancreatitis secondary to duodenojejunal intussusception ([table 1](#)) [3, 8]. One patient had acute pancreatitis associated with duodenojejunal intussusception and the other had chronic pancreatitis. Both patients were diagnosed with Peutz-Jegher syndrome.

Acute pancreatitis can be triggered by a temporary or permanent blockage of the pancreatic duct. Acute pancreatitis is sometimes associated with gastrointestinal polyposis syndrome [9–11]. These reports describe obstructive acute pancreatitis caused by ampullary masses related to gastrointestinal polyposis syndrome. However, our patient did not have an obstructive ampullary neoplasm and duodenoduodenal intussusception was induced by a duodenal adenoma. The duodenoduodenal intussusception presumably caused the acute pancreatitis as follows. The duodenoduodenal intussusception initially caused the common channel to be pulled towards the left side, thus stretching the common channel. The duodenoduodenal intussusception caused the duodenum to become elongated, causing thinning of the duodenal ampullary wall and inducing a spasm in the sphincter of Oddi, resulting in obstructive acute pancreatitis [8]. However, CT imaging did not show a relationship with the acute pancreatitis and the duodenoduodenal intussusception in our patient.

Fujiwara et al. [12] used a double-tract anastomosis to a retrocolic Roux-en-Y loop to reconstruct a large duodenal defect that followed resection of a duodenal tubulovillous adenoma. We simply closed the duodenal wall after resection of the tumor from the submucosal layer.

In conclusion, acute pancreatitis secondary to duodenoduodenal intussusception in adult is very rare. Duodenoduodenal intussusception is always associated with a lead point, which in our patient was a tubulovillous adenoma. Acute pancreatitis associated with duodenoduodenal intussusceptions requires early diagnosis and treatment to prevent pancreatic parenchymal atrophy, which could lead to serious complications such as diabetes mellitus.

Table 1. Summary of reports of pancreatitis secondary to duodenojejunal or duodenoduodenal intussusceptions

First author	Sex	Age	Chief complaints	Medical history	Type of intussusception	Pancreatitis	Treatment
Uggowitz [3]	female	58	abdominal pain, vomiting, low body weight, diarrhea, jaundice	Peutz-Jegher syndrome	duodenojejunal	chronic	surgery
Jeon [8]	female	19	abdominal pain and vomiting	Peutz-Jegher syndrome	duodenojejunal	acute	surgery
This report	female	31	abdominal pain	none	duodenoduodenal	acute	surgery

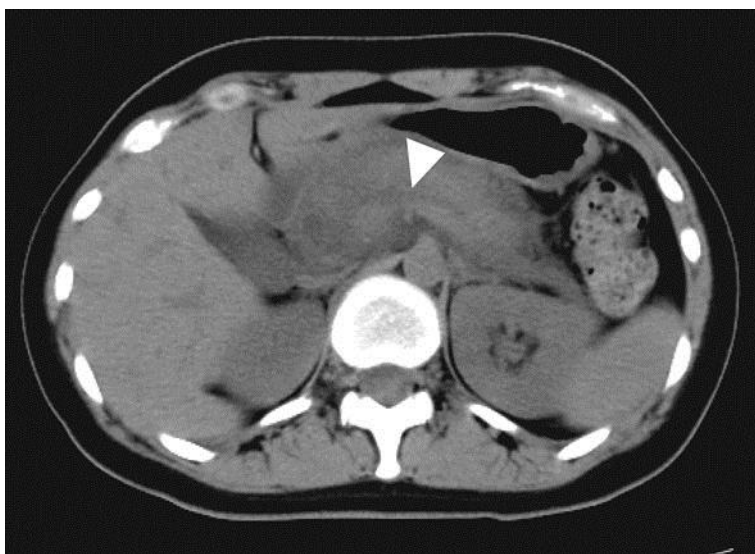


Fig. 1. CT image from a previous hospital shows diffusely swollen pancreas and slightly dilated main pancreatic duct (arrowhead).

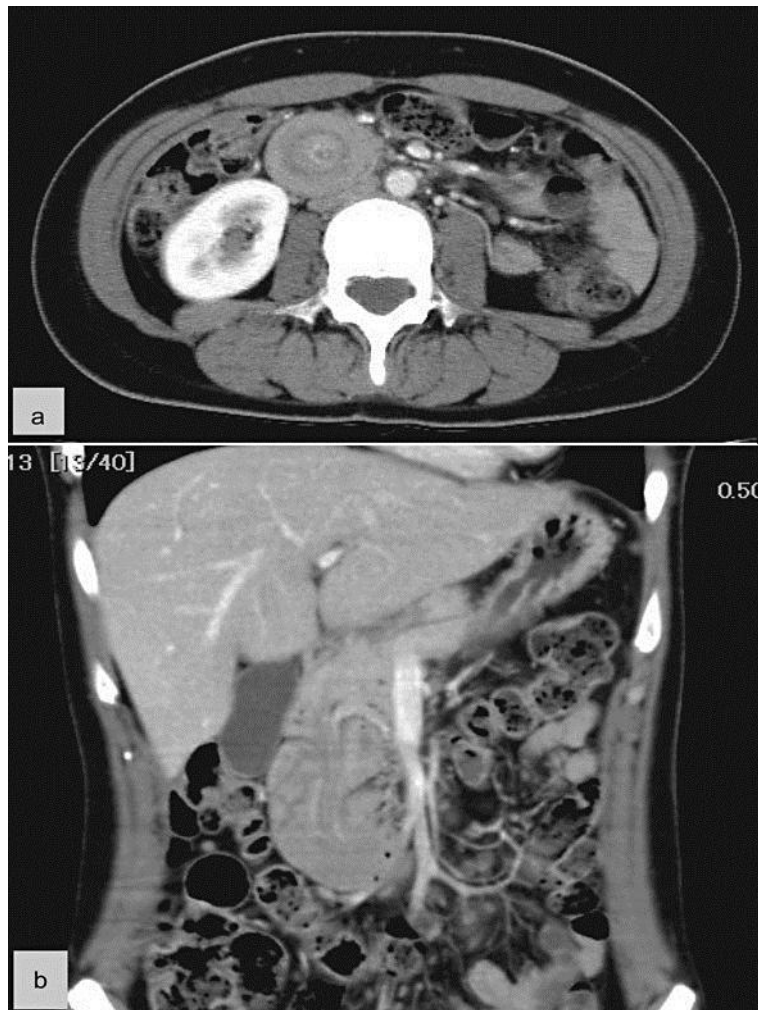

Fig. 2. Subsequent contrast-enhanced abdominal CT shows ‘target’ appearance in the region of the duodenum confirming the diagnosis of duodenoduodenal intussusception (a). Coronal multiplanar reformatted image shows duodenoduodenal intussusception (b).

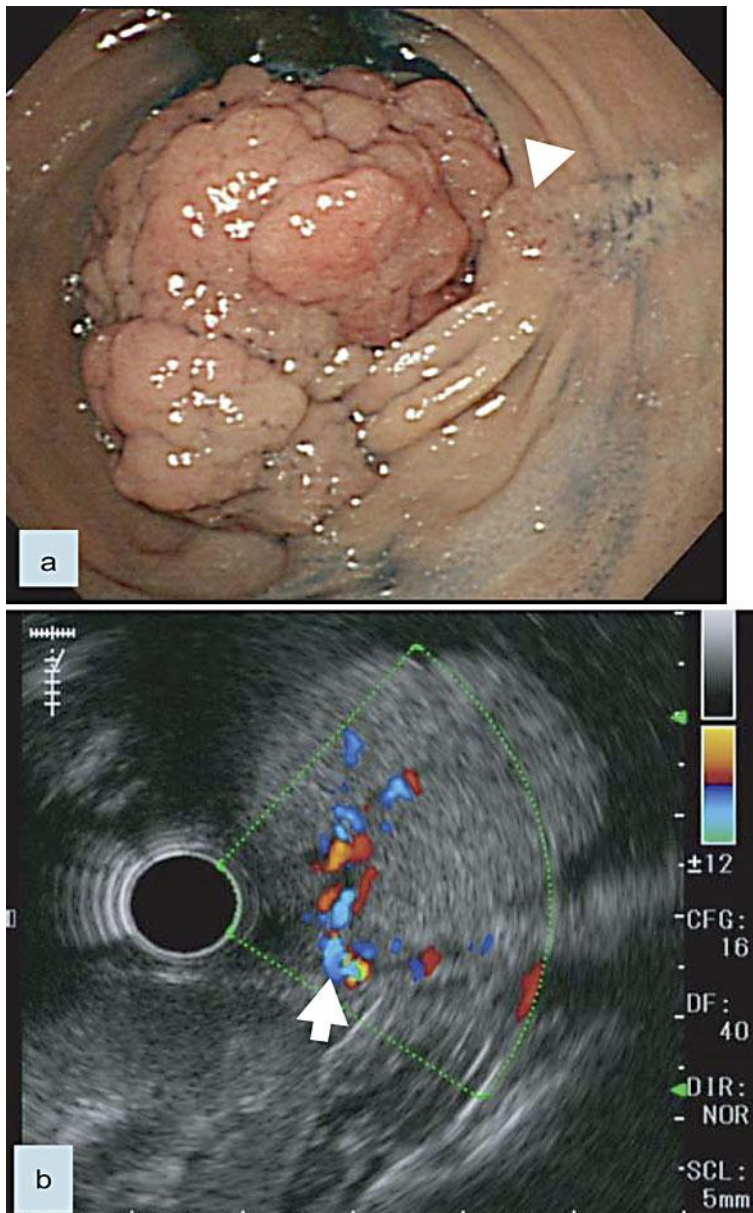


Fig. 3. **a** Upper gastrointestinal endoscopy findings show an elevated red and finely granular lesion from the oral side of the ampulla of Vater (arrowhead). **b** Endoscopic ultrasonography shows a highly vascularized tumor originating from the mucosa (arrow: feeding artery and drainage vessels).

References

- 1 Hwang CS, Chu CC, Chen KC, Chen A: Duodenojejunal intussusceptions secondary to hamartomatous polyps of duodenum surrounding the ampulla of Vater. *J Pediatr Surg* 2001;36:1073–1075.
- 2 McGrath FP, Moote DJ, Langer JC, Orr W, Somers S: Duodenojejunal intussusception secondary to a duodenal lipoma presenting in a young boy. *Pediatr Radiol* 1991;21:590–591.
- 3 Uggowitz M, Kugler C, Aschauer M, Hausegger K, Mischinger H, Klimpfing M: Duodenojejunal intussusceptions with biliary obstruction and atrophy of the pancreas. *Abdom Imaging* 1996;21:240–242.
- 4 Lempke RE: Intussusception of the duodenum: report of a case due to Brunner's gland hyperplasia. *Ann Surg* 1959;150:160–166.
- 5 Chuang JH, Chen WJ: Duodenojejunal intussusception secondary to hamartomatous polyp of Brunner's glands. *J Pediatr Gastroenterol Nutr* 1991;13:96–100.
- 6 Galandiuk S, Hermann RE, Jagelman DG, Fazio VW, Sivak MV: Villous tumors of the duodenum. *Ann Surg* 2007;198:234–239.
- 7 Chalmers N, De Beaux AC, Garden OJ: Case report: prolapse of an ampullary tumor beyond the duodeno-jejunal flexure. *Clin Radiol* 1993;47:141–142.
- 8 Jeon SJ, Yoon SE, Lee YH, Yoon KH, Kim EA, Juhng SK: Acute pancreatitis secondary to duodenojejunal intussusceptions in Peutz-Jegher syndrome. *Clin Radiol* 2007;62:88–91.
- 9 Berk T, Friedmen LS, Goldstein SD, Marks GP, Rosato FE: Relapsing acute pancreatitis as the presenting manifestation of an ampullary neoplasm in a patient with polyposis coli. *Am J Gastroenterol* 1985;80:627–629.
- 10 Burt RW, Rikkers LF, Gardner EJ, Lee RG, Tolman KG: Villous adenoma of the duodenal papilla presenting as necrotizing pancreatitis in a patient with Gardner's syndrome. *Gastroenterology* 1987;92:532–535.
- 11 Wright BE, Kozarek RA, Traverso LW, Wechter D, Thirlby R, Ralts SL: Recurrent pancreatitis in Gardner variant familial polyposis: etiology, diagnostic approach, and interventional results. *Arch Surg* 1999;134:311–315.
- 12 Fujiwara H, Yamasaki M, Nakamura S, Yasuda K, Tomiyoshi H, Teramura K: Reconstruction of a large duodenal defect created by resection of a duodenal tubulovillous adenoma using a double-tract anastomosis to a retrocolic roux-en-y loop: report of a case. *Surg Today* 2002;32:824–827.