

# Phacoemulsification in posterior polar cataract: Experience from a tertiary eye care Centre in North India

Chintan Malhotra, Deepika Dhingra, Nishant Nawani, Partha Chakma, Arun K Jain

**Purpose:** To determine the rate of posterior capsular rupture (PCR) and assess the postoperative outcomes in patients of posterior polar cataract (PPC) undergoing phacoemulsification using a combination of “V” or “λ” nucleofractis and viscodissection. **Methods:** It was a retrospective study of 80 eyes of 64 patients undergoing surgery for PPC. All surgeries were performed by a single surgeon. After completion of the continuous curvilinear capsulorrhexis (CCC), controlled hydrodelineation was used to separate the endonucleus from the epinuclear shell with limited viscodissection. Phacoemulsification was then carried out by making a “V” or lambda-shaped nucleofractis with the phaco tip followed by multiple chopping of the nucleus, ensuring the integrity of the epinuclear part of the lens. The epinuclear plate was removed after viscodissection. **Results:** The overall rate of PCR was 7.5% (6 out of 80 eyes). Of the 6 eyes, 4 eyes had been documented to have a pre-existing posterior capsular defect on slit-lamp examination. The rate of “on table” PCR, that is, PCR occurring intraoperatively was only 2.6% (2 of 76 eyes). Nucleus drop was not encountered in any case. Overall 87.5% eyes achieved a final visual acuity of 20/40 or better with 68.75% being 20/20 or better. Of the eyes developing PCR, two-third achieved a visual acuity of 20/30 or better. **Conclusion:** Using a combination of surgical techniques of V groove or lambda technique for nucleofractis and removal of epinucleus by viscodissection can result in a low rate of PCR and extremely good postoperative outcomes in cases of PPC.

**Key words:** Femtosecond laser assisted cataract surgery, FLACS, hydrodelineation, lambda technique, posterior polar cataract, V groove, viscodissection

Posterior polar cataract (PPC) is a type of developmental cataract which is considered to arise before birth or in early infancy.<sup>[1]</sup> The exact pathogenesis remains unknown and various causes have been proposed to contribute to its development. These include persistence of the hyaloid artery,<sup>[2]</sup> mesoblastic tissue invasion of the crystalline lens,<sup>[3,4]</sup> and various genetic mutations.<sup>[5,6]</sup> A positive family history has been reported in 40–55% of the cases.<sup>[7,8]</sup>

A mature PPC presents as a dense, circular plaque with concentric rings in the posterior central part of the lens involving mainly the posterior subcapsular and capsular region. It has classically been described to have a “Bull’s eye” or onion peel appearance. Ultrastructurally, PPC is associated with either a thin and fragile posterior capsule with the discoid opacity being adherent to it,<sup>[9]</sup> or in upto 20% of cases the posterior capsule may be congenitally deficient.<sup>[7]</sup> Surgery of PPC hence remains a surgical challenge because of the ever-present risk of posterior capsular rupture (PCR) and nucleus drop. Reported rates of PCR in these eyes vary widely from 0 to 36%.<sup>[7,8,10-16]</sup>

There are several techniques described earlier by various surgeons in an attempt to reduce the risk of PCR while operating on a PPC. These include among others “inside

out hydrodelineation” by Vasavada *et al.*,<sup>[15]</sup> “λ technique of nucleofractis” by Lee and Lee,<sup>[16]</sup> “V” groove phaco by Kelman,<sup>[17]</sup> “layer by layer” phacoemulsification by Vajpayee,<sup>[18]</sup> viscodissection of epinucleus and cortex using a dispersive viscoelastic by Allen *et al.*,<sup>[19]</sup> and Fine *et al.*,<sup>[20]</sup> and “inverse horseshoe technique” by Salahuddin.<sup>[21]</sup>

The present study was conducted to evaluate the PCR rate and assess the postoperative outcomes using a combination of controlled hydrodelineation, “V”, or λ (lambda) technique for nucleofractis and viscodissection of the epinucleus, prior to cortical aspiration.

## Methods

This was a retrospective study conducted at a tertiary eye care centre in North India. Eighty eyes of 64 patients with PPC having visual symptoms attributable to the presence of the cataract were included in the study. All surgeries were performed by a single surgeon (AKJ).

All patients had preoperative detailed ophthalmological examination including recording of uncorrected distance visual acuity (UDVA), corrected distance visual acuity (CDVA),

This is an open access journal, and articles are distributed under the terms of the Creative Commons Attribution-NonCommercial-ShareAlike 4.0 License, which allows others to remix, tweak, and build upon the work non-commercially, as long as appropriate credit is given and the new creations are licensed under the identical terms.

For reprints contact: reprints@medknow.com

Cite this article as: Malhotra C, Dhingra D, Nawani N, Chakma P, Jain AK. Phacoemulsification in posterior polar cataract: Experience from a tertiary eye care centre in North India. Indian J Ophthalmol 2020;68:589-94.

### Access this article online

#### Website:

www.ijo.in

#### DOI:

10.4103/ijo.IJO\_932\_19

### Quick Response Code:



Advanced Eye Centre, Postgraduate Institute of Medical Education and Research, Chandigarh, India

**Correspondence to:** Dr. Arun K Jain, Room No 110, Advanced Eye Centre, Postgraduate Institute of Medical Education and Research, Sector 12, Chandigarh - 160 012, India. E-mail: aronkjain@yahoo.com

Received: 16-May-2019

Revision: 13-Aug-2019

Accepted: 25-Oct-2019

Published: 16-Mar-2020

intraocular pressure measurement with non-contact tonometer, slit-lamp biomicroscopy, and dilated fundus examination. Pupillary retroillumination was attempted in every case to look for pre-existing capsular dehiscence. If the fundus examination was precluded due to presence of a dense cataract, B-scan ultrasonography was done to document the status of the posterior segment. PPC was graded according to the classification given by Singh,<sup>[22]</sup> that is, Type 1: posterior polar opacity associated with a posterior subcapsular cataract (PSC); Type 2: sharply defined round or oval opacity with ringed appearance like an onion, with or without greyish spots at the edge; Type 3: sharply defined round or oval white opacity with dense white spots at the edge often associated with thin or absent posterior capsule; Type 4: combination of the above 3 types with nuclear sclerosis.

Biometry was performed using partial coherence laser interferometry (IOL Master, Zeiss, Jena, Germany). In cases of dense cataract where IOL master was unable to acquire the readings, axial length was obtained by immersion A-scan and manually fed into the IOL master. Inclusion criteria: Patients aged 12–90 years with visually disabling posterior polar cataract who had minimum 3 months follow-up after surgery were included for analysis. Exclusion criteria: Secondary causes of cataract were excluded. Eyes with corneal opacity or posterior segment disease including glaucoma, age related macular degeneration, diabetic retinopathy, etc., were also excluded.

### Surgical technique

Under peribulbar anesthesia, the main incision was made with a 2.2 mm dual bevel keratome at the limbus and the site was planned according to the steepest keratometric readings to neutralize maximum amount of preoperatively existing astigmatism. Anterior chamber was formed with a cohesive dispersive viscoelastic, DisCovisc (Alcon Laboratories, Fort Worth, Texas) containing 17 mg/ml of sodium hyaluronate and 40 mg/ml of sodium chondroitin sulfate. Side ports were made with 15° blade. Continuous curvilinear capsulorhexis of about 5 mm was initiated with a needle cystitome and completed with microcapsulorhexis forceps. Fig. 1 shows the steps of surgery in a Type 2 PPC [Fig. 1a]. Hydrodelineation was performed with the help of hydrodissection cannula, burying the cannula under the epinuclear part of the lens followed by slow and controlled injection of the balanced salt solution [Fig. 1b]. The formation of a complete golden ring ensured the completion of the step. This was followed by a multiquadrant viscodissection, taking care that the ocular viscoelastic device (OVD) wave did not cross the PPC plaque [Fig. 1c]. The surgeries were performed on an Infiniti phaco machine (Alcon Laboratories Ltd, Fort Worth, TX, USA). In all cases, the nucleus was removed with a modified stop and chop technique. Sculpting was done with bottle height of 70–75 cm, torsional energy 90%, vacuum 60 mmHg, and aspiration flow rate (AFR) 21 ml/min. For chopping, a bottle height of 70 cm, torsional energy 65–75%, vacuum 250–350 mm Hg, and AFR 24–28 ml/min were used depending upon the hardness of cataract.

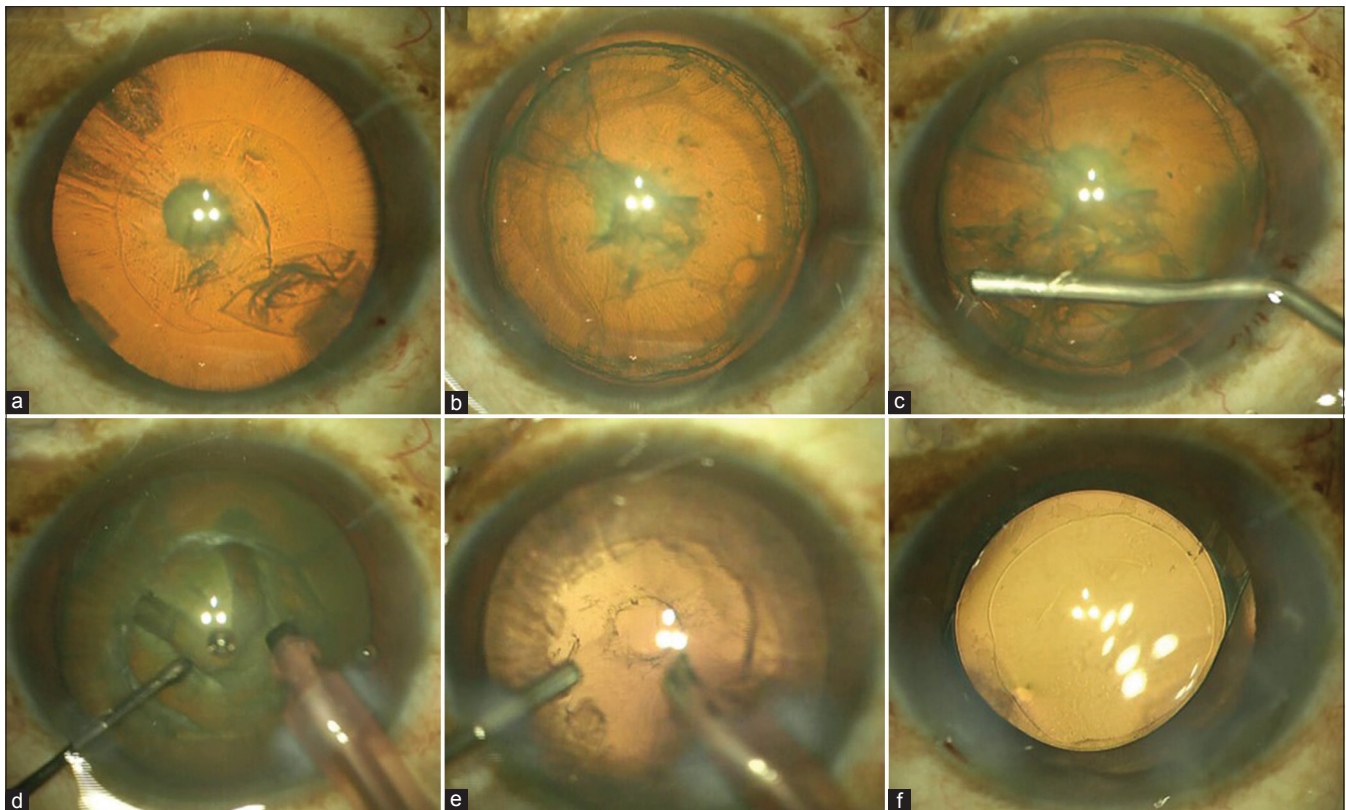
In type 2 and type 3 cataracts, the V groove (also known as “victory”) technique described by Kelman in 1994 was used for nucleotomy.<sup>[17]</sup> The endonucleus was sculpted, creating a “V” shaped trough so as to ensure that the posterior epinuclear

shell remains intact [Fig. 1d]. The arms of the “V” trough were cracked in slow and small manual rotatory movements from either side with the help of a Drysdale hook and the phaco needle tip. Then the “V”-shaped endonuclear quadrant was emulsified first, thus creating space for manipulation of the remaining endonucleus within an epinuclear shell. The remaining endonucleus was rotated minimally (just enough so as to enable access and a good hold of the phaco tip onto the remaining endonucleus) and chopped into multiple pieces and emulsified. It was ensured that the posterior epinuclear plate with the polar cataract remains intact during nucleofractis. Anterior chamber was always maintained throughout the procedure, injecting a dispersive OVD every time before withdrawing the phaco tip from main incision, ensuring that the chamber never shallowed suddenly [Fig. 1e]. In eyes with type 4 PPC, the “lambda” technique described by Lee<sup>[16]</sup> was used. In this particular technique, nucleus sculpting was done in the shape of the Greek letter lambda ( $\lambda$ ) [Fig. 2a and b]. Cracking was done along both arms of the lambda and the central piece was removed first.

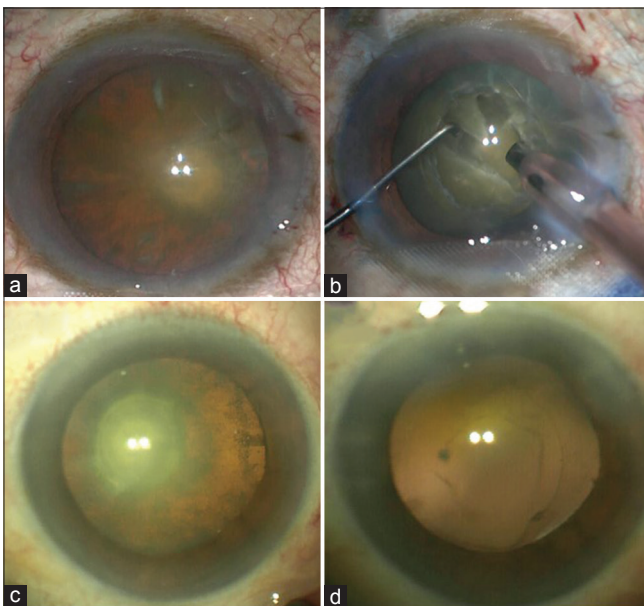
After nucleotomy, in all cases the epinuclear plate was viscodissected from under the edge of the capsulorhexis in multiple quadrants as described by Allen *et al.*,<sup>[19]</sup> and Fine *et al.*<sup>[20]</sup> Care was exercised that the wave of viscoelastic extended just short of the posterior polar plaque, without actually crossing it. Under low parameters (bottle height 70–74 cm, vacuum 220–230 mmHg, AFR 22–24 ml/min), the epinucleus was peeled from equator toward the centre with the help of phaco needle, and the part which was attached to the posterior pole was emulsified at last. For the cortex removal, vacuum was set to 500 mmHg and aspiration rate was 22–24 ml/min. Cortical matter was stripped from the equator to the centre. Cohesive viscoelastic Healon GV (Abbott Medical Optics, USA) containing 14 mg/ml sodium hyaluronate was injected to inflate the bag. If the posterior capsule was intact, IOL was implanted in the bag [Fig. 1f]. After the IOL insertion, residual viscoelastic was removed with the bimanual irrigation and aspiration tip from below the IOL by tilting the lens and inserting the irrigation tip under the lens surface and also from above the IOL.

In cases where pre-existing capsular dehiscence ( $n = 4$  eyes) was noted on slit-lamp examination, the surgical technique and precautions exercised were similar to cases where the posterior capsule was intact preoperatively, except that the technique of nucleofractis was the “lambda” technique, since all these were grade 4 PPCs. Whenever a posterior capsular rent (PCR) was encountered (whether pre-existing or occurring de novo), the phaco probe was withdrawn after injecting a dispersive OVD into the bag. The extent of the PCR was assessed subjectively as being less than or greater than 50% of the anterior capsulorhexis size. Infusion bottle height was reduced to 55 cm, and anterior vitrectomy was done in cases with vitreous disturbance using cut rate of 800/s and vacuum of 200 mm Hg. Viscoelastic was injected in the capsular bag and ciliary sulcus. In cases with PCR >50% of the anterior capsulorhexis size, a three-piece acrylic hydrophobic IOL was placed in the sulcus, the optic of which was captured within the capsulorhexis. In cases of PCR <50% of the anterior capsulorhexis, the IOLs were placed “in the bag.” OVD removal in these cases was done at the end, with the vitrectomy probe in the aspiration mode.





**Figure 1:** (a) Type 2 posterior polar cataract (PPC)- intraoperative photograph. (b) Complete hydrodelineation visible as golden ring. (c) Viscodissection. (d) “V” groove for nucleotomy. (e) Viscoelastic injection after completing the nucleotomy and before taking out the phaco probe. (f) Posterior chamber IOL implantation in the capsular bag



**Figure 2:** (a) Type 4 posterior polar cataract. (b) Lambda/inverted Y technique for nucleotomy. (c) Another patient with Type 4 cataract. (d) Pre-existing posterior capsule rent, best visible after completion of lens extraction under retroillumination

Postoperatively, patients were given a combination of moxifloxacin 0.5% and dexamethasone 0.1% 4–6 times a day, topical non-steroidal anti-inflammatory drug (NSAID)

nepafenac 0.1% 3 times a day and tear substitutes 4 times per day. The antibiotic–steroid combination was tapered over 3–4 weeks while the NSAID was continued for 6–8 weeks to prevent the development of cystoid macular edema<sup>[23]</sup>

Statistical analysis: Demographic data and case details including visual acuity, type of PPC, complications were studied using descriptive statistics in form of frequency, mean, and standard deviation. For normally distributed measurable data, Student’s *t*-test and for non-normally distributed data Wilcoxon-signed rank test were used. *P* value < 0.05 was considered significant.

### Results

Mean age of the study cohort was 52.21 ± 14.49 years (range 12–86 years). Of the 64 patients included in the study, there were 33 (51.6%) males and 31 (48.4%) females. Seven patients (10.9%) were less than 35 years of age. Of the 80 operated eyes, 38 (47.5%) were right and 42 (52.5%) were left eyes. Eighteen (28.1%) patients presented with bilateral cataract and 46 (71.8%) with unilateral cataract.

Type 2, Type 3, and Type 4 cataract was seen in 34 eyes (42.5%), 20 eyes (25%) and 26 eyes (32.5%), respectively. Mean age of patients with type 2, type 3, and type 4 cataract was 44.48 ± 12.79 years, 48.64 ± 12.40 years, and 64.68 ± 12.83 years, respectively. The combined mean age of presentation of patients with type 2 and type 3 cataract (46.16 ± 12.66 years; *n* = 42 subjects) was significantly lower compared to patients with type 4 cataract (64.68 ± 12.83 years, *n* = 22 subjects) (*P* value:

<0.0001). Eight eyes (10%) of 7 patients had very dense type 4 cataracts with visual acuity limited to counting fingers close to face; in them the diagnosis of PPC was made on the basis of “onion peel” morphology of cataract which was visible on slit-lamp biomicroscopy. Ultrasonography (B scan) was however needed in these cases for evaluation of posterior segment as visualization of the fundus was inadequate.

Phacoemulsification was completed in 79 eyes. One patient had Fuch’s endothelial dystrophy with Type 4 posterior polar cataract and dense nuclear sclerosis. Due to intraoperative occurrence of zonular dehiscence, an intracapsular cataract extraction (ICCE) was performed and patient was left aphakic. Posterior capsular rupture was seen in 6 (7.6%) out of the 79 eyes in which phacoemulsification was completed.

Of these six eyes with PCR, four eyes had type 4 polar cataract and two eyes had type 2 polar cataract. Based on slit-lamp biomicroscopy, the existence of a posterior capsular dehiscence had been documented preoperatively in the clinical records, for the four eyes with type 4 PPC in whom the PCR was also documented during surgery. The mean age of these four patients was 61.5 years (range 55–70 years). Fig. 2c and 2d show a patient of Type 4 cataract preoperatively and an intraoperative image of PCR visible on retroillumination, respectively. Anterior vitrectomy was required in all these four cases because of associated vitreous disturbance. IOL was implanted in the sulcus in all these cases as the size of the capsular dehiscence was >50% of the anterior capsulorrhexis. The remaining two eyes had Type 2 posterior polar cataract in which PCR occurred intraoperatively during removal of the epinucleus. In these two eyes, anterior vitrectomy was required in one case with vitreous disturbance, whereas other case did not require vitrectomy because of intact vitreous phase. An “in the bag” implantation of the IOL was possible in these two eyes, the PCR being smaller in size. There was no case of nucleus drop in the present series. Postoperatively, four eyes had a persistent posterior capsular plaque. Intraocular lenses (IOLs) could be implanted in 79 of the 80 eyes operated (98.75% eyes) of which single piece hydrophobic acrylic IOLs were implanted in 36 (45%) eyes and three-piece hydrophobic acrylic IOLs in 38 (47.5%) eyes. Rigid PMMA IOLs were implanted in five (6.25%) eyes of five patients who were unable to afford foldable lenses due to financial constraints.

Mean CDVA improved significantly from a preoperative value of  $0.67 \pm 0.52$  log MAR to  $0.11 \pm 0.20$  log MAR at 3 months postoperatively ( $P < 0.001$ , Wilcoxon-signed ranks test). Overall 70 eyes (87.5%) achieved a CDVA of 20/40 or better, while 55 eyes (68.75%) achieved a CDVA of 20/20 or better. CDVA of 20/20 or better was achieved in 97% eyes (33 of 34) with Type 2 PPC, 90% eyes (18 of 20) with Type 3 PPC, and 73% eyes (19 of 26) with Type 4 PPC. In the six eyes with PCR, CDVA of 20/20 was achieved in three eyes (50%), 20/40 in one eye (16.7%), and 20/60 in two eyes (33.3%). None of the eyes developed any delayed posterior segment complications, for example, cystoid macular edema or retinal detachment. Table 1 shows the distribution of cases according to the type of cataract and visual outcome.

## Discussion

The chief complaint in patients with PPC is reduced vision in bright sunlight and glare and haloes especially when exposed to strong sources of focussed light, for example, headlights of oncoming vehicles. Quality of life may thus be impaired

**Table 1: Distribution of cases according to the Type of PPC and visual outcome**

Type of cataract	No of eyes (%)	Postoperative BCVA 20/20 or better
2	34 (42.5%)	33 (97%)
3	20 (25%)	18 (90%)
4	26 (32.5%)	19 (73%)

significantly, relatively early on in the disease process even though visual acuity under high contrast testing conditions may still be good. Performing surgery in PPC without disrupting the integrity of the posterior capsule thus remains a constant challenge. Due to the inherent weakness/absence of the posterior capsule in PPC, a rupture can occur at every step including hydroprocedures, nuclear rotation, phacoemulsification, and cortical aspiration.

Variable incidence of capsular rupture has been reported in literature for posterior polar cataracts. Osher *et al.*<sup>[7]</sup> reported a 26% incidence in a series of 31 eyes while Vasavada and colleagues reported a 36% incidence in a series of 22 eyes.<sup>[8]</sup> Hayashi *et al.*<sup>[10]</sup> have reported posterior capsule tear occurring in 7.1% of 28 eyes while HariPriya *et al.*<sup>[11]</sup> reported PCR in 12.5% cases in a series of eight patients. The present study showed a lower PCR rate of 7.6% which is lower than most reported series of posterior polar cataracts. If cases of pre-existing PCR, that is, the four eyes documented preoperatively on slit-lamp biomicroscopy to have a capsular dehiscence are excluded, the actual “intraoperative” incidence of PCR in the present series was only 2.5% (2 of 80 eyes). The lower incidence of PCR in our series may be attributed to all patients being operated upon by a single surgeon (AKJ) with meticulous attention being paid to intraoperative surgical precautions (e.g., lowering of machine parameters and avoidance of sudden anterior chamber shallowing by using dispersive viscoelastic) as well as combining the nuances of multiple techniques which have been previously described to reduce the incidence of PCR in polar cataracts. These include a guarded, limited, slow hydrodelineation (instead of hydrodissection), using nucleotomy techniques which purportedly have the advantage of not stretching the capsule while removing the pieces,<sup>[16,17]</sup> and viscodissection for removal of epinuclear plate. In the present series, the “lambda technique” was reserved for type 4 posterior polar cataracts and the “V” groove nucleotomy for Type 2 and Type 3 PPC. The rationale for this subtle variation in the nucleotomy technique was that in Type 4 cataracts (where the polar opacity is associated with nuclear sclerosis and hence are likely to be harder than type 2 and type 3 PPC), removal of the smaller piece between the two oblique arms of the lambda would occur without causing undue anteroposterior or lateral stretch of the capsule, and make the subsequent manoeuvres easier because of the enhanced space in the capsular bag. On the contrary, creating the lambda groove in the softer type 2 and type 3 cataracts could inadvertently increase the risk of the tip of the phacoprobe going deeper than intended in the endonucleus (and perhaps also across the epinucleus) at the junction of the three limbs of the lambda ( $\lambda$ ), that is, the vertical and the two oblique arms while the “V” groove with only a single point of convergence at the apex of the V would be associated with a relatively lower risk. Apart from the four eyes with type 4 PPC, where a pre-existing PCR was suspected and confirmed intraoperatively, the authors did not encounter



**Table 2: Comparison of Present Study Outcome with other Studies**

Authors	Technique	Total no of eyes in series	PCR rate	Other outcomes
Osher <i>et al.</i> <sup>[7]</sup>	Low power, low infusion, slow-motion phaco (+ hydrodissection)	31	26% (8 eyes)	Vitreous loss 13% (4/31) Decentred IOL 6% (2/31)
Vasavada and Singh <sup>[8]</sup>	Delineation	25	36% (9 eyes)	
Hayashi <i>et al.</i> <sup>[10]</sup>	Delineation	25	8% (2 eyes)	RD 7% (2/28) Dropped nucleus 4% (1/25)
Lee and Lee <sup>[16]</sup>	'Lambda technique' for nucleus removal	36	11.1% (4 eyes)	
Vasavada and Raj <sup>[15]</sup>	Inside out delineation	25	8% (2 eyes)	Dropped nucleus 4% (1/25)
Haripriya <i>et al.</i> <sup>[11]</sup>	Bimanual microphaco	8	12.5% (1 eye)	
Saitiri H <sup>[12]</sup>	Hydrodissection-free phacoemulsification technique'	38	0	-
Das <i>et al.</i> <sup>[13]</sup>		81	31% (25 eyes)	Dropped nucleus 3% (2/81)
Our Series	V or lambda sculpting, <sup>[4,16]</sup> Viscodissection of epinucleus <sup>[18]</sup>	80	7.5% (6 eyes) Pre-existing in 4 eyes Intraoperative in 2 eyes 'On table PCR'- 2.6%	Nucleus drop- Nil Decentred IOL- Nil Aphakia - 1.25% (1/80)

any other incidence of PCR in any of the eyes where the "lambda" technique was used. Lee *et al.*<sup>[16]</sup> originally described the "lambda" technique, in which nucleus was sculpted in the shape of a Greek letter lambda ( $\lambda$ ), followed by cracking along both "arms" and removal of the central piece reported PCR in 4 out of 36 eyes (11.1%). The incidence of PCR was apparently higher with the lambda ( $\lambda$ ) technique of nucleotomy (4 of 25 eyes with type 4 PPC [excluding one eye which had zonular dialysis]; PCR rate = 16% eyes) vis-a-vis the "V" groove technique (2 of 54 eyes with type 2 and type 3 PPC; PCR rate = 3.7%). However, this difference in all probability reflects the greater predilection of type 4 PPCs to be associated with posterior capsular dehiscence (as also noted preoperatively in all four eyes) as compared to type 2 and type 3 PPCs and hence is not a true reflection of safety of this technique.

All the cases of PCR with vitreous disturbance in the present series were managed with anterior vitrectomy and depending on the size of the PCR, a three-piece acrylic IOL was implanted either in the sulcus with the optic capture into the capsular bag (4 eyes) or in the bag (2 eyes). The incidence of nucleus drops and retinal detachment in different series has been reported to vary from 0 to 4%<sup>[8,10,16,24]</sup> and 0 to 7.1%<sup>[8,10,24]</sup> respectively. A study by Osher *et al.*<sup>[7]</sup> had studied 31 eyes and found PCR in 26% cases, vitreous loss in 13%, and decentred IOL in 6% cases. None of the cases in the present series had nucleus drop, vitreous prolapse into the anterior chamber, or decentered IOL postoperatively. However, 5% cases had residual posterior capsular plaques which were later managed with Nd:YAG laser capsulotomy. Table 2 lists the comparison of present study with other studies.

The use of femtosecond laser-assisted cataract surgery (FLACS) for PPC is increasingly being reported.<sup>[25-27]</sup> However, there is controversy regarding the safety of FLACS over conventional phacoemulsification for PPC. A case report by Alder *et al.*<sup>[25]</sup> comparing traditional phacoemulsification versus FLACS in PPC found posterior capsular tear in one eye each of 2 patients operated using femtosecond laser in comparison to the contralateral eyes which had an uneventful intraoperative course with traditional phacoemulsification. They hypothesized that femtolaser surgery-associated PCR

was secondary to cavitation bubbles getting trapped behind the lens material or hydrodelineation not occurring through the usual planes leading to inadvertent hydrodissection. Recently, Vasavada *et al.*<sup>[26]</sup> described a technique of femtodelineation in which femtosecond laser was used with cylindrical pattern to create multiple cylinders in the lens with the number, diameter, and depth of each cylinder being customized by the surgeon aided by the live anterior segment optical coherence tomography (ASOCT) view. The nucleus was emulsified without performing hydroprocedure and they reported PCR rate of 4.4% (in 2 patients out of 45). Titiyal *et al.*<sup>[27]</sup> have also recently described a femtosecond laser-assisted hybrid technique of three cylinders and three chops for such cases in which they found 100% success rate in 25 eyes without any case of PCR and all eyes were implanted with IOL in capsular bag. Though FLACS may become the preferred technique for routine as well as complicated cataract surgeries in the future, at the present time, its widespread use is limited by the relatively higher cost as well as lack of access to femtosecond laser technology for a majority of the cataract surgeons in developing countries like India. Hence, the need for adopting a meticulous technique and ensuring safer outcomes with conventional phacoemulsification cannot be overemphasized.

**Limitations:** The authors would like to acknowledge certain limitations of the study. Being retrospective in nature, data about the size of the polar opacity was not available for a majority of the patients and hence is not reported in the results. Polar cataracts of >4 mm in size have been reported to have nearly five times higher risk of intraoperative capsular dehiscence vis-a-vis cataracts <4 mm in diameter.<sup>[24]</sup> ASOCT which has been shown to have a reasonably high sensitivity (87.5–100%) and specificity (62–94.9%)<sup>[28,29]</sup> to preoperatively detect posterior capsular dehiscence was also not done due to lack of availability of OCT technology with penetration sufficient enough to image the posterior lens capsule, during the period when the patients included in the study were operated.

## Conclusion

The rate of posterior capsular ruptures in the present series were lower than most published studies, which the authors believe is

a summative effect of combining the techniques which have been described in literature over time to tackle posterior polar cataracts more safely and effectively. Managing posterior polar cataracts always remains a challenge, and advancements in diagnostic and operative technology, that is, ASOCT and FLACS will help the surgeons to better prognosticate the cases preoperatively, as well as make the intraoperative events more predictable. However, the authors would like to reemphasize that given the socioeconomic milieu of our country where a majority of cataract surgeons may not have easy access to the sophisticated equipments, polar cataracts can still be managed very effectively by adopting techniques at every step of phacoemulsification which help to minimize the occurrence of posterior capsular dehiscence.

#### Financial support and sponsorship

Nil.

#### Conflicts of interest

There are no conflicts of interest.

#### References

- Duke Elder S. System of Ophthalmology. 1<sup>st</sup> ed, vol III. Mosby: The CV. Mosby Company; 1974. p. 723.
- Gifford SR. Congenital anomalies of the lens as seen with the slit lamp. *Am J Ophthalmol* 1924;7:678-85.
- Greeves RA. Two cases of microphthalmia. *Trans Ophthalmol Soc UK* 1914;34:289-300.
- Szily AV. The Doyné memorial lecture: The contribution of pathological examination to elucidation of the problems of cataract. *Trans Ophthalmol Soc UK* 1938;58:595-660.
- Addison PK, Berry V, Ionides AC, Francis PJ, Bhattacharya SS, Moore AT. Posterior polar cataract is the predominant consequence of a recurrent mutation in the PITX3 gene. *Br J Ophthalmol* 2005;89:138-41.
- Berry V, Francis P, Reddy MA, Collyer D, Vithana E, MacKay I, *et al.* Alpha-B Crystallin Gene (CRYAB) mutation causes dominant congenital posterior polar cataract in humans. *Am J Hum Genet* 2001;69:1141-5.
- Osher RH, Yu BC, Koch DD. Posterior polar cataracts: A predisposition to intraoperative posterior capsular rupture. *J Cataract Refract Surg* 1990;16:157-62.
- Vasavada A, Singh R. Phacoemulsification in eyes with posterior polar cataract. *J Cataract Refract Surg* 1999;25:238-45.
- Hejtmancik JF, Datilios M. Congenital and inherited cataracts. In: Tasman W, Jaeger EA, editors. *Duane's Clinical Ophthalmology*. CD ROM ed, vol 1, chapter 74. Baltimore, Md.: Lippincott Williams & Wilkins; 2001.
- Hayashi K, Hayashi H, Nakao F, Hayashi F. Outcomes of surgery for posterior polar cataract. *J Cataract and Refract Surg* 2003;29:45-9.
- Haripriya A, Aravind S, Vadi K, Natchiar G. Bimanual microphaco for posterior polar cataracts. *J Cataract Refract Surg* 2006;32:914-7.
- Siatiri H, Moghimi S. Posterior polar cataract: Minimizing risk of posterior capsule rupture. *Eye* 2006;20:814-6.
- Das S, Khanna R, Mohiuddin SM, Ramamurthy B. Surgical and visual outcomes for posterior polar cataract. *Br J Ophthalmol* 2008;92:1476-8.
- Nagappa S, Das S, Kurian M, Braganza A, Shetty R, Shetty B. Modified technique for epinucleus removal in posterior polar cataract. *Ophthalmic Surg Lasers Imaging* 2011;42:78-80.
- Vasavada AR, Raj SM. Inside-out delineation. *J Cataract Refract Surg* 2004;30:1167-9.
- Lee MW, Lee YC. Phacoemulsification of posterior polar cataracts—A surgical challenge. *Br J Ophthalmol* 2003;87:1426-7.
- Kelman CD. V Groove phaco technique: Fast, easy, safe: Interview with Dr. Kelman. *Ophthalmology Times* 1994;19:12.
- Vajpayee RB, Sinha R, Singhvi A, Sharma N, Titiyal JS, Tandon R. 'Layer by layer' phacoemulsification in posterior polar cataract with pre-existing posterior capsular rent. *Eye (Lond)* 2008;22:1008-10.
- Allen D, Wood C. Minimizing risk to the capsule during surgery for posterior polar cataract. *J Cataract Refract Surg* 2002;28:742.
- Fine IH, Packer M, Hoffman RS. Management of posterior polar cataract. *J Cataract Refract Surg* 2003;29:16-9.
- Salahuddin A. Inverse horse-shoe technique for the phacoemulsification of posterior polar cataract. *Can J Ophthalmol* 2010;45:154-6.
- Masket S. Consultation section: Cataract surgical problem. *J Cataract Refract Surg* 1997;23:819-24.
- Kessel L, Tendal B, Jorgensen KJ, Erngaard D, Flesner P, Andresen JL, *et al.* Post-cataract prevention of inflammation and macular edema by steroid and nonsteroidal anti-inflammatory eye drops: A systematic review. *Ophthalmology* 2014;121:1915-24.
- Kumar S, Ram J, Sukhija J, Severia S. Phacoemulsification in posterior polar cataract: Does size of lens opacity affect surgical outcome. *Clin Exp Ophthalmol* 2010;38:857-61.
- Alder BD, Donaldson KE. Comparison of two techniques for managing posterior polar cataracts: Traditional phacoemulsification versus femtosecond laser-assisted cataract surgery. *J Cataract Refract Surg* 2014;40:2148-51.
- Vasavada AR, Vasavada V, Vasavada S, Srivastava S, Vasavada V, Raj S. Femtodelineation to enhance safety in posterior polar cataracts. *J Cataract Refract Surg* 2015;41:702-7.
- Titiyal JS, Kaur M, Sharma N. Femtosecond laser-assisted cataract surgery technique to enhance safety in posterior polar cataract. *J Refract Surg* 2015;31:826-8.
- Chan TC, Li EY, Yau JC. Application of anterior segment optical coherence tomography to identify eyes with posterior polar cataract at high risk for posterior capsular rupture. *J Cataract Refract Surg* 2014;40:2076-81.
- Kumar GP, Krishnamurthy P, Nath M, Baskaran P, Janani M, Venkatesh R. Can preoperative anterior segment optical coherence tomography predict posterior capsular rupture during phacoemulsification in patients with posterior polar cataract? *J Cataract Refract Surg* 2018;12:1441-5.