

Novel 3-Dimensional Imaging Analysis of the Ryan Procedure for Inframammary Fold Elevation in the Reconstruction of the Revised Breast

Casey T. Kraft, MD
 Juan L. Rendon, MD, PhD
 Cynthia A. Koutz, MS, PA-C
 Michael J. Miller, MD

Summary: The inframammary fold (IMF) can be challenging to reconstruct after disruption during mastectomy or breast reconstruction. The Ryan procedure is a previously described technique with little long-term analysis. Our goal is to analyze the long-term results of the Ryan procedure using 3-dimensional (3D) technology, with the hypothesis that 3D measurements will provide quantitative outcomes that add to the qualitative assessment of the reconstruction. We retrospectively reviewed consecutive breast reconstruction patients by a single surgeon from January 1, 2012 to January 31, 2015 to identify patients who underwent the Ryan procedure. Previously obtained 3D photographs were then analyzed to compare breast base diameter, breast projection, and inter-IMF distance pre- and postoperatively. A survey was then given to 15 health professionals in our department to assess the IMF and symmetry pre- and postoperatively. Eight patients were eligible for inclusion. Four patients were unilateral reconstruction and 4 were bilateral. The Ryan procedure resulted in an inter-IMF discrepancy reduction of 39% and a breast projection increase of 18%. Average length of follow-up was 2.82 ± 0.75 years. One patient required a secondary IMF revision. The majority of survey respondents felt that the IMF and IMF symmetry were improved or stable postoperatively. The Ryan procedure seems to be a reliable and durable technique for IMF reconstruction with increased projection, decreased IMF discrepancy, and increased symmetry. Additionally, 3D imaging provides a useful approach in the assessment of breast reconstruction outcomes, adding quantitative outcomes measures to its evaluation. (*Plast Reconstr Surg Glob Open* 2019;7:e2287; doi: 10.1097/GOX.0000000000002287; Published online 24 July 2019.)

INTRODUCTION

The inframammary fold (IMF) is a critical component of the breast footprint and landmark in breast reconstruction. Significant disruption of the IMF profoundly impacts the overall aesthetic quality of reconstructed breasts and often requires secondary revision.^{1,2} Utilizing 3-dimensional (3D) imaging, we objectively analyze long-term outcomes following the Ryan procedure in secondary breast reconstruction.

The Ryan procedure was initially described in 1982 as one of the first methods of IMF reconstruction.³ The goal of the procedure is to restore definition and elevate the position of the IMF on the chest wall. The procedure is performed by creating a lower thoracic flap and advancing the flap onto the chest wall for creation of a neo-IMF.³ De-epithelialized skin flaps are folded on each other and anchored to the chest wall for the final result.³ Since its initial description, there has been no literature specifically assessing the reliability of the Ryan procedure for IMF reconstruction.

Three-dimensional imaging is a novel technique for assessing breast reconstruction outcomes. It is a validated, accurate method of assessing breast dimensions compared to in-person measurements and has been used for evaluating implant- and flap-based breast reconstruction.⁴⁻⁶ We used 3D imaging to objectively assess long-term outcomes following the Ryan procedure for IMF revision. Additionally, we designed a survey using these 3D images to evaluate the subjective aspects of the IMF reconstruction and correlate this with objective measurements.

From the Department of Plastic Surgery, The Ohio State University Wexner Medical Center, Columbus, Ohio.

Received for publication April 4, 2019; accepted April 12, 2019.

Copyright © 2019 The Authors. Published by Wolters Kluwer Health, Inc. on behalf of The American Society of Plastic Surgeons. This is an open-access article distributed under the terms of the Creative Commons Attribution-Non Commercial-No Derivatives License 4.0 (CCBY-NC-ND), where it is permissible to download and share the work provided it is properly cited. The work cannot be changed in any way or used commercially without permission from the journal.

DOI: 10.1097/GOX.0000000000002287

Disclosure: The authors have no financial interest to declare in relation to the content of this article.

METHODS

Patients who underwent IMF revision between January 1, 2012 and January 31, 2015 were retrospectively reviewed. Complications, including re-revision IMF surgery, and length of follow-up were recorded. Reconstruction type and laterality were recorded. Patient characteristics including age, body mass index, and comorbidities, such as smoking status, diabetes, and radiation therapy, were also collected.

Previously obtained pre- and postoperative 3D photographs were analyzed for objective measurements (Fig. 1). Photographs were taken using the Vectra 3D Imaging System and accompanying Mirror Imaging Software (Canfield Scientific, Parsippany, N.J.). The primary measurements obtained using the 3D images included discrepancy in IMF height, breast base diameter, and breast mound projection. These measurements were determined using the software's breast analysis calculator based on user-placed anatomic landmarks.

A survey was designed to obtain subjective evaluations of the reconstructed IMFs. The survey included multiple view 3D images of the patients in the study (**SDC1, see table, Supplemental Digital Content 1**, which displays a survey provided to medical professionals at our institution for evaluation of the IMF pre- and postoperatively to assess reconstruction, <http://links.lww.com/PRSGO/B134>). The survey was provided to 15 plastic surgery residents and

physician assistants to evaluate the IMFs' quality and symmetry pre- and postoperatively on a modified Likert scale.

RESULTS

Fourteen patients met inclusion criteria. There were no significant complications among all patients, and there was improvement in the IMF contour and symmetry following the procedure based on clinic records. Only 1 patient required further surgical revision. Average length of follow-up was 2.82 ± 0.75 years.

Pre- and postoperative 3D photographs were available for 8 patients. No patients had a history of diabetes or radiation, and 2 were former smokers. Three patients had an internal Ryan procedure performed, and 5 had an open Ryan procedure performed at the time of breast revision surgery. Seventy-five percentage of the patients reviewed had implant-based reconstruction. Six had objective improvement in IMF contour and symmetry on the basis of 3D photograph measurements. On average, IMF discrepancy was reduced by 39% and projection increased 18% (Table 1). Breast base diameter was minimally altered postoperatively.

Survey results were analyzed for a subjective comparison to the objective improvements noted. For all patients, the majority of those surveyed felt that the IMF quality and symmetry were either the same (25%) or improved (75%). Seven patients demonstrated an improvement in

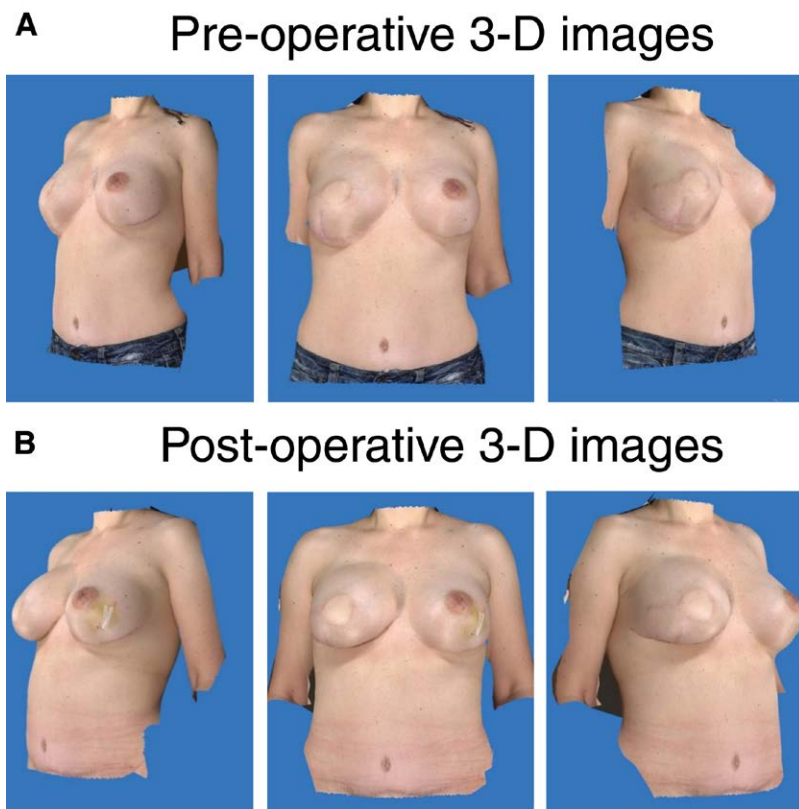


Fig. 1. Representative images of 3D photographs obtained after the Ryan procedure was performed for inframammary fold reconstruction. Similar photographs were provided for the survey administered as part of the study as well. A, Preoperative 3D images. B, Postoperative 3D images. 3D, 3-dimensional.

Table 1. Summary Table of Laterality of Reconstruction Performed and Pre- and Postoperative Measurements of IMF Discrepancy and Breast Projection, Also Included the Length of Stay from Ryan Procedure to Most Recent Clinic Visit

Patient	Laterality	Side	IMF Discrepancy Pre-operative, cm	IMF Discrepancy Post-operative, cm	Total Change, cm	Projection Pre-operative, cm	Projection Post-operative, cm	Total Change, cm	Base Diameter Pre-operative, cm	Base Diameter Post-operative, cm	Total Change, cm	Follow-up, d
1	Unilateral	Right	1.7	1.0	-0.7	9.4	9.2	-0.2	16.2	16.3	+0.1	1,524
2	Unilateral	Right	1.5	0.9	-0.6	7.5	6.9	-0.6	15.8	17.4	+1.6	1,362
3	Unilateral	Left	3.5	0.8	-2.7	9.2	11.4	+2.2	21.1	21.5	+0.4	1,079
4	Bilateral	Bilateral	0.7	0.1	-0.6	6.2, 6	9.3, 8.1	+3.1, +2.1	14.8, 13.5	13.6, 13.5	-1.2, 0	813
5	Bilateral	Bilateral	0.6	0.2	-0.4	5.5, 6.2	5.2, 6.2	-0.3, 0	12.7, 13.8	12.7, 13.3	0, -0.5	776
6	Bilateral	Bilateral	1.7	1.9	+0.2	8.1, 7.9	9.3, 9.1	+1.2, +1.2	16.6, 16.5	18.8, 18.5	+2.2, +2.0	895
7	Bilateral	Bilateral	1.8	1.4	-0.4	6.7, 6.6	9.3, 9.4	+2.6, +3.1	14.5, 14.4	14.3, 17	-0.2, +2.6	901
8	Unilateral	Left	0.5	1.0	+0.5	4.7	5.6	+0.9	12.9	13.2	+0.3	880

Table 2. Results of the Survey Provided to 15 Health Professionals in the Department of Plastic Surgery to Evaluate the IMF and Symmetry of the IMF Pre- and Postoperatively

Patient	Procedure	Side	IMF			Symmetry			Overall Reconstruction "Good" or "Excellent," %
			Improved	Same	Worse	Improved	Same	Worse	
Patient 1	Unilateral	Right	14	1	0	13	2	0	73
Patient 2	Unilateral	Right	5	10	0	4	10	1	87
Patient 3	Unilateral	Left	11	3	1	10	3	2	33
Patient 4	Bilateral	Bilateral	15, 15	0, 0	0, 0	14	1	0	80
Patient 5	Bilateral	Bilateral	15, 11	0, 4	0, 0	14	1	0	53
Patient 6	Bilateral	Bilateral	9, 14	3, 1	3, 0	10	5	0	27
Patient 7	Bilateral	Bilateral	10, 8	3, 6	2, 1	13	2	0	27
Patient 8	Unilateral	Left	8	6	1	6	7	2	87

either IMF quality or symmetry on the basis of survey responses (Table 2).

DISCUSSION

Pennisi first reported a method for IMF reconstruction utilizing de-epithelialized skin flaps in 1977.⁷ Ryan followed with his method in 1982.³ In addition to IMF elevation, the Ryan procedure can improve breast symmetry by elevating the reconstructed breast to the level of the native breast. Additionally, breasts with IMF loss may seem flatter, and breast projection may improve after the procedure by reducing the total area for breast tissue to sit on the chest wall.

Since the time of Ryan and Pennisi's original descriptions, several other methods of reconstruction for the IMF have been postulated, ranging from flap- and suture-based procedures to using external guiding appliances.⁸⁻¹⁷ Despite the numerous methods available, no articles have critically analyzed these methods, with the only results reported being in the initial descriptions.

Our goal with this study was to assess the reliability and durability of the Ryan procedure for IMF reconstruction and analyze both objective and subjective results using 3D imaging and a survey of medical professionals. Our 3D imaging results demonstrate objective improvement in the symmetry and quality of the IMF, and breast projection following the procedure. Our survey results

demonstrate subjective improvement that correlates with the objective improvement. Our long-term follow-up demonstrates the Ryan procedure's durability. We also show that revision rates are low, and similar to those reported for other methods of reconstruction.^{3,7,8} There is some concern with the Ryan flap that increased scarring may affect the aesthetics or vascularity of the breast, although we have not found this to be the case. Additionally, scarring can be minimized by placing the incisions in previously created scars.

We acknowledge that there are some limitations to this study. Our small patient sample size precludes definitive statements regarding the efficacy of the Ryan procedure or statistical analysis. Additionally, measurements were based on user-placed landmarks, which may be prone to some error in placement. This was minimized by having a single user perform all landmark placements and obtaining measurements, although this introduces its own bias as well.

CONCLUSIONS

The Ryan procedure is an infrequently reported but valuable tool for IMF reconstruction. The Ryan procedure seems to be reliable, efficacious, and durable for secondary breast surgery, with objective improvements correlating to subjective improvement in the reconstruction. Understanding the long-term outcomes of the Ryan

procedure can allow surgeons to use it to achieve better symmetry and aesthetics of the reconstructed breast.

Michael J. Miller, MD

Department of Plastic Surgery
The Ohio State University Medical Center
915 Olentangy River Rd, Suite 2100
Columbus, OH 43212.

REFERENCES

1. Kim MS, Sbalchiero JC, Reece GP, et al. Assessment of breast aesthetics. *Plast Reconstr Surg*. 2008;121:186e–194e.
2. Blondeel PN, Hijjawi J, Depypere H, et al. Shaping the breast in aesthetic and reconstructive breast surgery: an easy three-step principle. *Plast Reconstr Surg*. 2009;123:455–462.
3. Ryan JJ. A lower thoracic advancement flap in breast reconstruction after mastectomy. *Plast Reconstr Surg*. 1982;70:153–160.
4. Losken A, Seify H, Denson DD, et al. Validating three-dimensional imaging of the breast. *Ann Plast Surg*. 2005;54:471–476; discussion 477.
5. Tepper OM, Karp NS, Small K, et al. Three-dimensional imaging provides valuable clinical data to aid in unilateral tissue expander-implant breast reconstruction. *Breast J*. 2008;14:543–550.
6. Henseler H, Smith J, Bowman A, et al. Objective evaluation of the latissimus dorsi flap for breast reconstruction using three-dimensional imaging. *J Plast Reconstr Aesthet Surg*. 2012;65:1209–1215.
7. Pennisi VR. Making a definite inframammary fold under a reconstructed breast. *Plast Reconstr Surg*. 1977;60:523–525.
8. Versaci AD. A method of reconstructing a pendulous breast utilizing the tissue expander. *Plast Reconstr Surg*. 1987;80:387–395.
9. Terao Y, Taniguchi K, Tomita S. A new method for inframammary fold recreation using a barbed suture. *Aesthetic Plast Surg*. 2015;39:379–385.
10. Handel N, Jensen JA. An improved technique for creation of the inframammary fold in silicone implant breast reconstruction. *Plast Reconstr Surg*. 1992;89:558–562.
11. Chun YS, Pribaz JJ. A simple guide to inframammary-fold reconstruction. *Ann Plast Surg*. 2005;55:8–11; discussion 11.
12. Buccheri EM, Zoccali G, Costantini M, et al. Breast reconstruction and inframammary fold reconstruction: a versatile new technique. *J Plast Reconstr Aesthet Surg*. 2015;68:742–743.
13. Nava M, Quattrone P, Riggio E. Focus on the breast fascial system: a new approach for inframammary fold reconstruction. *Plast Reconstr Surg*. 1998;102:1034–1045.
14. Persichetti P, Langella M, Filoni A, et al. How to redefine the inframammary fold: the “slingshot” capsular flap. *Ann Plast Surg*. 2013;70:636–638.
15. Sarfati B, Honart JF, Guimond C, et al. Inframammary fold reconstruction: the “hammock” technique. *J Plast Reconstr Aesthet Surg*. 2015;68:433–434.
16. Ching JA, Dayicioglu D. The stylet technique for inframammary fold definition in breast reconstruction. *J Plast Reconstr Aesthet Surg*. 2014;67:273–275.
17. Akhavan M, Sadri A, Ovens L, et al. The use of a template to accurately position the inframammary fold in breast reconstruction. *J Plast Reconstr Aesthet Surg*. 2011;64:e259–e261.