



Letter

Repair of a small and crooked vesicovaginal fistula using electrocauterization



Dear Editor,

Vesicovaginal fistula (VVF) is an abnormal opening between the urinary bladder and the vagina. The condition has an immense psychological effect on patients due to the continuous leakage of urine or watery vaginal discharge. The wet feeling and foul smell associated with leakage of urine cause social outcasting of the patients. This leads to immense emotional trauma and makes life miserable for the patient. The most common etiology for VVF in developing countries is obstructed labour [1], and in developed countries, it is abdominal hysterectomy [2]. VVF poses a challenging problem to the surgeon. The location and the size of the fistula determine the extent of the patients' symptoms.

The transvaginal and abdominal routes (open, laparoscopic, or robotic) are the two approaches currently in vogue for the repair of VVF. However, some surgical procedures for fistula repair may worsen the situation for these patients. The appropriate surgical procedure needs to be chosen based on the particular condition of the fistula. The two patients in our research study, who have a small and crooked VVF, showed a poor prognosis after a cystoscopic holmium laser ablation. Therefore, electrocauterization was tried on them.

The objective of the present study is to describe the management of a small and crooked VVF using electrocauterization, with the specific aims of avoiding the disadvantages associated with using the abdominal route, thereby minimizing the surgical trauma and maximizing the prognosis.

Two women admitted to Peking University People's Hospital with vesicovaginal fistula were recruited for this study. The demographic information of the patients was shown in Table 1. They had a history of multiple uterine fibroids and endometriosis and underwent a hysterectomy. The patients developed continuous dribbling of urine 1 month after the operation, which was associated with position change and an increase of abdominal pressure. Physical symptoms and any illness were assessed prior to surgery. A speculum examination of both patients did not

reveal a distinct fistulous tract or leakage of fluid in the vagina. A vaginal methylene blue test was positive for both patients. Cystourethroscopy was performed and identified a small VVF with a diameter of 0.2 cm in one patient and 0.3 cm in the other patient, and both of the fistulas were located at the posterior wall of the bladder. A gynecological glimpse in both of the patients did not reveal any fistula. Furthermore, a methylene blue test could suggest only an outflow but not a fistula at the side of the vagina, so we concluded that the locations of the fistula in both patients were on the upper side of the vagina. A ureteral catheter from the fistula on the side of bladder to the vagina could not go straight through the fistula, which demonstrated that the fistula was crooked. The length of the ureteral catheter that was inserted into the fistula was recorded. Then a cystography was used to assess the two patients, and the image was that of a VVF (Fig. 1).

One patient underwent a fistula repair with laser ablation, but it failed. The laser ablation was performed vaginally, but the power was too high to cure the fistula, so the patient did not feel dry after the procedure. Subsequently, the two patients underwent repair of the VVF using electrocauterization. After epidural anesthesia, the perineum and vagina were disinfected regularly. A 70° cystoscope was implanted into the bladder, and a fistula was identified. A monopolefiliform electrode was stretched into the fistula, and the depth reflected the length of the ureteral catheter that was inserted into the fistula. The power was set to 20–30 W. The electrode was backed out while electrocoagulating the whole length of the fistula. The surrounding

Table 1 The basic information of the two patients.

	Patient A	Patient B
Age (year)	51	45
BMI (kg/m ²)	24.21	25.42
Reason for hysterectomy	Endometriosis	Multiple uterine fibroids
Surgery procedure for hysterectomy	Laparoscopic	Open
Time at which the fistula appeared	1 month after hysterectomy	1 month after hysterectomy
Diameter of fistula (cm)	0.2	0.3

BMI, body mass index.

<https://doi.org/10.1016/j.ajur.2018.01.004>

2214-3882/© 2018 Editorial Office of Asian Journal of Urology. Production and hosting by Elsevier B.V. This is an open access article under the CC BY-NC-ND license (<http://creativecommons.org/licenses/by-nc-nd/4.0/>).

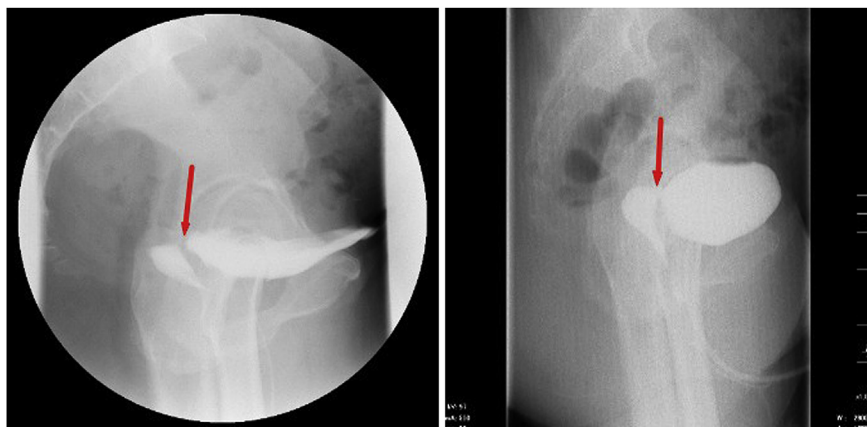


Figure 1 The cystography of the two patients. Red arrows indicate the position of fistula.

tissue of the fistula opening at the side of the bladder was enhanced by electrocoagulation. After careful hemostasis and observation on ureteric jets, double-J catheters were placed bilaterally into the ureters. One patient left the hospital with indwelling ureteral catheters, which were removed 2 weeks later, while the other patient left the hospital without ureteral catheters.

One month after discharge, the two patients returned to the hospital for follow-up. One patient felt dry, and she was highly satisfied with the outcome. The other patient reported improvement but was still damp. A second operation, which was the same as the first, was performed for the second patient. She was discharged without ureteral catheters and followed up 1 month later. She reported no urinary leakage this time. A cystourethroscopy was performed for both patients and revealed a healing bladder mucosa in both patients.

The two patients were followed up every 6 months for 4 years, during which they never reported a reoccurrence of the fistula.

The two cases of VVF reported here were both caused by hysterectomy. During the hysterectomy procedure, a possible cystectomy may occur while dissecting the bladder from the anterior uterine surface, thus forming a vesicovaginal fistula.

A cross-sectional, prospective study sought to assess the quality of life of women with surgical repair of their VVF. The conclusions suggested that the successful repair of VVF was associated with a significant improvement in the multidimensional quality of life among affected women [3]. Fistula patients experiencing improvements in their mental health at 3 months after discharge were also mentioned in another study [4]. Therefore, a proper method of management seems to be important.

For a small and crooked fistula, abdominal surgery will lead to too much trauma and too many complications, and its outcome is not equal to the severity of the condition. Thus, a transvaginal procedure is preferred. In our study, electrocauterization ablated the epithelial tissue of the fistula and stimulated the regeneration of epithelial tissue, which healed the urinary bladder epithelium and vaginal squamous

epithelium, respectively. All of this contributed to the closure of the fistula. During the procedure, the power needed to be not too high, since an excessively high power would cause too much tissue damage for it to heal. Further studies involving a larger number of patients are recommended for determining the long-term outcomes of this technique.

Conflicts of interest

The authors declare no conflict of interest.

References

- [1] Hilton P, Ward A. Epidemiological and surgical aspects of urogenital fistulae: a review of 25 years' experience in southeast Nigeria. *Int Urogynecol J Pelvic Floor Dysfunct* 1998;9:189–94.
- [2] Miller EA, Webster GD. Current management of vesicovaginal fistulae. *Curr Opin Urol* 2001;11:417–21.
- [3] Umoiyoho AJ, Inyang-Etoh EC, Abah GM, Abasiattai AM, Akaiso OE. Quality of life following successful repair of vesicovaginal fistula in Nigeria. *Rural Rem Health* 2011;11:1734.
- [4] Sarah MW, Kathleen JS, Melissa HW, Masenga GG, Moshia MV. Psychological symptoms and social functioning following repair of obstetric fistula in a low-income setting. *Matern Child Health J* 2016;20:941–5.

Weiyu Zhang
Kexin Xu*
Xiaopeng Zhang
Hao Hu
Qi Wang
*Department of Urology,
Peking University People's Hospital,
Beijing, China*

*Corresponding author.
E-mail address: cavinx@sina.com (K. Xu)

22 September 2016
Available online 1 February 2018