

First Human Infection of *Nocardia Crassostreae* in an Immunocompetent Patient

Usiakimi Igbaseimokumo¹, Sittana El Shafie², Abdul Latif Al Khal³

¹Department of Neurosurgery, University of Missouri–Kansas City School of Medicine, Children’s Mercy Hospital, Kansas City, MO 64108, USA

²Department of Medical Microbiology, Hamad Hospital, Doha, Qatar

³Department of Medicine, Hamad Hospital, Doha, Qatar

To the Editor: *Nocardia* species are Gram-positive partially acid-fast *Bacilli* that are found in soil and water. Nocardial brain abscess is rare but carries a high fatality rate, and there is controversy in literature whether these lesions should be routinely excised or simply aspirated.^[1] The first case of *Nocardia crassostreae* brain abscess in a 31-year-old immunocompetent male is reported here to highlight this emerging pathogen and the antimicrobial sensitivity. He presented with a 1-week history of progressive right hemiparesis. He regularly swam in the open sea and had a cut on his right big toe while swimming. His temperature was 36.2°C. He was alert and orientated with grade 4 Medical Research Council weakness in the right upper limb and grade 2 in the right lower limb, with brisk (3+) reflexes. The magnetic resonance imaging (MRI) of the brain showed an abscess [Figure 1a]. His white blood count including lymphocytes with differentials was normal, and blood cultures were negative. He had a normal chest radiograph.

A computed tomography-guided stereotactic aspiration yielded creamy nonoffensive pus. Laboratory examination of the pus showed Gram-positive *Bacilli*, and a modified Ziehl–Neelsen stain showed partially acid-fast *Bacilli* without true branching. Rough white colonies grew in blood agar aerobically within 48 h. The antimicrobial susceptibility of the isolate (Etest, AB Biodisc, Solna, Sweden) was shown in Table 1. It was identified by polymerase chain reaction and 16S ribosomal DNA sequence analysis as *N. crassostreae*. The patient was treated with oral clarithromycin and ciprofloxacin. He regained full power in 4 weeks with excellent radiological resolution on MRI [Figure 1b]. He was discharged from outpatient follow-up after 1-year and did not show any evidence of immunocompromise.

The portal of entry for the organism is likely to be the cut, he sustained while swimming. Therefore, it is postulated that antigen-specific T-cells and macrophages of the immunocompetent host cleared the peripheral foci, whereas any organism that successfully invades the brain is relatively protected from these activated cells (an immune sanctuary).^[2]

This organism was most susceptible to β -lactam antibiotics, and the tetracyclines but resistant to vancomycin and teicoplanin [Table 1]

Table 1: Drug susceptibility of *Nocardia crassostreae* isolated from the patient (Etest, AB Biodisc, Solna, Sweden)

Antimicrobial agent	Susceptibility
Penicillin G	S
Amoxicillin	S
Co-amoxiclav	S
Mezlocillin	S
Piperacillin	S
Cefaclor	S
Cefuroxime	S
Cefuroxime axetil	S
Imipenem	S
Meropenem	S
Gentamicin	I
Tobramycin	I
Netilmicin	I
Amikacin	I
Ciprofloxacin	S
Ofloxacin	S
Levofloxacin	S
Tetracycline	S
Doxycycline	S
Erythromycin	S
Clindamycin	R
Vancomycin	R
Teicoplanin	R

S: Susceptible; I: Intermediate; R: Resistant.

Address for correspondence: Dr. Usiakimi Igbaseimokumo, Department of Neurosurgery, University of Missouri–Kansas City School of Medicine, Children’s Mercy Hospital, 2401 Gillham Road, Kansas City, MO 64108, USA
E-Mail: uigbaseimokumo@cmh.edu

This is an open access article distributed under the terms of the Creative Commons Attribution-NonCommercial-ShareAlike 3.0 License, which allows others to remix, tweak, and build upon the work non-commercially, as long as the author is credited and the new creations are licensed under the identical terms.

© 2015 Chinese Medical Journal | Produced by Wolters Kluwer - Medknow

Received: 12-09-2015 **Edited by:** Peng Lyu
How to cite this article: Igbaseimokumo U, El Shafie S, Al Khal AL. First Human Infection of *Nocardia Crassostreae* in an Immunocompetent Patient. Chin Med J 2016;129:114-5.

Access this article online

Quick Response Code:



Website:
www.cmj.org

DOI:
10.4103/0366-6999.172609

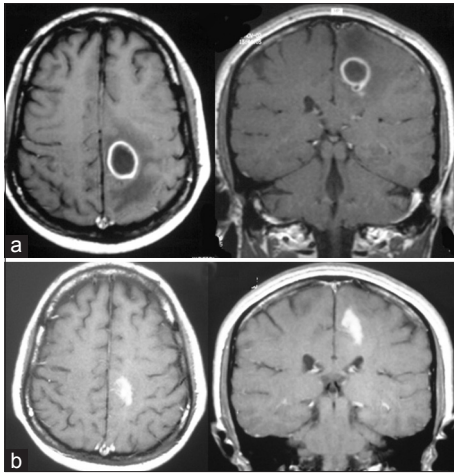


Figure 1: Axial T1-weighted postcontrast magnetic resonance imaging scan ring enhancing lesion at presentation (a) and 4 weeks after treatment (b).

and in this respect did not fit any of the patterns identified by Wallace *et al.* for *Nocardia asteroides* which caused the majority of human *Nocardia* infections.^[3] It also differs from the only other case reported in humans while this manuscript was in preparation.^[4] In

conclusion, this unique case is presented to allow other clinicians to learn from the outcome of this case, and the antimicrobial sensitivity which maybe variable.

Financial support and sponsorship

Nil.

Conflicts of interest

There are no conflicts of interest.

REFERENCES

1. Mamelak AN, Obana WG, Flaherty JF, Rosenblum ML. Nocardial brain abscess: Treatment strategies and factors influencing outcome. *Neurosurgery* 1994;35:622-31. doi: 10.1227/00006123-199410000-00007.
2. Gendelman H, Rappaport J, Hickey W. The blood-brain barrier: Defensive shield or a perpetrator of microbial invasion? *J Neurovirol* 1999;5:533-7. doi: 10.3109/13550289909021283.
3. Wallace RJ Jr, Steele LC, Sumter G, Smith JM. Antimicrobial susceptibility patterns of *Nocardia asteroides*. *Antimicrob Agents Chemother* 1988;32:1776-9. doi: 10.1128/AAC.32.12.1776.
4. Taj-Aldeen SJ, Deshmukh A, Doiphode S, Wahab AA, Allangawi M, Almuzrkchi A, *et al.* Molecular identification and susceptibility pattern of clinical *Nocardia* species: Emergence of *Nocardia crassostreae* as an agent of invasive nocardiosis. *Can J Infect Dis Med Microbiol* 2013;24:e33-8.