

Total talar prosthesis with and without ankle ligament reconstruction using the three-dimensional computer-aided design and computer numerical control manufacturing techniques

Chayanin Anghong,¹
Prasit Rajbhandari²

¹Orthopaedic Service, Faculty of Medicine, King Mongkut's Institute of Technology Ladkrabang, Bangkok, Thailand; ²Department of Orthopaedics, Manmohan Memorial Medical College and Teaching Hospital, Kathmandu, Nepal

Abstract

Severe damage and bone loss of the talus are problematic issues because of its unique shape, function, and characteristics. This present study's objective is to propose the process of customized total talar prosthesis manufacturing, using three-dimensional (3D) Computer-Aided Design (CAD) with Computer Numerical Control (CNC) production along with evaluation of the results of total talar prosthesis replacement with or without ankle ligament reconstruction in patients with severe conditions of talus. The case series included five patients (mean age: 27.6 years) with severe talar loss or damage. The mean follow-up time was 17.8±8.4 months. Related complications were: i) mild subsidence in 1 patient (20%) and ii) peri-prosthetic fracture in another patient (20%). The mean clinical scores including VAS-FA and SF-36 were improved following surgeries. Customized total talar prosthesis appears to provide satisfactory outcomes for the treatment of severe talar loss or damage at a short-term follow-up.

Introduction

The talus is a spectacular bone in humans. Its shape is unique, with majority of its surface area being articulated to the tibiotalar, subtalar, and talonavicular joints. Therefore, the talar functions not only in load distribution from the leg to the foot but also perform the necessary synchronized motions between the aforementioned joints. While the talus works very well in its native features, its stability in the mortise and other articulations are derived from its intrinsic

anatomy and the surrounding structures including the ligaments and bones. Therefore, severe conditions of the talus (severe talar loss, avascular necrosis, and large tumors) are problematic issues due to its unique shape, function, and characteristics. These pathologies present unique challenges to reproduce the native concerns,¹⁻³ to date a total talar prosthesis has been developed to mimic the talar anatomy in an aim to increase the possibility of recovering normal talar function and character.

The present study proposes the process of customizing total talar prosthesis manufacturing using the three-dimensional (3D) Computer-Aided Design (CAD) with Computer Numerical Control (CNC) production that includes evaluation of the results of total talar prosthesis replacement with or without ankle ligament reconstruction in patients with severe conditions of talus.

Case Report

A total of five patients (mean age: 27.6±12.7 years) with severe talar loss or damage were recruited for this study (Figure 1). All patients underwent a customized total talar prosthesis replacement. Each implant was manufactured via three-dimensional computed tomography imaging of the contralateral talus with CAD, by processing the mirror image of the injured or damaged side, and development with medical grade material (Figure 2), via the CNC technique (stainless steel 4 cases and titanium 1 case; Table 1).

Baseline clinical and radiographic data, including Visual Analog Scale Foot and Ankle (VAS-FA) (0=worst; 100=best)⁴ and Health-related Quality of Life via Short-Form 36 (SF-36) scores (0=worst; 100 = best)⁵ were collected for all patients. All patients involved provided informed consent for this report.

The stepwise approach was performed in all the patients in the present series. The patients with post-traumatic conditions underwent staging procedures. First, initial operations consisted of debridement with antibiotic cement spacers and soft-tissue coverage in cases with open injury. All post-traumatic patients underwent the joint-spanning external fixation to maintain the tibio-calcaneal space using non-circular (Figure 1) or circular external fixators. The second stage was a total talar prosthesis replacement, with or without, ankle ligament reconstruction. For the patients with secondary conditions, such as talar tumors,

Correspondence: Chayanin Anghong, Orthopaedic Service, Faculty of Medicine, King Mongkut's Institute of Technology Ladkrabang, Bangkok, Thailand.
E mail: chatthara@yahoo.com

Key words: Talus; talar prosthesis; trauma; avascular necrosis; tumor.

Contributions: CA: data collection, data analysis, manuscript drafting; PR: manuscript drafting and editing.

Conflict of interest: Dr. Anghong reports personal fees from Phoenix Surgical Equipment (Thailand) Co., Ltd, personal fees from Amgen, personal fees from THAI ADK ENGINEERING COMPANY LIMITED, during the conduct of the study. In addition, Dr. Anghong has a patent Manufacture protocol for the artificial total talus (Thailand patent number: 14879) issued.
Dr. Rajbhandari reports no conflict of interest.

Ethics approval and consent to participate: All patients involved provided informed consent for this report.

Availability of data and materials: Data repository was available from the corresponding author.

Received for publication: 16 August 2020.
Accepted for publication: 22 October 2020.

This work is licensed under a Creative Commons Attribution NonCommercial 4.0 License (CC BY-NC 4.0).

©Copyright: the Author(s), 2020
Licensee PAGEPress, Italy
Orthopedic Reviews 2020;12:8844
doi:10.4081/or.2020.8844

they underwent a single stage procedure that included tumor removal with total talar prosthesis replacement, with or without ankle ligament reconstruction.

The procedure of total talar prosthesis replacement surgery is as such - a pneumatic tourniquet was applied to the thigh. An anterior approach to the ankle was done in all patients. In cases numbered 4-5, the senior author (CA) developed the bilateral holes based on the previously anatomic study for the medial and lateral ligament reconstruction (Figure 3) using BioComposite, SwiveLock (Arthrex, Inc. Naples, FL, USA).⁶

Lateral ankle ligament reconstruction was done in these patients. In a case of deltoid ligaments insufficiency, the superficial deltoid ligament was repaired using a suture anchor and augmentation was done with tibialis anterior tendon plication. Following the operation, a short leg slab was

applied. The suture removal was done at two weeks post operatively after wound healing. Next, the patient was prescribed a Controlled Ankle Motion (CAM) walker. They were allowed ambulation with partial weight-bearing at the distal area of the forefoot. The patients were to perform range of motion exercises for dorsiflexion and plantar-flexion of the ankle while they were able to remove the CAM walker in the morning and evening at 3-6 weeks post operatively. The patients were permitted to walk with increasing weight-bearing as tolerated until full weight-

bearing was allowed at 7-12 weeks following the operation.

Results

The mean follow-up time was 17.8 ± 8.4 months. Related complications were a mild subsidence (1 patient, 20%, patient number 3), and periprosthetic fracture (1 patient, 20%, a mild displaced calcaneal fracture from a new traffic injury, patient number 2).

From the available data, the mean clinical scores including VAS-FA and SF-36 were improved following surgeries as shown in Table 2.

However, these improvements were not significantly different (P -values > 0.05) due to the limited number of patients in the current series. Regarding the postoperative clinical outcomes, the ankle range of motion was substantially satisfactory in patients 3, 4 and 5 (Figure 4).

The patients with pre-existing talar tumor or avascular necrosis of talus showed better postoperative ankle motions than the patients with post-traumatic talar body or total talar loss. The ankle stability was satisfactorily spared in the patients numbered 4 and 5 who both had ankle ligament reconstruction. Most patients returned to ambulating without significant disturbances of weight-bearing, pain or ankle instability. Despite these results, a patient number 1 had the stiffness in the subtalar joint but this did not disturb weight-bearing. In addition, patient number 3 had pain at her ankle area that inhibited full weight bearing and limited ambulation to short distances.

Regarding the postoperative radiographs, the total talar prosthesis implants were well seated in the ankle mortise, talocalcaneal, and talonavicular articulations (Figure 5). There were some related complications as previously

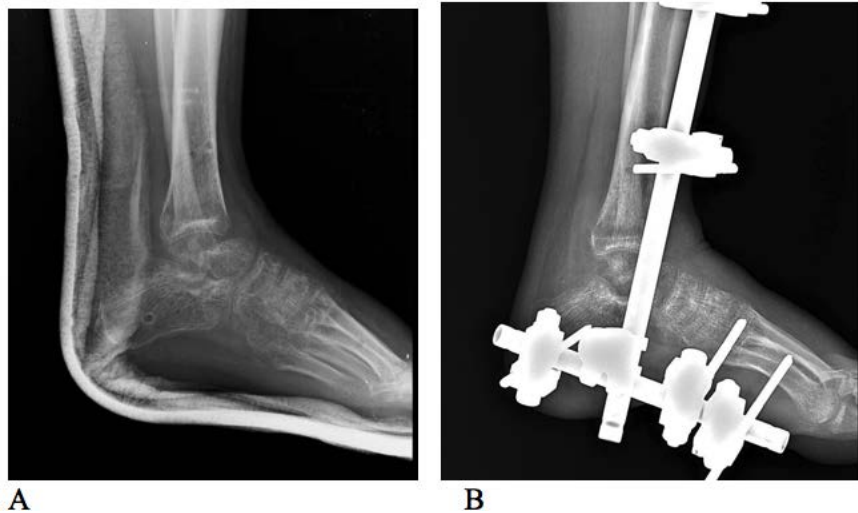


Figure 1. The lateral radiograph of right ankle demonstrating talar body loss (A), followed by staging with the joint spanning external fixator (B).



Figure 2. The image of expected talus processed by three-dimensional CT, CAD which is produced by measuring mirror image from the contralateral talus.



Figure 3. The total talar prosthesis with bilateral holes for the medial and lateral ligament reconstruction, (A) medial view and (B) lateral view.

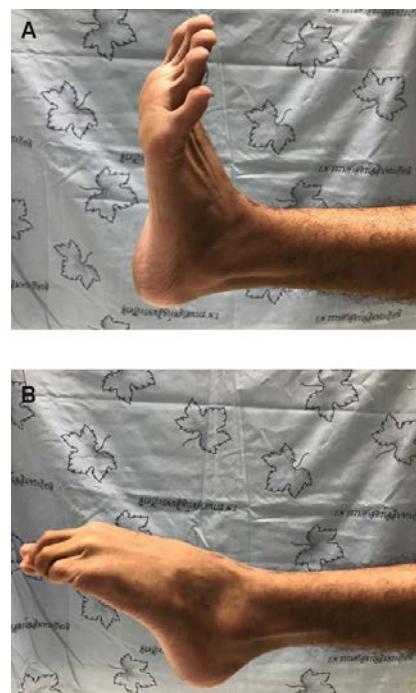


Figure 4. The ankle range of motion was substantially satisfactory in patient number 5 at around 20 months, (A) ankle dorsiflexion, and (B) ankle plantar flexion.

mentioned. A patient number 2 recovered following the periprosthetic fracture of the calcaneus with mild displacement. A patient number 3 required further follow-up.

Discussion

The present study highlights the process of customizing and manufacturing total talar prosthesis using three-dimensional (3D) CAD with CNC production and includes the results of total talar prosthesis replacement in patients with severe conditions of the talus. This new treatment modality changes the perspective in challenging conditions of talus. Traditionally, the treatments relied upon the ankle arthrodesis with Blair's technique⁷ or the tibiocalcaneal arthrodesis.⁸⁻¹⁰ These kinds of treatment inevitably limits the ranges of motion of the ankle and/or the subtalar joint. The limited motion potentially leads to limited function of the ankle and/or subtalar joint and compromises the quality of life. Some authors have proposed re-implantation of native talus in those cases of traumatic talar body loss.¹¹⁻¹⁵ However, this treatment option might attenuate the ankle area and may lead to infection. It may complicate the issue, such as recurrent infections and peri-articular bone loss that will require further invasive intervention. Based on the results of the present series, the total talar prosthesis replacement with or without ankle ligament reconstruction demonstrates superior outcome when compared with other kinds of conventional treatments in terms of sparing motion of ankle and/or subtalar joints and quicker recovery without the risk of nonunion at the

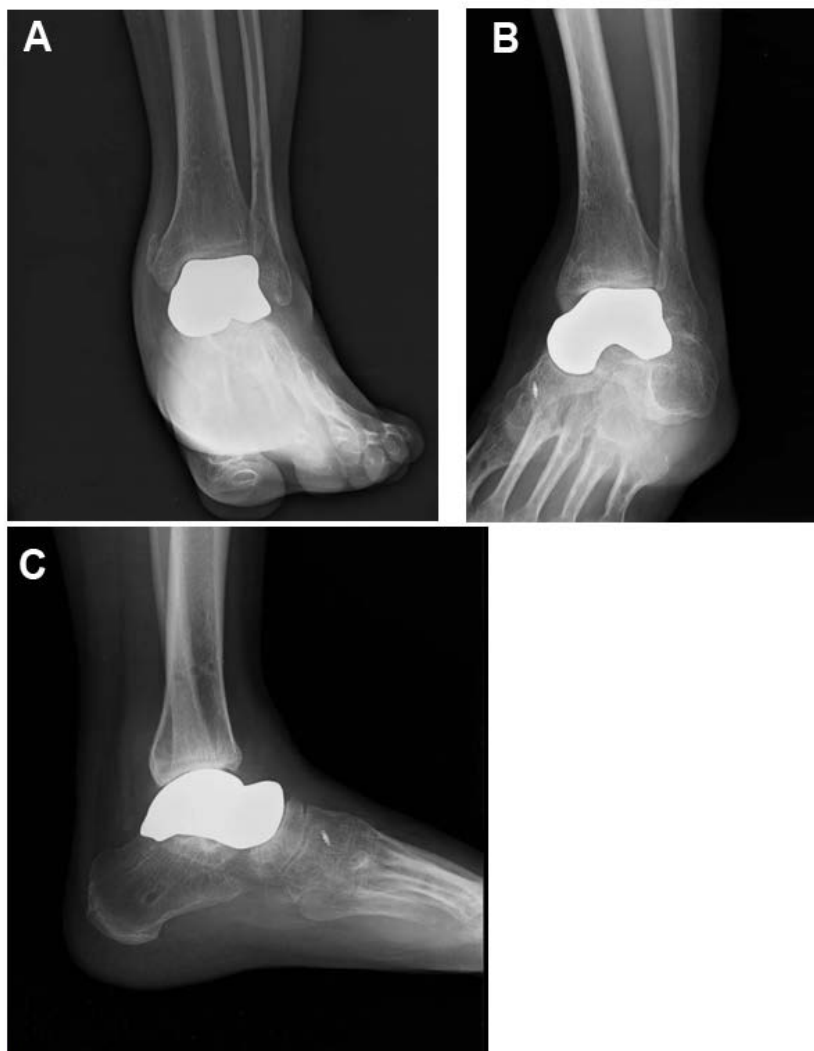

Figure 5. The postoperative radiographs showed the total talar prosthesis implant which was well seated in the ankle mortise, talocalcaneal, and talonavicular articulations, A) anteroposterior, B) mortise, and C) lateral radiographs.

Table 1. Patient demographics in the Study

Patient	Age	Sex	Entity	Cause	Prosthesis*
1	25	Male	Total talar loss	Injury	iTalar-M1.0
2	18	Male	Talar body loss	Injury	iTalar-M1.0
3	28	Female	Recurrent giant cell tumor	Tumor	iTalar-M1.0
4	49	Female	Avascular necrosis of talus	Injury	iTalar-M1.1
5	18**	Male	Large giant cell tumor	Tumor	iTalar-T1.1

*iTalar with number: implant generation; 1.0: no ligament reconstruction design; 1.1: with ligament reconstruction design; M: stainless steel; T: titanium; **Age at a patient's permission for the study.

Table 2. Summary of demographic data and clinical scores in the study.

	N*	Minimum	Maximum	Mean	S.D.
Age	5	18.00	49.00	27.60	12.73
Follow-up time	5	6.70	29.99	17.83	8.42
Preoperative VAS-FA	3	6.00	67.50	42.83	32.50
Postoperative VAS-FA	4	71.00	95.50	82.37	10.08
Preoperative SF-36	3	19.30	95.83	69.95	43.86
Postoperative SF-36	4	77.78	93.80	83.38	7.23

*Preoperative VAS-FA and SF-36 scores were available from three patients. Postoperative VAS-FA and SF-36 scores were available from four patients. Abbreviations: N, number; S.D., standard deviation.

arthrodesis site. In addition, there was no ankle instability in the patients who had ankle ligament reconstruction. These results supported that the total talar replacement with ankle ligament reconstruction may be the new standard option for the treatment in the severe conditions of talus. Regarding the issue of total talar prosthesis replacement¹⁻² versus talar body prosthesis replacement,^{3,16} there was no definite consensus on the superiority of either prosthesis type. However, Taniguchi *et al.*² proposed that the total talar prosthesis replacement showed higher satisfaction results than the talar body prosthesis replacement in their studies. Harnroongroj *et al.*³ also found a substantial rate of talar body prosthesis subsidence in their series. At this point, larger numbers of subjects and long-term follow-up periods may be necessary to clarify the benefits and limitations of each implant via comparative studies between these different procedures.

Finally, this present study may be the first report to demonstrate the process of customized total talar prosthesis manufacturing using the three-dimensional (3D) CAD with CNC production with or without the ankle ligament reconstruction that had a lower cost of prosthesis production than a 3D printing process. There was no consensus on which method is better. The author's hypothesis is that the total talar prosthesis via the CNC technique may have more strength than the implant via 3D printing technique as, in the CNC technique, there was no need for bonding among the raw product particles which was needed in the 3D printing technique.¹⁷ However, this issue needs further studies to validate this hypothesis. In addition, there was no previous report of the clinical outcome following the total talar prosthesis replacement with the ankle ligament reconstruction that was reported in the present study. This updated procedure may strengthen the novel reconstruction and

enhances ankle stability that has been emphasized and depicted in the present study.

Conclusions

The present series may be the first report of the customized metallic total talar prostheses via the CNC technique with or without the ankle ligament reconstruction that appears to provide satisfactory outcomes for the treatment of severe talar loss or damage at a short-term follow-up.

References

1. Anghong C. Anatomic total talar prosthesis replacement surgery and ankle arthroplasty: an early case series in Thailand. *Orthop Rev* 2014;6:5486.
2. Taniguchi A, Takakura Y, Tanaka Y et al. An alumina ceramic total talar prosthesis for osteonecrosis of the talus. *J Bone Joint Surg Am* 2015;97:1348-53.
3. Harnroongroj T, Harnroongroj T. The talar body prosthesis: results at ten to thirty-six years of follow-up. *J Bone Joint Surg Am* 2014;96:1211-18.
4. Anghong C, Chernchujit B, Suntharapa T, Harnroongroj T. Visual analogue scale foot and ankle: validity and reliability of Thai version of the new outcome score in subjective form. *J Med Assoc Thai* 2011;94:952-7.
5. Jirattanaphochai K, Jung S, Sumananont C, Saengnipanthkul S. Reliability of the medical outcomes study short-form survey version 2.0 (Thai version) for the evaluation of low back pain patients. *J Med Assoc Thai* 2005;88:1355-61.
6. Golano P, Vega J, de Leeuw PAJ et al. Anatomy of the ankle ligaments: a pictorial essay. *Knee Surg Sports*

Traumatol Arthrosc 2010;18:557-69.

7. Blair HC. Comminuted fractures and fracture dislocations of the body of the Astragalus, operative treatment. *Am J Surg* 1943;59:37-43.
8. Myerson MS, Alvarez RG, Lam PW. Tibiocalcaneal arthrodesis for the management of severe ankle and hindfoot deformities. *Foot Ankle Int* 2000;21:643-50.
9. Reckling FW. Early tibiocalcaneal fusion in the treatment of severe injuries of the talus. *J Trauma* 1972;12:390-96.
10. Rochman R, Jackson Hutson J, Alade O. Tibiocalcaneal arthrodesis using the Ilizarov technique in the presence of bone loss and infection of the talus. *Foot Ankle Int* 2008;29:1001-8.
11. Apostle KL, Umran T, Penner MJ. Reimplantation of a totally extruded talus: a case report. *J Bone Joint Surg Am* 2010;92:1661-65.
12. Brewster NT, Maffulli N. Reimplantation of the totally extruded talus. *J Orthop Trauma* 1997;11:42-5.
13. Gerken N, Yalamanchili R, Yalamanchili S et al. Talar revascularization after a complete talar extrusion. *J Orthop Trauma* 2011;25:107-10.
14. Lee J, Hamilton G. Complete talar extrusion: a case report. *J Foot Ankle Surg* 2009;48:372-5.
15. Smith CS, Nork SE, Sangeorzan BJ. The extruded talus: results of reimplantation. *J Bone Joint Surg Am* 2006;88:2418-24.
16. Harnroongroj T, Vanadurongwan V. The talar body prosthesis. *J Bone Joint Surg Am* 1997;79:1313-22.
17. Tracey J, Arora D, Gross CE, Parekh SG. Custom 3D-Printed total talar prostheses restore normal joint anatomy throughout the hindfoot. *Foot Ankle Spec* 2019;12:39-48.