



Contents lists available at ScienceDirect

Indian Pacing and Electrophysiology Journal

journal homepage: www.elsevier.com/locate/IPEJ

Venoplasty of a chronic venous occlusion allowing for cardiac device lead placement: A team approach



Mehrdad Golian*, Minh Vo, Amir Ravandi, Colette M. Seifer

Max Rady Faculty of Health Sciences, Rady College of Medicine, University of Manitoba, Winnipeg, Canada

ARTICLE INFO

Article history:

Received 1 May 2016

Received in revised form

8 November 2016

Accepted 9 November 2016

Available online 10 November 2016

Keywords:

Venoplasty

Externalization technique

Total venous occlusion

ABSTRACT

In patients with complete venous occlusion requiring venous access for cardiac device lead placement, venous revascularization is a viable option. A percutaneous approach to venous revascularization has gained popularity. This method reduces patient exposure to more invasive therapies. In this case series, we describe two cases of a total venous occlusion that were successfully revascularized using a “wire externalization” technique. This technique requires the use of antegrade and retrograde access.

Copyright © 2016, Indian Heart Rhythm Society. Production and hosting by Elsevier B.V. This is an open access article under the CC BY-NC-ND license (<http://creativecommons.org/licenses/by-nc-nd/4.0/>).

1. Introduction

Upper extremity transvenous access is the method of choice for implantation of cardiac implantable electronic devices (CIED). However, venous access for many patients can be challenging and not achievable due to vessel occlusion. The most common cause of venous occlusion is prior instrumentation [1–4].

In patients requiring CIEDs, venous occlusion is usually recognized with venography prior to device insertion. If left-sided venous access is unavailable, contralateral venous access or an epicardial approach to device placement can be performed. Epicardial lead placement is an invasive procedure requiring a mini-thoracotomy. There can be associated complications such as infection, post-procedural pain, and the need for repeat procedures [1]. Right sided access can be technically more challenging for lead placement. In addition, the recovery post-procedure is more difficult for the right-handed patient.

Percutaneous techniques for safe revascularization of stenotic veins can reduce both the need for more invasive procedures as well as the risk of harm to patients. Techniques for angioplasty in Chronic Total Occlusions (CTO) of coronary arteries are well

established. We describe two patients with total subclavian vein occlusion who underwent venoplasty and successful lead placement. A single chamber, VVI pacemaker was implanted successfully in one patient. The second patient had an implantable cardioverter defibrillator (ICD) upgraded to a cardiac resynchronization therapy-defibrillator device (CRT-D) with the addition of a left ventricular lead. The procedures were done using a “Heart Team Approach” with physicians and staff experienced in coronary CTO techniques as well as complex CIED’s to ensure optimal safety and success.

2. Case 1

An 84 year old male on hemodialysis via a right upper limb fistula presented with syncope. A 12 lead electrocardiogram demonstrated sinus rhythm with 2 to 1 atrioventricular block and he was offered a permanent pacemaker (PPM). Prior to device insertion, left upper limb venography revealed an occluded left subclavian vein (Fig. 1A). As the right subclavian vein was required for hemodialysis, it was decided to attempt venoplasty of the left subclavian vein.

The procedure was a collaborative effort between interventional cardiology and electrophysiology with both teams present in the cardiac catheterization lab.

The left subclavian vein and right femoral vein were accessed with 7 and 8 French sheaths respectively, to establish access on both sides of the stenosis. Simultaneous dual injections were performed with a multipurpose guide catheter in the left subclavian and a pigtail catheter in the superior vena cava (SVC) (Fig. 1A). This

* Corresponding author. Department of Cardiology, University of Toronto, 6th Floor, Arrhythmia service, St Michael’s Hospital, 30 Bond St., Toronto, Ontario M5B 1W8, Canada.

E-mail address: Mehrdad.Golian@icloud.com (M. Golian).

Peer review under responsibility of Indian Heart Rhythm Society.

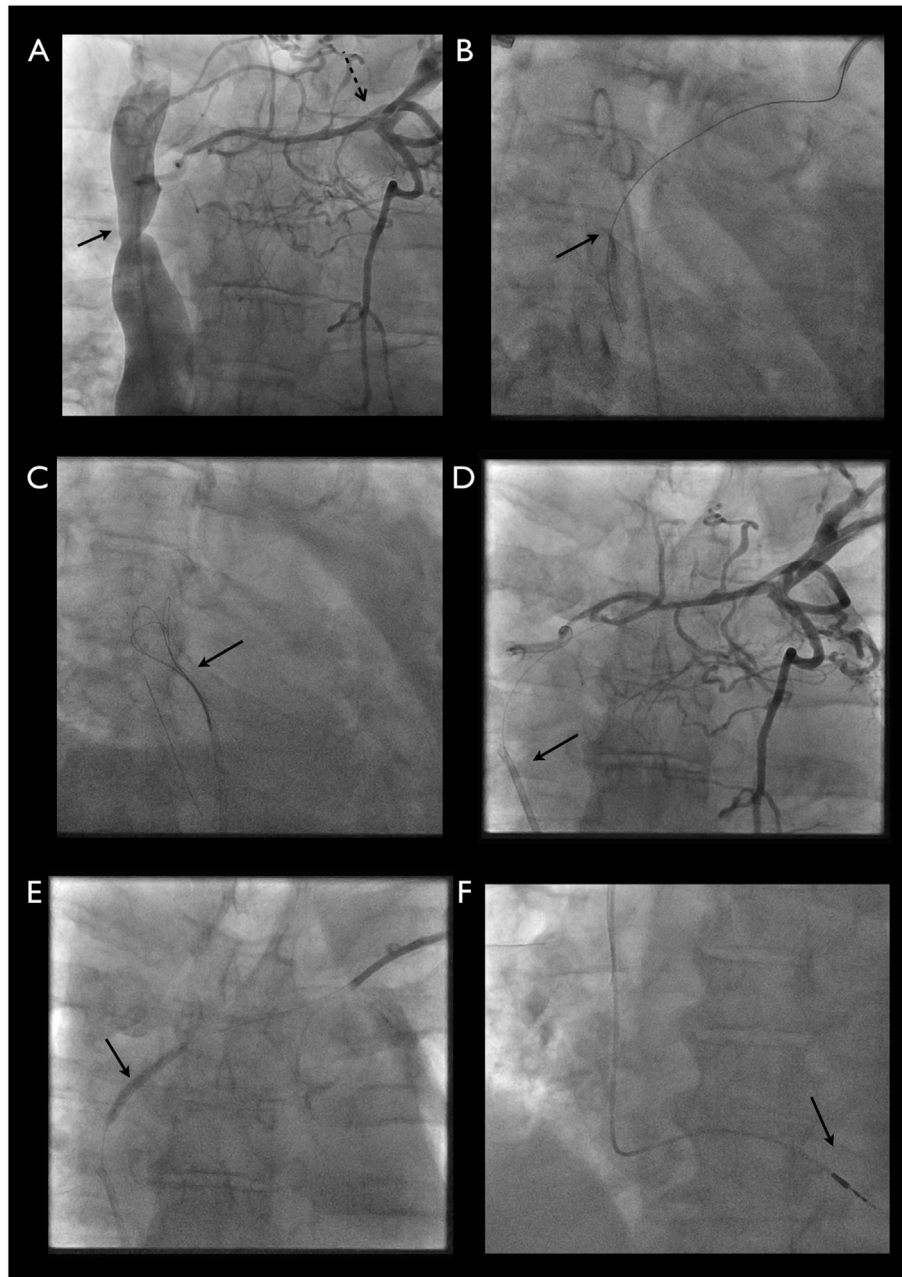


Fig. 1. A. Pig tail catheter in the SVC (solid arrow) and multipurpose guide catheter in the left subclavian vein (dashed arrow) with simultaneous contrast injection showing a long venous occlusion B. Confianza PRO 12 wire (solid arrow) entering the true lumen of the SVC C. R350 externalization wire being snared (solid arrow) D. Snared R350 wire being pulled into the guide catheter E. Retrograde noncompliant balloon (solid arrow) dilation of the stenotic vein F. Pacemaker lead (solid arrow) being advanced through a SafeSheath.

revealed a long venous total occlusion with an ambiguous proximal and distal cap (Fig. 1A).

Using the femoral vein access site, a Finecross[®] MG coronary micro-guide catheter (Terumo Europe NV) was advanced near the distal cap and it was then punctured. The Finecross[®] was then advanced into the cap. A HI-TORQUE PILOT 200 guidewire (Abbott Vascular, USA) was used to cross to the occluded segment, but was unable to successfully puncture the distal cap. The Finecross[®] was advanced to the distal cap and an ASAHI[®] Confianza PRO 12 (ASAHI Intecc Co., Ltd) was used to puncture the distal cap and the Finecross[®] catheter was subsequently placed over an R350 300 cm guidewire (Vascular Solutions, USA) into the SVC. (Fig. 1B).

An EN Snare[®] 120 cm (18–30 mm snare diameter) (Merit Medical Systems, Inc.) endovascular snare was used to snare the

R350 which was then externalized (Fig. 1C and D).

Retrograde angioplasty was performed using progressively larger non-compliant balloons (up to 5 × 20 mm), to facilitate antegrade advancement of a QUICK-CROSS[®] support catheter (Spectranetics) into the SVC (Fig. 1E). The externalized R350 wire was then removed and exchanged for an Amplatz support wire (Cook Medical).

A 25 cm 7 French SafeSheath[®] (Pressure Products Medical Supplier, Inc.) was then placed antegradely over the Amplatz support wire. A 4076 58 cm active fixation lead (Medtronic Inc., Minneapolis, USA) was then placed into the right ventricular apex and connected to a Sensia SESR01 (Medtronic) (Fig. 1F). The pocket was closed in the usual fashion and the femoral vein catheter was removed. There were no early complications.

3. Case 2

A 57 yo male with an ischemic cardiomyopathy, New York Heart Association (NYHA) functional class III symptoms, and an ejection fraction of 30%, had an ICD inserted 6 years previously for secondary prevention of sudden cardiac death. The ICD generator now requires replacing due to battery depletion. A 12 lead ECG revealed an underlying left bundle branch block with a QRS duration of 170 msec so it was decided to upgrade his ICD to a CRT-D. Left upper limb venography documented occlusion of the left subclavian vein (Fig. 2A).

Using a team approach similar to the first case, access on both sides of the stenotic vein was obtained using the left subclavian vein, right femoral vein, and right antecubital vein. Using the right

femoral vein access, a Judkins Right size 4 (JR4) guiding catheter was advanced under fluoroscopic guidance into the left innominate vein. Through the antecubital access, a JR4 guiding catheter was also advanced to the level of the left subclavian vein occlusion. A Confianza PRO 12 was advanced successfully past the occlusion and into the distal segment of the vessel from the left subclavian access site (Fig. 2B). The wire was then advanced into the right ventricle confirming a 'true lumen to true lumen' connection. The CTO lesion was then dilated with progressively larger balloons from a 1.25 × 15 mm compliant balloon to a 5 × 20 mm noncompliant balloon (Fig. 2C and D). Following the angioplasty, a QUICK-CROSS® support catheter and an Amplatz Super Stiff™ guidewire (Boston Scientific Corp.) were placed into the right atrium. A 9 French SafeSheath® was then inserted over the Amplatz Super Stiff™

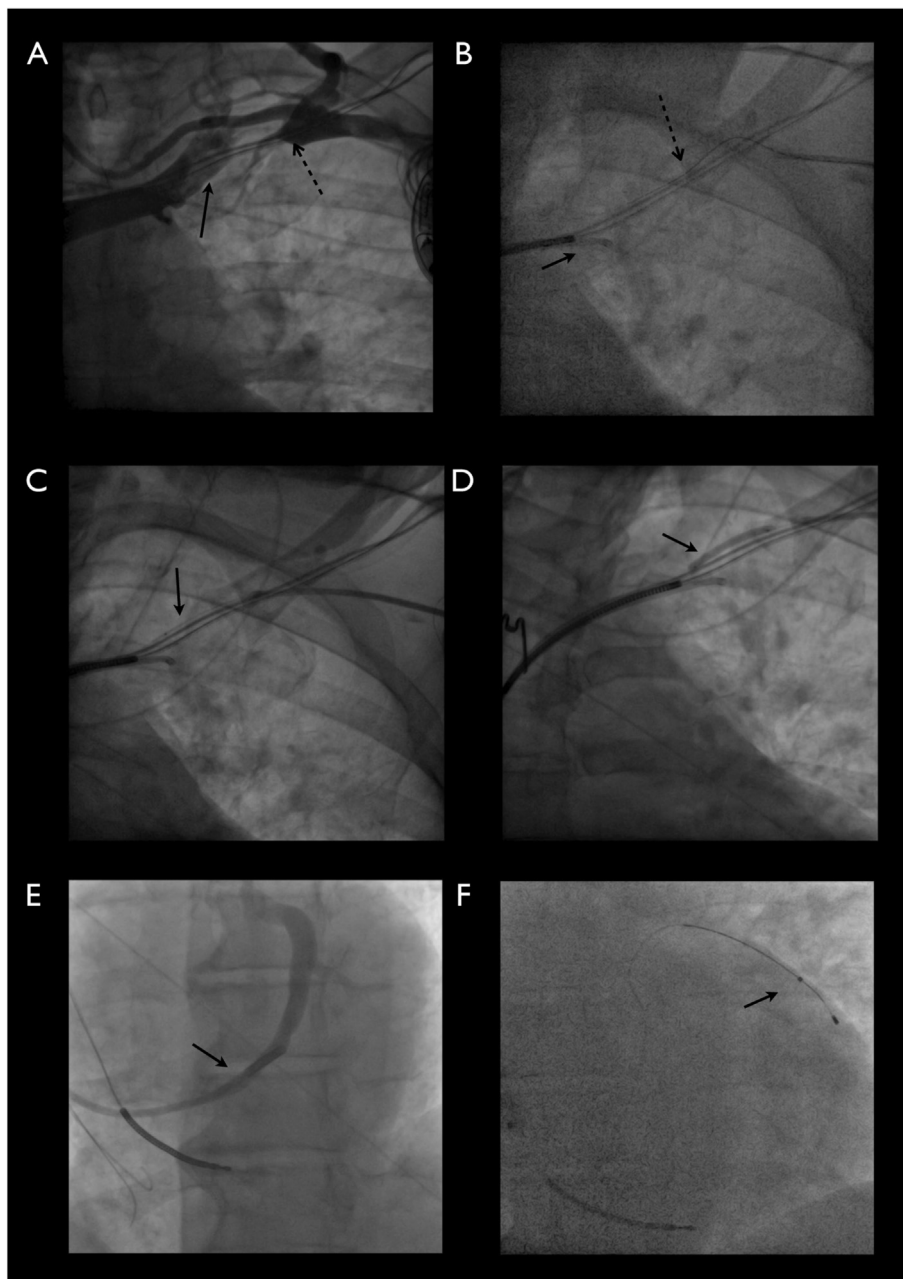


Fig. 2. A. Proximal site to subclavian stenosis (solid arrow) and distal cap of stenotic lesion (dashed arrow) seen with bilateral contrast injection B. Confianza PRO 12 wire (dashed arrow) entering the true lumen of the innominate vein, JR4 guide (solid arrow) C. Uninflated compliant balloon (solid arrow) D. Inflated 5 × 20 mm non-compliant balloon crossing the stenotic lesion E. Contrast injection in the cannulated coronary sinus F. Lateral cardiac vein cannulated using LV lead (Solid arrow).

guidewire. Through this, an Attain Command[®] SureValve[®] catheter (Medtronic Inc.) was advanced into the right atrium. Using a Mariner[®] catheter (Medtronic Inc.), the coronary sinus was cannulated and injection of 10 cc of Visipaque revealed a narrow posterolateral vein and small lateral vein (Fig. 2E). A Medtronic 4396-88 cm dual electrode lead was successfully placed in the lateral vein (Fig. 2F). The existing right atrial and right ventricular leads had good sense/pace characteristics and stable impedance measurements. A CRT-D was connected to all 3 leads and placed in the pocket. There were no early complications.

4. Discussion

Venous access for placement of CIED's can be challenging. Utilization of stenotic veins is increasingly required to deliver optimal care and minimize invasive procedures.

Venous occlusion can be divided into two types, primary and secondary. Primary venous stenosis occurs in the absence of prior instrumentation or external compression. It can be due to venous thrombosis, either idiopathic or secondary to predisposing factors conditions such as thrombophilias or hormone therapy. Secondary stenosis, seen in patients with prior venous instrumentation or with external vein compression, can occur due to impingement of the subclavian vein between the first rib and the clavicle ('subclavian crush'). Other predisposing risks include prior instrumentation, which can result in vessel wall damage, inflammation and promotion of thrombogenesis [2,3].

In a retrospective study by Ji and colleagues, the rate of venous stenosis was as high as 5% [3]. In a consecutive series of 105 patients presenting for their first generator replacement, 9% had complete occlusion of the insertion vein and a further 16% had at least a moderate stenosis [4]. Worley et al. showed that two thirds of encountered stenoses occur at the subclavian to distal innominate vein junction with a total angiographic occlusion rate of 20% [5].

When a total venous occlusion is encountered options include: 1) puncturing proximal to the site of stenosis if possible; 2) abandoning and obtaining access on the contralateral side or an alternative site such as the femoral vein; 3) epicardial implantation through a thoracotomy; and 4) venoplasty.

In patients with venous occlusion, contralateral access or proximal puncture is not always feasible. The contralateral side may be used for other lifesaving procedures such as dialysis and proximal venous puncture may not be safely performed. Venoplasty can offer a viable option in such cases.

Post balloon dilation of the venous stenosis, stenting can be considered if primary balloon angioplasty fails or long-term patency is desired. Unlike arterial stents that lead to improved long-term vessel patency, results are mixed in venous stenting. In a study including 146 stenosed veins, there was a higher primary

patency rate with venoplasty alone (24%) compared to stenting (13%) [6].

In case 1, immediate vessel patency was required for lead placement and as the patient did not have any symptoms due to the venous stenosis, stenting was not performed. In case 2, stenting was not possible due to the presence of previous leads which could result in stent malapposition and intraluminal thrombosis as well as the possibility of damage to the leads. Subclavian venous stent placement complications also include overlap of the stent with the internal jugular vein which would limit future central line placement; occlusion of the contralateral brachiocephalic or other venous branches causing superior vena cava or brachiocephalic vein syndrome. Systemic anticoagulation was not required in either case.

To improve procedural success and reduce the complication risk we chose a collaborative approach with interventional skills in total vessel occlusion as well as electrophysiology skills in device implantation.

5. Conclusion

Total venous occlusion is an increasingly common problem encountered at the time of device implantation. Revascularization of the occluded vein can be achieved safely using a collaborative team approach.

Disclosures

None.

References

- [1] Patwala A, Woods P, Clements R, Albouaini K, Rao A, Goldspink D, et al. A prospective longitudinal evaluation of the benefits of epicardial lead placement for cardiac resynchronization therapy. *Europace* 2009;11:1323–9.
- [2] Deighan CJ, McLaughlin KJ, Simpson K, Boulton Jones JM. Unsuspected subclavian vein stenosis resulting from a permanent pacing wire. *Nephrol Dial Transpl* 1996;11:2333–4.
- [3] Ji SY, Gundewar S, Palma EC. Subclavian venoplasty may reduce implant times and implant failures in the era of increasing device upgrades. *Pacing Clin Electrophysiol* 2012;35(4):444–8.
- [4] Lickfett L, Bitzen A, Arepally A, Nasir K, Wolpert C, Jeong KM, et al. Incidence of venous obstruction following insertion of an implantable cardioverter defibrillator. A study of systematic contrast venography on patients presenting for their first elective ICD generator replacement. *Europace* 2004;6:25–31.
- [5] Worley S, Gohn DC, Pulliam RW, Raifsnider MA, Ebersole BI, Tuzi J. Subclavian venoplasty by the implanting physicians in 373 patients over 11 years. *Heart Rhythm* 2011;8:526–33.
- [6] Ozyer U, Harman A, Yildirim E, Aytekin C, Karakayali F, Boyvat F. Long-term results of angioplasty and stent placement for treatment of central venous obstruction in 126 hemodialysis patients: a 10-year single-center experience. *Am J Roentgenol* 2009;193(6):1672–9.