



CASE REPORT

Iris Retraction Without Hypotony

Carson C. Petrash · Alan G. Palestine · Jesse Smith ·
Richard Davidson · Mina B. Pantcheva

Received: January 30, 2022 / Accepted: March 4, 2022 / Published online: March 22, 2022
© The Author(s) 2022

ABSTRACT

Purpose: All published cases of iris retraction syndrome have been associated with low intraocular pressure. We report here a case clinically indistinguishable from iris retraction syndrome except for the absence of hypotony, which has not been previously described in the literature.

Observations: A 35-year-old woman with a history of atopic dermatitis developed a rapidly progressive anterior subcapsular cataract and acute uveitis. During follow-up, the presence of bilateral iris retraction was noted, while ocular pressure was either normal or elevated, and the position did not normalize with pupillary dila-

tion. The clinical course was complicated by retinal detachment and posterior cyclitic membrane, which was managed with pars plana vitrectomy, lensectomy, and dissection of cyclitic membrane. The case was further complicated by ocular hypertension attributed to steroid response and formation of an epiretinal membrane. Following micropulse cyclophotocoagulation, placement of an Ahmed tube shunt, epiretinal membrane peel, and placement of secondary intraocular lens, our patient eventually had a good visual outcome.

Conclusions and Importance: Hypotony is generally recognized as a key physiological step in the development of iris retraction syndrome. Our case demonstrates that posterior bowing of the iris can occur in the absence of hypotony, and suggests that an alternative mechanism involving posterior cyclitic membrane may be responsible.

Keywords: Atopic Dermatitis; Cyclitic Membrane; Iris Retraction

C. C. Petrash (✉) · A. G. Palestine · J. Smith ·
R. Davidson · M. B. Pantcheva
Department of Ophthalmology, University of
Colorado Anschutz Medical Campus, Rocky
Mountain Lions Eye Institute, 1675 Aurora Court,
Aurora, CO 80045, USA
e-mail: Carson.Petrash@cuanschutz.edu
A. G. Palestine
e-mail: Alan.Palestine@cuanschutz.edu
J. Smith
e-mail: Jesse.Smith@cuanschutz.edu
R. Davidson
e-mail:
Richard.Davidson@cuanschutz.edu
M. B. Pantcheva
e-mail:
Mina.Pantcheva@cuanschutz.edu

Key Summary Points

Hypotony has previously been understood to be essential in causing iris retraction.

This case demonstrates iris retraction in the absence of hypotony.

A new mechanism causing iris retraction is suggested that has not been documented in the literature.

Atopic dermatitis may be associated with intraocular inflammation and retinal detachment.

INTRODUCTION

Atopic dermatitis (AD) is a chronic inflammatory skin disease characterized by itchy, erythematous, cracked skin, especially on the insides of the knees and elbows. With regard to ophthalmic manifestations, itching and rubbing predisposes to blepharitis, keratoconjunctivitis, and keratoconus [1–4]. However, further ophthalmic diseases are associated with AD and the mechanisms are not as clear.

Cataracts may develop rapidly, especially with classic “shield-like” anterior subcapsular cataract (ASC) morphology [5, 6]; however, a posterior subcapsular cataract (PSC) is more common [7]. Rhegmatogenous retinal detachment (RD) is the most vision-threatening complication associated with atopic dermatitis, and the incidence of RD correlates with the severity of AD [8]. Postulated mechanisms of RD in AD include retinal edema [9], uveitis [10, 11], vascular changes [12], and vitreous disease [13]; however, the characteristics of RD in patients with atopic dermatitis are similar to traumatic RD, and case series have demonstrated an association with eye rubbing and tapping [14–16].

“Iris retraction syndrome” (IRS) was initially described by Campbell in 1984 as a phenomenon that may follow rhegmatogenous RD,

where reabsorption of fluid through the retinal pigment epithelium (RPE) pump at a rate exceeding production by the ciliary body causes retrograde aqueous flow and posterior iris bowing. This general mechanism was annotated by Geyer, who demonstrated that IRS may occur in the absence of RD when chronic inflammation causes decreased aqueous production and extreme hypotony permits retrograde flow through Schlemm’s canal [17]. Regardless of the supposed mechanism, in all documented cases of iris retraction, hypotony is considered an essential component.

Here we present a case of a patient with atopic dermatitis who presented due to a rapidly progressive ASC and iris retraction with a posterior cyclitic membrane in the absence of both rhegmatogenous RD and hypotony. This is a unique case in the literature that sheds light on alternative mechanisms for iris retraction.

Consent to publish this case report was obtained from the patient in writing.

CASE REPORT

A 35-year-old Asian woman presented to our institution with 1 week of gradual-onset blurry vision in the right eye. She complained of dryness and itching but denied all other symptoms including pain, erythema, or any problems with her left eye. The medical history was significant for eczema, asthma, and seasonal allergies. Ocular history included myopia of -2.00 D in both eyes. There were no prior episodes of blurry vision or notable trauma.

Best-corrected visual acuity was 20/60 in the right eye and 20/20 in the left eye. Intraocular pressure (IOP) was 21 and 16 mmHg, respectively. Pupils were equal, round and reactive. Significant findings in the right eye included anterior chamber (AC) pigmented and inflammatory cells and flare, ASC (see Fig. 1), and vitreous pigment. The left eye exhibited trace AC pigmented and inflammatory cells. At this time, the bilateral irides were noted to bow posteriorly, right more than left, as shown in Fig. 2. In addition, gonioscopy demonstrated open angles with 4+ pigment in the trabecular meshwork of both eyes. She did not have iris

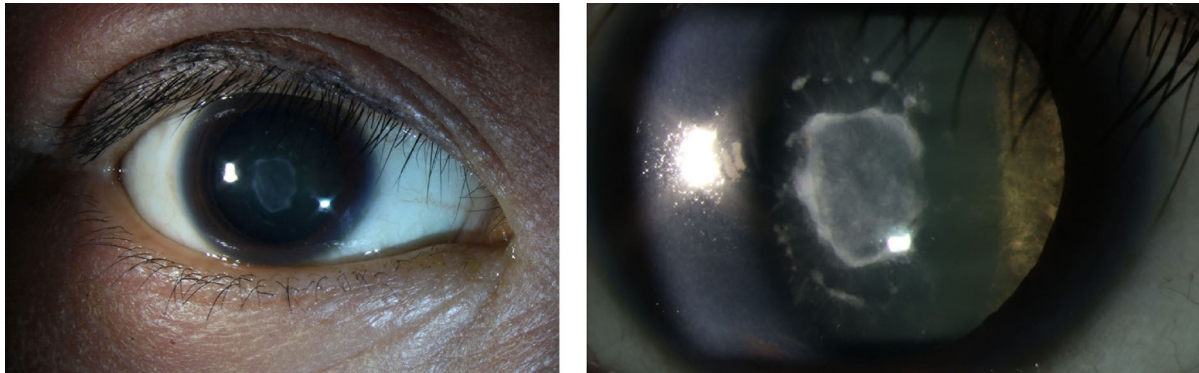


Fig. 1 The left image demonstrates periocular eczema and lenticular opacity seen in our patient. The photograph on the right highlights the characteristic “shield”-like appearance of the ASC

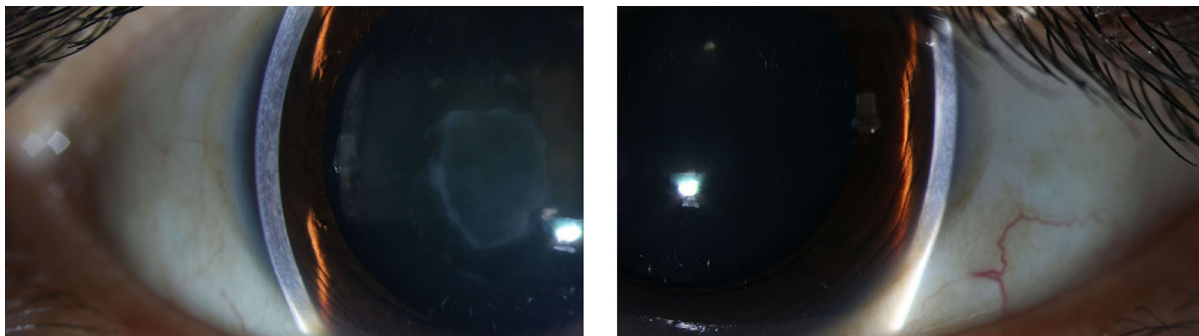


Fig. 2 The image on the left demonstrates the anterior segment in the right eye of our patient. Note the presence of dilation. The vertical beam is lost centrally as it nears the pupillary margin, highlighting the posterior bow of the

iris. The photograph on the right shows the anterior segment of the left eye of our patient. While not as severe as the right eye, nonetheless, posterior bowing is evident

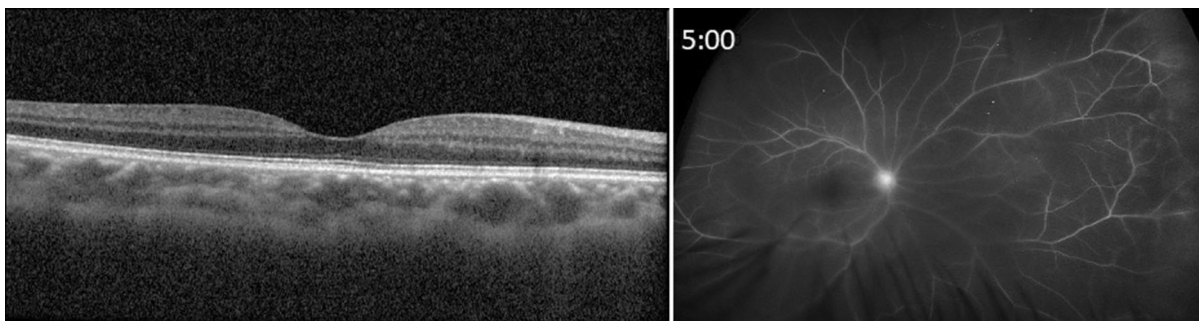


Fig. 3 The image on the left demonstrates the normal OCT of the right eye, without inflammatory CME. The image on the right is the fluorescein angiogram of the right

eye at time of 5 min. General haze is apparent, due to the ASC. Again, there is no significant CME but mild peripheral vascular leakage is observed

transillumination defects or Krukenberg spindles. Iris retraction did not normalize after dilation. The rest of the exam, including 360-degree scleral depression, was unremarkable. Optical coherence tomography (OCT) and fluorescein angiogram of the right eye demonstrated the absence of cystoid macular edema (CME), with minimal vascular leakage (Fig. 3).

A clinical diagnosis of posterior cyclitis was made based on AC and vitreous cells. A systemic workup was ordered including human leukocyte antigen (HLA)-B27, treponema antigen, chest X-ray, antinuclear antibody (ANA), antineutrophil cytoplasmic antibodies (ANCA), C-reactive protein (CRP), erythrocyte sedimentation rate (ESR), angiotensin-converting enzyme (ACE), and urinalysis. Except for HLA-B27, which was positive, all tests were negative. The patient was started on prednisolone acetate hourly in the right eye and four times daily in the left eye.

Intraocular inflammation was reduced at follow-up and sub-tenon triamcinolone (STK) was administered as longer-term therapy for posterior cyclitis. After 2 weeks, the patient returned complaining of headache for 1 week. Intraocular pressure was 55 and 12 mmHg in the right and left eye, respectively. Pressure elevation was attributed to steroid response. Anti-glaucomatous therapy was started as follows: acetazolamide 500 mg by mouth twice daily, dorzolamide/timolol 2%/0.5% one drop

twice daily, brimonidine 0.2% one drop twice daily. The patient quickly responded and oral therapy was withdrawn after 4 days. Pressure and inflammation were much improved after 1 week.

After 2 weeks, our patient returned due to feeling a “soft eyeball” in her right eye. IOP in this eye was 6 mmHg, and B-scan ultrasonography, seen in Fig. 4, was concerning for RD, either exudative or rhegmatogenous.

Scleral encircling buckle was placed, followed by pars plana lensectomy in order to view the posterior segment without obscuration by cataract. After the lens was removed, a posterior cyclitic membrane was visualized directly and dissected. Subsequently, vitrectomy was completed. No breaks were observed but there were two areas of retinal thinning and significant choroidal folds. These areas were treated as breaks with endolaser and silicone oil (SO) tamponade. The patient was left aphakic. Following surgery, retraction resolved and the iris returned to the normal configuration.

The postoperative course was complicated for 4 weeks by recurrent prolonged elevation of IOP up to 47 mmHg while on antiglaucoma therapy as mentioned above. Ocular hypertension was attributed to emulsified silicone oil in a unicameral eye. Interventions escalated from micropulse cyclophotocoagulation to silicone oil removal with placement of an Ahmed glaucoma valve. Approximately 2 months post-op,

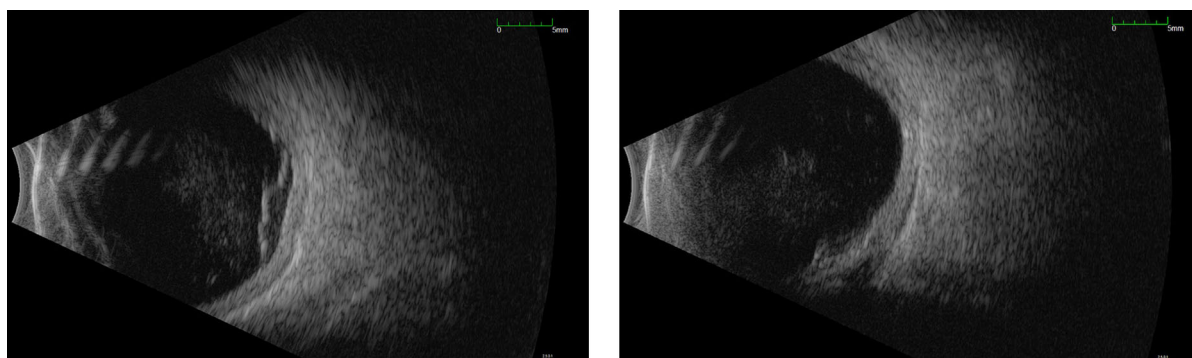


Fig. 4 Images of B-scan ultrasonography of the right eye of our patient. The image on the left demonstrates vitreous debris and subretinal fluid, concerning for RD in the setting of vitreous pigment, myopia, and chronic rubbing

of the eye. The scan on the right demonstrates thickened choroid and sub-tenon fluid, concerning for exudative RD in the setting of uveitis

the patient developed retinal detachment, managed with posterior retinotomy, pneumatic retinopexy, and endolaser. After 4 months of clinical stability, secondary intraocular lens (IOL) was placed in the right eye via the Yamane technique, along with removal of an epiretinal membrane that had formed due to chronic intraocular inflammation.

With regard to the left eye, ASC progressed in this eye as well, and cataract extraction with primary IOL placement was performed with perioperative STK and methylprednisolone without significant complication.

At the latest follow-up, the patient was stable on topical anti-inflammatory agents and aqueous suppressants along with azathioprine for chronic immunomodulation. Her distance visual acuity was measured at 20/30–1 and 20/20 and pressure at 13 and 19, respectively. Both eyes were quiet. The retina of the right eye was attached, with mild proliferative vitreoretinopathy (PVR) around the site of the retinotomy. En face infrared imaging of the macula of the right eye is shown in Fig. 5.

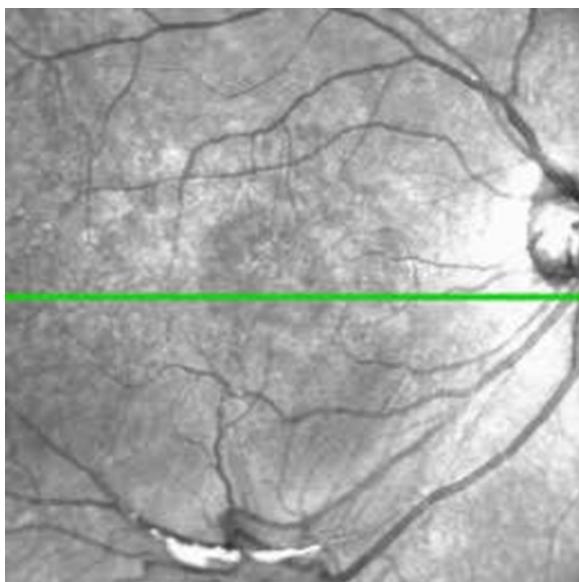


Fig. 5 En face infrared image of macula of the right eye after operations, demonstrating attached retina with only minor distortions following removal of epiretinal membrane

DISCUSSION

Many features of this case are typical for AD. As she is of Asian descent, our patient corresponds to the most common demographic affected by ophthalmic complications of AD [18, 19]. She admitted to frequent rubbing and tapping of the globe, a risk factor for complications [15]. A rapidly progressive “shield-like” ASC developed [20]. As discussed previously, there is increased risk of rhegmatogenous RD associated with PVR in patients with AD [15]. While our patient did not have any definitive retinal breaks, she did have a posterior cyclitic membrane that corresponds to the proliferative phenotype of AD [15, 21]. If just for these factors, our patient would be a typical presentation for a well-documented, albeit rare, pathological process.

Iris retraction in the absence of hypotony is unique to the literature. Posterior bowing of the iris is a rare phenomenon initially described by Schnaubel in 1876 in a myopic eye with RD that suddenly developed hypotony and deepened anterior chamber [22]. While it was purportedly due to rupture of a posterior staphyloma, the eye quickly regained normal pressure and appearance. The association of RD with hypotony was well documented by subsequent authors [23, 24]; however, Graham in 1958 was next to also report deepening of the anterior chamber, which he attributed to ciliary body detachment and vitreous contraction [25]. Mechanical traction on anterior structures was proposed by Jarret when he noted PVR in eyes with a posteriorly bowing iris following RD [26]. The term “iris retraction syndrome” was not coined until 1984, and both Cambell’s original explanation and Geyer’s subsequent amendment in 1998 require hypotony as a key physiological step [17, 27]. In summary, all documented cases of posterior iris bowing from Schnaubel in 1876 to Geyer in 1998 occur in the setting of hypotony due to either rhegmatogenous RD or ciliary body shutdown. While our patient eventually developed intraocular pressure as low as 6 mmHg, the IOP was 21 when iris retraction was first noted. In addition, mild iris retraction was noted in the left eye, which never

developed hypotony or any other significant complication beyond ASC.

Although it was subsequent to the development of iris retraction, our patient did eventually develop hypotony of the right eye. At that time, B-scan ultrasound demonstrated evidence of RD that prompted surgical repair; however, during the operation there were no definitive retinal breaks visualized. This signifies that the etiology of the hypotony in this case was ciliary body shutdown rather than rhegmatogenous RD. Geyer is the only other author to report IRS in patients without RD; however, IRS in his patients resolved with pupillary dilation, while bilateral iris retraction in our patient persisted with dilation, as seen in Fig. 2 [17].

The absence of hypotony and persistence following dilation both suggest an alternative mechanism for IRS than has been previously described. A posterior cyclitic membrane was encountered and dissected during surgery in our patient, and this may suggest a posterior-pulling mechanism as suggested by Jarret or Graham, though even their patients were hypotonous [25, 26]. Contraction of the cyclitic membrane would be mechanically consistent with posterior bowing in the absence of hypotony and would explain persistence following dilation.

CONCLUSIONS

Iris retraction syndrome is associated with hypotony due to retinal detachment or ciliary body shutdown. However, posterior bowing of the iris may also occur in the absence of hypotony and may be a sign of contraction from a posterior cyclitic membrane.

ACKNOWLEDGEMENTS

Funding. No funding or sponsorship was received for this study or publication of this article.

Authorship. All named authors meet the International Committee of Medical Journal

Editors (ICMJE) criteria for authorship for this article, take responsibility for the integrity of the work as a whole, and have given their approval for this version to be published.

Author Contributions. Recognition of significance of case: Alan Palestine, Jesse Smith, Richard Davidson, Mina Pantcheva. The first draft of the manuscript was written by Carson Petrash and all authors commented on previous versions of the manuscript. All authors read and approved the final manuscript.

Disclosures. The following authors have no financial disclosures to declare: Carson Petrash, Alan Palestine, Jesse Smith, Richard Davidson, Mina Pantcheva. All named authors confirm that they have conflicts of interest.

Compliance with Ethics Guidelines. Consent to publish this case report has been obtained from the patient(s) in writing.

Data Availability. Data sharing is not applicable to this article as no datasets were generated or analyzed during the current study.

Open Access. This article is licensed under a Creative Commons Attribution-NonCommercial 4.0 International License, which permits any non-commercial use, sharing, adaptation, distribution and reproduction in any medium or format, as long as you give appropriate credit to the original author(s) and the source, provide a link to the Creative Commons licence, and indicate if changes were made. The images or other third party material in this article are included in the article's Creative Commons licence, unless indicated otherwise in a credit line to the material. If material is not included in the article's Creative Commons licence and your intended use is not permitted by statutory regulation or exceeds the permitted use, you will need to obtain permission directly from the copyright holder. To view a copy of this licence, visit <http://creativecommons.org/licenses/by-nc/4.0/>.

REFERENCES

1. Bielory B, Bielory L. Atopic dermatitis and keratoconjunctivitis. *Immunol Allergy Clin North Am*. 2010;30:323–36.
2. Guglielmetti S, Dart JK, Calder V. Atopic keratoconjunctivitis and atopic dermatitis. *Curr Opin Allergy Clin Immunol*. 2010;10:478–85.
3. Shajari M, Eberhardt E, Muller M, et al. Effects of atopic syndrome on keratoconus. *Cornea*. 2016;35:1416–20.
4. Sugar J, Macsai MS. What causes keratoconus? *Cornea*. 2012;31:716–9.
5. Rich LF, Hanifin JM. Ocular complications of atopic dermatitis and other eczemas. *Int Ophthalmol Clin*. 1985;25:61–76.
6. Thompson RG. Cataract with atopic dermatitis; dermatologic aspects, with special reference to preoperative and postoperative care. *Arch Derm Syphilol*. 1950;61:433–41.
7. Castrow FF 2nd. Atopic cataracts versus steroid cataracts. *J Am Acad Dermatol*. 1981;5:64–6.
8. Choi M, Byun SJ, Lee DH, Kim KH, Park KH, Park SJ. The Association with rhegmatogenous retinal detachment and paediatric atopic dermatitis: a 12-year Nationwide Cohort Study. *Eye (Lond)*. 2020;34:1909–15.
9. Bayleat R. Complete retinal detachment (both eyes). *Am J Ophthalmol*. 1937;20:580–2.
10. Katsura H, Hida T. Atopic dermatitis. Retinal detachment associated with atopic dermatitis. *Retina*. 1984;4:148–51.
11. Jutte ALL. Amotio-Katarakt-Keratokinus als okulärer Symptomenkomplex bei endogenem Ekzem. *Klin Monatsbl Augenheikd*. 1965;147:12–25.
12. Mylius K. Doppelseitige spontane Netzhautablosung bei 2 jugendlichen, seit Jahren an Neurodermatitis disseminata leidenden Patienten. *Klin Monatsbl Augenheikd*. 1949;115:247–50.
13. Coles RSLJ. Retinal detachments occurring in cataract associated with neurodermatitis. *Arch Ophthalmol*. 1952;48:30–9.
14. Cordes FCC-MR. Atopic cataracts: report of 4 cases. *Am J Ophthalmol*. 1946;29:402–7.
15. Gnana Jothi V, McGimpsey S, Sharkey JA, Chan WC. Retinal detachment repair and cataract surgery in patients with atopic dermatitis. *Eye (Lond)*. 2017;31:1296–301.
16. Oka C, Ideta H, Nagasaki H, Watanabe K, Shinagawa K. Retinal detachment with atopic dermatitis similar to traumatic retinal detachment. *Ophthalmology*. 1994;101:1050–4.
17. Geyer O, Neudorfer M, Rothkoff L, Michaeli-Cohen A, Lazar M. Iris retraction syndrome associated with nonrhegmatogenous retinal detachment. *Acta Ophthalmol Scand*. 1998;76:617–9.
18. Sasoh M, Mizutani H, Matsubara H, et al. Incidence of retinal detachment associated with atopic dermatitis in Japan: review of cases from 1992 to 2011. *Clin Ophthalmol*. 2015;9:1129–34.
19. Kaufman BP, Guttman-Yassky E, Alexis AF. Atopic dermatitis in diverse racial and ethnic groups-Variations in epidemiology, genetics, clinical presentation and treatment. *Exp Dermatol*. 2018;27:340–57.
20. Bair B, Dodd J, Heidelberg K, Krach K. Cataracts in atopic dermatitis: a case presentation and review of the literature. *Arch Dermatol*. 2011;147:585–8.
21. Takahashi M, Suzuma K, Inaba I, Ogura Y, Yoneda K, Okamoto H. Retinal detachment associated with atopic dermatitis. *Br J Ophthalmol*. 1996;80:54–7.
22. Beigelman M. Acute hypotony in retinal detachment. *Arch Ophthalmol*. 1929;1:463–7.
23. Gonin L. Hypotonie oculaire dans ses relations avec le décollement rétinien. *Arch d'Ophthalmol*. 1934;51:426–30.
24. Gottlieb F. Combined choroidal and retinal detachment. *Arch Ophthalmol*. 1972;88:481–6.
25. Graham PA. Unusual evolution of retinal detachments. *Trans Ophthalmol Soc UK*. 1958;78:359–69.
26. Jarrett WH 2nd. Rhegmatogenous retinal detachment complicated by severe intraocular inflammation, hypotony, and choroidal detachment. *Trans Am Ophthalmol Soc*. 1981;79:664–83.
27. Campbell DG. Iris retraction associated with rhegmatogenous retinal detachment syndrome and hypotony. A new explanation. *Arch Ophthalmol*. 1984;102:1457–63.