

# Current interventional management of male stress urinary incontinence following urological procedures

Ireneusz Ostrowski<sup>1</sup>, Emil Śledź<sup>1</sup>, Janusz Ciechan<sup>1</sup>, Tomasz Golabek<sup>2</sup>, Jakub Bukowczan<sup>3</sup>, Mikołaj Przydacz<sup>2</sup>, Tomasz Wiatr<sup>2</sup>, Klaudia Stangel-Wojcikiewicz<sup>4</sup>, Piotr L. Chłosta<sup>2</sup>

<sup>1</sup>Department of Urology, Regional Hospital in Puławy, Poland

<sup>2</sup>Department of Urology, Collegium Medicum at the Jagiellonian University, Cracow, Poland

<sup>3</sup>Department of Endocrinology and Diabetes Mellitus, Northumbria NHS Foundation Trust, North Shields, United Kingdom

<sup>4</sup>Department of Gynaecology and Oncology, Collegium Medicum at the Jagiellonian University, Cracow, Poland

**Citation:** Ostrowski I, Śledź E, Ciechan J, et al. Current interventional management of male stress urinary incontinence following urological procedures. Cent European J Urol. 2015; 68: 340-347.

## Article history

Submitted: April 6, 2015

Accepted: July 17, 2015

Published on-line:

Sept. 26, 2015

## Corresponding author

Tomasz Golabek  
Collegium Medicum  
at the Jagiellonian University  
Department of Urology  
18, Grzegórzecka Street  
31-531 Cracow, Poland  
phone: +48 12 424 79 50  
elementare@op.pl

**Introduction** Despite improvements in surgical techniques and implementation of minimally invasive procedures, male stress urinary incontinence affects a substantial number of patients after prostatic surgery. In response to increasing demand of optimal treatment modality, new alternatives to artificial urinary sphincter have recently been introduced. This review summarises the therapeutic surgical options with their outcomes in management of postprostatectomy stress incontinence.

**Material and methods** We performed a literature review by searching the PubMed, Web of Science and Embase databases for articles published from January 2000 until April 2015 based on clinical relevance.

**Results** Artificial urinary sphincter is currently considered the “gold standard” treatment of male stress urinary incontinence. Although the new devices in this group have recently been investigated, the AMS 800 remains the only widely used implant. Male slings and adjustable continence devices, achieve the social continence rates up to 60%. Periurethral injections of bulking agents, have limited efficacy of male stress incontinence. Argus sling and ProACT are both associated with substantial explantation rates. Stem cell therapy is a promising option but still requires additional testing.

**Conclusions** The development of new alternatives to artificial urinary sphincter is constantly progressing. Although recently introduced minimally invasive treatment options have not yet surpassed the outcomes of the artificial urinary sphincter they should continue to be evaluated and compared against the gold standard.

**Key Words:** bulking agents ◊ pro-ACT ◊ artificial urinary sphincter ◊ stem cells

## INTRODUCTION

Stress urinary incontinence (SUI) has been defined by the International Continence Society as the involuntary leakage of urine on effort or exertion, sneezing, or coughing [1]. In men this type of incontinence most commonly occurs after prostatectomy for benign or malignant disease. Despite improvements in surgical techniques and implementation of minimally invasive procedures, the reported prevalence of post radical prostatectomy (RP) SUI varies widely, ranging 4–50% in contemporary series [2, 3, 4].

On contrary, the prevalence of SUI following transurethral resection of the prostate (TURP) and holmium laser enucleation of the prostate (HoLEP) is much less common (approximately 1%) [5]. However, TURP performed in the setting of prior external beam irradiation or brachytherapy can result in particularly high incontinence rates of up to 18% [6]. The observed discrepancy in the published post radical prostatectomy SUI rates results from differences in definition of incontinence used by different authors, data collection methodology, and evaluation outcomes (patient versus surgeon-reported conti-

nence). Although small degree of SUI may not affect patient's well-being, moderate-to-severe post prostatectomy incontinence negatively impacts men's quality of life [7, 8]. The most common mechanisms of SUI after radical prostatectomy include a direct injury to the urethral sphincter itself, as well as, to adjacent supportive tissues and nerves [9, 10]. Whereas after TURP urinary incontinence is most likely due to the pre-existing abnormalities of bladder function rather than direct sphincter injury [11]. Improvements in urinary leakage may occur spontaneously or with conservative measures within the first 12 months after prostatic surgery. However, management of persistent incontinence is often challenging and may be frustrating for both a patient and his doctor, and as a consequence, it can negatively affect doctor-patient relationship.

Initial management of male SUI consists of pelvic floor muscle training, biofeedback and electrical stimulation. Should conservative approach fail, surgical interventions become inevitable. Currently there have been several competitive products available for operative treatment of male SUI. This paper summarises indications, technical and surgical aspects, risk factors, reported complications and challenges of different treatment modalities offered to men with post prostatectomy stress urinary incontinence.

## MATERIAL AND METHODS

A comprehensive search strategy was applied for PubMed, Web of Science and Embase electronic databases from January 2000 until April 2015. We selected all human research articles published in English, not classified as case report, review, editorial, comment, letter, or news. The search strategy included the following terms: "male urinary incontinence", "urinary stress incontinence", "post prostatectomy", "post-prostatectomy", "prostatectomy", "TURP", "HoLEP", "treatment", "suburethral sling", "suburethral slings", "transobturator tape", "transobturator tapes", "transobturator suburethral tape", "trans-obturator tape", "artificial urinary sphincter", "artificial urinary sphincters", "artificial genitourinary sphincter", "artificial genitourinary sphincters", "bulking agents", "augmentation agents".

## RESULTS AND DISCUSSION

The search for relevant papers was performed independently by 2 reviewers, in duplicate. The search strategy yielded 1478 citations. 1332 of these were excluded after screening titles and abstracts and fur-

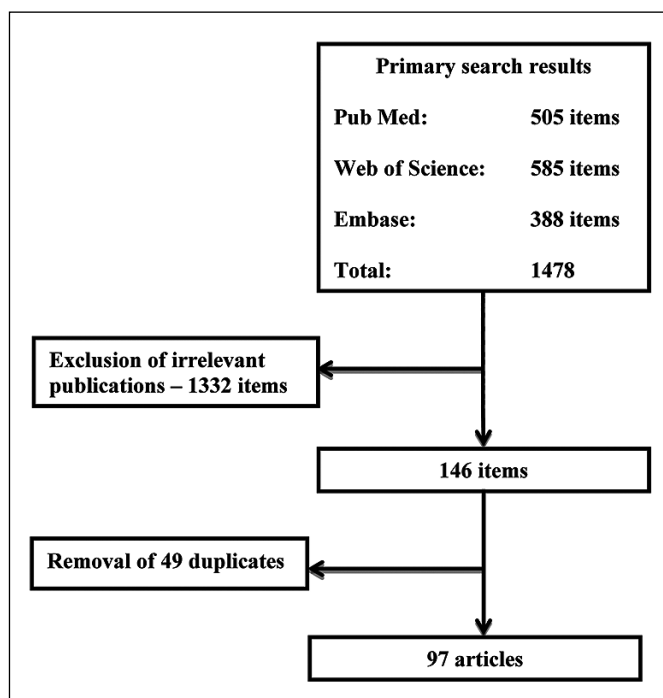


Figure 1. Flow diagram of study selection.

ther 49 items as being duplicated. Eventually, this overview was based on the text of the remaining 97 studies (Figure 1).

## Bulking agents

Intramural urethral bulking agents (synthetic or autologous) injections are one of the latest treatment methods of the MSUI [12–18]. The aim of this approach is to increase the intraurethral pressure and thus enhance the continence. For this reason the U.S. Food and Drug Administration (FDA) has approved the use of bovine glutaraldehyde cross-linked collagen (Contigen; CR Bard, Covington) in 1993. It was generally well tolerated by patients and had relatively low complication rates [12, 15, 16, 17]. However, the long term treatment outcomes of this method proved unfavourable [15, 17]. Moreover, in order to maintain the therapeutic effect several repeat injections are often required. The most commonly used bulking agent substances have generally small volume of distribution, and, do not migrate to other organs [13, 16]. However, the use of Teflon was withheld after animal studies found that it migrated into the lymph nodes, the brain, the spleen and the lungs [16]. The early treatment failure rates with bulking agents approach 70%, and increase even further with time despite repeat treatments [12–16]. Another complication of this technique is the development of local inflammation, which can lead to so-called frozen urethra

[13, 16]. Bulking agents, despite its minimal invasiveness, can only be offered to narrow cohort of patients with only mild urinary incontinence.

### Stem cell therapy

To date, only few studies have examined the efficacy of autologous adult-derived stem cells for the management of MSUI in human patients. Mitterberger et al. reported results of his study from 2008 where 41 of the 63 male patients (65%) with SUI after radical prostatectomy were continent 12 months following injection of autologous myoblasts and fibroblasts [18]. In addition, a significant improvement in quality of life scores, the thicknesses of the urethra and the rhabdosphincter, as well as, the increased contractility of the rhabdosphincter were observed after a period of 1-year. Further confirmatory data regarding the benefit of muscle-derived stem cells application for treatment of MSUI have been reported by Cornu et al. [19]. In addition to MDSCs, adipose-derived stem cells (ADSCs) have also been investigated for treatment of MSUI [20, 21]. The encouraging preliminary results were evidenced by both functional and imaging studies. Table 1 summarises the clinical studies of autologous mesenchymal-derived stem cells in men with SUI after prostatic surgery.

### Tape procedures

Tape procedures were first used in 1958 to treat male incontinence post radical prostatectomy. John L. Berry was the first who used acrylic prosthesis, which he implanted between the bulbar urethra and bulbospongiosus muscles just below the urogenital diaphragm. The aim of this procedure was to improve the urinary continence *via* supporting, elongation and pressing onto the urethra. In his study dating 1961 Berry [22] reported successful treatment outcomes achieved in 45% of his cases. Currently used tape procedures in the treatment of urinary incontinence vary in terms of tape fix-

ing method. Bone anchored male slings (BAMS), for example, are fixated to the bone [23]. Clinical trials assessing BAMS (InVance tape) treatment success rates (no need to use pads) reported results between 36% and 65% [23, 24]. The highest rates of successful BAMS treatment were reported by Madjar [25]. During 12 months of follow-up 86% of subjects were considered cured (0-1 pads/day), significant improvement was reported in the remaining 14%. However, others reported BAMS treatment failure rates ranging between 15% and 60% [23, 24]. The exceptionally high treatment failure rates (85%) have been consistently reported in men who underwent radiation therapy. Ultimately, high rates of treatment complications (pelvic pain within first 3 months (<76%), infections (15%), increased post voiding residual urine volume (12%), infections and trauma to the pubic bones (5%)), contributed to declining popularity of BAMS systems [23, 24, 25]. Additionally, they have been superseded by the novel and more efficacious treatment options.

New tape generations were subsequently introduced and designed to allow modification of either under or overcorrection of tension. The Argus and Reemex tapes are examples of such adjustable sling systems. Argus Adjustable System consists of thick silicone-foam pad just under the bulbar urethra, which is connected with two silicone cone columns. After bulbar preparation (bulbospongiosus muscle remains intact), and freeing up the crural roots of the corpora cavernosa, two slings are placed: first in the region of the bulbar urethra and second around the incision site just above the pubic symphysis. They allow for moving silicone cone columns into the suprapubic region. The silicone rings are placed over the columns and then attached to the fascia of the rectus abdominis muscle. This allows to attain high leak point pressure during surgery (maximal 45 cm H<sub>2</sub>O), and further adjustment if needed [26].

The Reemex sling is similarly applied [27, 28]. A polypropylene mesh located under the bulbar urethra is connected with bilateral longitudinal

**Table 1.** Clinical studies of autologous mesenchymal-derived stem cells for male stress urinary incontinence.

Author [reference]	Number of male patients	Grade of MSUI	Stem cell source	Harvesting Tissue	Duration of follow-up	Morbidity
Mitterberger [17]	63	Severe	MDSCs	Biceps muscle	12 months	No
Cornu [18]	12	ND	MDSCs	Deltoid muscle	12 months	UTI in 3 men
Yamamoto [19]	3	Moderate	ADSCs	Anterior abdominal wall	6 months	No
Gotoh [20]	11	ND	ADSCs	Anterior abdominal wall	12 months	No

MSUI – male stress urinary incontinence; ND – not described; MDSCs – muscle-derived stem cells; ADSCs – adipose-derived stem cells; UTI – urinary tract infection

silicone fortifications, which extend towards the mechanical regulator located subcutaneously on fascia of the rectus abdominis muscle in the suprapubic region. The mesh is connected to monofilament traction threads, which are connected to so-called "Varitensor". It allows for continuous tension adjustment if needed.

The studies examining the efficacy of the Argus tape treatment of moderate to severe urinary incontinence have reported 79% success rates, and in 38.6% tape tension readjustment was needed [27]. The Reemex tapes have similar efficacy (up to 83%) [28]. The most commonly reported treatment complications include chronic pelvic pain (15%), trauma to the bladder (about 10%), infections and erosions necessitating tape removal (8-12%) [26, 27]. Explantation rates for Argus tape due to complications may be as high as 15.8% [27].

Another type of tape treatment of MSUI is the AdVance (American Medical Systems) transobturator sling system device. It consists of polypropylene mesh sling with two single-use needle passers. During the AdVance system implantation the bulbocavernosus muscle is dissected and moved aside so the urethral bulb could be exposed [29]. The mesh sling is positioned over the proximal urethral bulb and the introducer needle is passed through the stab incision reaching the external obturator muscle and obturator membrane. The mesh sling is sutured and both sling ends are pulled simultaneously to achieve appropriate tension. Incontinence cure rate defined as no pad usage has reached 73.7% in studies assessing efficacy of this method [29]. The most commonly reported treatment complications include postoperative urinary retention (21%), infections (0.8%), chronic pelvic pain (0.4%) [29].

Virtue (Coloplast) is the latest achievement among all currently used male slings. It is the hybrid of previously described sling methods. It consists of 5.5 x 7 cm suburethral propylene mesh sling, and four arms. There are two transobturator and two pre-pubic arms [30]. The Virtue system covers relatively large surface of the urethra and additionally moves it proximally. In the studies with minimum 12-month follow-up the objective improvement of urinary incontinence evaluated with 24-hour pad weight test with more than 50% reduction of symptoms was achieved in 79.2% of patients [30].

### ProACT System

ProACT (Uromedica) is another treatment option of MSUI, which has been in use since 2001. It consists of two adjustable silicone elastomer implants, similar to those used in artificial urinary sphinc-

ters (AMS 800, ZSI 375). Each device contains two balloons attached to a titanium port. The balloons are placed periurethrally at the bladder neck just proximal to the external sphincter [31]. Adjustment of balloon pressure can be facilitated *via* percutaneous injection. The efficacy of this treatment, measured as usage of 0-1 pads daily, has been reported as high as 67%. This, however, often requires balloon pressure re-adjustment. The most commonly occurring complications of this method include urethral erosions, infections or balloon malpositioning requiring device explantation in up to 18% of cases [31].

### Artificial urinary sphincters

#### AMS 800

The AMS 800 (American Medical Systems, USA) is the most renowned artificial urinary sphincter, which has been implanted to almost 150,000 patients during last 40 years. Scott, Bradley and Timm were the first to perform the artificial urinary sphincter implantation in 1972 [32]. It consists of three components: one is a circular cuff placed around the urethra, second is a pump-valve piece within the scrotum and the third is a small fluid filled balloon. The entire system is internally connected *via* silicone catheters and filled with isotonic solution ascertaining that no air bubbles are present. The cuff is typically being placed around the urethral bulb or the bladder neck. The cuff size is selected based on the intraoperatively measured urethral diameter. The pump-valve is placed in the most convenient position within the scrotum allowing for device self-re-adjustment if required. The fluid filled container sits in the abdominal wall, peritoneal cavity, or space of Rezius nearby the bladder. The operative time can range between 40 and 90 minutes [33, 34].

Artificial urinary sphincter implantation is the gold standard treatment of stress urinary incontinence due to the internal sphincter dysfunction (ISD) following radical prostatectomy [2, 3, 8, 33, 34]. Although the procedure itself has been well standardised, and the latest released AMS 800 represents the sixth device generation, the operative risk with both early and late complications remains high. Infection at the site of the incision further leading to device removal is one of the most commonly reported. It typically occurs in 1.8% to 10% of all cases [34]. The risk can be even greater if predisposing factors such as diabetes mellitus co-exist. Artificial urinary sphincter cuff erosion is another serious treatment complication [33, 34]. It can develop on average 20 months after the surgery [33]. The risk has been reported as 9% [33, 34]. The de-

**Table 2.** Outcomes, complications, advantages and disadvantages of different procedures used in surgical treatment of stress urinary incontinence in men

Technique	1-year success rate (%)	3-year success rate (%)	5-year success rate (%)	10-year success rate (%)	Mechanical Failure (%)	Complications (%)	Explantation (%)	Advantages	Disadvantages
Bulking agents	12-69	–	–	–	–	TUR:3	–	Minimally invasive technique	Low effectiveness Repeat injection often needed Local inflammation Limited to mild urinary incontinence only
Stem cell therapy	65	–	–	–	–	UTI:25	–	Minimally invasive technique	Short follow-up Small sample size and number of studies available
BAMS	16-87	–	–	–	–	Infection:2-15 Erosion:0-3 Perineal pain:76 De novo urgency/OAB:0-14	0-17	Relatively easy implantation Well established technique	Perineal pain commonly occurring Low effectiveness in many studies
Argus	17-79	2.1years: 69	–	–	–	Infection :3-8 Erosion:12 Persistent perineal pain: 15 TUR:8	15-35	Relatively easy implantation Well established technique	Tape tension readjustment often required Perineal pain commonly occurring
Reemex	42-83	32months: 64	–	–	–	Infection:2 Erosion:4	6	Relatively easy implantation Well established technique	Tape tension readjustment often required Perineal pain commonly occurring
AdVance	9-56	39months: 60 3.9years: 42	–	–	–	Infection- 0.6-0.8 Chronic perineal pain:0.4-10 TUR:9-21 Mild dysuria:14	0.6-0.9	Relatively easy implantation Well established technique	High rates of urinary retention
Virtue	79.2 – reduction of symptoms	–	–	–	–	There were no cases of prolonged retention and no severe adverse events.	–	Relatively easy implantation	Short follow-up Small sample size and number of studies available
ProACT	35-71	20months: 67	56months: 66	–	–	Infection: 3 Erosion:8	8-58	Pressure adjustment within the circuit	Short follow-up Repeat balloon pressure re-adjustment often needed Mild to moderate urinary incontinence patients preferable
AMS 800 TM	82-95	69-81	59-85	73	8-45	Infection:2-10 Erosion:2-17 Urethral atrophy:22 TUR:1-32	4-47	Long history on the market Strong and reliable data Highly effective Dual cuff system Contrast medium within the circuit	Complex multipart design Expensive Complex implantation technique Relatively high rate of adverse events
ZSI 375	73-94.2	–	–	–	–	Infection:5-8 Erosion:2-11	11	Simplified one-piece device Relatively easy implantation Cuff pressure readjustment possible post-op Highly effective	Expensive Relatively high rate of adverse events Sparse reliable data Studies with short follow-up only
Flow-Secure	89-97	–	–	–	15	Infection:13 Erosion:0	22-28	Easy implantation Low risk of urethral erosion Low rate of technical issues Cuff pressure readjustment possible post-op Highly effective	Expensive Sparse reliable data Studies with short follow-up only
PUC	73-92	–	39-79	–	3.5-8.9	Infection :2-10 Erosion:2.3-6.8	4.6-41.1	Easy implantation Low cost Pressure readjustment Optional self-catheterisation with no cuff deflation	High rate of adverse events High rates of device explantation

S.C – success rate; BAMS – Bone Anchored Male Slings; AMS 800 TM – American Medical System 800 TM, ZSI 375 – Zephyr Surgical Implants 375, PUC – Periurethral Constrictor; TUR – transient urinary retention; OAB – overactivity. Success has been defined as use of 0 to 1 pads after the procedure



vice must be explanted should this occur. The next large group of complications, which is normally independent of neither the operator nor the patient, includes technical issues affecting the sphincter part of the device. The mean time of these occurring is roughly 68.9 months postoperatively [33, 34]. The exact fault relates to either specific part malfunction of the permeability of the entire system. In spite of all aforementioned treatment drawbacks, artificial urinary sphincters help to control urinary incontinence symptoms in 85% to 95% of patients post radical prostatectomy, who admit both achieving social continence (1 pad/day), as well as, quality of life improvement [33, 34]. Comparison of outcomes, complications, advantages and disadvantages of AMS 800 versus other devices and methods used for surgical treatment of stress urinary incontinence in men is presented in Table 2.

### ZSI 375 artificial urinary sphincter

In 2007, Swiss brand ZEPHYR Surgical Implants (Geneva, Switzerland) patented their own artificial urinary sphincter – ZSI 375. Compared to AMS 800 this product significantly differs in terms of its design. The two-part device composition (cuff and pump connected *via* kink-resistant tubing) eased off the ZSI 375 implantation process in terms of technical difficulty, as well as, operative time compared to AMS 800. As there is no third part of device which otherwise would be left in the obturator fossa, the risk of damage to either the bladder or to the intestine is minimised. Although it is a one-piece implant it still requires filling in with saline solution and ascertaining that no air was left within the circuit. It is hugely advantageous that cuff pressure can be postoperatively adjusted by refilling the amount of solution present within the circuit. This can be achieved percutaneously through the scrotal skin. The device is usually activated 6 to 8 weeks post-op. This method remains effective at one year following implantation in 79% of cases (0-1 pad/day) [35]. Infection at the site of incision is one of the most commonly reported complications. According to Staerman et al. [35] the frequency is 8.3%. Urethral erosion is also among the most significant complications of this technique necessitating device re-implantation (rate: 11.1%). The erosion results from local ischaemia caused by the cuff pressure. It appears to be more prevalent among patients after radiation therapy. The cuff pressure is typically between 60 and 80 cm H<sub>2</sub>O, occasionally, however, it can be as high as 90-100 cm H<sub>2</sub>O. At times the device can be faulty or damaged, which occurs approximately in 8-45% cases [35].

### FlowSecure artificial urinary sphincter

The FlowSecure (RBM, U.K.) artificial urinary sphincter is a new prosthesis for the management of urinary incontinence due to the intrinsic urethral sphincter deficiency. It has been designed and developed by Professors Craggs M. D. and Mundy A. R. from Great Britain in 2006 [36]. This sphincter is filled with saline, therefore both ultrasound scan and, in some cases, MRI are adequate radiographic techniques for its evaluation [36, 37]. Similarly to the ZSI 375 this is a one-piece device composed of two fluid-filled reservoirs, sphincter cuff and pump. The reservoirs are placed in the paravesical space, a cuff surrounds the urethral bulb and a control pump with a self-sealant port is placed in patient's scrotum. Montes et al. presented 9 cases of men with stress incontinence due to radical prostatectomy treated with FlowSecure artificial urinary sphincter [36]. The patients were followed for the minimum period of 12 months. In two patients devices had to be removed for technical reasons. Excellent results were obtained in the remainder of cases. In another study by Rodriguez et al. 100 patients with stress urinary incontinence of various aetiologies were looked at [37]. The implantation period was ranging between 38 and 47 minutes. The mean hospital stay was 4.3 days. Overall, socially satisfactory continence was achieved in 89 patients (1 pad/day). The adverse events reported were: early infections (8%), late infections secondary to pressurization procedures (5%), perforation of the pump at pressurization (9%), other mechanical failures (6%). No erosions were noted, however, the FlowSecure implants had to be removed in 28 men [37].

### Periurethral Constrictor

The Periurethral Constrictor (PUC) (Silimed, Brazil) urethral sphincter was first introduced in 1996 by Dr. Fabio Vilar for the treatment of urinary incontinence caused by the external urethral sphincter deficiency in children. These are also one-piece devices consisting of two integral components. The sphincter cuff is permanently connected with an injection port *via* 20 cm long silicone tubing. The puncturing port is implanted subcutaneously at the iliac fossa. The device is activated 6 to 8 weeks after implantation. The mechanism of action of the PUC is based on the hydrostatic pressure effect induced by the saline solution within the cuff on the urethral bulb. The reported efficacy of PUC in post prostatectomy MSUI was 86% after one year of follow-up and 73.3% after 42 months [38, 39]. However, the frequency of the PUC explantation due to complications (ero-

sion, infection) can be as high as 41.07% [40]. Despite all the limitations PUC has also some advantages. These are low cost, simple and easy to install design, easy cuff pressure self-adjustment mechanism.

## CONCLUSIONS

Despite improvements in surgical techniques stress urinary incontinence in men after operative treatment of prostate diseases is relatively common. If noninvasive management fails, surgical treatment is a recommended option. AUS remains the gold standard for management of MSUI as it has the best short-, intermediate- and long-term outcomes. However, new minimally invasive procedures, such as the

male sling and adjustable continence device, have recently become acceptable alternatives to AUS with the social continence rates up to 60%. Periurethral injections of bulking agents, have limited efficacy for MSUI. Argus sling and ProACT are associated with substantial explantation rates secondary to urethral erosion or infection, reaching up to 15.8% and 18%, respectively. To date, only few studies have examined the efficacy of autologous adult-derived stem cells for the management of MSUI in humans. Although the short-term results are encouraging, stem-cell therapy cannot be currently recommended.

## CONFLICTS OF INTEREST

The authors declare no conflicts of interest.

## References

- Abrams P, Cardozo L, Fall M, et al. The standardisation of terminology of lower urinary tract function: report from the Standardisation Sub-committee of the International Continence Society. *Neurourol Urodyn.* 2002; 21: 167-178.
- Bauer RM, Bastian PJ, Gozzi C, Stief CG. Postprostatectomy incontinence: all about diagnosis and management. *Eur Urol.* 2009; 55: 322-333.
- Herschorn S, Bruschini H, Comiter C, et al. Surgical treatment of stress incontinence in men. *Neurourol Urodyn.* 2010; 29: 179-190.
- Gregorio SA, Rivas JG, Molina SS, et al. Laparoscopic radical prostatectomy training for residents: Hospital Universitario La Paz model. *Cent European J Urol.* 2014; 67: 247-252.
- Rassweiler J, Teber D, Kuntz R, Hofmann R. Complications of transurethral resection of the prostate (TURP)-incidence, management, and prevention. *Eur Urol.* 2006; 50: 969-979.
- Kollmeier MA, Stock RG, Cesaretti J, Stone NN. Urinary morbidity and incontinence following transurethral resection of the prostate after brachytherapy. *J Urol.* 2005; 173: 808-812.
- Rosen M. A simple artificial implantable sphincter. *Br J Urol.* 1976; 48: 675-680.
- Gundian JC, Barrett DM, Parulkar BG. Mayo Clinic experience with use of the AMS800 artificial urinary sphincter for urinary incontinence following radical prostatectomy. *J Urol.* 1989; 142: 1459-1461.
- Gomha MA, Boone TB. Voiding patterns in patients with post-prostatectomy incontinence: urodynamic and demographic analysis. *J Urol.* 2003; 169: 1766-1769.
- Radomski SB. Practical evaluation of post-prostatectomy incontinence. *Can Urol Assoc J.* 2013; 7: 186-188.
- Abrams PH. Investigation of postprostatectomy problems. *Urology.* 1980; 15: 209-212.
- Appell RA. Collagen injection therapy for urinary incontinence. *Urol Clin North Am.* 1994; 21: 177-182.
- Stenberg A, Larsson E, Lindholm A, Ronneus B, Stenberg A, Läckgren G. Injectable dextranomer-based implant: histopathology, volume changes and DNA-analysis. *Scand J Urol Nephrol.* 1999; 33: 355-361.
- Malizia AA Jr, Reiman HM, Myers RP, et al. Migration and granulomatous reaction after periurethral injection of polytef (Teflon). *JAMA.* 1984; 251: 3277-3281.
- Onur R, Singla A. Comparison of bone-anchored male sling and collagen implant for the treatment of male incontinence. *Int J Urol.* 2006; 13: 1207-1211.
- McGuire EJ. Urethral bulking agents. *Nat Clin Pract Urol.* 2006; 3: 234-235.
- Gomes CM, Broderick GA, Sánchez-Ortiz RF, Preate D Jr, Rovner ES, Wein AJ. Artificial urinary sphincter for post-prostatectomy incontinence: impact of prior collagen injection on cost and clinical outcome. *J Urol.* 2000; 163: 87-90.
- Mitterberger M, Marksteiner R, Margreiter E, et al. Myoblast and fibroblast therapy for post-prostatectomy urinary incontinence: 1-year followup of 63 patients. *J Urol.* 2008; 179: 226-231.
- Cornu JN, Doucet C, Sèbe P, et al. Prospective evaluation of intrasphincteric injections of autologous muscular cells in patients with stress urinary incontinence following radical prostatectomy. *Prog Urol.* 2011; 21: 859-865.
- Yamamoto T, Gotoh M, Kato M, et al. Periurethral injection of autologous adipose-derived regenerative cells for the treatment of male stress urinary incontinence: Report of three initial cases. *Int J Urol.* 2012; 19: 652-659.
- Gotoh M, Yamamoto T, Kato M, et al. Regenerative treatment of male stress urinary incontinence by periurethral injection of autologous adipose-derived regenerative cells: 1-year outcomes in 11 patients. *Int J Urol.* 2014; 21: 294-300.
- Berry JL. New procedure for correction of urinary incontinence: a preliminary report. *J Urol.* 1961; 85: 771-775.
- Mouracade P, Wagner B, Charles T, Lang H, Jacqmin D, Saussine C. Treatment of postoperative male urinary incontinence by bone-anchored male sling. *Prog Urol.* 2008; 18: 390-394.
- Comiter CV. The male perineal sling: intermediate-term results. *Neurourol Urodyn.* 2005; 24: 648-653.

25. Madjar S, Jacoby K, Giberti C, et al. Bone anchored sling for the treatment of post-prostatectomy incontinence. *J Urol.* 2001; 165: 72-76.
26. Romano SV, Huebner W, Rocha FT, Vaz FP, Muller V, Nakamura F. A transobturator adjustable system for male incontinence: 30-month follow-up of a multicenter study. *Int Braz J Urol.* 2014; 40: 781-789.
27. Hübner WA, Gallistl H, Rutkowski M, Huber ER. Adjustable bulbourethral male sling: experience after 101 cases of moderate-to-severe male stress urinary incontinence. *BJU Int.* 2011; 107: 777-782.
28. Sousa-Escandón A, Cabrera J, Mantovani F, et al. Adjustable suburethral sling (male Remeex system) in the treatment of male stress urinary incontinence: a multicentric European study. *Eur Urol.* 2007; 52: 1473-1479.
29. Cornu JN, Sèbe P, Ciofu C, et al. The AdVance transobturator male sling for postprostatectomy incontinence: clinical results of a prospective evaluation after a minimum follow-up of 6 months. *Eur Urol.* 2009; 56: 923-927.
30. Comiter CV, Rhee EY, Tu LM, Herschorn S, Nitti VW. The virtue sling-a new quadratic sling for postprostatectomy incontinence-results of a multinational clinical trial. *Urology.* 2014; 84: 433-438.
31. Rouprêt M, Misrai V, Gosseine PN, Bart S, Cour F, Chartier-Kastler E. Management of stress urinary incontinence following prostate surgery with minimally invasive adjustable continence balloon implants: functional results from a single center prospective study. *J Urol.* 2011; 186: 198-203.
32. Scott FB, Bradley WE, Timm GW. Treatment of urinary incontinence by implantable prosthetic sphincter. *Urology,* 1973; 1: 252-259.
33. Kim SP, Sarmast Z, Daignault S, Faerber GJ, McGuire EJ, Latini JM. Long-term durability and functional outcomes among patients with artificial urinary sphincters: a 10-year retrospective review from the University of Michigan. *J Urol.* 2008; 179: 1912-1916.
34. Elliott DS, Barrett DM. Mayo Clinic long-term analysis of the functional durability of the AMS 800 artificial urinary sphincter: a review of 323 cases. *J Urol.* 1998; 159: 1206-1208.
35. Staerman F, Llorens C, Leon P, Leclerc Y. ZSI 375 artificial urinary sphincter for male urinary incontinence: a preliminary study. *BJU Int.* 2013; 111: E202-206.
36. García Montes F, Vicens Vicens A, Ozonas Moragues M, et al. "FlowSecure" artificial urinary sphincter: a new adjustable artificial urinary sphincter concept with conditional occlusion for stress urinary incontinence. *Actas Urol Esp.* 2007; 31: 872-879.
37. Rodriguez DA, Ascanio EF, Barranco LF, Vicens AV, Garcia-Montes F. 100 Flowsecure artificial urinary sphincters. *Eur Urol Suppl* 2011; 10: 309.
38. Simone G, Guaglianone S, Papalia R, Leonardo C, Ferriero M, Gallucci M. Periurethral constrictor (Silimed): a new device for treatment of mild urinary incontinence Following radical prostatectomy. *J Urol.* 2009; suppl 4: 619.
39. Schiavini JL, Damião R, de Resee Júnior JA, et al. Treatment of post-prostate surgery urinary incontinence with the periurethral constrictor: a retrospective analysis. *Urology* 2010; 75: 1488-1492.
40. Lima RS, Barros EG, Souza CA, de O Vilar F, Lima SV. Periurethral constrictor: late results of the treatment of post prostatectomy urinary incontinence. *Int Braz J Urol.* 2011; 37: 483-487. ■