

Technical Note

Treatment of the hook of hamate fracture with robot navigation: A note on technique

Fang Jie^{ID}, Zhu Hui^{ID}, Zheng Dawei^{ID}, Qi Weiya^{ID}

Department of Hand Surgery, Clinical Anatomy Laboratory, Xuzhou Renci Hospital, Jiangsu, China

ARTICLE INFO

Article history:

Submitted September 6, 2021

Received in revised form

November 30, 2021

Last revision received

April 8, 2022

Accepted May 20, 2022

Keywords:

The hook of the hamate fracture

Robot navigation

Minimally invasive

ORCID iDs of the authors:

F.J. 0000-0003-1231-7155;

Z.H. 0000-0003-2008-1437;

Z.D. 0000-0003-2568-8270;

Q.W. 0000-0002-0002-2838.

ABSTRACT

Objective: The aim of this study was to demonstrate a new robotic technique for the fixation of the fracture of the hook of hamate.**Methods:** In this retrospective study, six patients who had undergone treatment of the hook of hamate fracture with a new technique using robot navigation were included. Patients were evaluated postoperatively with flexion - extension and radial-ulnar range of wrist motion, and were measured using a goniometer. Grip strength and pinch strength were measured and compared with the contralateral wrist at the final follow-up. The Visual Analog Scale (VAS) and the Mayo Wrist Score were used to evaluate and record the recovery outcome of the wrist.**Results:** Primarily, healing was achieved at 12.3 weeks postoperatively. At the final follow-up (5-22 months, average 13.1 months) the VAS score of the wrist was an average of 0.3 (0-2); the mean radial-ulnar deviation was 64.7°; the average of the flexion and extension range of motion was 141.9°; the average grip strength was 40.9 Kg; the average pinch strength was 11.8 Kg and the average Mayo Wrist Score was 95.8.**Conclusion:** This study has shown us that treatment of nondisplaced or minimal displaced fractures of the hook of the hamate with robot navigation is a viable technique with satisfactory clinical and radiological results.

Introduction

The hook of the hamate fracture is a rare pathology representing 2%-4% of all carpal bone fractures and is more common than hamate body fracture.¹⁻³ The fracture is most frequently attributed to 2 main mechanisms: direct blow and compression to the hamate on the heel of the hand or cumulative chronic injury during sports activities such as using a racquet or a bat sport.^{4,5} And the hook of the hamate fracture is most usually seen in racket sport athletes, golfers, and baseball players.^{6,7} As the fracture is difficult to visualize and appraise on routine radiographs of the wrist, the diagnosis often cannot be made at the time of the initial injury.⁸ Therefore, delayed diagnosis is not uncommon; unfortunately, it usually associates with high nonunion rates.⁹ Other factors of nonunion include poor blood supply and fragment displacement with unmerited continuous movement of the fourth and fifth digits.⁹⁻¹¹

Therefore, how to manage the small fragment is still a challenge for a hand surgeon or an orthopedic surgeon. Herein, we present a new commercially available robot associated with the 3D fluoroscopy unit for surgical navigation called TiRobot (TINAVI Medical Technologies Co., Ltd., Beijing, China) to address it.

Materials and Methods

After we obtained institutional review board approval (the protocol number of ethics: RC201911001), we retrospectively 6 patients who suffered from the hook

of the hamate fracture and were treated by closed reduction and internal fixation with a headless compression screw under robot navigation in our center between November 1, 2019, and October 31, 2021.

A typical case

A 37-year-old man whose left arm was caused a bruise injury by a heavy object leading to his left hook of the hamate and radius fractures was examined. Then he underwent the closed reduction percutaneous internal fixation under the TiRobot navigation for the hook of the hamate in our center (Figure 1A-E).

Surgical technique

The patient was in a supine position with the injured limb abduction on a radiolucent table, under general anesthesia, without the tourniquet assisted. A custom-built radiolucent jig was used to affix the wrist, and fixation of the wrist had to be stable and secure on the table. The image intensifier was positioned caudally.

Based on the 3D volumetric image data, the hamate was targeted at the TiRobot workstation. The entry point, track, and length of the headless compression screw were simulated and planned in a visualized TiRobot workstation image screen. And the simulated entry point was designed and modified in the workstation in the axial, sagittal, and coronal planes to acquire the optimal position which was in an appropriate position in the 3D volumetric modal of the hook. The final error of the simulated model was

Corresponding author:
Qi Weiya
qiweizheng@126.com



Content of this journal is licensed under a Creative Commons Attribution-NonCommercial 4.0 International License.

Cite this article as: Jie F, Hui Z, Dawei Z, Weiya Q. Treatment of the hook of hamate fracture with robot navigation: A note on technique. Acta Orthop Traumatol Turc. 2022;56(4):296-299.

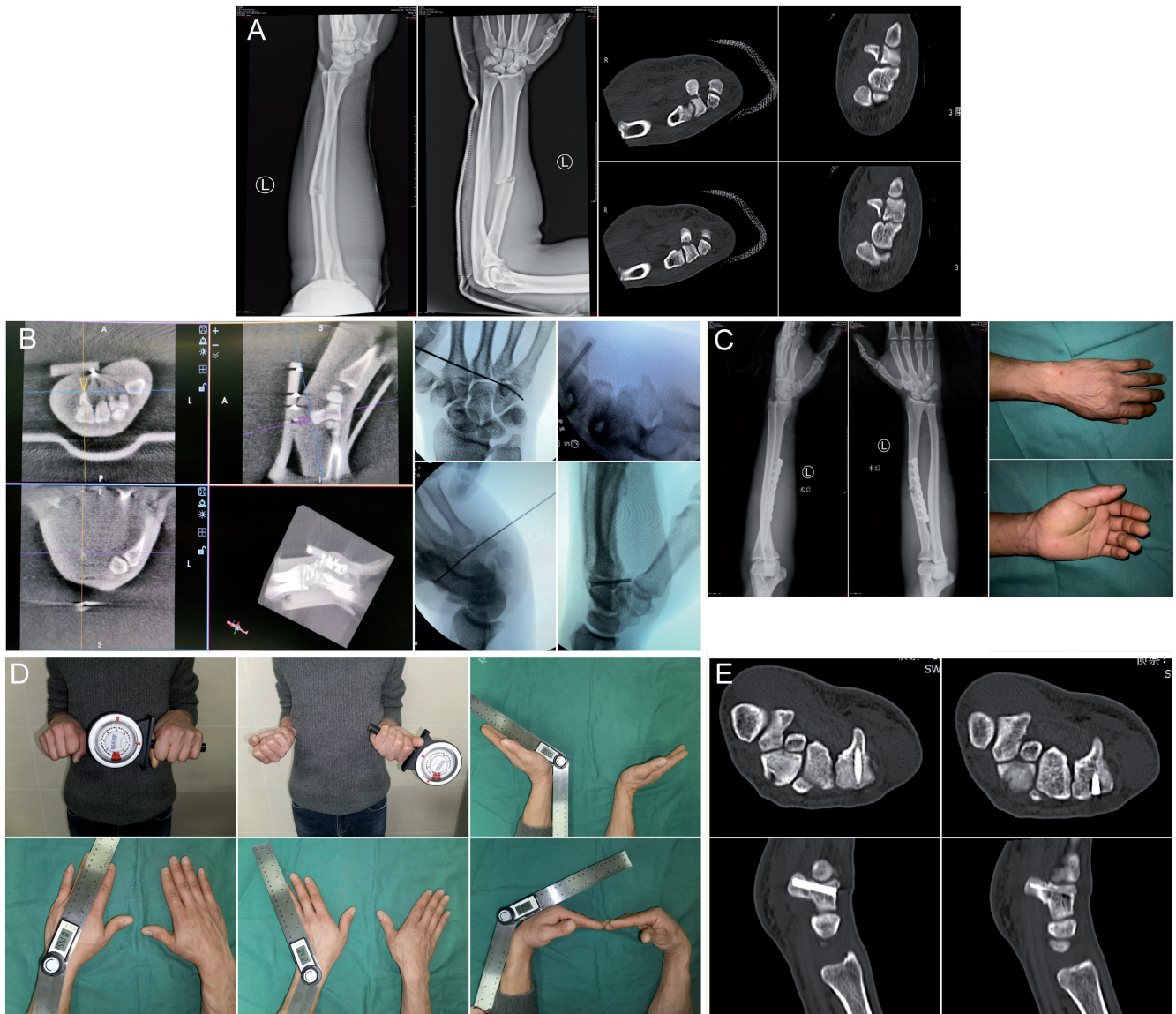


Figure 1. A-E. The 37-year-old man whose left arm was caused a bruise injury by a heavy object and underwent the closed reduction percutaneous internal fixation under the TiRobot navigation in our center. The X-ray film and CT images of the patient of the preoperation (A). Intraoperative guidance K-wire was inserted into the fragments and then the headless compression screw was inserted into the hook through the trajectory with robot navigation. (B). The X-ray immediately after operation and the appearance of the hand (C). After follow-up for 9 months, the function and appearance recovered satisfactory (D), and the CT images of the hook of the hamate fracture healing. (E). CT, computerized tomography.

less than 1 mm. Once the planning was confirmed and performed, the TiRobotic arm automatically moved to the skin anchor point and navigated the trajectory.

After that, a percutaneous 0.8 mm K-wire as a guide pin through the wire aiming guide was drilled into the hook; a less than 0.5 cm incision was made at the anchor point of the dorsal hand while the tip

of the K-wire penetrated the dorsal cortex of the hamate and bluntly separated to the tip to avoid damage the extensor tendon, nerve, and vessel of the dorsal hand, and the position and trajectory was inspected by fluoroscopy. Once the result was optimal, a cannulated drill was used to drill the hole along the guide pin. As the parameter of the simulating design in the TiRobot workstation, a headless compression screw was inserted into the hook through the trajectory. Finally, the position and length of the screw were evaluated by fluoroscopy, and the wound was primarily closed with absorbable suture and dressed with self-adhesive bandage.

Postoperative Protocol

Physical rehabilitation program for the fingers of hand including active and passive began when the pain was relieved. The patient was reviewed in our department for 1, 2, 3, and 6 months and till the final follow-up. The hook of the hamate union was confirmed by computerized tomography (CT) scan while the line of fragment

HIGHLIGHTS

- Although the hook of the hamate fracture is rare, the treatment is still a challenge for surgeons. This study describes the utility of a new commercially available robot associated with 3D fluoroscopy unit for surgical navigation in treatment of hook of hamate fractures.
- In 6 patients with hook of hamate fractures, who received robotic assisted treatment, the mean time to achieve primary healing was 12.3 weeks. The fracture union was confirmed by CT in all patients, and the position of screw was also confirmed that it remained in its original implanted position.
- The results indicate that treatment of nondisplaced or minimal displaced fractures of the hook of the hamate with robot navigation may be a safe and effective technique.

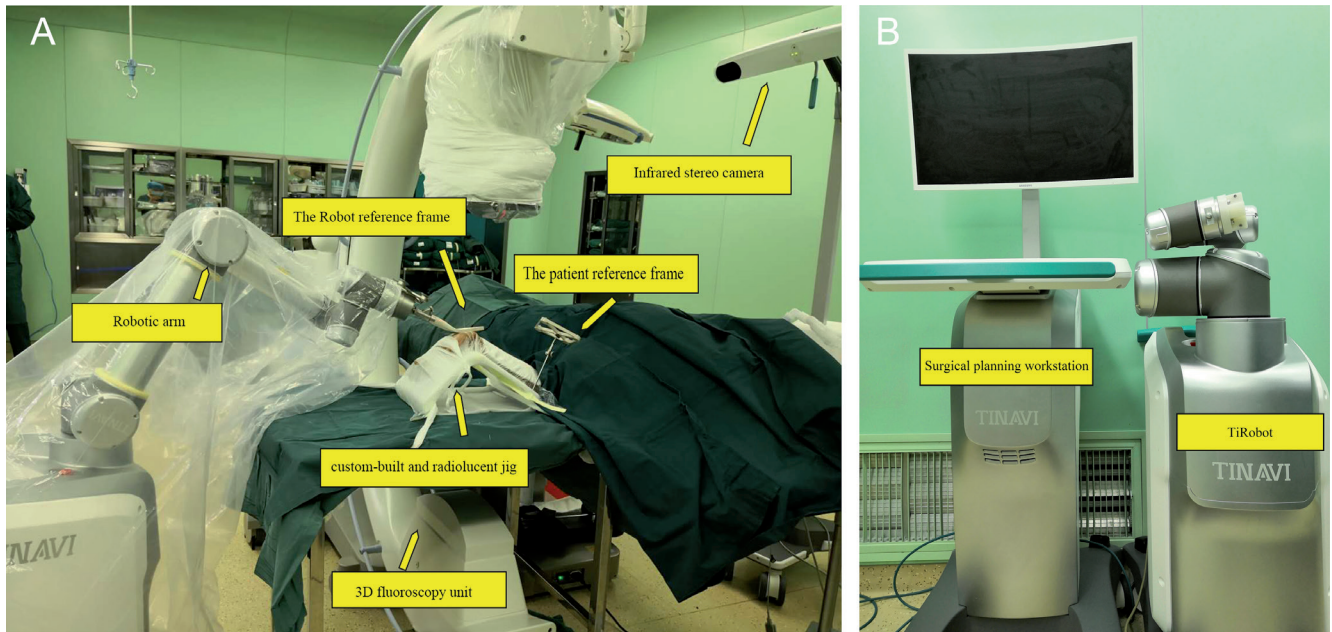


Figure 2. A, B. (A) Two reference frames of the robot are fixed onto the positioning jig and the robotic arm, respectively. The wrist of the patient is extended on the surgical table and stably fixed to the custom-built and radiolucent jig. (B) The surgical planning workstation which can receive the 3D volumetric image data and admit the surgeon to design and modify the entry point, path, and length of the percutaneous internal fixation screw in a visualized TiRobot workstation image screen.

fracture completely disappeared postoperatively. At the final follow-up, the flexion-extension and radial-ulnar range of the motion of the wrist was measured by a goniometer. The grip strength and the pinch strength were measured and compared with the contralateral wrist at the final follow-up. There was a visual analog scale (VAS) ranging from 0 (no pain) to 10 (severe pain). And the Mayo wrist score was used to evaluate and record the recovery outcome of the wrist.

Results

The hook of the hamate fracture of the 6 patients achieved primary healing 12.3 weeks postoperatively. The fracture union was confirmed by CT in all patients, and the position of screw was also confirmed that it remained in its original implanted position. The mean follow-up time was 13.1 months (5-22 months), the VAS score of the wrist was an average of 0.3 (0-2); the mean radial-ulnar deviation was 64.7°; the average of the flexion and extension activity was 141.9°; except the case 3 50-year-old patient, all of the forearm pronation and supination were 90°; the average grip strength was 40.9 kg; the pinch strength was 11.8 kg; the Mayo wrist score was 95.8, and all patients were rated excellent.

Discussion

The TiRobot is a robotic navigation system (TINAVI Medical Technologies, Beijing, China) with an optical tracking system, a stereotactic robotic arm with 6° of freedom, and a surgical planning workstation.^{10,12} And it associates with a 3-dimensional (3D) fluoroscopy unit (ISO-C3D, Siemens, Erlangen, Germany) which was used for capturing 3D image and guiding K-wire positioning (Figure 2A, B).^{10,12}

The optical tracking device as the eyes of the TiRobot consists of an infrared stereo camera and 2 reference frames. The one reference

frame is patient reference which is stably and securely fixed onto a customized and radiolucent the wrist positioning jig, the other is the robotic reference frame which is attached to the robotic arm to identify and collect the position information of the wrist relative to the robotic arm. They are the kernel component to guide the robot navigation to a planned position.

The 3D fluoroscopy unit is the image acquisition system which is used to capture and process the axial, coronal, and sagittal planes of the fractured bone, then the images are delivered to the TiRobot workstation to construct a 3D volumetric image for intraoperative planning, and its component including a 3D C-arm and a C-arm reference tracker, which can be circumferentially scanned images around the target.¹⁰ The position was confirmed by fluoroscopy while the C-arm and the reference frames were appropriately positioned; after that, an automated registration scan is performed, and the images will be circumferentially captured around the patient's wrist in fixed angular steps.

The accuracy of screw placement during surgery was inspected by comparison of the radiography results. The planning position and track of the interoperative implanted screws in all the patients were confirmed by postoperative X-ray and CT scanning, and the results showed that were the similar to X-ray and 3D volumetric image data. The length of the headless compression screw matched exactly with the intraoperative planning from the workstation length. And the results of accurate positioning, the dimensions of implants and the screw trajectories can successfully acquire. There were no cortical violations of either the dorsal or palm plane in all cases. There were no complications in intraoperation and postoperation. To the best of our knowledge, this method is the first case with robotic treatment for hamatum hook fractures. We believe that the treatment for the hook of hamate fracture with robot navigation is a new beginning and will certainly lead to future research.

Ethics Committee Approval: Ethics committee approval was received for this study from the Ethics Committee of Xuzhou Renci Hospital (RC201911001).

Informed Consent: Informed consent of all clinical cases has been signed.

Author Contributions: Concept - J.F., W.Q.; Design - W.Q.; Supervision - H.Z., D.Z.; Materials - W.Q.; Data Collection and/or Processing - J.F.; Analysis and/or Interpretation - J.F., H.Z., D.Z., W.Q.; Literature Review - J.F., H.Z., W.Q.; Writing - J.F.; Critical Review - H.Z., D.Z., W.Q.

Declaration of Interests: The authors have no conflicts of interest to declare.

Funding: The authors declared that this study has received no financial support.

References

1. Sochacki KR, Liberman SR, Mehlhoff TL, Jones JM, Lintner DM, McCulloch PC. Progression of hamate hook stress reactions in elite baseball players. *Orthop J Sports Med.* 2020;8(5):2325967120919389. [\[CrossRef\]](#)
2. Shewmaker C, Moses K. Nonoperative comminuted hamate fracture. *J Orthop Sports Phys Ther.* 2019;49(7):557. [\[CrossRef\]](#)
3. O'Shea K, Weiland AJ. Fractures of the hamate and pisiform bones. *Hand Clin.* 2012;28(3):287-300. [\[CrossRef\]](#)
4. Taleb C, Murachowsky J, Ruggiero GM. Hamate hook nonunion treated with a hook plate: case report and surgical technique. *Tech Hand Up Extrem Surg.* 2012;16(4):194-197. [\[CrossRef\]](#)
5. Suh N, Ek ET, Wolfe SW. Carpal fractures. *J Hand Surg Am.* 2014;39(4):785-791; quiz 791. [\[CrossRef\]](#)
6. Kato H, Nakamura R, Horii E, Nakao E, Yajima H. Diagnostic imaging for fracture of the hook of the hamate. *Hand Surg.* 2000;5(1):19-24. [\[CrossRef\]](#)
7. Li S, Khan A, Chen J, Tan J. Diagnosis of a hamate hook fracture with 3D reconstruction of computed tomography images: A case report and review of literature. *J Xray Sci Technol.* 2019;27(4):765-772. [\[CrossRef\]](#)
8. Xiao ZR, Zhang WG, Xiong G. Features of intra-hamate vascularity and its possible relationship with avascular risk of hamate fracture. *Chin Med J (Engl).* 2019;132(21):2572-2580. [\[CrossRef\]](#)
9. Xiong G, Dai L, Zheng W, Sun Y, Tian G. Clinical classification and treatment strategy of hamate hook fracture. *J Huazhong Univ Sci Technolog Med Sci.* 2010;30(6):762-766. [\[CrossRef\]](#)
10. Liu B, Wu F, Chen S, Jiang X, Tian W. Robot-assisted percutaneous scaphoid fracture fixation: a report of ten patients. *J Hand Surg Eur Vol.* 2019;44(7):685-691. [\[CrossRef\]](#)
11. Dashe J, Jones NF. A modified surgical approach through Guyon's canal and the proximal ulnar border of the carpal tunnel allows for safe excision of the hook of the hamate. *J Hand Surg Am.* 2019;44(12):1101 e1-1101 e5.
12. Le X, Tian W, Shi Z, et al. Robot-assisted Versus fluoroscopy-assisted cortical bone trajectory screw instrumentation in lumbar spinal surgery: a matched-cohort comparison. *World Neurosurg.* 2018;120:e745-e751. [\[CrossRef\]](#)