

A persistent primitive hypoglossal artery-posterior inferior cerebellar artery convergence aneurysm treated by stent-assisted coil embolization

A case report

Shi Zeng, MD, Donghong Yang, MD*, Huajiang Yang, MM, Lun-Shan Xu, MD, Min-Hui Xu, MD

Abstract

Rationale: Persistent primitive hypoglossal artery (PPHA) is often associated with intracranial anomalies such as aneurysms. Surgical treatment of aneurysms on the PPHA is challenging due to that the posterior circulation depends solely on PPHA.

Patient concerns: A case of an 83-year-old woman with a large aneurysm on PPHA presented with vertigo was reported.

Diagnosis: Three-dimensional angiogram revealed a wide-neck aneurysm on the PPHA.

Interventions: The aneurysm was successfully treated using a novel low-profile visualized intraluminal support stent-assisted coiling technique.

Outcomes: No complications occurred during the procedure. The final angiogram confirmed the patency of the posterior inferior cerebellar artery and the parent artery and its distal branches.

Lessons: Our case suggests that stent-assisted coil embolization is safe and effective for the treatment of aneurysms on the PPHA.

Abbreviations: LVIS = low-profile visualized intraluminal support, PHA = persistent hypoglossal artery, PICA = posterior inferior cerebellar artery, PPHA = persistent primitive hypoglossal artery.

Keywords: aneurysms, case report, persistent primitive hypoglossal artery, stent-assisted coil embolization

1. Introduction

Persistent primitive hypoglossal artery (PPHA) is the 2nd most common persistent carotid-basilar anastomosis^[1] with an incidence of 0.03% to 0.09%.^[2,3] PPHA causes the changes in the hemodynamics of the carotid and vertebrobasilar arteries, leading to intracranial vascular anomalies, such as aneurysms.^[4,5] Aneurysms on the PPHA occur in approximately 40% of patients with PPHA with intracranial saccular aneurysms.^[6] Since the hypoglossal artery is often the sole artery to provide blood supply for the posterior circulation, surgical treatment of aneurysms on the PPHA has a higher risk of ischemic

complications. Most aneurysms on the PPHA were treated by clipping or wrapping.^[7–10] Baldi et al has reported a case of a wide-neck aneurysm on PPHA, which was successfully treated with stent-assisted coil embolization.^[11] Here, we reported a case of an 83-year-old patient with a large aneurysm on PPHA, who was then successfully treated with a novel low-profile visualized intraluminal support (LVIS) stent-assisted coiling technique.

2. Case report

An 83-year-old woman was admitted to neurosurgery department of our hospital, presenting with episodic vertigo. Computed tomography angiography (CTA) showed a large aneurysm in the vertebrobasilar territory. A persistent hypoglossal artery (PHA) supplied the distal right vertebral artery ipsilateral to the aneurysm. The vessel entered the skull base through the hypoglossal canal (Fig. 1). The contralateral vertebral artery to the aneurysm was hypoplastic. The PHA was the dominant supply to the vertebrobasilar system. Diagnostic angiogram revealed that the PHA originated from the vertebral artery at the level of C2 (Fig. 2). A 3-dimensional angiogram was then performed to delineate the morphology of the aneurysm and assess for suitability of coiling embolization. The angiogram showed a wide-neck cylindrical aneurysm (4.3 × 8.3 mm) with a posterior inferior cerebellar artery (PICA) originating from the base (Fig. 3).

Stent-assisted coil embolization was chosen as the therapeutic regimen for this patient. Before endovascular therapy was performed, the patient administered with 100mg aspirin and 75 mg clopidogrel daily for 7 days. Under general anesthesia and

Editor: N/A.

The authors have no funding and conflicts of interest to disclose.

Department of Neurosurgery, Institute of Surgery Research, Daping Hospital, Army Medical University, Chongqing, China.

* Correspondence: Donghong Yang, Department of Neurosurgery, Institute of Surgery Research, Daping Hospital, Army Medical University, Branch Road, No 10, Yuzhong District, Chongqing 400042, China (e-mail: dh_yang18@163.com).

Copyright © 2019 the Author(s). Published by Wolters Kluwer Health, Inc. This is an open access article distributed under the terms of the Creative Commons Attribution-Non Commercial License 4.0 (CCBY-NC), where it is permissible to download, share, remix, transform, and buildup the work provided it is properly cited. The work cannot be used commercially without permission from the journal.

How to cite this article: Zeng S, Yang D, Yang H, Xu LS, Xu MH. A persistent primitive hypoglossal artery-posterior inferior cerebellar artery convergence aneurysm treated by stent-assisted coil embolization: a case report. *Medicine* 2019;98:39(e17151).

Received: 6 March 2019 / Received in final form: 19 July 2019 / Accepted: 20 August 2019

<http://dx.doi.org/10.1097/MD.00000000000017151>

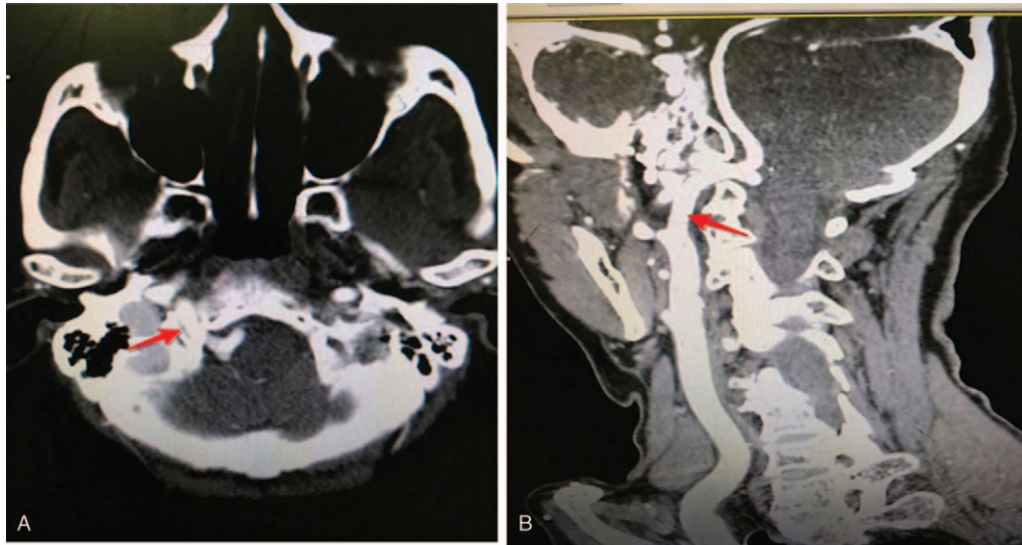


Figure 1. The vessel entered the skull base through the hypoglossal canal. A. Transverse position; B. Sagittal position.

systemic heparinization, a 6-Fr guiding catheter was advanced to the ostium of the PPHA and the working projection was chosen. Coaxially, a headway 21 microcatheter (Microvention/Terumo, Tustin, CA) with Synchro2 microguidewire (Target Therapeutics, Fremont, CA) was navigated into the parent artery to 2 cm beyond aneurysm neck. Then, an Echelon10 microcatheter (eV3, Irvine, CA) was catheterized over the same microguidewire into aneurysm sac. Under continuous fluoroscopic and roadmap guidance, a 3.5×20 mm LVIS stent (Microvention/Terumo) was deployed using the “shelf” technique as previously described by Du and Shankar^[12] to protect the PICA. Six microcoils (Axium, eV3) were used to completely obliterate the aneurysm (Fig. 4). No complications occurred during the procedure. The final angiogram confirmed the patency of the PICA and the parent artery and its distal branches. Heparin was administered for 24 hours to keep the Activated Clotting Time of whole blood (ACT) between 200 and 250 seconds. The patient was discharged 7 days later. She was told to continue clopidogrel for 3 months and aspirin for life. Six months after treatment, the patient recovered well, and

no more vertigo occurred. DSA follow-ups showed complete occlusion of the aneurysm. Patient has provided informed consent for publication of the case. The protocol was approved by the Ethics Committee of Daping Hospital, Army Medical University.

3. Discussion

The PPHA usually arises from the internal carotid artery and rarely from the external carotid artery.^[2] The diagnosis of PPHA is based on the following criteria^[13]: PPHA originates from the cervical part of the internal carotid artery at C1-C2 vertebral level; PPHA enters the posterior cranial fossa along with the accessory nerve through the hypoglossal canal; Basilar trunk is filled only beyond its anastomosis with the PPHA; Vertebral arteries and posterior communicating arteries may be hypoplastic or absent. In our case, all these diagnostic criteria were satisfied.

The PPHA is more common in females and on the left side. It may be associated with intracranial arterial aneurysms, ischemic

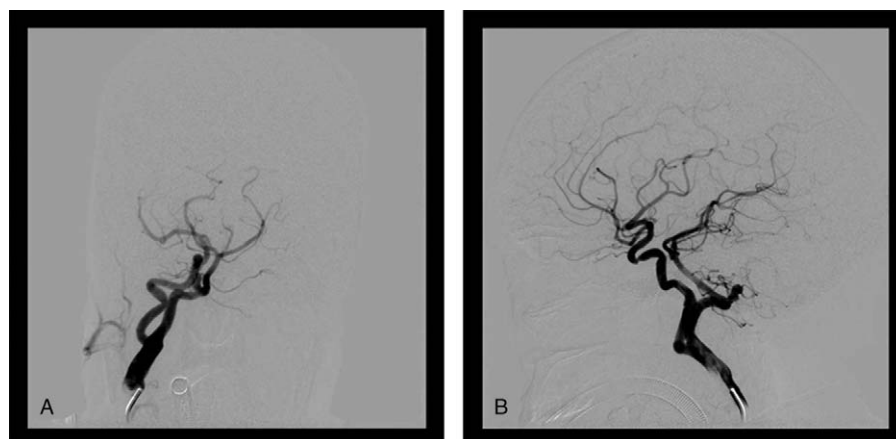


Figure 2. Diagnostic angiogram revealed that the persistent hypoglossal artery originated from the vertebral artery at the level of C2. A. The contralateral vertebral artery to the aneurysm was hypoplastic; B. The PPHA was the dominant supply to the vertebrobasilar system.

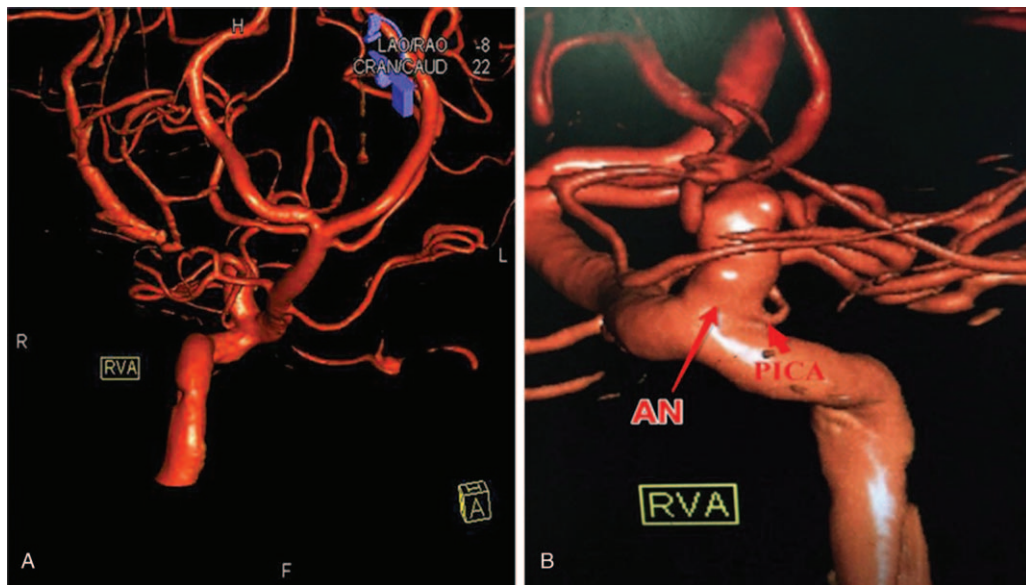


Figure 3. The angiogram demonstrated a wide-neck cylindrical aneurysm with a posterior inferior cerebellar artery (PICA) originating from the base aneurysm (AN), Right vertebral artery (RVA). A. The morphology of the aneurysm; B. Assess for suitability of coiling embolization.

cerebrovascular attacks, atherosclerosis, subarachnoid hemorrhage, arteriovenous malformations, moyamoya disease, or tumors.^[4,5,14] Baltasvias et al has reported that persistent PHA is associated with intracranial saccular aneurysms in 40 cases, and aneurysms on the PPHA occur only in 16 cases.^[6] To our knowledge, our case is the 22th aneurysm located on the PPHA which has been reported to date.^[6,7,11,15-17]

Almost all aneurysms located on the PPHA were treated surgically by either clipping or wrapping.^[7,8-10] However, a surgical approach for these aneurysms, as for other aneurysms in the posterior circulation, is always challenging, while the posterior circulation is exclusively fed by the PPHA confers additional risk to the treatment.

Since Baltasvias et al has reported the first case of endovascular management of a ruptured aneurysm located on the PPHA^[6], endovascular treatment of PPHA aneurysms showed good safety and efficacy in other 4 cases.^[11,15-17] Of the 4 cases, Baldi et al firstly described application of the stent-assisted coiling in an unruptured wide-neck aneurysm located on PPHA in a patient with pulsatile tinnitus.^[11] Here, we reported the 2nd case of an aneurysm located on PPHA, which was successfully treated using a stent-assisted coil embolization technique.

In this case, since PICA originated from the base of the aneurysm, we adopted a novel LVIS stent-assisted coiling technique termed as “shelf” technique which was recently described by Du and Shankar.^[12] With this technique, the

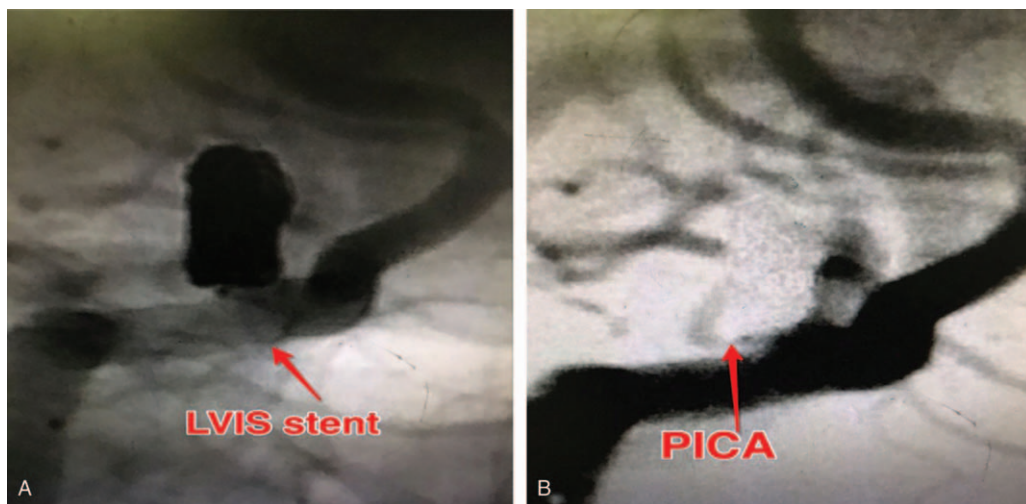


Figure 4. The final angiogram confirmed the patency of the PICA and the parent artery and its distal branches. A. A 3.5 × 20mm low-profile visualized intraluminal support (LVIS) stent (Microvention/Terumo, Tustin, CA) was deployed to protect the posterior inferior cerebellar artery (PICA). B. Six microcoils (Axium, eV3, Irvine, CA) were used to completely obliterate the aneurysm.

aneurysm was completely occluded with the patency of the PICA. To reduce the risk of acute or subacute stent thrombosis, which is catastrophic in this patient who had a single functional artery to provide the blood to the posterior circulation, effective antiaggregation with aspirin and clopidogrel before and after treatment is mandatory. In addition, accurate preoperative information about the lesion (location, diameters, neck, and morphology) obtained by CT angiography with three-dimensional reconstruction or 3D rotational angiography is mandatory to perform a safe and effective treatment.^[11] In our case, three-dimensional rotational angiography provided a complete assessment of the lesion and the possibilities of treatment.

In conclusion, our case demonstrates that endovascular treatment is a safe and effective method for the treatment of a persistent PHA aneurysm, even with the involvement of PICA.

Author contributions

Conceptualization: Shi Zeng, Donghong Yang.

Data curation: Shi Zeng.

Formal analysis: Shi Zeng.

Investigation: Huajiang Yang.

Methodology: Shi Zeng, Huajiang Yang.

Writing – original draft: Shi Zeng, Lun-Shan Xu.

Writing – review & editing: Min-Hui Xu.

References

- [1] Luh GY, Dean BL, Tomsick TA, et al. The persistent fetal carotid-vertebrobasilar anastomoses. *AJR* 1999;172:1427–32.
- [2] Osborne AG. *Osborne's Brain*. 1st ed Canada: Amirsys Publishing Inc; 2013. 172–174.
- [3] Fujita N, Shimada N, Takimoto H, et al. MR appearance of the persistent hypoglossal artery. *AJNR* 1995;16:990–2.
- [4] Garza-Mercado R, Cavazos E, Urrutia G. Persistent hypoglossal artery in combination with multifocal arteriovenous malformations of the brain: case report. *Neurosurgery* 1990;26:871–6.
- [5] Huynh-Le P, Matsushima T, Muratani H, et al. Persistent primitive hypoglossal artery associated with proximal posterior inferior cerebellar artery aneurysm. *Surg Neurol* 2004;62:546–51.
- [6] Baltsavias GM, Chourmouzi D, Tasianas N, et al. Ruptured aneurysm of a persistent primitive hypoglossal artery treated by endovascular approach - case report and literature review. *Surg Neurol* 2007;68:338–43.
- [7] He S, Russin JJ, Adamczyk P, et al. A persistent primitive hypoglossal artery arising from the external carotid artery associated with subarachnoid hemorrhage. *World Neurosurg* 2014;82:239.e1-3.
- [8] Bongartz EB, Nau HE, Grote W. Successful operative treatment of an aneurysm on a left persistent hypoglossal artery. *Neurochirurgia (Stuttg)* 1977;20:169–73.
- [9] Duffill J, Lang DA, Dwyer GN. subarachnoid hemorrhage in a child from aneurysm of a persistent primitive hypoglossal artery. *Br J Neurosurg* 1996;10:607–10.
- [10] Yamamoto S, Sunada I, Matsuoka Y, et al. Persistent primitive hypoglossal artery aneurysms—report of two cases. *Neurol Med Chir (Tokyo)* 1991;31:199–202.
- [11] Baldi S, Zander T, Rabellino M, et al. Stent-assisted coil embolization of a wide-neck aneurysm of a persistent primitive hypoglossal artery. *Cardiovasc Intervent Radiol* 2009;32:352–5.
- [12] Du EHY, Shankar JJS. LVIS Jr 'shelf' technique. an alternative to Y stent-assisted aneurysm coiling. *J NeuroIntervent Surg* 2016;8:1256–9.
- [13] Lie TA. *Congenital Anomalies of the Carotid Arteries*. Amsterdam: Excerpta Medica; 1968. 35–51.
- [14] Katayama W, Enomoto T, Yanaka K, et al. Moyamoya disease associated with persistent primitive hypoglossal artery: report of a case. *Pediatr Neurosurg* 2001;35:262–5.
- [15] De Blasi R, Medicamento N, Chiumarullo L, et al. A case of aneurysm on a persistent hypoglossal artery treated by endovascular coiling. *Interv Neuroradiol* 2009;15:175–8.
- [16] Hui FK, Schuette AJ, Cawley CM. Endovascular treatment of an aneurysm of a persistent primitive hypoglossal artery with complete resolution of brainstem compressive symptoms: case report. *Neurosurgery* 2011;68:E854–7.
- [17] Kimball D, Ples H, Miclaus GD, et al. Persistent hypoglossal artery aneurysm located in the hypoglossal canal with associated subarachnoid hemorrhage. *Surg Radiol Anat* 2015;37:205–9.