

Percutaneous Vertebroplasty Using Fresh Frozen Allogeneic Bone Chips as Filler

Dong Ki Ahn, MD, Song Lee, MD, Dae Geun Kim, MD, Won Sik Shin, MD

Department of Orthopedic Surgery, Seoul Sacred Heart General Hospital, Seoul, Korea

Background: Vertebroplasty is not free from cement related complications. If an allograft is used as a filler, most of them can be averted.

Methods: Forty consecutive cases of osteoporotic vertebral fracture were divided into two groups by self-selection. The study and the control groups underwent vertebroplasty with fresh frozen allogeneic bone chips and bone cement, respectively. Clinical results were assessed at preoperation, postoperative day 1 and months 3, 6, and 12 by 10-grade visual analog scale (VAS), and radiological results were assessed at the same time by vertebral kyphotic angle (VKA) and local kyphotic angle (LKA). The results were compared within and between the groups. Survival function was analyzed. The criteria of an event were clinical or radiological deterioration versus pre-index surgery state.

Results: VAS was improved in the study group from 8.4 ± 0.8 to 5.2 ± 1.4 , 6.4 ± 1.2 , 5.5 ± 2.7 , and 3.7 ± 1.4 at postoperative day 1 and months 3, 6, and 12, respectively, and in the control group from 8.4 ± 1.2 to 3.2 ± 1.1 , 3.2 ± 1.7 , 3.2 ± 2.7 , and 2.5 ± 1.7 , respectively (within group, $p < 0.001$; between groups, $p < 0.001$). VKA was improved in the study group from $18.9^\circ \pm 8.0^\circ$ to $15.2^\circ \pm 6.1^\circ$ ($p = 0.046$) and in the control group from $14.7^\circ \pm 5.2^\circ$ to $10.3^\circ \pm 4.7^\circ$ ($p < 0.001$) at postoperative day 1. LKA was not improved in the study group but was improved in the control group from $16.8^\circ \pm 11.7^\circ$ to $14.3^\circ \pm 9.6^\circ$ ($p = 0.015$). Correction angle was $2.7^\circ \pm 4.6^\circ$, $-7.9^\circ \pm 5.3^\circ$, $-7.2^\circ \pm 5.2^\circ$, and $-7.4^\circ \pm 6.3^\circ$ at postoperative day 1 and months 3, 6, and 12, respectively, in the study group and $4.3^\circ \pm 3.7^\circ$, $0.7^\circ \pm 3.6^\circ$, $0.7^\circ \pm 4.2^\circ$, and $0.1^\circ \pm 4.4^\circ$, respectively, in the control group. Correction loss was significant in both groups ($p < 0.001$) and more serious in the study group ($p < 0.001$). The 6-month survival rate was 16.7% in the study group and 64.3% in the control group ($p = 0.003$; odds ratio, 5.250).

Conclusions: In treatment of osteoporotic vertebral fracture, fresh frozen allogeneic bone chips are not recommendable as a filler for its worse results than bone cement.

Keywords: *Vertebroplasty, Fresh frozen allogeneic bone*

Vertebroplasty (VP) was first invented to treat aggressive hemangiomas in vertebral bodies. Its application has been increasing exponentially since its use was extended as an option for osteoporotic compression fracture treatment. It began as a simple augmentation of a vertebral

body with bone cement and evolved to kyphoplasty (KP), which involves using a balloon to reduce the collapsed body. Though KP has not been widely approved to reduce the collapsed body, it is recognized to reduce the leakage of bone cement.¹⁾ However, at the same time, it can cause adjacent fractures by increasing the pressure against the adjacent end plates.²⁾ The possibility of cardiovascular complications also increases due to the increased amount of infused monomer.³⁾ Furthermore, as patients age, the strength of vertebral body decreases, but the strength of bone cement is constant. There has been no decisive solution for the late complications that may develop due to this

Received February 15, 2013; Accepted May 10, 2013

Correspondence to: Dong Ki Ahn, MD

Department of Orthopedic Surgery, Seoul Sacred Heart General Hospital,
Wangsan-ro 259, Dongdaemun-gu, Seoul 130-867, Korea

Tel: +82-2-966-1616, Fax: +82-2-968-2394

E-mail: adkajs@hanmail.net

Copyright © 2014 by The Korean Orthopaedic Association

This is an Open Access article distributed under the terms of the Creative Commons Attribution Non-Commercial License (<http://creativecommons.org/licenses/by-nc/3.0>) which permits unrestricted non-commercial use, distribution, and reproduction in any medium, provided the original work is properly cited.

Clinics in Orthopedic Surgery • pISSN 2005-291X eISSN 2005-4408

discrepancy. Additives have been mixed with the bone cement to decrease the hardness and polymerizing temperature. The filler was also substituted with biologic materials that have osteoconductivity such as calcium sulfate and calcium phosphate. However, these methods were not successful because of frequent collapse.⁴⁾

We devised a novel method using fresh frozen allogeneic bone chips to augment the fractured vertebral body. Charging a bone defect with allogeneic bone chips has been used successfully in revision total hip arthroplasty. This material was presumed to withstand mechanical compression force, much like wet sand in closed space. Our hope was that complications related to bone cement leakage and potential risks coming from the permanent hard mass could be fundamentally averted.

METHODS

Materials

Patients who were suffering from a single level osteoporotic compression fracture and had been treated in this hospital from March 2010 to August 2010 were selected as subjects. The diagnosis of fracture was made by simple radiography and magnetic resonance imaging. Patients had to be above 60 years old, have a T-score of femur neck

bone mineral density (BMD) less than -2.5 , and a fracture level between T10 and L3. Those who had multiple spinal compression fractures, associated fractures in other places, pathologic fractures, or fusion surgeries at other segments were excluded. Fractures above T10 and below L4 were also excluded because fixed vertebrae and lordotic zone vertebrae would have different behaviors. The study group received VP using fresh frozen allogeneic bone chips (VPAB). The control group received VP using bone cement (VPBC). Patients were allocated by self-selection method. We explained the potential advantages and disadvantages of VPAB. Those who accepted the new method were allocated to VPAB and the others were allocated to VPBC. There were a total of 42 patients: 12 in VPAB and 30 in VPBC.

The null hypothesis was that the clinical and radiological results of the two groups are equivalent.

Methods of Performance

Vertebroplasty with allogeneic bone

Fresh frozen allogeneic bones were collected from the distal femoral and proximal tibial condyle of patients who underwent replacement arthroplasty of knee joints. The bone fragments were milled into chips less than 1 mm, packed in 10-mL disposable syringes, and preserved in an

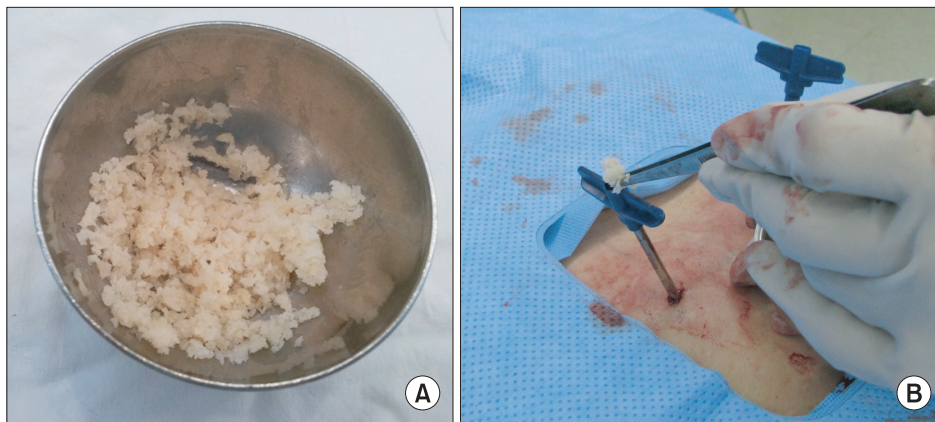


Fig. 1. (A) Fresh allogeneic bone chips were made by bone mill. (B) Allogeneic bone chips were charged through the cannula.

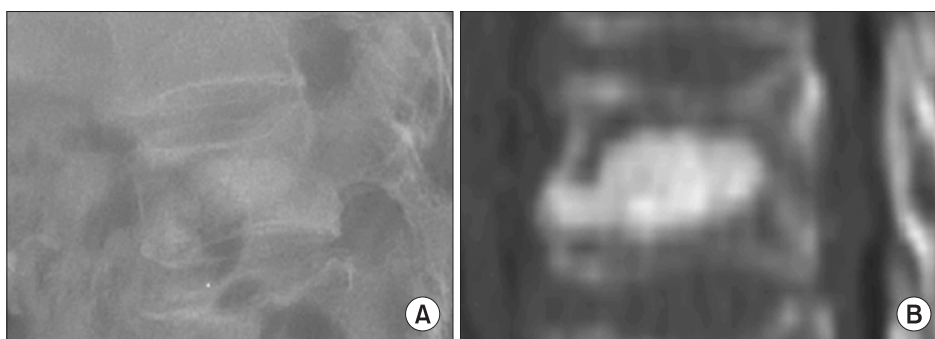


Fig. 2. Simple radiography (A) and computed tomography scan (B) show fracture site of vertebral body charged by allogeneic bone chips.

accredited bone bank for more than 3 months at -70°C . With the patient in the prone position, under local anesthesia 3-mm cannulas were inserted bilaterally into the fractured vertebral body with fluoroscopic guidance. Fresh allogeneic bone chips were thawed and charged into the vertebral body to the maximum impaction (Figs. 1 and 2).

Vertebroplasty with bone cement

Three-mm cannulas were inserted by the same method, and conduits were made by 2.8-mm infusion plunger. Bone cement (Exsolut, Elmdown Ltd, Hungerford, UK) composed of 20 g of multimer and 9.2 g of monomer was mixed with 6 mL of autologous blood obtained from the vertebral body. The compound filler was infused with the infusion plunger under fluoroscopic guidance at the point of 1/3 from the anterior cortex when it reached sufficient viscosity to prevent leakage. Infusion was stopped when sufficient amount of filler was infused to support both end plates or when leakage was observed.

Postoperative Management

Both groups underwent the same management. Free ambulation was allowed 2 hours after the operation and thoracolumbosacral orthoses were worn for 3 months. Anti-osteoporotic agents acting on the catastrophic phase and calcium carbonate agents were administered at least for 1 year. Radiological and clinical improvement was assessed at day 1 and months 3, 6, and 12 after the operation.

Assessment

Homogeneity was investigated as to age, gender, BMD, type of fracture, site of fracture, previous fracture, kyphotic angle and medical treatment against osteoporosis. BMD was assessed with dual-energy X-ray absorptiometry (DEXA) at the femur neck, and types of fracture were classified as acute compression, acute stable bursting and Kummell disease. Site of fracture was classified as thoracic (above T10), thoracolumbar (T11–L1), and lumbar (below L2) region. Total amount of filler materials was assessed. Clinical improvement was assessed by 10-grade visual analogue scale (VAS). Immediate improvement was assessed by comparing the preoperation and postoperation day 1 scores. Maintenance was assessed by taking all measured scores into account. Radiological results were assessed by Cobb angle for vertebral kyphotic angle (VKA), between the upper and lower end plate of fracture vertebra, and local kyphotic angle (LKA), between an upper end plate of upper vertebra and lower end plate of lower vertebra. Correction angle (CA) was defined as the difference in VKA from the preoperation state. Survival function was

analyzed. The criteria of an event were increment of VAS above the preoperation state or increment of VKA or LKA 5 degrees above the preoperation state or revision with other methods. Statistical analysis was performed by chi-square test for homogeneity, and clinical and radiological results were assessed by paired *t*-test and repeated measured analysis of variance. Survival function was assessed by Kaplan-Mayer method and hazard ratio was calculated by Cox regression test.

RESULTS

Two cases of VPBC dropped out. A total of 40 cases, 12 experimental and 28 control, were included. The demographics of the two groups were homogenous, and details are shown in Table 1. Clinical improvement of the two groups is shown in Table 2. At postoperative day 1, VAS was improved in VPAB from 8.50 ± 0.91 to 5.08 ± 1.38 ($p < 0.001$) and in VPBC from 8.39 ± 3.21 to 3.21 ± 1.10 ($p < 0.001$). However, the improvement was greater in VPBC ($p < 0.001$). In four repeated measurements (day 1 and months 3, 6, and 12), VAS changed to 5.2 ± 1.4 , 6.4 ± 1.2 , 5.5 ± 2.7 , and 3.7 ± 1.34 in VPAB and to 3.2 ± 1.1 , 3.2 ± 1.7 , 3.12 ± 2.7 , and 2.5 ± 1.7 in VPBC. It deteriorated in month 3 then improved again in VPAB and was maintained throughout the year in VPBC ($p < 0.001$). The radiological assessments are noted in Table 2. At postoperative day 1, VKA was reduced from 18.9 ± 8.0 to 15.2 ± 6.1 ($p = 0.046$) in VPAB, but LKA was not reduced significantly (from 20.9 ± 10.1 to 18.8 ± 8.1 , $p = 0.134$). In VPBC, VKA was reduced from 14.7 ± 5.2 to 10.3 ± 4.7 ($p < 0.001$) and LKA was also reduced from 16.8 ± 11.7 to 14.3 ± 9.6 ($p = 0.015$). In four repeated measurements (at 1 day and 3, 6, and 12 months), CA was lost in both groups as 2.7 ± 4.6 , -7.9 ± 5.3 , -7.2 ± 5.2 , and -7.4 ± 6.3 degrees, respectively, in VPAB and 4.3 ± 3.7 , 0.7 ± 3.6 , 0.7 ± 4.2 , and 0.1 ± 4.4 degrees, respectively, in VPBC. This loss was more significant in VPAB ($p < 0.001$ within group, $p < 0.001$ between groups) (Fig. 3). In survival analysis, survival rates of VPAB were 25.0% at month 3, 16.7% at month 6, and no more drop-outs thereafter and those of VPBC were 82.1% at month 3, 64.3% at month 6, and 60.7% at month 12. The difference was significant ($p = 0.003$) (Fig. 4). The odds ratio of survival was 5.2 times higher in VPBC (95% confidence interval, 1.104 to 24.963). One case of VPAB crossed over to VPBC due to continuous pain at month 3. There were 3 cases of Kummell disease in VPAB. Two of them showed interbody cleft again at 3 month radiologic examination and continued thereafter. One of them showed bone union; however, the vertebral body collapsed again. Bone

Table 1. Homogeneity of Two Groups

Demography	Vertebroplasty with allogeneic bone	Vertebroplasty with bone cement	<i>p</i> -value
Age (yr)	71.8 ± 7.6	72.0 ± 5.3	0.910
Bone mineral density (femoral neck, T-score)	-2.9 ± -0.8	-2.8 ± 0.4	0.433
Preoperative visual analog scale	8.5 ± 0.9	8.4 ± 1.2	0.779
Preoperative kyphosis (°)	31.6 ± 10.6	24.7 ± 10.6	0.075
Amount of filler (mL)	5.3 ± 1.4	6.3 ± 1.9	0.097
Sex (male:female)	4:8	6:22	0.451
Fracture configuration (C/B/K)	7/2/3	24/2/2	0.061 Likelihood ratio
Fracture site (T/TL/L)	1/9/2	1/25/2	0.535 Likelihood ratio
Previous fracture (+/-)	10/2	19/9	0.451
Bisphosphonate medication (+/-)	8/4	19/9	1.000

C/B/K: compression/bursting/Kummell disease. T/TL/L: thoracic/thoracolumbar/lumbar spine.

Table 2. Clinical and Radiological Results

		Preoperative	Postoperative				<i>p</i> -value
			1 day	3 mo	6 mo	12 mo	
VAS	VPAB	8.4 ± 0.8	5.2 ± 1.4	6.4 ± 1.2	5.5 ± 2.7	3.1 ± 1.4	Between groups: < 0.001
	VPBC	8.4 ± 1.2	3.2 ± 1.1	3.2 ± 1.7	2.5 ± 2.7	1.5 ± 1.7	Within group: < 0.001
VKA (°)	VPAB	18.9 ± 8.0	15.2 ± 6.1	-	-	-	0.046
	VPBC	14.5 ± 5.2	10.3 ± 4.7	-	-	-	< 0.001
LKA (°)	VPAB	20.9 ± 10.1	18.8 ± 8.1	-	-	-	0.134
	VPBC	16.8 ± 11.7	14.3 ± 9.6	-	-	-	0.015
CA (°)	VPAB	-	2.7 ± 4.6	-7.9 ± 5.3	-7.2 ± 5.2	-7.4 ± 6.3	Between groups: < 0.001
	VPBC	-	4.3 ± 3.7	0.7 ± 3.6	0.7 ± 4.2	1.0 ± 4.4	Within group: < 0.001

VAS: visual analog scale, VPAB: vertebroplasty with allogeneic bone, VPBC: vertebroplasty with bone cement, VKA: vertebral kyphotic angle, LKA: local kyphotic angle, CA: correction angle.

cement leakage developed in 5 cases of VPBC (18%; 3 intradiscal, 1 epidural, and 1 extravertebral body). There was no other complication related to performance in either group.

DISCUSSION

The objective appraisal of VP has been equivocal to date. In most nonrandomized studies, early results were very encouraging and complications were regarded as not serious. Although there are still debates about the mechanisms of pain reduction, mechanical support for bearing

body weight and giving resistance against flexion force by sagittal support have been regarded as plausible mechanisms.^{5,6)} However, recent randomized studies suggested a placebo effect, noting similar improvement even in a sham group.^{7,8)} Furthermore, safety has been challenged by bone cement-related complications such as intravascular leakage,⁹⁾ pulmonary embolism,^{10,11)} cerebral embolism,¹²⁾ paraplegia by spinal cord compression,^{13,14)} hypotension^{9,15)} and pulmonary embolism by monomer,³⁾ acute respiratory failure by monomer¹⁶⁾ and thermal damage to the spinal cord and nerve roots.¹⁷⁾ There have been reports about performance-related complications such as epidural

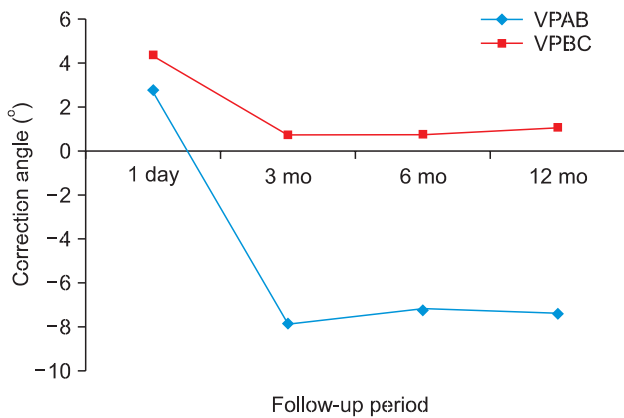


Fig. 3. Loss of correction angle over time. VPAB: vertebroplasty with allogeneic bone, VPBC: vertebroplasty with bone cement.

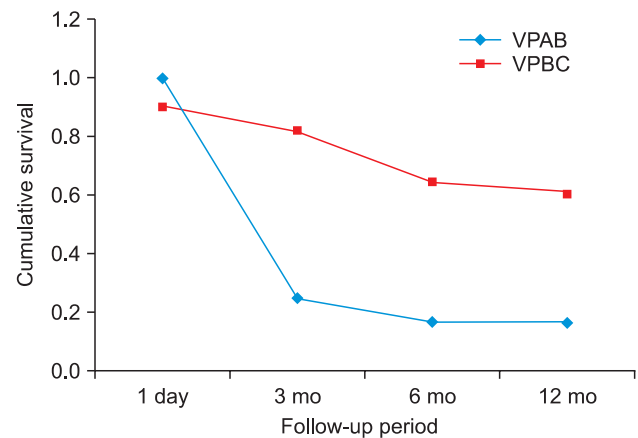


Fig. 4. Survival rates of vertebroplasty. VPAB: vertebroplasty with allogeneic bone, VPBC: vertebroplasty with bone cement.

hematoma,¹⁸⁾ dural tear,¹⁹⁾ and infection.²⁰⁾ Adjacent vertebral fracture was underestimated in the early period as an anecdotal episode.²¹⁾ However, it was thought to happen because bone cement is much harder than the adjacent vertebral bodies.^{22,23)} In KP, the configuration of augmented vertebral body is more solid. Therefore additional fractures developed more frequently (36%) in KP, and 28% developed at adjacent vertebra. The earliest case developed at 2 weeks, and 76% developed within 60 days.²²⁾ Development increases as the follow-up period is extended because hardness of the bone cement mass is constant while the vertebral bodies are becoming osteoporotic. For the ideal filler, the following conditions should be considered: (1) chemical and physical reactions while hardening, (2) appropriate mechanical strength, and (3) biologic activity.⁴⁾ Bone cement hardens rapidly and its polymerization produces heat. Therefore, leakage due to hasty injection and thermal damage can occur. Furthermore, it is too hard compared to the surrounding osteoporotic bone and has no biologic activity. Meanwhile, allogeneic bone has no heat-producing polymerization like poly methyl methacrylate (PMMA) or crystallization like calcium phosphate. It undergoes only creeping substitution, so it does not have initial mechanical strength. However, if it is fully charged in a closed space, it can have a solid nature to bear a compression force, much like wet sand.²⁴⁾ This concept has already been accepted in total hip arthroplasty for reconstruction of bone defect.²⁵⁾ Fresh allogeneic bone has osteoconductivity and weak osteoinductivity compared to freeze-dried allogeneic bone or synthetic bone substitute. Furthermore, the vertebral body has bone marrow, which contains osteoprogenitor cells. Herein, the grafted fresh allogeneic bone was expected to make a bone union. However, the results were completely different from our as-

sumption. Immediate pain reduction was less than VPBC and pain relapsed as time elapsed. After 3 months, it was reduced again; however, this was considered the natural course of fracture healing. The clinical inferiority was attributable to the less stable mechanical support. In radiological assessment, immediate reduction of kyphosis was less, and most cases collapsed again within 3 months. The current method failed because we didn't consider the various forces on the vertebral body. It has to bear not only the compression force but also distraction and shearing forces. However, bone chips in a closed space could only withstand compression force. Calcium phosphate cement failed as a VP filler for the same reason. PMMA and calcium phosphate had similar mechanical strength against compression force,²⁶⁾ however the latter had far less strength against cyclic eccentric loading²⁷⁾ and showed poor results in more unstable fractures.⁴⁾ We thought that allogeneic bone could be charged compactly and the speed of absorption would be longer than that of calcium phosphate. Resorption of allogeneic bone occurs between 6 months and 1 year,²⁸⁾ while up to 74% of calcium phosphate is absorbed after 4 weeks.²⁹⁾ After the substitution, we thought the allogeneic bone could bear all kinds of forces. However, given the current results, the mass of allogeneic bone chips must have less strength than calcium phosphate.

Biological activity was not identified. We anticipated that allogeneic bone chips would work in Kümmell's disease; however, in 2 of 3 cases, vacuum cleft was seen again. We reported successful reconstruction of Kümmell disease with transpedicular auto iliac and allogeneic composite bone graft and posterior pedicle screw fixation,³⁰⁾ but without the mechanical support of pedicle screw fixation, the grafted bone chips and pure allogeneic bone couldn't undergo creeping substitution.

In radiological assessment, we measured LKA and VKA. We anticipated that vertebral augmentation could not improve global sagittal balance because of the offset of adjacent discs, as we presumed the reduction magnitude of LKA was less than VKA. However, in measuring the change of the CA, VKA was more specific to the purpose of the current study.

In survival analysis that considered both clinical and radiological results, VPAB showed rapid dropout within 3 months, while VPBC dropped out gradually. Radiological deterioration, that is, collapse of the vertebral body, was the main reason for dropout rather than clinical score. LKA increased 7.9° more than before the operation within 3 months and there was no further collapse in VPAB. In contrast, the collapse of the vertebral body in VPBC continued until 12 months.

Bone cement leakage developed in 5 cases of control group, but there was no symptomatic case. There was no bone cement mass fracture. Further collapse developed in the extracement portion.

There were several limitations in the current study. There was a large difference between the two groups in the number of cases. At first, we planned to allocate both groups equally, but initial poor results seemed to influence the self-selection process. Also, the time interval before the operation was not elucidated because most of patients couldn't remember the exact day of injury. We do not believe that this influenced the results.

In VP, using fresh frozen allergenic bone chips as a filler material showed poorer results than using bone cement in clinical and radiological assessments. This technique was totally unacceptable because the clinical and radiological survival rate was only 25% in 3 months and the odds ratio of failure was 5 times greater than VP using bone cement.

CONFLICT OF INTEREST

No potential conflict of interest relevant to this article was reported.

REFERENCES

- Pradhan BB, Bae HW, Kropf MA, Patel VV, Delamarter RB. Kyphoplasty reduction of osteoporotic vertebral compression fractures: correction of local kyphosis versus overall sagittal alignment. *Spine (Phila Pa 1976)*. 2006;31(4):435-41.
- Frankel BM, Monroe T, Wang C. Percutaneous vertebral augmentation: an elevation in adjacent-level fracture risk in kyphoplasty as compared with vertebroplasty. *Spine J*. 2007;7(5):575-82.
- Chen HL, Wong CS, Ho ST, Chang FL, Hsu CH, Wu CT. A lethal pulmonary embolism during percutaneous vertebroplasty. *Anesth Analg*. 2002;95(4):1060-2.
- Blattert TR, Jestaedt L, Weckbach A. Suitability of a calcium phosphate cement in osteoporotic vertebral body fracture augmentation: a controlled, randomized, clinical trial of balloon kyphoplasty comparing calcium phosphate versus polymethylmethacrylate. *Spine (Phila Pa 1976)*. 2009;34(2):108-14.
- Peters KR, Guiot BH, Martin PA, Fessler RG. Vertebroplasty for osteoporotic compression fractures: current practice and evolving techniques. *Neurosurgery*. 2002;51(5 Suppl):S96-103.
- Phillips FM, Pfeifer BA, Lieberman IH, Kerr EJ 3rd, Choi IS, Pazzianos AG. Minimally invasive treatments of osteoporotic vertebral compression fractures: vertebroplasty and kyphoplasty. *Instr Course Lect*. 2003;52:559-67.
- Buchbinder R, Osborne RH, Ebeling PR, et al. A randomized trial of vertebroplasty for painful osteoporotic vertebral fractures. *N Engl J Med*. 2009;361(6):557-68.
- Kallmes DE, Comstock BA, Heagerty PJ, et al. A randomized trial of vertebroplasty for osteoporotic spinal fractures. *N Engl J Med*. 2009;361(6):569-79.
- Groen RJ, du Toit DF, Phillips FM, et al. Anatomical and pathological considerations in percutaneous vertebroplasty and kyphoplasty: a reappraisal of the vertebral venous system. *Spine (Phila Pa 1976)*. 2004;29(13):1465-71.
- Bernhard J, Heini PF, Villiger PM. Asymptomatic diffuse pulmonary embolism caused by acrylic cement: an unusual complication of percutaneous vertebroplasty. *Ann Rheum Dis*. 2003;62(1):85-6.
- Jang JS, Lee SH, Jung SK. Pulmonary embolism of polymethylmethacrylate after percutaneous vertebroplasty: a report of three cases. *Spine (Phila Pa 1976)*. 2002;27(19):E416-8.
- Scroop R, Eskridge J, Britz GW. Paradoxical cerebral arterial embolization of cement during intraoperative vertebroplasty: case report. *AJNR Am J Neuroradiol*. 2002;23(5):868-70.
- Lee BJ, Lee SR, Yoo TY. Paraplegia as a complication of percutaneous vertebroplasty with polymethylmethacrylate: a case report. *Spine (Phila Pa 1976)*. 2002;27(19):E419-22.
- Shapiro S, Abel T, Purvines S. Surgical removal of epidural

- and intradural polymethylmethacrylate extravasation complicating percutaneous vertebroplasty for an osteoporotic lumbar compression fracture: case report. *J Neurosurg.* 2003;98(1 Suppl):90-2.
15. Aebli N, Krebs J, Davis G, Walton M, Williams MJ, Theis JC. Fat embolism and acute hypotension during vertebroplasty: an experimental study in sheep. *Spine (Phila Pa 1976).* 2002;27(5):460-6.
 16. Watts NB, Harris ST, Genant HK. Treatment of painful osteoporotic vertebral fractures with percutaneous vertebroplasty or kyphoplasty. *Osteoporos Int.* 2001;12(6):429-37.
 17. Verlaan JJ, Oner FC, Verbout AJ, Dhert WJ. Temperature elevation after vertebroplasty with polymethyl-methacrylate in the goat spine. *J Biomed Mater Res B Appl Biomater.* 2003;67(1):581-5.
 18. Truumees E, Hilibrand A, Vaccaro AR. Percutaneous vertebral augmentation. *Spine J.* 2004;4(2):218-29.
 19. Amar AP, Larsen DW, Esnaashari N, Albuquerque FC, Lavine SD, Teitelbaum GP. Percutaneous transpedicular polymethylmethacrylate vertebroplasty for the treatment of spinal compression fractures. *Neurosurgery.* 2001;49(5):1105-14.
 20. Walker DH, Mummaneni P, Rodts GE Jr. Infected vertebroplasty: report of two cases and review of the literature. *Neurosurg Focus.* 2004;17(6):E6.
 21. Barr JD, Barr MS, Lemley TJ, McCann RM. Percutaneous vertebroplasty for pain relief and spinal stabilization. *Spine (Phila Pa 1976).* 2000;25(8):923-8.
 22. Fribourg D, Tang C, Sra P, Delamarter R, Bae H. Incidence of subsequent vertebral fracture after kyphoplasty. *Spine (Phila Pa 1976).* 2004;29(20):2270-6.
 23. Pflugmacher R, Schroeder RJ, Klostermann CK. Incidence of adjacent vertebral fractures in patients treated with balloon kyphoplasty: two years' prospective follow-up. *Acta Radiol.* 2006;47(8):830-40.
 24. Mitarai N, Nori F. Wet granular materials. *Adv Phys.* 2006;55(1-2):1-45.
 25. Patil N, Hwang K, Goodman SB. Cancellous impaction bone grafting of acetabular defects in complex primary and revision total hip arthroplasty. *Orthopedics.* 2012;35(3):e306-12.
 26. Tomita S, Molloy S, Jasper LE, Abe M, Belkoff SM. Biomechanical comparison of kyphoplasty with different bone cements. *Spine (Phila Pa 1976).* 2004;29(11):1203-7.
 27. Wilke HJ, Mehnert U, Claes LE, Bierschneider MM, Jaksche H, Boszczyk BM. Biomechanical evaluation of vertebroplasty and kyphoplasty with polymethyl methacrylate or calcium phosphate cement under cyclic loading. *Spine (Phila Pa 1976).* 2006;31(25):2934-41.
 28. Goldberg VM. The biology of bone grafts. *Orthopedics.* 2003;26(9):923-4.
 29. Tsai CH, Lin RM, Ju CP, Chern Lin JH. Bioresorption behavior of tetracalcium phosphate-derived calcium phosphate cement implanted in femur of rabbits. *Biomaterials.* 2008;29(8):984-93.
 30. Choi DJ, Ahn DK, Lee S, Park KY, Jun YW, Kim KS. Operative treatment of delayed collapse of osteoporotic vertebral fracture with claudication: transpedicular bone graft and pedicle screw fixation. *J Korean Soc Spine Surg.* 2007;14(2):73-8.