

A Novel Autosomal Recessive *GJA1* Missense Mutation Linked to Craniometaphyseal Dysplasia

Ying Hu¹, I-Ping Chen², Salome de Almeida³, Valdenize Tiziani⁴, Cassio M. Raposo Do Amaral⁵, Kalpana Gowrishankar⁶, Maria Rita Passos-Bueno⁷, Ernst J. Reichenberger^{1*}

1 Department of Reconstructive Sciences, Center for Regenerative Medicine and Developmental Biology, University of Connecticut Health Center, Farmington, Connecticut, United States of America, **2** Department of Oral Health and Diagnostic Sciences, University of Connecticut Health Center, Farmington, Connecticut, United States of America, **3** Medical Genetics Service, Centro Hospitalar de Lisboa, Central, Portugal, **4** Universidade Estadual Vale do Acaraú, Brazil, **5** Instituto de Cirurgia Plástica Cranio-facial - SOBRAPAR, Campinas, Brazil, **6** Department of Medical Genetics, Kanchi Kamakoti Childs Trust Hospital, Chennai, Tamil Nadu, India, **7** Instituto de Biociencias, Universidade de Sao Paulo, São Paulo, Brazil

Abstract

Craniometaphyseal dysplasia (CMD) is a rare sclerosing skeletal disorder with progressive hyperostosis of craniofacial bones. CMD can be inherited in an autosomal dominant (AD) trait or occur after *de novo* mutations in the pyrophosphate transporter *ANKH*. Although the autosomal recessive (AR) form of CMD had been mapped to 6q21-22 the mutation has been elusive. In this study, we performed whole-exome sequencing for one subject with AR CMD and identified a novel missense mutation (c.716G>A, p.Arg239Gln) in the C-terminus of the gap junction protein alpha-1 (*GJA1*) coding for connexin 43 (Cx43). We confirmed this mutation in 6 individuals from 3 additional families. The homozygous mutation cosegregated only with affected family members. Connexin 43 is a major component of gap junctions in osteoblasts, osteocytes, osteoclasts and chondrocytes. Gap junctions are responsible for the diffusion of low molecular weight molecules between cells. Mutations in Cx43 cause several dominant and recessive disorders involving developmental abnormalities of bone such as dominant and recessive oculodentodigital dysplasia (ODDD; MIM #164200, 257850) and isolated syndactyly type III (MIM #186100), the characteristic digital anomaly in ODDD. However, characteristic ocular and dental features of ODDD as well as syndactyly are absent in patients with the recessive Arg239Gln Cx43 mutation. Bone remodeling mechanisms disrupted by this novel Cx43 mutation remain to be elucidated.

Citation: Hu Y, Chen I-P, de Almeida S, Tiziani V, Do Amaral CMR, et al. (2013) A Novel Autosomal Recessive *GJA1* Missense Mutation Linked to Craniometaphyseal Dysplasia. PLoS ONE 8(8): e73576. doi:10.1371/journal.pone.0073576

Editor: Andreas R. Janecke, Innsbruck Medical University, Austria

Received: April 24, 2013; **Accepted:** July 4, 2013; **Published:** August 12, 2013

Copyright: © 2013 Hu et al. This is an open-access article distributed under the terms of the Creative Commons Attribution License, which permits unrestricted use, distribution, and reproduction in any medium, provided the original author and source are credited.

Funding: Funding provided by National Institutes of Health support #M01RR006192 and University of Connecticut Health Center institutional support. The funders had no role in study design, data collection and analysis, decision to publish, or preparation of the manuscript.

Competing interests: The authors have declared that no competing interests exist.

* E-mail: reichenberger@uchc.edu

Introduction

Craniometaphyseal dysplasia (CMD; MIM #123000) is a rare genetic disorder affecting the skeleton with progressive hyperostosis of craniofacial bones and abnormal modeling of tubular bones. Craniofacial abnormalities include wide-set eyes, wide nasal bridge, paranasal bossing and prominent mandible. The main feature leading to morbidity is hyperostosis of cranial bones, which can lead to increased intracranial pressure and narrowing of neural foramina [1,2,3,4]. Nerve damage can lead to facial palsy, blindness and deafness. Increased bone formation can further lead to Chiari malformation, compression of the spinal cord and syringomyelia [5,6,7]. The metaphyses of long bones are widened and undertrabeculated, possibly due to insufficient

bone remodeling by dysfunctional osteoblasts and osteoclasts [8,9].

Many CMD cases described so far are inherited as an autosomal dominant (AD) trait [10,11,12,13] or occur as *de novo* mutations [12,13,14,15,16]. Until now all CMD mutations have been found in the human progressive ankylosis gene (*ANKH*). *ANKH* encodes for a ten-span transmembrane protein associated with pyrophosphate transport [17]. Most of the *ANKH* mutations are located in cytoplasmic domains close to the C-terminus [12,13]. A CMD knock-in mouse model carrying a Phe377del mutation in *ANKH* develops many of the features that are characteristic for CMD patients and has been shown to exhibit impaired osteoblastogenesis and osteoclastogenesis [8,9].

Some pedigrees suggest an autosomal recessive (AR) mode of transmission [1,18,19,20,21] and a linkage study has

identified a potential locus for the autosomal recessive form of CMD within a 7 cM interval on chromosome 6q21-22 [18]. However, a causative variant responsible for AR CMD could not be identified. Here we report the first gene mutation for autosomal recessive CMD in the gap junction gene *GJA1*, better known as *CONNEXIN 43* (*CX43*), responsible for small molecule transport.

Materials and Methods

Ethics Statement

This study was approved by the Institutional Review Board at UCHC and the Ethics Committees at Kanchi Kamkoti, Childs Trust Hospital, University of Campinas, Ethics Commission for Health of the Hospital Center of Lisboa Central and Institute of Biosciences, University of Sao Paolo. Written informed consent had been obtained from study participants and parents of minors. Families and individuals included in this study were selected based on absence of mutations in *ANKH* and a potential recessive inheritance pattern. The data described here cannot be deposited to a public repository due to issues of patient confidentiality. Data can be shared with other investigators upon request and subject to clearance from our Institutional Review Board.

Whole-Exome Sequencing

Genomic DNA (gDNA) was extracted from blood (Genra Puregene; QIAGEN Inc., Valencia, CA) or saliva (OraGene saliva kit; DNA Genotek Inc., Kanata, Ontario, Canada) and submitted to Otogenetics Corporation (Norcross, GA USA) for exome capture and sequencing.

Briefly, gDNA was subjected to agarose gel electrophoresis and OD ratio tests to confirm the purity and concentration prior to fragmentation by a Covaris fragmenter (Covaris, Inc., Woburn, MA). Fragmented gDNAs were tested for size distribution and concentration using an Agilent Bioanalyzer 2100 (Agilent Technologies, Santa Clara, CA) and Nanodrop (Thermo, Fisher Scientific, Pittsburgh, PA). Sequencing libraries were prepared using NEBNext reagents (New England Biolabs, Ipswich, MA) and the resulting libraries were subjected to exome enrichment using the TruSeq Exome Enrichment Kit (Illumina, Inc., San Diego, CA) following manufacturer's instructions. Enriched libraries were tested for enrichment by qPCR and for size distribution and concentration with Agilent Bioanalyzer 2100. The samples were then sequenced on an Illumina HiSeq2000, which generated paired-end reads of 100 nucleotides.

Sequencing Alignment, Variant Calling and Annotation

Alignment and variant calling were evaluated on the DNAnexus platform (DNAnexus, Inc., Mountain View, CA). Burrows-Wheeler Aligner (BWA, version 0.5.9-r16) was used to align the sequence reads to the human reference genome GRCh37 (hg19). Subsequently, Nucleotide-Level Variation Analysis was used to identify differences in the sample genome with respect to the reference genome. Differences include single- and multi-nucleotide polymorphisms (SNPs, MNPs),

insertions and/or deletions (indels). Resulting variant calls were first filtered for confidence calls originating from bidirectional sequence reads using a quality threshold of ≥ 30 and read depth ≥ 10 . Variants were then prioritized for further filtering and retained for further analysis when a variant appeared as a homozygous and non-synonymous, i.e. altering an amino acid. Selected variants were then compared to public databases. All variants present in the dbSNP database (version 135), 1000 Genomes Project and NHLBI Exome Sequencing Project Exome Variant Server (EVS) were excluded.

Mutation Validation Analysis

Nucleotide changes in the candidate gene *CX43* were numbered corresponding to their position in *CX43* mRNA (Ensembl gene ID: ENSG00000152661). Verification of the c.716G>A candidate variant was performed by Sanger sequencing of exon 2 of *CX43* using PCR primers GJA1-F (5'-TTCTGGGTCCTGCAGATCAT-3') and GJA1-R (5'-TCTTGATGCTTTCAAGCCTGT-3') resulting in a 944 bp product. All available family members were tested for cosegregation of the candidate variant with the disease phenotype. PCR products containing the variant of interest were purified with ExoSAP-IT (Affymetrix, Santa Clara, CA) and sequenced by Sanger sequencing using ABI PRISM 3730xl DNA Analyzers with standard protocol (Genewiz, South Plainfield, NJ). The functional effect of a missense variant was evaluated using in silico prediction tools PolyPhen2, SIFT, Mutation Taster and SNAP. Sequence alignment among different species was performed with ClustalW2.

Results and Discussion

We performed exome sequencing on proband VIII5 from the consanguineous Family 1 (Figure 1) at an average depth of 78x using a TruSeq Exome 62Mb Enrichment kit and HiSeq2000 sequencer (Illumina). 20,794 genes were targeted which include 201,121 exons in total. A total of 163,463 genetic variants, including SNPs and indels were identified. Out of 46,866 homozygous variants 4,895 were non-synonymous. Only one of these variants, a G to A transversion (c.716G>A) in *GJA1* (RefSeq NM_000165.3) (Figure 2), which was novel according to dbSNP, the Human Gene Mutation Database (HGMD), 1000 Genomes Project (approx. 1,000 individuals) and National Heart, Lung, and Blood Institute (NHLBI) Exome Sequencing Project (ESP; approx. 2,200 individuals) data colocalized with the putative recessive CMD locus on chromosome 6q21–q22. *GJA1* codes for the gap junction alpha 1 protein and is also known as *CONNEXIN 43*, *CX43* (MIM #121014).

The non-synonymous missense variant in *GJA1* resulted in a homozygous amino acid substitution from Arginine to Glutamine (p.Arg239Gln; R239Q). This variant was predicted to be damaging by Mutation Taster and SNAP although SIFT and PolyPhen2 did not flag this mutation as damaging. The R239Q variant in *CX43* is located in a phylogenetically highly conserved region, which has also been identified as a potential tubulin binding motif (Figure 3) [22]. This Arginine is conserved in 4 other connexins, *CX37*, (*GJA4*), *CX40* (*GJA5*), *CX30*

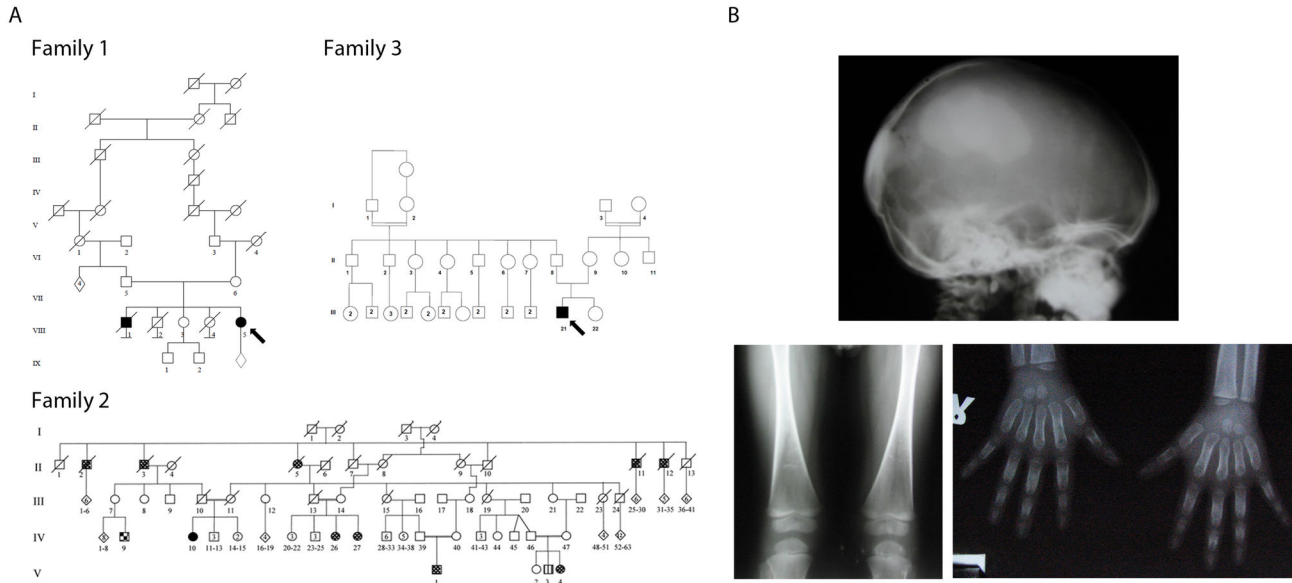


Figure 1. Pedigree information and case description. (A) Pedigrees of Families 1, 2 and 3 with mutation in the novel CMD gene *GJA1*. Proband DNA from Family 1 was used for exome sequencing (Arrow). (B) Radiographic images of proband for Family 3 show hyperostosis of cranial base and facial bones, femoral flaring and undertrabeculation of metaphyses with dense diaphyseal bone consistent with findings in Family 2. Diffuse widening of the proximal and medial phalanges are consistent with findings in CMD patients from Family 2 [18].

doi: 10.1371/journal.pone.0073576.g001

(GJB6) and CX32 (GJB1), however, no mutations have been reported for Arginine at this position.

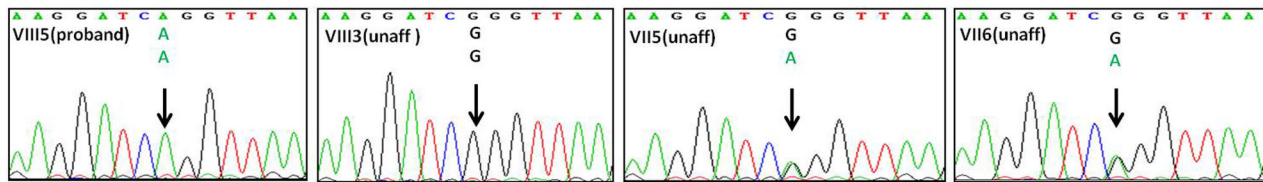
We then identified this variant in 4 affected individuals (V1 (proband), V4, IV26, IV27) of Brazilian Family 2 [18] and in the affected child of the Indian Family 3 (III11) by Sanger sequencing (Figure 2). The c.716G>A variant was absent in the unaffected sibling of family 1 (VIII3), who had a wild type genotype. The parents of all probands as well as two unaffected siblings in Family 2 and one unaffected sibling in Family 3 were heterozygous for the mutation. We found the same homozygous c.716G>A mutation in a fourth proband from Brazil diagnosed with CMD but with unknown family background (data not shown). The summary of all subject genotypes is shown in Table S1.

The affected individuals in Family 2 (V1, V4, V26 and IV27) were born to healthy consanguineous parents and showed relatively mild symptoms as described before [18] with nasal flattening and hypertelorism. 3D computed tomography and radiographs for V1 and V4 showed sclerosis of the cranial vault and cranial base. Facial bones were hyperostotic. All affected individuals in this study had difficulties breathing, probably due to hyperostosis, but none showed loss of vision or hearing loss. Affected members of this family displayed diaphyseal hyperostosis in limb bones with mild metaphyseal widening. Another AR disorder, a form of spondylocostal dysostosis (SD), also segregates in this family. Subject V3 with SD (indicated as striped square in Figure 1) showed normal skull and limb radiographs.

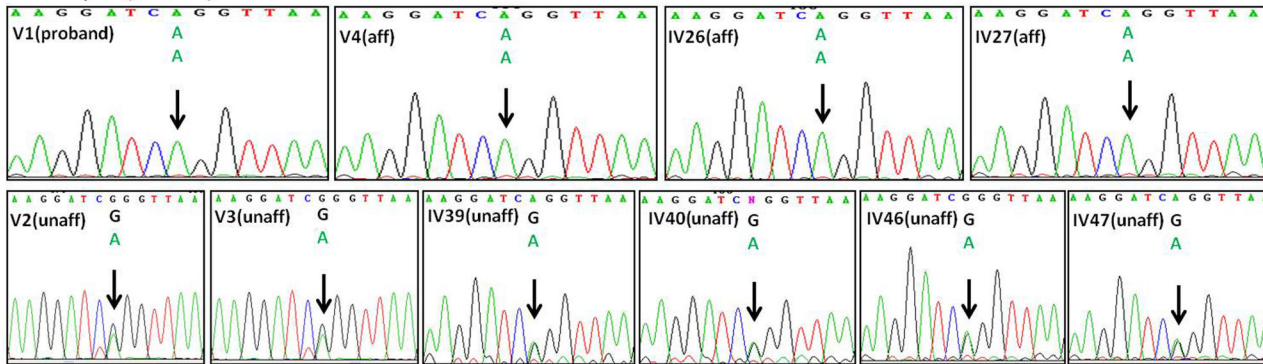
The proband of Family 3 (Figure 1B) is a 3-year-old male referred to the genetics clinic for epiphora (L) and dysmorphic facial features. His height was 96 cm (50th centile) and head circumference was 50 cm (50th–85th centile). He had relative macrocephaly, hypertelorism, an unusual thick bony wedge over the bridge of the nose and a depressed and flattened nasal bridge. The ophthalmological exam revealed secondary naso-lacrimal duct obstruction (bilateral). X-ray of skull revealed significant sclerosis of skull base and 3D MRI of paranasal sinuses and orbits showed bilateral dense sclerotic thickening in parietal, occipital and ethmoid bones as well as in the frontal process of maxillary and zygomatic bones. His serum calcium, phosphorus and serum alkaline phosphate levels were normal. The proband of Family 1 is unfortunately lost to follow up and detailed clinical information is no longer available.

CX43 is a major component of hemichannels and gap junctions. Two opposing hemichannels form a gap junction connecting the cytoplasm of neighboring cells to facilitate gap junctional intercellular communication (GJIC) via exchange of ions and molecules smaller than 1.2 kDa. The *GJA1* gene consists of 2 exons and encodes a transmembrane protein with four transmembrane domains (TM), two extracellular loops, one intracellular loop and intracellular amino- (N-term) and carboxyl-terminal ends (C-term) (Figure 4). The mutation identified in this study is located in exon 2 of the *CX43* gene and leads to a substitution in position 239 in the intracellular C-terminal domain proximal to the fourth transmembrane domain. At least three connexins, CX43, CX45 and CX46 are

Family 1 (Portugal)



Family 2 (Brazil)



Family 3 (India)

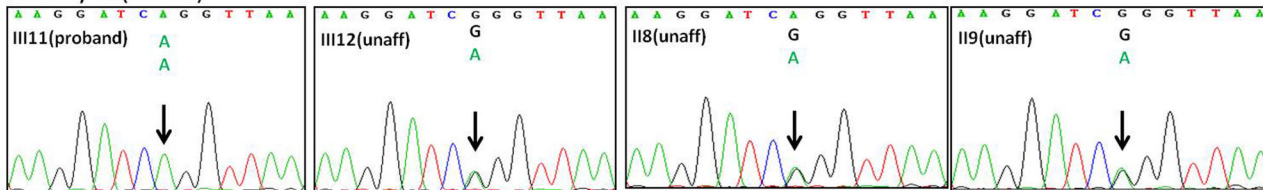


Figure 2. Confirmatory sequencing. Sanger sequencing to confirm exome sequencing data with a mutation in the CONNEXIN 43 gene *GJA1* in position c.716G>A (p.Arg239Gln). Data shown for Family 1 (VIII5 proband; VIII3 unaffected sibling; VII5 and VII6 heterozygous parents), Family 2 (V1 proband, V4 affected cousin; IV26 and IV27 affected aunts; V2 and V3 unaffected cousins; IV39 and IV40 heterozygous parents of V1; IV46 and IV47 heterozygous parents of V4) and Family 3 (III11 proband; III12 unaffected sibling; II8 and II9 heterozygous parents).

doi: 10.1371/journal.pone.0073576.g002

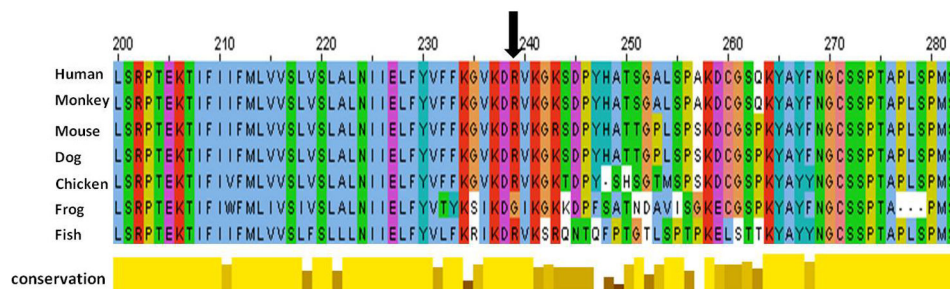


Figure 3. Phylogenetic comparison of *GJA1* across species. Position of the mutation within a highly conserved region indicated with arrow.

doi: 10.1371/journal.pone.0073576.g003

expressed in bone cells with CX43 being the most abundant. There is solid evidence for an important role of CX43 in skeletal development and the function and survival of osteoblasts and osteocytes [23,24,25,26]. Data from *in vitro* studies supported a role for CX43 and gap junctional intracellular communication

during osteoblastic cell differentiation and coordinated cell responsiveness [27,28]. *In vivo* studies demonstrated that global ablation of *Gja1* in mice results in delayed skeletal ossification, craniofacial abnormalities and osteoblast dysfunction [29,30]. Tissue-specific *Gja1* ablation in

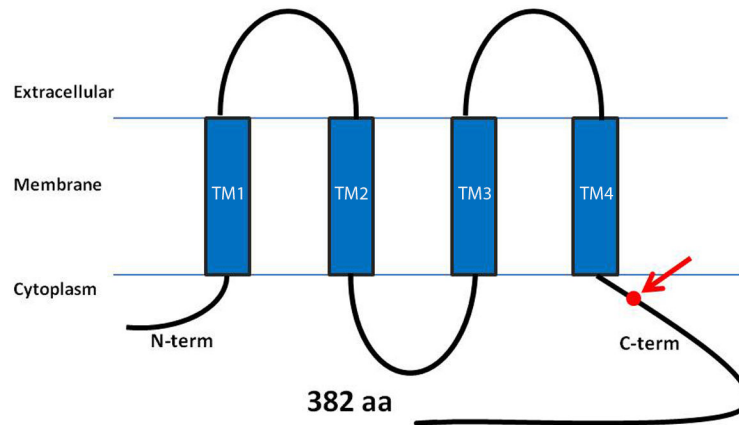


Figure 4. Domain structure of CONNEXIN 43. The CX43 protein consists of an intracellular amino acid domain (AT), four transmembrane domains (TM), two extracellular loops and one intracellular loop. The novel CMD mutation is indicated as a red dot in the carboxyl-terminal domain (CT).

doi: 10.1371/journal.pone.0073576.g004

osteoblasts results in accrual of a low peak bone mass and an attenuated response to the anabolic effects of parathyroid hormone (increase mineral apposition rate in response to PTH) despite increased osteoblast numbers, which suggests a functional defect in CX43-deficient bone-forming cells [31]. Osteoblast- and osteocyte-specific ablation of CX43 using an osteocalcin-driven Cre-lox system resulted in bone loss due to increased bone resorption and osteoclastogenesis [32]. Mice lacking CX43 in osteocytes develop increased osteocyte apoptosis and empty lacunae in cortical bone [25].

Further proof of the critical role of CX43 in skeletal biology provides the identification of 65 mutations in *GJA1* as the cause of the predominantly autosomal dominant oculodentodigital dysplasia (ODDD; MIM # 164200). ODDD is characterized by craniofacial abnormalities, microphthalmia, tooth defects, and hand and foot abnormalities such as fifth finger camptodactyly, syndactyly of the fourth and fifth fingers, and missing phalanges of the toes. Other skeletal abnormalities include cranial hyperostosis, wide alveolar ridge of the mandible as well as broad tubular bones [33,34,35,36]. The fact that the CMD patients described in this study do not display the characteristic tooth defects, ocular involvement or camptodactyly / syndactyly of ODDD strongly suggests that their phenotype is consistent with CMD and not part of the ODDD spectrum.

Another rare genetic disorder, Hallermann–Streiff syndrome (HSS) is characterized by proportionate short stature, hypotrichosis, congenital cataracts, malformation of cranial and facial bones as well as dental anomalies (MIM #234100) and shares several clinical characteristics with ODDD. Recently, a single case with a homozygous CX43 gene mutation p. R76H (c.227G>A) in a conserved region was found with overlapping phenotypes of HSS/ODDD [37]. Some digital anomalies such as type III syndactyly can be syndromic with ODDD although isolated type III syndactyly has been attributed to a *GJA1* mutation as well [38]. The only overlapping features of ODDD

patients with CMD patients harboring a Arg239Gln mutation in *GJA1* are cranial hyperostosis and widening of tubular bones.

Most of the autosomal dominant CX43 mutations for ODDD that were studied in detail showed reduced channel function inhibiting wild type CX43 in a dominant negative manner [39,40]. It is therefore possible that the Arg239Gln mutation in *GJA1* also acts in a dominant negative manner by reducing the function of other connexin homo- or oligomers or of interacting connection proteins. Recently, R76H and R33X mutations in CX43 have been reported as the cause for autosomal recessive ODDD by distinct mechanisms [41]. In vitro experiments showed that the R76H mutant was able to form functional gap junctions whereas the R33X mutant reduced the connexin gap junction plaques.

In addition to its role as intercellular channel CX43 has been shown to interact with intracellular structures and signaling molecules such as β -arrestins for PTH receptor/cAMP signaling in osteoblasts [42] and to affect cellular functions through its cytoplasmic C-terminal domain [43].

Gap junctions can serve as anchoring locations for microtubules thus regulating cellular activity associated with microtubule function. Microtubules are one of the major components of the cytoskeleton providing scaffolding, sequestration and delivery functions. They are involved in various signaling pathways such as Wnt, hedgehog (Hh), nuclear factor κ B (NF- κ B) and mitogen activated protein kinase K (MAPK) through diverse mechanisms [44,45,46,47,48,49]. These signaling pathways have also been implicated in skeletal development and skeletal homeostasis.

The CX43 C-terminal cytoplasmic domain harbors a highly conserved potential tubulin binding motif²³⁴ KGVKDRVKGK²⁴³ [22] thus mediating the TGF- β signaling pathway via Smad2/3, which is a major player in osteoblast differentiation and osteoblast-induced osteoclastogenesis [50]. CX43 competes with Smad2/3 for binding to microtubules inducing release of Smad2/3 from microtubules [51] and can increase phospho-

Smad2/3 accumulation in the nucleus leading to transcriptional activation of target genes.

The R239Q mutation in our CMD patients is located within this tubulin binding motif and we hypothesize that the amino acid change may affect binding to microtubules. In this case Smads may compete with microtubule binding and with their translocation to the nucleus thus altering the expression of osteoblastic genes regulated by Smads.

Therefore, it is possible that the CX43 mutation causes CMD by either changing the tubulin binding site or by affecting signal transduction events via alteration of transport properties of gap junctions/hemichannels.

Conclusions

In summary, our exome sequencing study identified a novel disease gene for the autosomal recessive form of craniometaphyseal dysplasia. The causative variant in the *CONNEXIN 43* gene *GJA1* results in a disease-specific CMD phenotype demonstrating that CMD is a genetically heterogeneous disorder. It will be interesting to study any discernible clinical differences of the recessive CX43 form of CMD to the autosomal dominant form caused by ANKH mutations once more patients with CX43 mutations have been identified for this very rare craniotubular disorder. It is also remains to be investigated whether any mechanistic interactions between CX43 and ANKH exist.

URLs

1000 Genomes Browser: <http://browser.1000genomes.org/>
 NHLBI Exome Variant Server: <http://evs.gs.washington.edu/EVS/>

The Human Gene Mutation Database (HGMD): <http://www.hgmd.cf.ac.uk/ac/index.php>

References

- Gorlin RJ (1994) Craniotubular bone disorders. *Pediatr Radiol* 24: 392-406. doi:10.1007/BF02011904. PubMed: 7700714.
- Hayashibara T, Komura T, Sobue S, Ooshima T (2000) Tooth eruption in a patient with craniometaphyseal dysplasia: case report. *J Oral Pathol Med* 29: 460-462. doi:10.1034/j.1600-0714.2000.290907.x. PubMed: 11016689.
- Mintz S, Velez I (2004) Craniometaphyseal dysplasia associated with obstructive sleep apnoea syndrome. *Dentomaxillofac Radiol* 33: 262-266. doi:10.1259/dmfr/17660567. PubMed: 15533982.
- Zhang H, Somerman MJ, Berg J, Cunningham ML, Williams B (2007) Dental anomalies in a child with craniometaphyseal dysplasia. *Pediatr Dent* 29: 415-419. PubMed: 18027777.
- Day RA, Park TS, Ojemann JG, Kaufman BA (1997) Foramen magnum decompression for cervicomedullary encroachment in craniometaphyseal dysplasia: case report. *Neurosurgery* 41: 960-964. doi:10.1097/00006123-199710000-00039. PubMed: 9316062.
- Sewell MD, Akram H, Wadley J (2008) Foramen magnum decompression and expansile duroplasty for acquired Chiari type I malformation in craniometaphyseal dysplasia. *Br J Neurosurg* 22: 83-85. doi:10.1080/02688690701658737. PubMed: 18224526.
- Juergens P, Ratia J, Beinemann J, Krol Z, Schicho K et al. (2011) Enabling an unimpeded surgical approach to the skull base in patients with cranial hyperostosis, exemplarily demonstrated for craniometaphyseal dysplasia. *J Neurosurg* 115: 528-535. doi:10.3171/2011.3.JNS101517. PubMed: 21495823.
- Chen IP, Wang CJ, Strecker S, Koczon-Jaremko B, Boskey A et al. (2009) Introduction of a Phe377del mutation in ANK creates a mouse model for craniometaphyseal dysplasia. *J Bone Miner Res* 24: 1206-1215. doi:10.1359/jbmr.090218. PubMed: 19257826.
- Chen IP, Wang L, Jiang X, Aguila HL, Reichenberger EJ (2011) A Phe377del mutation in ANK leads to impaired osteoblastogenesis and osteoclastogenesis in a mouse model for craniometaphyseal dysplasia (CMD). *Hum Mol Genet* 20: 948-961. doi:10.1093/hmg/ddq541. PubMed: 21149338.
- Beighton P (1995) Craniometaphyseal dysplasia (CMD), autosomal dominant form. *J Med Genet* 32: 370-374. doi:10.1136/jmg.32.5.370. PubMed: 7616544.
- Tinschert S, Braun HS (1998) Craniometaphyseal dysplasia in six generations of a German kindred. *Am J Med Genet* 77: 175-181. doi:10.1002/(SICI)1096-8628(19980518)77:3. PubMed: 9605583.
- Nürnberg P, Thiele H, Chandler D, Höhne W, Cunningham ML et al. (2001) Heterozygous mutations in ANKH, the human ortholog of the mouse progressive ankylosis gene, result in craniometaphyseal dysplasia. *Nat Genet* 28: 37-41. doi:10.1038/ng0501-37. PubMed: 11326272.
- Reichenberger E, Tiziani V, Watanabe S, Park L, Ueki Y et al. (2001) Autosomal dominant craniometaphyseal dysplasia is caused by mutations in the transmembrane protein ANK. *Am J Hum Genet* 68: 1321-1326. doi:10.1086/320612. PubMed: 11326338.
- Dutra EH, Chen IP, McGregor TL, Ranells JD, Reichenberger EJ (2012) Two novel large ANKH deletion mutations in sporadic cases with craniometaphyseal dysplasia. *Clin Genet* 81: 93-95. doi:10.1111/j.1399-0004.2011.01700.x. PubMed: 22150416.
- Kornak U, Brancati F, Le Merrer M, Lichtenbelt K, Höhne W et al. (2010) Three novel mutations in the ANK membrane protein cause craniometaphyseal dysplasia with variable conductive hearing loss. *Am J Med Genet A* 152A: 870-874. doi:10.1002/ajmg.a.33301. PubMed: 20358596.

DbSNP: <http://www.ncbi.nlm.nih.gov/projects/SNP/> ;
 Online Mendelian Inheritance in Man (OMIM): <http://www.ncbi.nlm.nih.gov/omim> ;
 SIFT: <http://sift.jcvi.org/> ;
 Polyphen2: <http://genetics.bwh.harvard.edu/pph2/> ;
 SNAP: <http://www.rostlab.org/services/snap/> ;
 MutationTaster: <http://www.mutationtaster.org/> ;
 ClustalW2: <http://www.ebi.ac.uk/Tools/msa/clustalw2/>.

Accession numbers

The following accession codes were used to number nucleotide changes in *CONNEXIN 43*: Ensembl gene ID: ENSG00000152661.

We thank the families for participating in this study and for institutional support from the University of Connecticut Health Center and for NIH support # M01RR006192 to the UCHC CRC.

Supporting Information

Table S1. Summary of AR CMD subjects in this study. (DOCX)

Acknowledgements

We thank the families for participating in this study.

Author Contributions

Conceived and designed the experiments: EJR. Performed the experiments: YH. Analyzed the data: YH. Contributed reagents/materials/analysis tools: IPC SdA VT CMRA KG MRPB. Wrote the manuscript: YH EJR.

16. Zajac A, Baek SH, Salhab I, Radecki MA, Kim S et al. (2010) Novel ANKH mutation in a patient with sporadic craniometaphyseal dysplasia. *Am J Med Genet A* 152A: 770-776. doi:10.1002/ajmg.a.33317. PubMed: 20186813.
17. Ho AM, Johnson MD, Kingsley DM (2000) Role of the mouse ank gene in control of tissue calcification and arthritis. *Science* 289: 265-270. doi: 10.1126/science.289.5477.265. PubMed: 10894769.
18. Iughetti P, Alonso LG, Wilcox W, Alonso N, Passos-Bueno MR (2000) Mapping of the autosomal recessive (AR) craniometaphyseal dysplasia locus to chromosome region 6q21-22 and confirmation of genetic heterogeneity for mild AR spondylocostal dysplasia. *Am J Med Genet* 95: 482-491. doi:10.1002/1096-8628(200012)95:5. PubMed: 11146471.
19. Millard DR Jr., Maisels DO, Batstone JH, Yates BW (1967) Craniofacial surgery in craniometaphyseal dysplasia. *Am J Surg* 113: 615-621. doi: 10.1016/0002-9610(67)90307-8. PubMed: 6021432.
20. Penchaszadeh VB, Gutierrez ER, Figueroa E (1980) Autosomal recessive craniometaphyseal dysplasia. *Am J Med Genet* 5: 43-55. doi: 10.1002/ajmg.1320050107. PubMed: 7395899.
21. Prontera P, Rogaia D, Sobacchi C, Tavares VL, Mazzotta G et al. (2011) Craniometaphyseal dysplasia with severe craniofacial involvement shows homozygosity at 6q21-22.1 locus. *Am J Med Genet A* 155A: 1106-1108. PubMed: 21465646.
22. Giepmans BN, Verlaan I, Hengeveld T, Janssen H, Calafat J et al. (2001) Gap junction protein connexin-43 interacts directly with microtubules. *Curr Biol* 11: 1364-1368. doi:10.1016/S0960-9822(01)00424-9. PubMed: 11553331.
23. Civitelli R (2008) Cell-cell communication in the osteoblast/osteocyte lineage. *Arch Biochem Biophys* 473: 188-192. doi:10.1016/j.abb.2008.04.005. PubMed: 18424255.
24. Stains JP, Civitelli R (2005) Gap junctions in skeletal development and function. *Biochim Biophys Acta* 1719: 69-81. doi:10.1016/j.bbame.2005.10.012. PubMed: 16359941.
25. Bivi N, Nelson MT, Failace ME, Li J, Miller LM et al. (2012) Deletion of Cx43 from osteocytes results in defective bone material properties but does not decrease extrinsic strength in cortical bone. *Calcif Tissue Int* 91: 215-224. doi:10.1007/s00223-012-9628-z. PubMed: 22865265.
26. Loisel AE, Paul EM, Lewis GS, Donahue HJ (2013) Osteoblast and osteocyte-specific loss of Connexin 43 results in delayed bone formation and healing during murine fracture healing. *J Orthop Res* 31: 147-154. doi:10.1002/jor.22178. PubMed: 22718243.
27. Donahue HJ, Li Z, Zhou Z, Yellowley CE (2000) Differentiation of human fetal osteoblastic cells and gap junctional intercellular communication. *Am J Physiol Cell Physiol* 278: C315-C322. PubMed: 10666026.
28. Li Z, Zhou Z, Yellowley CE, Donahue HJ (1999) Inhibiting gap junctional intercellular communication alters expression of differentiation markers in osteoblastic cells. *Bone* 25: 661-666. doi: 10.1016/S8756-3282(99)00227-6. PubMed: 10593410.
29. Chaible LM, Sanches DS, Cogliati B, Menecier G, Dagli ML (2011) Delayed osteoblastic differentiation and bone development in Cx43 knockout mice. *Toxicol Pathol* 39: 1046-1055. doi: 10.1177/0192623311422075. PubMed: 21934140.
30. Lecanda F, Warlow PM, Sheikh S, Furlan F, Steinberg TH et al. (2000) Connexin 43 deficiency causes delayed ossification, craniofacial abnormalities, and osteoblast dysfunction. *J Cell Biol* 151: 931-944. doi: 10.1083/jcb.151.4.931. PubMed: 11076975.
31. Chung DJ, Castro CH, Watkins M, Stains JP, Chung MY et al. (2006) Low peak bone mass and attenuated anabolic response to parathyroid hormone in mice with an osteoblast-specific deletion of connexin 43. *J Cell Sci* 119: 4187-4198. doi:10.1242/jcs.03162. PubMed: 16984976.
32. Zhang Y, Paul EM, Sathyendra V, Davison A, Sharkey N et al. (2011) Enhanced osteoclastic resorption and responsiveness to mechanical load in gap junction deficient bone. *PLoS ONE* 6: e23516. doi:10.1371/journal.pone.0023516. PubMed: 21897843.
33. Loddenkemper T, Grote K, Evers S, Oelerich M, Stögbauer F (2002) Neurological manifestations of the oculodentodigital dysplasia syndrome. *J Neurol* 249: 584-595. doi:10.1007/s004150200068. PubMed: 12021949.
34. Paznekas WA, Boyadjiev SA, Shapiro RE, Daniels O, Wollnik B et al. (2003) Connexin 43 (GJA1) mutations cause the pleiotropic phenotype of oculodentodigital dysplasia. *Am J Hum Genet* 72: 408-418. doi: 10.1086/346090. PubMed: 12457340.
35. Watkins M, Grimston SK, Norris JY, Guillotin B, Shaw A et al. (2011) Osteoblast connexin 43 modulates skeletal architecture by regulating both arms of bone remodeling. *Mol Biol Cell* 22: 1240-1251. doi: 10.1091/mbc.E10-07-0571. PubMed: 21346198.
36. Kjaer KW, Hansen L, Eiberg H, Leicht P, Opitz JM et al. (2004) Novel Connexin 43 (GJA1) mutation causes oculo-dento-digital dysplasia with curly hair. *Am J Med Genet A* 127A: 152-157. doi:10.1002/ajmg.a.20614. PubMed: 15108203.
37. Pizzuti A, Flex E, Mingarelli R, Salpietro C, Zelante L et al. (2004) A homozygous GJA1 gene mutation causes a Hallermann-Streiff/ODDD spectrum phenotype. *Hum Mutat* 23: 286. doi:10.1002/humu.9219. PubMed: 14974090.
38. Richardson R, Donnai D, Meire F, Dixon MJ (2004) Expression of Gja1 correlates with the phenotype observed in oculodentodigital syndrome/type III syndactyly. *J Med Genet* 41: 60-67. doi:10.1136/jmg.2003.013003. PubMed: 14729836.
39. Gong XQ, Shao Q, Langlois S, Bai D, Laird DW (2007) Differential potency of dominant negative connexin 43 mutants in oculodentodigital dysplasia. *J Biol Chem* 282: 19190-19202. doi:10.1074/jbc.M609653200. PubMed: 17420259.
40. Shao Q, Liu Q, Lorentz R, Gong XQ, Bai D et al. (2012) Structure and functional studies of N-terminal Cx43 mutants linked to oculodentodigital dysplasia. *Mol Biol Cell* 23: 3312-3321. doi:10.1091/mbc.E12-02-0128. PubMed: 22809623.
41. Huang T, Shao Q, Macdonald A, Xin L, Lorentz R et al. (2013) Autosomal recessive GJA1 (Cx43) gene mutations cause oculodentodigital dysplasia by distinct mechanisms. *J Cell Sci*, 126: 2857-66. PubMed: 23606748.
42. Bivi N, Lezcano V, Romanello M, Bellido T, Plotkin LI (2011) Connexin 43 interacts with betaarrestin: a pre-requisite for osteoblast survival induced by parathyroid hormone. *J Cell Biochem* 112: 2920-2930. doi: 10.1002/jcb.23208. PubMed: 21630325.
43. Crespin S, Bechberger J, Mesnil M, Naus CC, Sin WC (2010) The carboxy-terminal tail of connexin 43 gap junction protein is sufficient to mediate cytoskeleton changes in human glioma cells. *J Cell Biochem* 110: 589-597. doi:10.1002/jcb.22554. PubMed: 20512920.
44. Jung YJ, Isaacs JS, Lee S, Trepel J, Neckers L (2003) Microtubule disruption utilizes an NF-kappa B-dependent pathway to stabilize HIF-1alpha protein. *J Biol Chem* 278: 7445-7452. doi:10.1074/jbc.M209804200. PubMed: 12488445.
45. Mackenzie GG, Keen CL, Oteiza PI (2006) Microtubules are required for NF-kappaB nuclear translocation in neuroblastoma IMR-32 cells: modulation by zinc. *J Neurochem* 99: 402-415. doi:10.1111/j.1471-4159.2006.04005.x. PubMed: 17029595.
46. Nogales E, Wang HW (2006) Structural intermediates in microtubule assembly and disassembly: how and why? *Curr Opin Cell Biol* 18: 179-184. doi:10.1016/j.ceb.2006.02.009. PubMed: 16495041.
47. Salinas PC (2007) Modulation of the microtubule cytoskeleton: a role for a divergent canonical Wnt pathway. *Trends Cell Biol* 17: 333-342. doi:10.1016/j.tcb.2007.07.003. PubMed: 17643305.
48. Stegman MA, Vallance JE, Elangovan G, Sosinski J, Cheng Y et al. (2000) Identification of a tetrameric hedgehog signaling complex. *J Biol Chem* 275: 21809-21812. doi:10.1074/jbc.C000043200. PubMed: 10825151.
49. Zhao M, Ko SY, Liu JH, Chen D, Zhang J et al. (2009) Inhibition of microtubule assembly in osteoblasts stimulates bone morphogenetic protein 2 expression and bone formation through transcription factor Gli2. *Mol Cell Biol* 29: 1291-1305. doi:10.1128/MCB.01566-08. PubMed: 19103752.
50. Chen G, Deng C, Li YP (2012) TGF-beta and BMP signaling in osteoblast differentiation and bone formation. *Int J Biol Sci* 8: 272-288. PubMed: 22298955.
51. Dai P, Nakagami T, Tanaka H, Hitomi T, Takamatsu T (2007) Cx43 mediates TGF-beta signaling through competitive Smads binding to microtubules. *Mol Biol Cell* 18: 2264-2273. doi:10.1091/mbc.E06-12-1064. PubMed: 17429065.