



ELSEVIER

Contents lists available at ScienceDirect

JSES International

journal homepage: www.jseinternational.org

Progression patterns of range of motion progression after open release for post-traumatic elbow stiffness



Farhan Ahmad, BS^{a,*}, Luis Torres-Gonzales, BS^b, Nabil Mehta, MD^a, Mark S. Cohen, MD^a, Xavier Simcock, MD^a, Robert W. Wysocki, MD^a

^aRush University Medical Center, Chicago, IL, USA

^bUniversity of Illinois College of Medicine, Chicago, IL, USA

ARTICLE INFO

Keywords:

Elbow
Open release
Osteocapsular débridement
Post-traumatic stiffness
Motion recovery

Level of evidence: Level II; Retrospective
Multivariable Analysis; Prognosis Study

Background & Hypothesis: Post-traumatic stiffness of the elbow may be treated surgically with open osteocapsular release. This study investigated postoperative range of motion (ROM) improvements after this procedure. We hypothesized that there would be predictable recovery patterns and significant progress up to 6 months after surgery.

Methods: A retrospective chart review of patients who underwent open elbow release for post-traumatic stiffness (PTS) was performed. Demographic information and surgical approach were recorded. Patients with ipsilateral primary elbow osteoarthritis were excluded. Range of motion (ROM) data were collected at preoperative, intraoperative, and postoperative intervals of 2 weeks, 6 weeks, 3 months, and 6 months. Growth mixture modeling (GMM) and latent class growth analysis (LCGA) were performed to identify motion recovery trajectory groups, and Student's t-tests were performed to compare ROM data between intervals.

Results: One hundred and eighty-seven patients who underwent open elbow release for PTS were included (112 with a medial approach, 50 lateral, and 25 both). The mean preoperative arc was $84^\circ \pm 31$, and the arc of motion at final follow-up was $119^\circ \pm 19$ ($P < .05$). The mean time to the final follow-up arc of motion was 16 weeks, with 56% of patients achieving their final arc by their 3-month follow-up visit. The largest improvement was seen with extension between 6 weeks and 3 months, where 26% of the extension at final follow-up was gained. Most of the recovery occurred within the first 3 months postoperatively, with small improvements thereafter. GMM and LCGA did not identify statistically significant groups for postoperative ROM progression trajectories. Arc of motion preoperatively, intraoperatively, and at 2 weeks postoperatively did not correlate with the final arc of motion. There were no demographic or historical characteristics, or thresholds of motion, which conferred a higher likelihood of achieving a better result postoperatively.

Conclusions: ROM recovery after surgical release for post-traumatic elbow stiffness did not depend on the preoperative, intraoperative, or 2-week postoperative arcs of motion. Most ROM recovery occurs early after surgery, and maximal arc of motion can be expected by approximately 16 weeks postoperatively. This knowledge may inform patients about their expected rehabilitation and splinting time and reduce the total costs of therapy.

© 2022 The Author(s). Published by Elsevier Inc. on behalf of American Shoulder and Elbow Surgeons. This is an open access article under the CC BY-NC-ND license (<http://creativecommons.org/licenses/by-nc-nd/4.0/>).

Joint stiffness is a well-recognized complication following elbow trauma.¹⁶ A combination of intraarticular impingement, heterotopic ossification, and soft tissue contracture can cause loss of range of motion (ROM). Open osteocapsular release is 1 treatment for functionally limiting post-traumatic elbow stiffness, and various

techniques have been described.^{11,20} This operative intervention aims to achieve a greater arc of motion, with a particular focus on restoring flexion as a large contributor to normal elbow function, as limited extension can often be more easily compensated.^{17,18}

An understanding of the progression patterns over time and differences in motion outcomes following this procedure is helpful to counsel patients appropriately both preoperatively and postoperatively—and to the author's knowledge, no such investigation has examined the open release of post-traumatic elbows. For example, this information could inform patients about the

Rush University Medical Center Ruling: Exempt ORA #: 20092807-IRB01.

*Corresponding author: Farhan Ahmad, BS, Department of Orthopaedic Surgery, Rush University Medical Center, 1611 W. Harrison St., Chicago, IL 60612, USA.

E-mail address: ahmadfr@icloud.com (F. Ahmad).

<https://doi.org/10.1016/j.jseint.2022.02.005>

2666-6383/© 2022 The Author(s). Published by Elsevier Inc. on behalf of American Shoulder and Elbow Surgeons. This is an open access article under the CC BY-NC-ND license (<http://creativecommons.org/licenses/by-nc-nd/4.0/>).

expected duration of postoperative supervised physiotherapy, home exercises, or static/dynamic progressive splinting. Growth mixture modeling is a statistical tool that has been used in prior studies to establish patterns in postoperative recovery after other orthopedic procedures, such as total hip arthroplasty and hip arthroscopy.^{10,19} This effect has not been investigated in open surgical release for post-traumatic elbow stiffness.

Therefore, the goal of this study was to identify recovery trajectories in a cohort of patients who underwent open surgical release for post-traumatic elbow stiffness. We hypothesized that we would identify distinct recovery trajectories after this procedure and that patients with relatively worse preoperative motion would recover more slowly secondary to the need for more robust débridement and increased motion deficits.

Materials and methods

Patient selection

After institutional review board (IRB) approval, 442 patients who underwent open osteocapsular resection and contracture release of the elbow at our institution from January 2010 to December 2019 were identified. Two fellowship-trained orthopedic hand and upper extremity surgeons performed all procedures at a tertiary referral center.

Patients who underwent post-traumatic elbow release were included in this study. Patients who had prior osteocapsular débridement in the affected elbow or prior elbow surgery, osteoarthritis due to an etiology other than trauma (eg, primary osteoarthritis, inflammatory arthropathy), or those aged <18 years old were excluded.

Patient charts were reviewed to confirm that they had a history of a traumatic injury to the elbow and that it was the cause of their elbow contracture. The electronic health record (EHR) was then examined to collect demographics, initial injury, preoperative and intraoperative flexion and extension, and any other pertinent history. The postoperative flexion and extension values were collected at approximately 2 weeks, 6 weeks, 3 months, and 6 months. The operating surgeon made all measurements with a standard goniometer, except for intraoperative measurements, which were surgeon estimates.

Surgical technique

All patients in this study underwent open elbow release, and no arthroscopic cases were included. One of 2 approaches was taken for the procedure: medial or lateral. The medial approach was typically performed if there was concomitant ulnar involvement or primary disease in the ulnohumeral joint and less in the radiocapitellar joint. Two working windows were used, a more posterior window between the distal triceps and an anterior window accessed through a split in the flexor pronator anterior to the ulnar nerve and deep to the brachialis proximally. An ulnar nerve subcutaneous transposition was routinely performed with this approach following the joint release, regardless of whether the patient was experiencing ulnar nerve symptoms before the operation. Meanwhile, the lateral approach was typically performed in isolation if there was disease in the lateral gutter, radiocapitellar joint, or cases with predominantly a flexion contracture of the elbow. In some cases, both surgical approaches were utilized. With the lateral approach, 2 working windows were also used, with a posterior window accessed deep to the anconeus and triceps and an anterior window working between the extensor carpi radialis

longus and brevis distally and deep to the brachialis proximally, raised as a single sleeve anteriorly.^{4,15}

Rehabilitation protocol

All patients underwent the same postoperative rehabilitation protocol. Immediately postoperatively, continuous passive motion (CPM) was initiated in the recovery room and continued overnight as an inpatient and then as an outpatient twice per day for 30–45 minutes for 4 weeks, set from 0 to 140° in all patients. Static-progressive splints for flexion in the evening and extension in the morning for 30 minutes each were continued for 3–4 months postoperatively. Additionally, patients were seen by a therapist within 24 hours, and then at a frequency of 2–3 times per week initially, focusing on edema control, concentrated weighted stretches, and both active and passive ROM. Strengthening was initiated at 6–8 weeks postoperatively.

Statistical analysis

Using the software MPlus (version 8.5, Muthen & Muthen, Los Angeles, CA, USA), growth mixture modeling (GMM) and then latent class growth analysis (LCGA) with 1–7 classes was performed as described by Ram et al previously.²¹ This range of classes permitted the identification of up to 7 distinct groups in the data, if statistically significant. Variations on model parameters were employed. First, the preoperative flexion was fixed to 0, and the last measurement (6 months follow-up) was fixed to 1. Additional combinations of analyses wherein the first and last measurements were not fixed followed. Models were assessed with a combination of entropy value, size of the output groups, and statistical significance via the Vuong-Lo-Mendell-Rubin (VLMR) test.

Subsequently, the authors manually consulted the database to perform statistical and subjective testing to identify any progression patterns and test various groups to identify flexion progression patterns.

Quantitative interval variables were analyzed by means and 2-tailed t-tests for *P* values. First, the preoperative arc of motion was compared with the final arc of motion at 6 months, followed by the intraoperative arc with the final arc. Second, at the first follow-up of approximately 2 weeks, the percentage of final flexion was calculated, and patients were grouped accordingly to track progression—and then grouped as either ≥80% of final flexion at first follow-up or <80%. Third, 2 groups were created by endpoint flexion (<135° and ≥135°), and t-tests comparing the endpoint flexion to intraoperative and first follow-up flexions were performed. The 135° cutoff value was chosen as it generated symmetrical groups within the normal Gaussian dataset distribution. Data normality was determined with a D'Agostino-Pearson test. Additional subgroup analyses by age, sex, and surgical approach (medial vs. lateral) were also performed with Student's t-test comparisons of all the ROM outcomes. The level of significance was set to $\alpha < 0.05$.

Results

After applying inclusion and exclusion criteria, 187 patients were included in this study (111 males and 76 females). The average age was 43 ± 15 years. A medial approach was used for 112 patients, a lateral approach for 50 patients, and both were used in 25 cases. The mean time from trauma to elbow release surgery was 346 ± 284 days.

Mean ROM at each follow-up interval is shown in [Table 1](#). Preoperative elbow flexion averaged 115° ± 22, extension 31° ± 18,

Table 1
Mean range of motion data at each follow-up interval.

	Preoperative	1-2 weeks	6 weeks	3 months	6 months (final)	Total gain from preoperative motion
Flexion	115° ± 22	117° ± 15	128° ± 13	132° ± 11	133° ± 11	18°
Extension	31° ± 18	23° ± 11	18° ± 12	15° ± 11	14° ± 12	17°
Arc	84° ± 31	94° ± 21	110° ± 22	117° ± 19	119° ± 19	35°

and arc 84° ± 31. For the unaffected arm, flexion averaged 141° ± 6, extension 3° ± 6, and arc 139° ± 10. Intraoperative flexion averaged 142° ± 8, extension 3° ± 9, and arc 139° ± 14. The mean improvement of motion from preoperative motion to the 6-month (final) interval was 18° of flexion, 17° of extension, and 35° total arc of motion. There was a statistically significant difference between preoperative and 6-month (final) arcs of motion (*P* < .05).

Calculation of the percentage of total gain from preoperative flexion, extension, and arc of motion was also performed at each interval (Table II). For flexion, the percentage of final gain was 11% at 1-2 weeks, 72% at 6 weeks, and 94% at 3 months postoperatively. For extension, the percentage of final gain was 47% at 1-2 weeks, 76% at 6 weeks, and 94% at 3 months postoperatively. For the total arc of motion, the percentage of final gains was 29% at 1-2 weeks, 74% at 6 weeks, and 94% at 3 months postoperatively.

Table III shows the percentage of patients achieving their final (6-month) arc of motion at each postoperative time point. The mean time to the final arc was 16 weeks. At 1-2 weeks, 12 patients (6%) were at 100% or more of their arc at final follow-up. At 6 weeks, 25 patients (13%) reached 100%. At 3 months, 68 patients (36%) reached 100%. The remaining 82 patients were still approaching 100% before their final follow-up.

Growth mixture modeling

GMM and LCGA analyses were performed, and while some identified viable groups, they were either too small to be clinically helpful or statistically insignificant on a Vuong-Lo-Mendell-Rubin (VLMR) test. Figure 1 shows the flexion, extension, and arc trajectories for each patient in our cohort.

Consequently, to generate a single model to describe our data best instead of identifying different patterns via GMM or LCGA, a traditional time series analysis was performed in the form of nonlinear regression fitted by the least-squares method. Regression results are graphed in Figure 1 as well.

Subsequently, the dataset was reviewed manually to identify trends or groups subjectively and via 2-tailed t-tests for quantitative interval variables. The preoperative arc of motion was significantly different from the postoperative arc (*P* < .05). However, matching preoperative arcs to postoperative arcs to identify progression patterns was not possible as the trajectories differed between patients.

Neither preoperative nor intraoperative arc of motion predicted the final arc at 6 months. After calculating the percentage of final flexion for each interval (Table II), no trend was apparent that could be used to identify groups of rapid or slow progressors. Subgrouping at the first follow-up by 80% of final flexion did not result in statistically significant comparisons between groups or any obvious differences in endpoint flexion. Another subgroup analysis by endpoint flexion, either <135° or ≥135°, did not result in significant t-tests examining intraoperative and first follow-up flexions.

After grouping by age (<40, 40-50, 51-59, and >60), analysis of variance (ANOVA) for final flexion, extension, and arc were all nonsignificant (*P* > .05). Subgroup analyses by sex and surgical

approach (medial vs. lateral) were also not statistically significant (*P* > .05) on Student's t-tests for final flexion, extension, and arc.

Discussion

The main findings of the current investigation were (1) the mean time to achieving final arc of motion after elbow release for post-traumatic osteoarthritis was 16 weeks postoperatively, (2) patients reached 94% of their final arc of motion by 3 months postoperatively, with the largest improvement seen in flexion between 1-2 weeks and 6 weeks, (3) although the majority of recovery occurred within the first 3 months postoperatively, with small improvements seen up to 6 months after surgery, and (4) surgical approach, patient age, sex, and thresholds of motion did not confer a higher likelihood of achieving better postoperative ROM. These results were not consistent with our hypothesis that there would be distinct recovery trajectories and that patients with relatively worse preoperative motion would recover more slowly.

Unlike primary elbow OA, most of which is confined to the ulnohumeral joint, the effect of post-traumatic elbow OA is more variable and depends on the initial trauma, resulting in ligamentous instability and malalignments in the articular surface geometry that can result in altered contact pressures within the joint.¹ Open osteocapsular release in patients with post-traumatic elbow OA has proven to be a durable and effective treatment for this pathology.^{7,25} In a series conducted by Park et al, the mean arc of motion increased by approximately 60° at an average of 39 months postoperatively, with 88% of patients regaining a total arc of ≥100°. ²⁰

Similarly, Ehsan et al reported a mean gain in flexion of 58° at 12 months postoperatively, and Ring et al reported a mean improvement of 53° with a final average arc of 103°. ^{7,22} ROM increases have been reported up to over 100°, with multiple authors reporting improvements in functional outcomes scores over time. ^{5,23,24} Our cohort received an average 35° of improvement in the arc of motion by 6 months postoperatively, which is less than many studies reported in the literature. One explanation for this is that our cohort had higher preoperative flexion values than patients in the aforementioned studies. The flexion and extension values at final follow-up (133° ± 11 and 14° ± 12, respectively) are consistent with or exceed those reported in the literature, indicating the ability of our technique to reach similar endpoints despite a smaller overall net improvement. ^{20,22,23} Our results demonstrated that the majority of improvement occurred between 1-2 weeks and 6 weeks postoperatively and that over half of patients achieved their final arc of motions by the 3-month time point. At 1-2 weeks postoperatively, our patients had only achieved 11% of their flexion gain and 47% of their eventual extension gain from their preoperative baseline. However, by 3 months, they achieved 72% of their flexion and 76% of extension gain from preoperative. This suggests that most of the range of motion gains are achieved by 3 months postoperatively, and most patients fall within what would be considered a functional arc of motion. Thus, strong consideration can be given to discontinuing dedicated treatment at 3 months postoperatively if patients are trending in this way. The results from our study also

Table II
Percentage of total gains in flexion, extension, and arc at each follow-up interval.

	1-2 weeks (%)	6 weeks (%)	3 months (%)
Percentage of 6-month flexion gain from preoperative	11	72	94
Percentage of 6-month extension gain from preoperative	47	76	94
Percentage of 6-month arc gain from preoperative	29	74	94

Table III
Time to 6-month arc, by follow-up interval.

	Patients at ≥100% of their 6-month arc	Running total
1-2 weeks	12 (6%)	12 (6%)
6 weeks	25 (13%)	37 (20%)
3 months	68 (36%)	105 (56%)

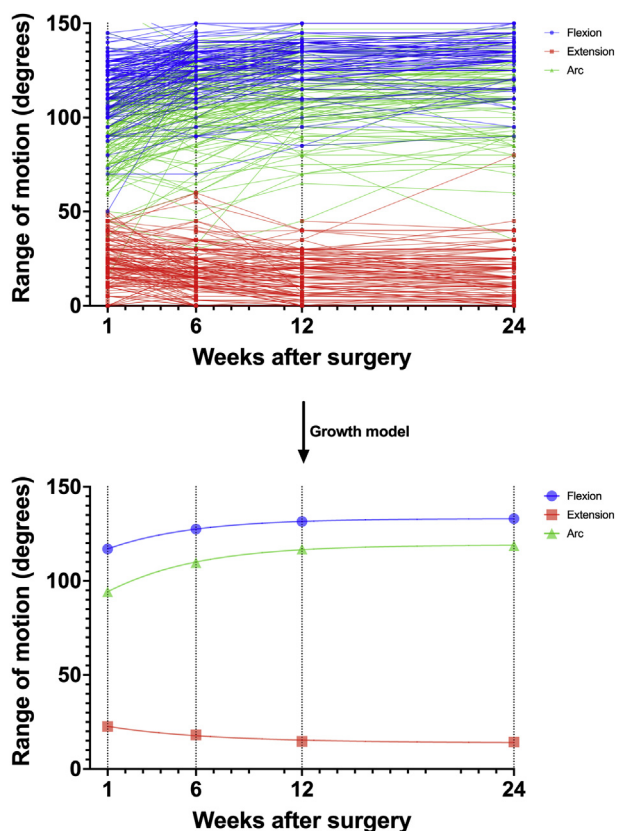


Figure 1 Growth modeling of flexion, extension, and arc.

have implications in setting expectations preoperatively and counseling patients during rehabilitation.

While surgical factors are undoubtedly crucial, rehabilitation has been shown to help patients achieve optimal outcomes after elbow release. In a randomized controlled trial, Guglielmetti et al showed that patients undergoing surgical elbow release for post-traumatic OA and treated with a postoperative rehabilitation protocol resulted in a greater final arc of motion than those treated with rehabilitation alone.⁸ Despite these findings, there is no consensus on postoperative rehabilitation protocol for elbow release. Static and dynamic splinting is beneficial for up to 12 months in patients treated nonoperatively for post-traumatic OA, indicating that the capsule can stretch over time.^{6,12,26} While many authors consider continuous passive motion (CPM) a mainstay of rehabilitation, others have shown no benefit of CPM after open

elbow release.^{2,14,16} The patients in our cohort received a combination of CPM and static progressive splinting in conjunction with formal therapy for the first 3 to 4 months postoperatively. The postoperative timepoint during which the bulk of the rehabilitation occurred corresponded with the period of greatest improvement in ROM, with over half of our cohort reaching their final arc of motion during that time. This suggests that our protocol effectively complements our surgical technique to provide optimal ROM outcomes for patients with post-traumatic OA. Furthermore, a sizeable proportion of our cohort was still experiencing improvement at 6-months postoperatively, indicating that our combination of surgery and rehabilitation provided lasting benefits in ROM up to and likely beyond this time point, although the clinical significance of this increase is unknown.

Growth mixture modeling did not identify any preoperative or intraoperative flexion or extension value that predicted postoperative ROM. We did not identify any patterns in recovery trajectory to target interventions or risk factors for slow or fast progression, even when divided into subgroups based on the final arc of motion or ROM at the first postoperative visit. Similarly, age, sex, and surgical approach were also not significant predictors of final ROM. Several authors have investigated predictors of final outcome after open elbow release for post-traumatic OA. Lindenhovius et al found that pain was the strongest predictor of final health status and arm-specific disability in the post-traumatic population. The authors also examined the difference between final flexion or extension values and postoperative Disabilities of the Arm, Shoulder, and Hand questionnaire (DASH) and the Short Form-36 scores.¹³ In contrast, Gundes et al found that a postoperative flexion >115° predicted increased postoperative patient satisfaction.⁹ The majority of our cohort reached this threshold before their first postoperative visit.

Growth mixture modeling has been applied to other orthopedic procedures, such as femoroacetabular impingement and total hip arthroplasty, to identify recovery trajectories that allow physicians to identify potential outliers and prevent complications or poor outcomes.^{10,19} Our inability to identify such trajectories after open elbow release for post-traumatic OA indicates that trends may not cross over to this procedure when considering ROM. Therefore, physicians must be diligent in monitoring each patient's progress and adjusting interventions accordingly to optimize patient outcomes on an individual level.

Limitations

There are a few limitations of this study to note. First, patient comorbidities were not available for our cohort, so there may be other predictors of postoperative ROM that were not assessed. Due to the availability of data, functional outcomes scores were unable to be included as part of the postoperative assessment. It should be noted that pain levels may play a large role in patients' evaluations of postoperative outcome.³ In this way, greater ROM does not necessarily imply greater function or satisfaction, and our results may represent only a single facet of a patient's overall outcome. Finally, although we had sufficient postoperative observations to employ a latent basis model, it is possible that underlying

trajectories could have been more accurately assessed with a larger cohort size, which would have given the model a higher likelihood of demonstrating and identifying more explicit group differences.

Conclusions

Patients undergoing open elbow release for post-traumatic stiffness reach their maximum arc of motion at an average of 16 weeks postoperatively, with most recovery happening between 6 weeks and 3 months. Growth mixture modeling of patients revealed no factors or preoperative ROM thresholds that predicted recovery trajectory. Our results have implications in setting expectations for recovery preoperatively and counseling patients during their rehabilitation.

Disclaimers:

Funding: No funding was disclosed by the authors.

Conflicts of interest: The authors, their immediate families, and any research foundation with which they are affiliated have not received any financial payments or other benefits from any commercial entity related to the subject of this article.

References

1. Biswas D, Wysocki RW, Cohen MS. Primary and posttraumatic arthritis of the elbow. *Arthritis* 2013;2013:473259. <https://doi.org/10.1155/2013/473259>.
2. Breen TF, Gelberman RH, Ackerman GN. Elbow flexion contractures: treatment by anterior release and continuous passive motion. *J Hand Surg Edinb Scotl* 1988;13:286-7.
3. Chammas M. Post-traumatic osteoarthritis of the elbow. *Orthop Traumatol Surg Res* 2014;100:S15-24. <https://doi.org/10.1016/j.otsr.2013.11.004>.
4. Cohen MS, Hastings H. Post-traumatic contracture of the elbow. Operative release using a lateral collateral ligament sparing approach. *J Bone Joint Surg Br* 1998;80:805-12.
5. Dai J, Zhang G, Li S, Xu J, Lu J. Arthroscopic treatment of posttraumatic elbow stiffness due to soft tissue problems. *Orthop Surg* 2020;12:1464-70. <https://doi.org/10.1111/os.12787>.
6. Doornberg JN, Ring D, Jupiter JB. Static progressive splinting for posttraumatic elbow stiffness. *J Orthop Trauma* 2006;20:400-4. <https://doi.org/10.1097/00005131-200607000-00006>.
7. Ehsan A, Huang JI, Lyons M, Hanel DP. Surgical management of posttraumatic elbow arthrofibrosis. *J Trauma Acute Care Surg* 2012;72:1399-403. <https://doi.org/10.1097/TA.0b013e3182471ec9>.
8. Guglielmetti CLB, Gracitelli MEC, Assunção JH, Andrade-Silva FB, Pessa MMN, Luzo MC, et al. Randomized trial for the treatment of posttraumatic elbow stiffness: surgical release vs. rehabilitation. *J Shoulder Elbow Surg* 2020;29:1522-9. <https://doi.org/10.1016/j.jse.2020.03.023>.
9. Gundes H, Selek Ö, Gok U, Gumuslu B, Buluc L. The relation between elbow range of motion and patient satisfaction after open release of stiff elbow. *Acta Orthop Traumatol Turc* 2017;51:303-7. <https://doi.org/10.1016/j.aott.2017.05.005>.
10. Hesselting B, Mathijssen NMC, van Steenberghe LN, Melles M, Vehmeijer SBW, Porsius JT. Fast starters, slow starters, and late dippers: trajectories of patient-reported outcomes after total hip arthroplasty: results from a Dutch Nationwide database. *J Bone Joint Surg Am* 2019;101:2175-86. <https://doi.org/10.2106/JBJS.19.00234>.
11. Kodde IF, van Rijn J, van den Bekerom MPJ, Eygendaal D. Surgical treatment of posttraumatic elbow stiffness: a systematic review. *J Shoulder Elbow Surg* 2013;22:574-80. <https://doi.org/10.1016/j.jse.2012.11.010>.
12. Lindenhovius ALC, Doornberg JN, Brouwer KM, Jupiter JB, Mudgal CS, Ring D. A prospective randomized controlled trial of dynamic versus static progressive elbow splinting for posttraumatic elbow stiffness. *J Bone Joint Surg Am* 2012;94:694-700. <https://doi.org/10.2106/JBJS.J.01761>.
13. Lindenhovius ALC, Doornberg JN, Ring D, Jupiter JB. Health status after open elbow contracture release. *J Bone Joint Surg Am* 2010;92:2187-95. <https://doi.org/10.2106/JBJS.H.01594>.
14. Lindenhovius ALC, van de Luitgaarden K, Ring D, Jupiter J. Open elbow contracture release: postoperative management with and without continuous passive motion. *J Hand Surg* 2009;34:858-65. <https://doi.org/10.1016/j.jhssa.2009.01.003>.
15. Mansat P, Morrey BF. The column procedure: a limited lateral approach for extrinsic contracture of the elbow. *J Bone Joint Surg Am* 1998;80:1603-15.
16. Morrey BF. Posttraumatic contracture of the elbow. Operative treatment, including distraction arthroplasty. *J Bone Joint Surg Am* 1990;72:601-18.
17. Morrey BF, An KN. Functional anatomy of the ligaments of the elbow. *Clin Orthop Relat Res* 1985;201:84-90.
18. Morrey BF, Askew LJ, Chao EY. A biomechanical study of normal functional elbow motion. *J Bone Joint Surg Am* 1981;63:872-7.
19. Nguyen TQ, Friedman JM, Flores SE, Zhang AL. Fast starters and slow starters after hip arthroscopy for femoroacetabular impingement: correlation of early postoperative pain and 2-year outcomes. *Am J Sports Med* 2020;48:2903-9. <https://doi.org/10.1177/0363546520952406>.
20. Park MJ, Chang MJ, Lee YB, Kang HJ. Surgical release for posttraumatic loss of elbow flexion. *J Bone Joint Surg Am* 2010;92:2692-9. <https://doi.org/10.2106/JBJS.1.01367>.
21. Ram N, Grimm KJ. Growth mixture modeling: a method for identifying differences in longitudinal change among unobserved groups. *Int J Behav Dev* 2009;33:565-76. <https://doi.org/10.1177/0165025409343765>.
22. Ring D, Adey L, Zurakowski D, Jupiter JB. Elbow capsulectomy for posttraumatic elbow stiffness. *J Hand Surg* 2006;31:1264-71. <https://doi.org/10.1016/j.jhssa.2006.06.009>.
23. Sun Z, Cui H, Ruan J, Li J, Wang W, Fan C. What range of motion and functional results can be expected after open arthrolysis with hinged external fixation for severe posttraumatic elbow stiffness? *Clin Orthop* 2019;477:2319-28. <https://doi.org/10.1097/CORR.0000000000000726>.
24. Sun Z, Li J, Luo G, Wang F, Hu Y, Fan C. What constitutes a clinically important change in Mayo Elbow Performance Index and range of movement after open elbow arthrolysis? *Bone Jt J* 2021;103-B:366-72. <https://doi.org/10.1302/0301-620X.103B2.BJJ-2020-0259.R3>.
25. Tan V, Daluiski A, Simic P, Hotchkiss RN. Outcome of open release for post-traumatic elbow stiffness. *J Trauma* 2006;61:673-8. <https://doi.org/10.1097/01.ta.0000196000.96056.51>.
26. Veltman ES, Doornberg JN, Eygendaal D, van den Bekerom MPJ. Static progressive versus dynamic splinting for posttraumatic elbow stiffness: a systematic review of 232 patients. *Arch Orthop Trauma Surg* 2015;135:613-7. <https://doi.org/10.1007/s00402-015-2199-5>.