

Point-of-care ultrasound during the COVID-19 pandemic: A multidisciplinary approach between intensivists and echocardiographers

Eugene Yuriditsky MD  | Muhamed Saric MD, PhD  | James M. Horowitz MD

Department of Medicine, Leon H. Charney
Division of Cardiology, NYU Langone
Medical Center, New York, NY, USA

Correspondence

Eugene Yuriditsky MD, 530 First Ave.
Skirball 9R, NYU Langone Medical Center,
New York, NY 10016.
Email: Eugene.yuriditsky@nyulangone.org

Abstract

Purpose: The coronavirus disease-2019 (COVID-19) led to a large influx of critically ill patients and altered echocardiography laboratory workflow. We developed a point-of-care ultrasound (POCUS) first approach to patients requiring echocardiography and describe our workflow and findings.

Methods: We performed a single-center retrospective analysis of all POCUS studies performed on critically ill patients with COVID-19. Sonography was performed by intensivists, uploaded and archived, and rapidly reviewed by echocardiographers. We evaluated each study based on the number of views obtained. Additionally, we provide a description of the workflow during the COVID-19 surge at a tertiary care hospital in New York City.

Results: Fifty patients had POCUS studies performed by intensivists and reviewed by echocardiographers obviating the need for sonographer-performed studies. Of the 48 cardiac POCUS studies, 17% of patients had 4 of 4 standard views available while 53% had 3 of 4 standard views. The parasternal long-axis view was obtained on 81%, subxiphoid view on 79%, apical 4-chamber view on 71%, and parasternal short-axis view on 63% of patients.

Conclusions: Our POCUS workflow allowed intensivists to perform cardiac sonography for rapid bedside diagnosis of pathology with immediate interpretation performed by echocardiographers. At least 3 views were obtained in the majority of cases.

KEYWORDS

COVID-19, lung ultrasound, point-of-care ultrasound, venous ultrasonography

1 | INTRODUCTION

The number of people diagnosed with coronavirus disease-2019 (COVID-19) worldwide is in excess of 1 million.¹ Approximately 14% of hospitalized patients with COVID-19 are treated in an intensive care unit (ICU).^{1,2} Point-of-care ultrasonography (POCUS) is an

essential imaging modality in the ICU used in the diagnosis and management shock and respiratory failure.³⁻⁵

In standard practice, the sonographer performs a full echocardiographic examination; however, no other organ systems are imaged. The primary advantages of a POCUS first approach to the critically ill patient during this pandemic are reducing exposure of

Abbreviations: COVID-19, Coronavirus disease-2019; ICU, Intensive care unit; LV, Left Ventricle; POCUS, Point-of-care ultrasound; PPE, Personal protective equipment; RV, right ventricle; SARS-CoV-2, Severe acute respiratory syndrome coronavirus-2.

sonographers to SARS Coronavirus 2 (SARS-CoV-2), conservation of personal protective equipment (PPE), whole body ultrasound performed as a single study, and often immediate bedside diagnosis.^{4,6-10} However, there is a wide range of skill among intensivists in the performance and interpretation of cardiac ultrasound. As suggested by the American Society for Echocardiography (ASE), this provided an opportunity for echocardiographers to work with intensivists in skill enhancement.^{6,7,11}

At our institution, we developed a multidisciplinary approach to POCUS during the COVID-19 pandemic; an integration of the expertise of echocardiographers and intensivists. POCUS studies were performed by intensivists, images were uploaded and archived, and feedback was provided rapidly, and often in real time, by echocardiographers. Aspects of this approach were integrated into the ASE guidelines on POCUS during the COVID-19 pandemic.⁸ In this article, we describe our multidisciplinary approach to POCUS during the COVID-19 pandemic and review our imaging findings.

2 | METHODS

2.1 | Equipment

At our institution, POCUS was the first-line ultrasound imaging technique in our ICU during the COVID-19 pandemic. Ultrasound studies were performed by intensivists using the Phillips Lumify ultrasound system using either an S4-1 broadband phase array transducer for cardiac and lung imaging and/or the L12-4 broadband linear array transducer for vascular and pleural imaging (Koninklijke Phillips, NV). Transducers were attached to Samsung Galaxy tablets (SAMSUNG) equipped with the Phillips Lumify application. Commonly, tablets were set on Nova Pro mounts (Tryten Technologies, Inc) equipped with transducer and ultrasound gel bottle holders. The touchscreen technology and minimal accessories allowed for easy and thorough disinfection. Devices were kept on the COVID units and designated solely for COVID-19 patients. All studies were performed in patient rooms either in the ICU or the ward.

2.2 | Image storage and interpretation

Ultrasound studies were ordered by the care team in our electronic health record system (Epic ©, Epic Systems Corporation, Milky Way, Verona, WI), and the patient was automatically added to the worklist in the Phillips Lumify application. After completion of the examination, images were uploaded to our ultrasound PACS system (Syngo © Dynamics workplace (version: VA20E_20.0.0.2645_HF02 Build 2645). A board-certified echocardiographer would read the study and provide a report in Epic. This collaboration afforded teaching opportunity for the intensivist and a means to have their image

interpretation evaluated. Archived images provided an option to compare POCUS studies to prior echocardiograms. During the initial phases of the pandemic at our institution, echocardiographers would review transthoracic echocardiogram (TTE) orders and in discussion with intensivists, often change the studies to POCUS to limit formal TTEs when deemed appropriate.

2.3 | PPE and disinfecting of devices

Intensivists performing POCUS entering the room of a mechanically ventilated patient required an N-95 mask, facie shield, gown, and 2 sets of gloves. Worklists on the Phillips Lumify application were updated, and the patient was selected prior to entering the room. After performing a POCUS examination, one layer of gloves was removed and the tablet and transducer were thoroughly cleaned with germicidal disposable wipes. Rolling stands housing the tablets stored on the unit obviated the need to place tablets on clean surfaces. No equipment was used on COVID negative patients to further mitigate potential spread.

3 | RESULTS

Over a period of 2 months, 50 patients underwent POCUS studies with images transmitted, archived, and reviewed by an echocardiographer. There was a total of 48 cardiac ultrasounds, 10 venous ultrasounds, and 6 lung ultrasounds. In each scenario, the POCUS study was of sufficient quality to answer the question posed by the intensivist. While level of comfort and experience in POCUS varied between intensivists, at the time of this study no individual was certified under the National Board of Echocardiography Examination of Special Competence in Critical Care Echocardiography. As a result of the POCUS studies, formal echocardiographic examination was not performed. The most common clinical scenario evaluated by POCUS was shock and hypotension (20/48 patients), suspected acute coronary syndrome (14/48 patients), suspected acute pulmonary embolism (8/48 patients), and respiratory failure (6/48 patients). In each scenario, urgent ultrasound was felt necessary to answer the clinical question and advance management.

We reviewed the views obtained on the 48 cardiac ultrasound studies. An examination with all 4 views included a parasternal long-axis view, parasternal short-axis view, apical 4-chamber view, and subxiphoid view. Eight patients (17%) had all 4 views, 25 (52%) had 3 views, 10 (21%) had 2 views, and 5 (10%) had a single view obtained (Figure 1). The parasternal long-axis view was obtained on 39/48 patients (81%), subxiphoid view on 38/48 patients (79%), apical 4-chamber view on 33/48 patients (71%), and parasternal short-axis view on 30/48 patients (63%) (Figure 2).

The most common finding of cardiac POCUS in the ICU was normal biventricular function without significant pericardial effusion

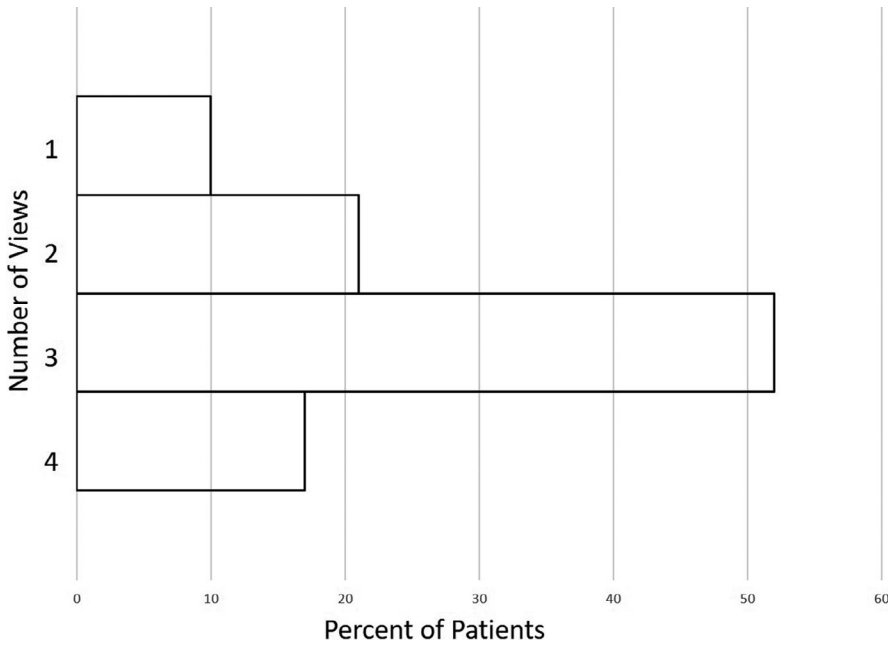


FIGURE 1 Number of unique echocardiographic views obtained

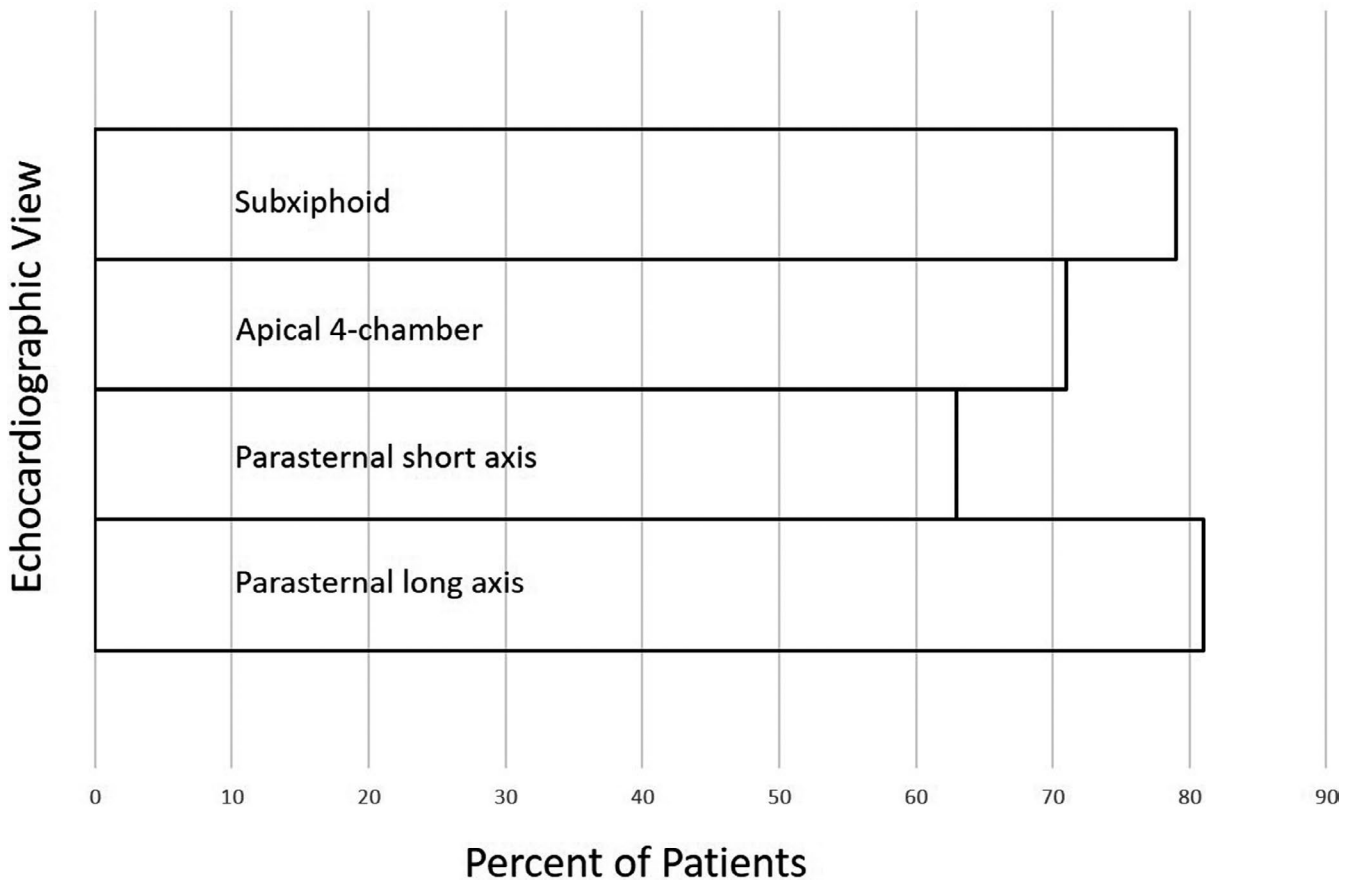


FIGURE 2 Specific echocardiographic views obtained

(39/48 studies). As a result, cardiac causes of shock or hypotension were excluded shifting focus to alternative pathophysiology such as vasodilatory shock. Of the remaining cases, 2 patients had right significant ventricular (RV) dysfunction, and 7 had left ventricular (LV) dysfunction and/ or regional wall motion abnormalities.

4 | DISCUSSION

Ultrasonography is an indispensable tool in the management of critically ill patients. Echocardiography provides for rapid diagnosis of shock states and causes of respiratory failure. A large influx of critically ill patients

with COVID-19 to our institution prompted a number of workflow changes to our echocardiography laboratory with the goal of maintaining the highest standards of care while protecting healthcare workers.

Our collaborative approach between echocardiographers and intensivists has a number of distinct advantages. POCUS images are archived for comparison to prior studies and availability for future review whereas previously clips were not being stored. Echocardiographers are able to provide real time feedback to intensivists upon image review to help guide decision-making. This collaboration is likely most useful to less experienced POCUS operators and allows for an immediate second opinion on image interpretation. As such, we obviated the need for a number of formal TTE studies and were able to protect sonographers and conserve PPE. While POCUS interpretation is generally binary (ie, pericardial effusion present or absent), collaboration with echocardiographers allowed for more granular interpretation of imaging findings.

In review of our data, 69% of patients had at least 3 echocardiographic views available for interpretation. In cases where fewer views were obtained, the data were sufficient to answer the clinical question posed. In cases of shock, often a single view demonstrating normal or hyperdynamic biventricular function without a significant pericardial effusion was sufficient to exclude multiple causes of circulatory failure.

In total, 9/48 patients (19%) had significant pathology on cardiac POCUS that was thought to explain the cause of the patients' decompensation; 2 patients had significant RV dysfunction, and 7 patients had significant LV dysfunction. As studies were not performed in a systematic way, we are unable to comment on the true frequency of cardiac pathology among critically ill patients with COVID-19.

Likely, some POCUS studies were performed during instances of acute deterioration and were not transmitted for review therefore limiting the numbers in this report. As such, we are unable to comment on the utility of those studies in regard to answering the question posed. As POCUS interpretation is often binary, more advanced cardiac assessment, such as evaluation of valvular dysfunction, is usually not performed by intensivists and requires advanced skills. A formal approach integrating a strict POCUS protocol, and more advanced training and simulations for intensivists may improve both study quality and interpretation.

5 | CONCLUSIONS

To limit exposure of sonographers to SARS-CoV-2 and conserve PPE, we established a system at our institution that allowed for intensivist-performed POCUS to be immediately interpreted by echocardiographers with images stored for future access. Of the patients that underwent cardiac POCUS, the majority of patients had at least 3 views available for interpretation. In each instance, it was felt that the study was sufficient to urgently answer the question and understand the pathophysiology of respiratory failure and shock. Whether this approach will prove useful in post-pandemic times is worth exploring.

CONFLICT OF INTEREST

None.

DATA AVAILABILITY STATEMENT

The data that support the findings of this study are available from the corresponding author upon reasonable request.

ORCID

Eugene Yuriditsky  <https://orcid.org/0000-0003-2263-9297>

Muhammed Saric  <https://orcid.org/0000-0001-7682-3749>

REFERENCES

- Phua J, Weng LI, Ling L, et al Intensive care management of coronavirus disease 2019 (COVID-19): challenges and recommendations. *Lancet Respir Med.* 2020;8(5):506-517.
- Richardson S, Hirsch JS, Narasimhan M, et al Presenting characteristics, comorbidities, and outcomes among 5700 patients hospitalized with COVID-19 in the New York city area. *JAMA.* 2020;323(20):2052-2059.
- Narasimhan M, Koenig SJ, Mayo PH A whole-body approach to point of care ultrasound. *Chest.* 2016;150(4):772-776.
- Johri AM, Galen B, Kirkpatrick JN, Lanspa M, Mulvagh S, Thamman R ASE statement on point-of-care ultrasound during the 2019 novel coronavirus pandemic. *J Am Soc Echocardiogr.* 2020;33(6):670-673.
- Cheung JC-H, Lam KN POCUS in COVID-19: pearls and pitfalls. *Lancet Respir Med.* 2020;8(5):e34-e34.
- Picard MH, Weiner RB Echocardiography in the time of COVID-19. *J Am Soc Echocardiogr.* 2020;33(6):674-675.
- Kirkpatrick JN, Grimm R, Johri AM, et al Recommendations for echocardiography laboratories Participating in Cardiac Point of Care Cardiac Ultrasound (POCUS) and critical care echocardiography training: report from the american society of echocardiography. *J Am Soc Echocardiogr.* 2020;33(4):409-422.e404.
- Kirkpatrick JN, Mitchell C, Taub C, Kort S, Hung J, Swaminathan M ASE Statement on protection of patients and echocardiography service providers during the 2019 novel coronavirus outbreak: endorsed by the American college of cardiology. *J Am Soc Echocardiogr.* 2020;33(6):648-653.
- Kim DJ, Jelic T, Woo MY, Heslop C, Olszynski P Just the facts: recommendations on point-of-care ultrasound use and machine infection control during the coronavirus disease 2019 pandemic. *CJEM.* 2020;22(4):445-449.
- Zhang L, Wang B, Zhou J, Kirkpatrick J, Xie M, Johri AM Bedside focused cardiac ultrasound in COVID-19 from the Wuhan epicenter: the role of cardiac point-of-care ultrasound, limited transthoracic echocardiography, and critical care echocardiography. *J Am Soc Echocardiogr.* 2020;33(6):676-682.
- Drake DH, De Bonis M, Covella M, et al Echocardiography in pandemic: front-line perspective, expanding role of ultrasound, and ethics of resource allocation. *J Am Soc Echocardiogr.* 2020;33(6):683-689.

How to cite this article: Yuriditsky E, Saric M, Horowitz JM. Point-of-care ultrasound during the COVID-19 pandemic: A multidisciplinary approach between intensivists and echocardiographers. *Echocardiography.* 2021;38:446-449. <https://doi.org/10.1111/echo.14996>