



Original Article

Covid-19-associated fungal osteomyelitis of jaws and sinuses: An experience-driven management protocol

Amal Suresh ^{1,*}, Abhijit Joshi², Anil Kumar Desai³, Uday Juturu⁴, Denis Jacob Kurian⁵, Pavithra Jain⁶, R. D. Kulkarni⁷ and Niranjana Kumar⁸

¹Assistant Professor, Department of Oral and Maxillofacial Surgery, SDM Craniofacial Surgery and Research Centre, SDM College of Dental Sciences and Hospital, A Constituent Unit of Shri Dharmasthala Manjunatheshwara University, Dharwad, 580009, Karnataka, India, ²Additional Professor, Department of Oral and Maxillofacial Surgery, SDM Craniofacial Surgery and Research Centre, SDM College of Dental Sciences and Hospital, A Constituent Unit of Shri Dharmasthala Manjunatheshwara University, Dharwad, 580009, Karnataka, India, ³Professor and Head, Department of Oral and Maxillofacial Surgery, SDM Craniofacial Surgery and Research Centre, SDM College of Dental Sciences and Hospital, A Constituent Unit of Shri Dharmasthala Manjunatheshwara University, Dharwad, 580009, Karnataka, India, ⁴Resident, Department of Oral and Maxillofacial Surgery, SDM Craniofacial Surgery and Research Centre, SDM College of Dental Sciences and Hospital, A Constituent Unit of Shri Dharmasthala Manjunatheshwara University, Dharwad, 580009, Karnataka, India, ⁵Resident, Department of Oral and Maxillofacial Surgery, SDM Craniofacial Surgery and Research Centre, SDM College of Dental Sciences and Hospital, A Constituent Unit of Shri Dharmasthala Manjunatheshwara University, Dharwad, 580009, Karnataka, India, ⁶Assistant Professor, Department of Microbiology, SDM College of Medical Sciences and Hospital, A Constituent Unit of Shri Dharmasthala Manjunatheshwara University, Dharwad, 580009, Karnataka, India, ⁷Professor and Head, Department of Microbiology, SDM College of Medical Sciences and Hospital, A Constituent Unit of Shri Dharmasthala Manjunatheshwara University, Dharwad, 580009, Karnataka, India and ⁸Professor and Head, Department of Plastic and Reconstructive Surgery, SDM College of Medical Sciences and Hospital, A Constituent Unit of Shri Dharmasthala Manjunatheshwara University, Dharwad, 580009, Karnataka, India

*To whom correspondence should be addressed. Amal Suresh, Department of Oral and Maxillofacial Surgery, SDM Craniofacial Surgery and Research Centre, SDM College of Dental Sciences and Hospital, A Constituent Unit of Shri Dharmasthala Manjunatheshwara University, Dharwad, 580009, Karnataka, India. Tel: +91 9686721200; E-mail: dramalsuresh@gmail.com

Received 24 June 2021; Revised 16 December 2021; Accepted 22 December 2021; Editorial Decision 20 December 2021

Abstract

Invasive fungal co-infections with COVID-19 are currently being reported at an alarming rate. Our study explores the importance of early identification of the disease, probable etiopathogenesis, clinical and radiological features and a treatment protocol for COVID-19 Associated Fungal Osteomyelitis of Jaws and Sinuses (CAFOJS). A one-year prospective study from June 2020 to May 2021 was conducted among CAFOJS diagnosed patients at a tertiary care center in South India. Demographic details, COVID-19 infection and treatment history, time taken for initiation of symptoms after COVID-19 diagnosis, medical history and clinical features were recorded. All patients were managed with a standard diagnostic and intervention protocol which included pre-operative and post-operative administration of Inj. Amphotericin B 50 mg (liposomal), early aggressive surgical debridement and tab. Posaconazole GR 300 mg OD for 90 days after discharge. Thirty-nine (78%) patients were diagnosed with CAFOJS out of 50 osteomyelitis patients. 35 patients (90%) were diabetic and 21 patients (54%) were known to receive steroids during the COVID-19 treatment. Sole existence of *Mucorales spp.* was seen in 30 patients (77%), *Aspergillus fumigatus* in 2 patients (5%), *Curvularia spp.* in 2 patients (5%). Concomitant existence of *Mucorales* and *Aspergillus fumigatus* was reported in two patients (5%) and *Candida albicans* in three patients (8%). Patients underwent treatment with standard protocol and no recurrence noted. CAFOJS is a clinical entity with aggressive presentation and warrants early diagnosis and treatment.

Lay summary

Invasive fungal infections of head and neck region cause necrosis of bones affected by it, especially maxilla. Early diagnosis and treatment are advocated in such infections due to its aggressive clinical presentation compared to similar infections before COVID-19 pandemic.

Key words: Fungal osteomyelitis, COVID-19, Mucormycosis, Curvalaria, Aspergillosis, Maxillectomy.

Introduction

The consequences related to COVID-19 infection has not been studied properly yet. One of the serious consequences associated with this virus which has gained attention among health workers and public is invasive opportunistic fungal infection of oro-facial region. Opportunistic fungal infections affecting human body are mucormycosis, candidiasis, aspergillosis, cryptococcosis, pneumocystis etc. Among these, candidiasis is the most common fungal infection orofacial region followed by Aspergillosis and mucormycosis.¹ Opportunistic fungi invade the arteries leading to thrombosis and further compromised blood supply to the soft and hard tissues of the affected region causing osteomyelitis.² We have termed the fungal osteomyelitis of jaws occurring in COVID-19 recovered patients as COVID-19 Associated Fungal Osteomyelitis of Jaws and sinuses (CAFOJS).

Incidence of fungal osteomyelitis is more in maxilla (52%) due to close proximity to paranasal sinuses, the male to female ratio is 2.1:1 and the age group affected is 10–65 years.² Mucorale species, causing mucormycosis was noted to be the most common organism causing fungal osteomyelitis (44%) followed by *Aspergillus* spp. (2%).² Prakash H and Chakrabarthi A reported the prevalence of mucormycosis in India to be 0.02 to 9.5 cases per 100 000 population which is 70 times more than global data.³

Our study focuses on presenting a one-year audit of CAFOJS patients who reported to our department. The study explores the importance of early identification of the disease, probable etiopathogenesis, clinical and radiological features and a treatment protocol for CAFOJS.

Methodology

Single centre prospective study was conducted at our tertiary care teaching institute from June 2020 to May 2021. Institutional ethics committee clearance obtained for the study (No. 2021/S/OS/83). Data was obtained from all the patients diagnosed with fungal osteomyelitis of jaws. Demographic details, chief complaint, COVID-19 infection and treatment history, date of initiation of CAFOJS symptoms, medical history, clinical features were recorded for all the patients suspected of fungal osteomyelitis of jaws. Standard imaging for all patients included orthopantomogram (OPG), paranasal sinus view (PNS),

contrast enhanced computed tomography (CECT) and magnetic resonance imaging (MRI).

Blood investigations, KOH staining, fungal culture and histopathological evaluation were done for all patients. Patients without any COVID-19 infection history which is confirmed by RTPCR test or negative fungal culture report were excluded from the study and were given treatments as per the protocol.² All the patients were treated as per our standardized protocol which included two to three doses of intravenous liposomal amphotericin B 50 mg (AMB) each preoperatively, followed by aggressive surgical debridement, 2 to 8 doses of inj. AMB 50 mg post-operatively depending upon the extent of involvement and the residual lesion (if present). We followed a protocol of administering inj. AMB 50 mg as a single dose irrespective of patient's weight, on alternative days with strict monitoring of renal parameters and electrolyte values. Patients were discharged with 90 days of oral Posaconazole GR 300 mg BD on first day, followed by OD and close follow up was done. The data were recorded and analyzed.

Results

A total of 50 patients were diagnosed with osteomyelitis of jaws during the study period, in which 11 patients were excluded from the study since nine among them gave negative covid-19 infection history and 2 were negative for fungal infection. Thirty-nine CAFOJS patients (78%) comprised the study group. Age of the patients ranged from 34 years to 72 years with a mean age of 50.69 years. 32 were male patients (82%) and 7 were female (18%). Patient presented with tooth pain (n = 32, 80%), tooth mobility (n = 38, 97%), gingival swelling (n = 27, 69%) (Figure 1a), ulceration or blackish discoloration of hard plate (n = 12, 31%) (Figure 1b), sinus opening with pus discharge (n = 27, 69%), infraorbital paraesthesia (n = 31, 80%) and facial swelling with pain (n = 30, 77%). Time period from diagnosis of COVID-19 infection (positive RT-PCR test) and development of CAFOJS symptoms ranged from one day to 159 days with a mean of 53.38 days. 21 patients (54%) received corticosteroids during the COVID-19 treatment, 8 patients (21%) did not receive steroids and 10 patients (26%) were unaware of the treatment they received, nor they had any treatment records with them. 32 patients gave history of diabetes (82%), 3 patients (8%) were diagnosed as diabetic on reporting to us, and 4 patients

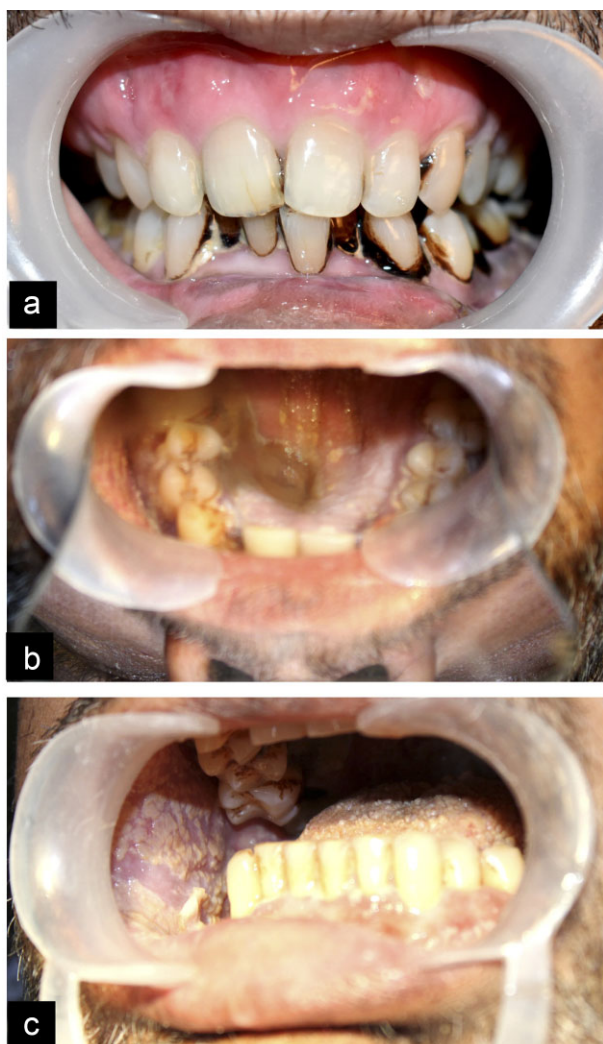


Figure 1. (a) Clinical picture showing gingival swelling. (b) Clinical picture showing blackish discoloration of hard palate. (c) Clinical picture showing white scrapable lesion of buccal mucosa suggestive of candida co-infection.

(10%) were non-diabetic. The HbA1c of the diabetic patients ranged from 6.6 to 14.2 with a median of 10.1. Data summarized in Table 1.

Features on CECT PNS scan (Figure 2a) revealed maxillary sinus mucosal thickening ($n = 39$, 100%), erosion of alveolar process of maxilla ($n = 39$, 100%), destruction of hard palate ($n = 36$, 92%), erosion of anterior wall of maxillary sinus ($n = 37$, 95%), involvement of ethmoid sinus ($n = 21$, 54%), involvement of sphenoid sinus ($n = 21$, 54%), oro-antral fistula ($n = 4$, 10%), hypertrophied turbinate ($n = 21$, 54%) and deviation of nasal septum ($n = 10$, 26%). Bilateral CAFOJS noted in 31 patients (80%).

KOH wet mount preparation was positive for fungal elements in 27 patients (69%). Fungal culture reported as sole existence of *Mucorales spp.* in 30 patients (77%), *Aspergillus fumigatus* in 2 patients (5%), *Curvularia lunata* in 2 patients (5%). Concomitant existence of *Mucorales* and *Aspergillus* was reported in two

patients (5%) and *C. albicans* in 3 patients (8%). Histopathological examination revealed fungal osteomyelitis of jaws in all the patients and specifically reported as mucormycosis in 16 patients (41%).

37 patients received treatment from our center and 2 patients did not report to us for treatment. Alveolectomy was performed in two patients (5%), hemi-maxillectomy was done in 18 patients (49%), sub-total maxillectomy in 6 patients (16%), total maxillectomy was done in 6 patients (16%) and ethmoidal and sphenoidal sinus debridement was done with Functional Endoscopic Sinus Surgery by ENT surgeons in five patients (14%) along with partial maxillectomy. All open surgical procedures were done through intra-oral approach only (Figure 3). Patients were followed up closely for maximum of 11-month post treatment.

One patient reported back with persistent wound dehiscence 6 months post operatively and was managed surgically using buccal advancement flap. No signs of recurrence were seen in any of the patients till date. No other harms or adverse events encountered.

Discussion

Osteomyelitis is defined as an inflammation of the medullary cavities, haversian system, and adjacent cortex of bone. In the present COVID-19 scenario, the incidence of fungal osteomyelitis of jaws and sinuses has increased and mucormycosis is commonest among them. Mucormycosis is an opportunistic fatal fungal infection caused due to fungi belonging to the *Mucorales* order.¹ It can manifest as varied clinical presentations ranging from localized to disseminated infections. Pulmonary or disseminated diseases are commonly found in immunocompromised patients, cutaneous and soft tissue mucormycosis in immunocompetent patients and rhino-cerebral form is typically seen in diabetic patients. The rhino-cerebral form of mucormycosis usually originates from the paranasal sinuses and further destroys the bone invading into orbit, eye, and brain. The fungus invades the arteries causing thrombosis that result in necrosis of hard and soft tissues causing osteomyelitis of involved bone.⁴

Our study patients had history of recent recovery from COVID 19 infection. The high aggressive feature of SARS-COV-2 virus to the lung tissue and the large bilateral alveolo-interstitial lesions make the occurrence of invasive fungal infections very likely, especially those with pulmonary entry and an airborne route of infection. The absolute number of T Lymphocytes, CD4 + T and CD8 + T cells are shown to be markedly lower in severe viral infection cases than moderate cases, associated with markedly higher levels of IL-2R, IL-6, IL-10, TNF-alpha and other inflammatory markers.^{5,6} This immunocompromised state of the patients may predispose them to opportunistic invasive fungal infection.

Table 1. Demographic and clinical details of the CAFOJS patients.

Number	Age/sex	Time period from RTPCR positive to initiation of CAFOJS symptoms	Diabetic status	HBA1C	KOH	Fungal culture	Steroid received	Total amphotericin B received (mg)
1	58/female	36	YES	12.2	Positive	<i>MUCORALE SPP.</i>	Not available	250
2	58/male	76	YES	13.3	Positive	<i>MUCORALE SPP.</i>	Dexamethasone	250
3	65/male	139	YES	6.6	Positive	<i>MUCORALE SPP.</i>	Not available	250
4	44/male	49	NO	7.2	Positive	<i>MUCORALE SPP.</i>	Not available	250
5	46/male	96	YES	10.1	Positive	<i>MUCORALE SPP.</i>	Not available	250
6	70/male	106	YES	8.8	Positive	<i>MUCORALE SPP.</i>	Not available	250
7	68/male	144	YES	6.7	Positive	<i>MUCORALE SPP.</i>	Methyl prednisolone	250
8	52/male	159	YES	8.8	Negative	<i>MUCORALE SPP.</i>	Not available	250
9	50/male	144	NO	7	Positive	<i>MUCORALE SPP.</i>	Not available	250
10	56/male	1	YES	10.9	Positive	<i>MUCORALE SPP.</i>	Not available	250
11	42/male	14	YES	11.1	Positive	<i>CURVULARIA LUNATA</i>	Not available	250
12	48/male	16	YES	6.9	Negative	<i>Aspergillus fumigatus</i>	Not available	250
13	47/male	17	YES	12.1	Positive	<i>MUCORALE SPP.</i>	Nil	550
14	48/male	1	YES	10.1	Negative	<i>MUCORALE SPP.</i>	Methyl prednisolone	250
15	34/male	35	YES	4.2	Positives	<i>MUCORALE SPP.</i>	Dexamethasone	700
16	42/male	29	YES	9.3	Negative	<i>MUCORALE SPP.</i>	Methyl prednisolone & dexamethasone	400
17	72/male	51	YES	10.4	Negative	<i>MUCORALE SPP.</i>	Dexamethasone	250
18	42/male	45	YES	5.1	Negative	<i>MUCORALE SPP.</i>	Methyl prednisolone	250
19	44/male	37	YES	10.5	Negative	<i>CURVULARIA LUNATA</i>	Methyl prednisolone	250
20	47/female	35	YES	7.6	PositiveS	<i>MUCORALE SPP.</i>	Methyl prednisolone	250
21	54/male	46	YES	13.1	Negative	<i>MUCORALE SPP.</i>	NIL	400
22	52/male	33	YES	13.5	Positive	<i>MUCORALE SPP.</i>	Methyl prednisolone	350
23	41/male	41	YES	9.2	Positive	<i>MUCORALE SPP.+ CANDIDA ALBICANS</i>	Nil	300
24	60/male	103	DIAGNOSED ON REPORTING	7.1	Positive	<i>MUCORALE SPP.</i>	Nil	250
25	57/male	60	YES	14.2	Positive	<i>MUCORALE SPP. + ASPERGILLUS FUMIGATUS</i>	Methyl prednisolone	250
26	43/male	23	YES	11.3	Positive	<i>MUCORALE SPP.</i>	Methyl prednisolone	250
27	52/male	15	YES	11.1	Positive	<i>MUCORALE SPP.</i>	Methyl prednisolone	250
28	60/female	21	YES	9.1	Positive	<i>MUCORALE SPP.</i>	Methyl prednisolone	400
29	57/male	35	YES	11.2	Negative	<i>MUCORALE SPP.</i>	Dexamethasone	250
30	60/male	66	DIAGNOSED ON REPORTING	10.6	Positive	<i>MUCORALE SPP.</i>	Nil	250
31	38/male	37	YES	9.3	Positive	<i>MUCORALE SPP.</i>	Nil	250
32	36/male	27	NO	7	Positive	<i>Aspergillus fumigatus</i>	Dexamethasone	400
33	27/female	35	DIAGNOSED ON REPORTING	11.5	Negative	<i>MUCORALE SPP.</i>	Methyl prednisolone	400
34	45/female	66	YES	13.1	Positive	<i>MUCORALE SPP.</i>	Methyl prednisolone	250
35	64/female	56	YES	9.2	Negative	<i>MUCORALE SPP.</i>	Methyl prednisolone	400
36	46/male	57	YES	11.5	Positive	<i>MUCORALE SPP.</i>	Nil	400
37	52/male	34	YES	7.9	Positive	<i>MUCORALE SPP.</i>	Methyl prednisolone & dexamethasone	550
38	51/male	52	YES	5.1	Negative	<i>MUCORALE SPP.</i>	Methyl prednisolone & dexamethasone	400
39	49/female	45	NO	6.3	Positive	<i>MUCORALE SPP.</i>	Nil	250

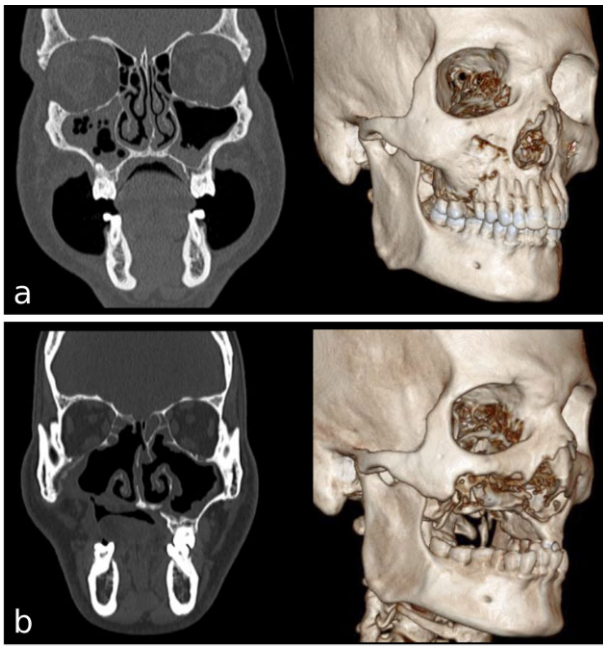


Figure 2. (a) Computed tomographic images showing the extent of the lesion. (b) 6 month followup computed tomographic images.

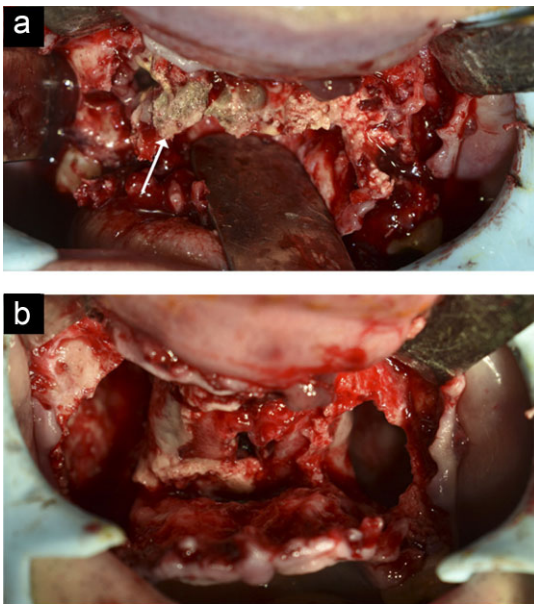


Figure 3. (a) Intraoperative photograph showing necrotic bone. (b) Intraoperative photograph after surgical debridement and extraction of involved teeth.

In our study, fungal culture identified 36 patients with *Mucorales spp.*, one patient each had concomitant presence of *Aspergillus fumigatus* and *C. Albicans* (Figure 1c). Two patients had only *Aspergillus fumigatus* and another two had *Curvularia lunata* causing osteomyelitis. Aspergillosis infection is commonly found in severely immunocompromised patients and not frequently with uncontrolled diabetes. On the other hand, hyperglycemic status provides an optimal condition for the growth of *mucorales*.⁷

Curvularia Spp. is a dematiaceous filamentous fungus. It can enter in human body by local implantation following trauma or inhalation. Among the 31 known species of *Curvularia Spp.*, *curvularia lunata* is the most common. Infection by these species can occur in individuals with intact or compromised immune system. *Curvularia* infection of sino-nasal or maxilla is rare, and the first case of maxillary osteomyelitis caused by this organism was reported in our hospital in 2013. Aggressive surgical debridement and combination anti-fungal therapy are the favored treatment suggested in literature.⁸

Diabetes mellitus, a classic risk factor for mucormycosis, is associated with increased morbidity and mortality in COVID-19 infection. *Rhizopus arrhizus*, produces the enzyme ketoreductase, which utilizes the ketone bodies. Patients with COVID-19 infection are predisposed to diabetic keto acidosis, like any other infection. SARS-Cov-1 induces damage to pancreatic islets resulting in acute diabetes and diabetic keto acidosis. This is said to be the reason for the diabetogenic state in SARS Cov-2 infection, as there is high expression of angiotensin converting enzyme 2 receptors in pancreatic islets, along with increase insulin resistance due to cytokine storm.^{7,9,10} In our study, 32 patients were under treatment for diabetes, but three patients were diagnosed after reporting to us. These three patients could have gotten diabetes due to the organ damage caused by SARS-COV-2 virus itself. Acidemic states and hyperglycemia induce endothelial receptor glucose-regulated protein (GRP 78) and the Mucorales adhesin spore coat protein homologs (CotH), creating a perfect storm for increased adhesion and penetration of *mucorales* to the endothelium.⁶ Along with the hyperglycemic state, use of steroids during the treatment of moderate to severe COVID-19 infection, that exacerbates the glucose homeostasis, may have predisposed patients to mucormycosis co-infection.^{11,12}

COVID-19 infection also causes alteration of iron metabolism in severe cases resulting in a hyper-ferritinemic syndrome. These high ferritin levels lead to excess intracellular iron that in turn generates reactive oxygen species resulting in tissue damage. Cytokines, majorly by IL6, stimulate ferritin synthesis and down-regulate iron export resulting in intracellular iron overload due to severe infection and diabetic keto acidosis. The tissue damage caused by excessive iron overload, release free iron into circulation. Iron overload and excess free iron in circulation in acidemic states are one of the key and unique risk factors for mucormycosis infection.¹³

Opportunistic fungal infections are presently hypothesized to be hospital-acquired also, due to the use of non-sterile instruments, contaminated linen, wooden tongue depressors, water used in oxygen humidifiers and medical devices such as insulin pumps, catheters etc. Molds may also be found in air, dust, water, or any surfaces of the hospital. Defective ventilation systems and water leakage in hospital setup is also attributed to incidence of mucormycosis.¹² Over loaded hospital wards and ICU along with increase of workload for the healthcare workers have led

to compromised hospital atmosphere and defective handling of devices, instruments, linen, food packaging etc. We have not observed any direct correlation of CAFOJS to be hospital acquired.

The diagnosis of CAFOJS depends on an expert clinician, availability of imaging techniques, mycological and histopathological investigations. The patients with CAFOJS usually presents with clinical features ranging from tooth mobility, tooth ache, gingival swelling, palatal ulceration or blackish discoloration, sinus opening with pus discharge, nasal blockage on the affected side, unilateral facial swelling, proptosis, palatal or palpebral fistula, orbital pain, facial numbness, and black necrotic skin in extensive cases. Intra-orally it usually affects hard palate first due to its proximity to the nasal floor and para nasal sinuses. The patient presenting with these classical symptoms of CAFOJS should be asked for COVID-19 infection history and the duration of hospital or ICU stay and the treatment received. The comorbidities should be thoroughly investigated with special emphasis on diabetic status. History of corticosteroid administration during the COVID-19 treatment should be asked, which plays an important role in further compromising the immunity in COVID patients, providing a favorable environment for the opportunistic fungal infections to establish. In our study only 21 patients were confirmed to have received steroids during the treatment of COVID-19 and 8 patients did not receive steroids. But the strength and duration of steroid treatment was unknown. 10 patients who reported to us initially, during the first wave of COVID-19 pandemic did not have any treatment records. These patients also would have received steroids. Establishing a casual effect relationship between steroid administration and CAFOJS is difficult due to lack of complete COVID 19 treatment details in our patients.

CAFOJS symptoms were noted to be set in as early as 1 day after diagnosis of COVID-19 by RT-PCR and as late as 159 days with a mean of 53 days. This suggests that the infection can be very aggressive and can be presented concomitantly with COVID-19 symptoms. Patients with any immunocompromised conditions, receiving corticosteroids or any other immunosuppressive drugs during the treatment of COVID-19 should be screened for invasive fungal infections and should be followed up closely.

An OPG and PNS view can reveal radio-opacity of involved sinuses and change in bone pattern of the affected maxilla in COVID-19 recovered patients. This is of value in those who are presenting only with tooth pain or mobility. CT scan should be performed in suspected patients along with MRI if cerebral or orbital extension is suspected. MRI has greater sensitivity than CT for evaluating cranial or ophthalmic extension.¹⁴ Guidelines provided by European Confederation of Medical Mycology suggests CT scans to be performed every week to evaluate the progress of the treatment provided.¹⁴ But in view of poor-socioeconomic background in many of our patients to reduce the financial burden, we performed CECT immediately after surgical

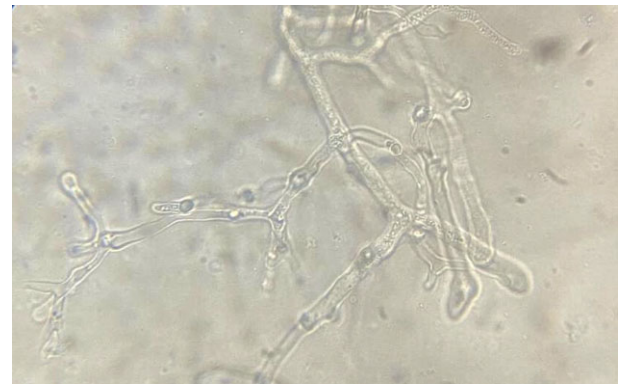

Figure 4. KOH wet mount preparation showing direct evidence of presence of broad sparsely septate fungal hyphae suggestive of mucormycosis.

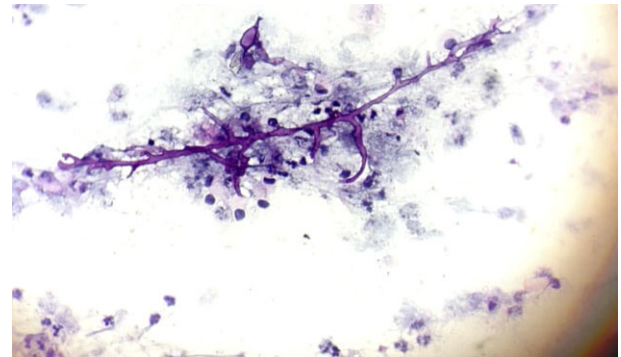


Figure 5. Hematoxylin and eosin (H&E, 40X) staining showing broad, non-septate with irregular branching hyphae (usually at 90 degrees) suggestive of mucormycosis in tissue.

debridement to check for any residual lesion. Follow up CT was performed at 3 months and 6 months (Figure 2b) to evaluate the treatment outcome and for dental rehabilitation planning.

If CAFOJS is a potential diagnosis after clinical and radiological evaluation, mycological test and histopathological investigation is mandatory to confirm the diagnosis. KOH wet mount preparation to demonstrate fungal elements is an easy and quick investigation to get the initial confirmation of any fungal infection. In our study only 27 out of 39 patients (69%), KOH was positive for fungal elements (Figure 4), correlating to the less sensitivity of the test. But KOH staining will help in early initiation of anti-fungal therapy if reported positive since it is quicker than other tests. Performing an open biopsy for histopathological evaluation is preferred to confirm the diagnosis (Figure 5). Identification of fungal species is difficult by histopathological examination although it is not impossible. Histopathology reports of 15 patients in our study were specifically diagnosed as osteomyelitis induced by mucormycosis. Therefore, confirmation of the presence of any fungus should be done by culture (Figure 6) or by molecular or in situ identification techniques (if available).¹⁴

Effective treatment of CAFOJS depends on the early diagnosis, immediate commencement of intravenous antifungal therapy,

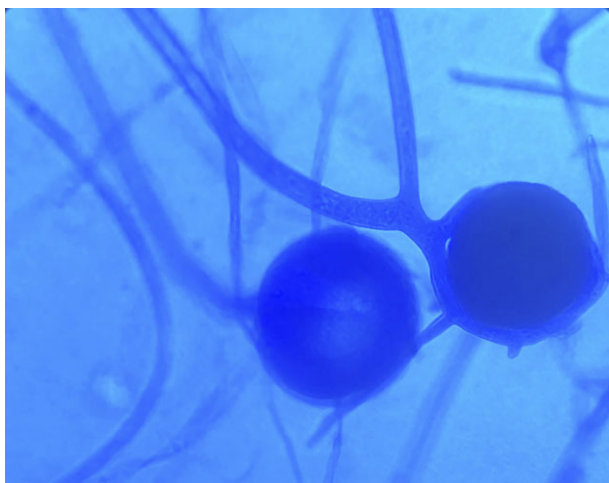


Figure 6. Lactophenol cotton blue mount showing rhizoids and sporangium of *Rhizopus microspores* (400× magnification).

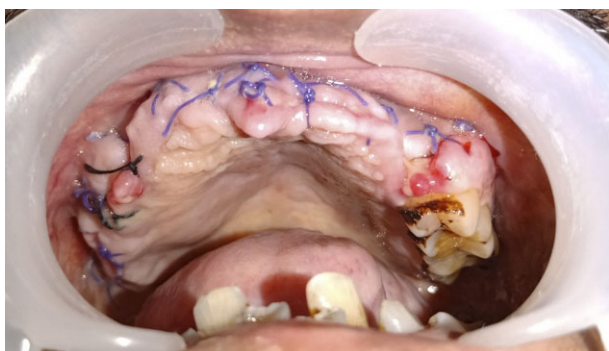

Figure 7. Intraoperative photograph showing primary closure of the defect.

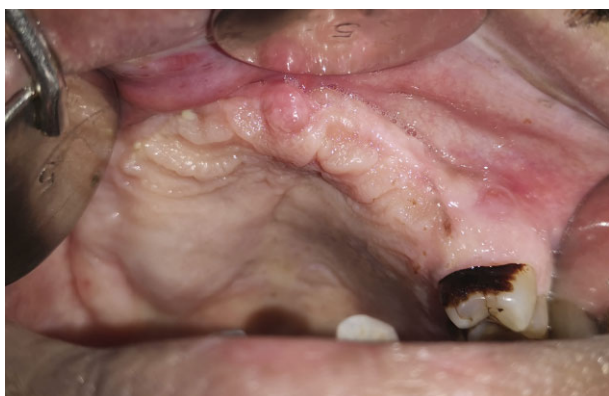

Figure 8. 8 months follow-up photograph showing good healing.

stabilizing medical condition, surgical intervention, and post-operative care. Every attempt should be made to confirm the presence of fungal infection before initiation of antifungal therapy, but therapy should not be delayed. Anti-fungal therapy should be immediately initiated if the patient is clinically suspected of CAFOJS, and KOH wet mount is positive for fungal elements. First line antifungal of choice is liposomal amphotericin B. Due to aggressive clinical presentation, aggressive

treatment was initiated which involves two to three doses of pre-operative intra venous amphotericin B 50 mg and two to eight doses post-surgical debridement depending on the severity/extension/residual lesion. In our experience, pre-operative AMB administration helped in achieving local and systemic control over the infection, in turn reducing the post-operative AMB requirement and, reduced hospital stays. Unlike our previous protocol,² we have increased the total number of doses administered in our study patients due to the aggressive clinical presentation of the disease. Thorough surgical debridement till inducing fresh bleeding from the bone margins, facilitated more local availability of anti-fungal administered. Our protocol for antifungal therapy includes intra venous liposomal AMB 50 mg diluted in 500 ml normal saline as a single dose infused over 6 hours, repeated on alternative days.² Due to the high nephrotoxicity and probable cause of hypokalemia with amphotericin B, it is mandatory to perform serum urea, serum creatinine and serum electrolytes at regular intervals during antifungal therapy, we performed the same investigations at every third day. Careful monitoring of urine output is also recommended. None of our study patients experienced any of these adverse reactions of amphotericin B administration.² Every attempt should be made to use liposomal amphotericin over conventional one with severe nephrotoxicity.^{2,14} Use of conventional amphotericin should be restricted to settings in which there is no other alternative available. Doses can be increased in cases of orbital or cerebral extension and incomplete surgical debridement, 5–10 mg per kilogram body weight for 14–21 days.¹⁴ Isavuconazole and Posaconazole with moderate strength can be considered for first line treatment as an alternative if liposomal amphotericin is unavailable.¹⁴

ECMM guidelines for liposomal AMB therapy in management of fungal osteomyelitis recommend administration of 3–5 mg/kg/day.¹⁴ Our protocol could not strictly adhere to the ECMM guidelines in view of the following factors:

- The high cost of the drug
- Poor socioeconomic status of all the patients who reported to us
- Limited availability of the drug and
- The rampant increase in the number of reporting patients with CAFOJS

The above-mentioned factors added to the burden of administration of liposomal AMB in accordance with the guidelines. All our patients were from poor socioeconomic status which is prevalent in this part of the country. Liposomal AMB was made available by the government at subsidized rates. This was restricted only to designated government hospitals. Due to the high volume of cases, not all patients could access this care and sought treatment at private hospitals where these subsidies were unavailable. The pandemic also brought about a storm of patients suffering from mucormycosis secondary to COVID 19. The rampant increase in numbers, the lack availability of the medicine

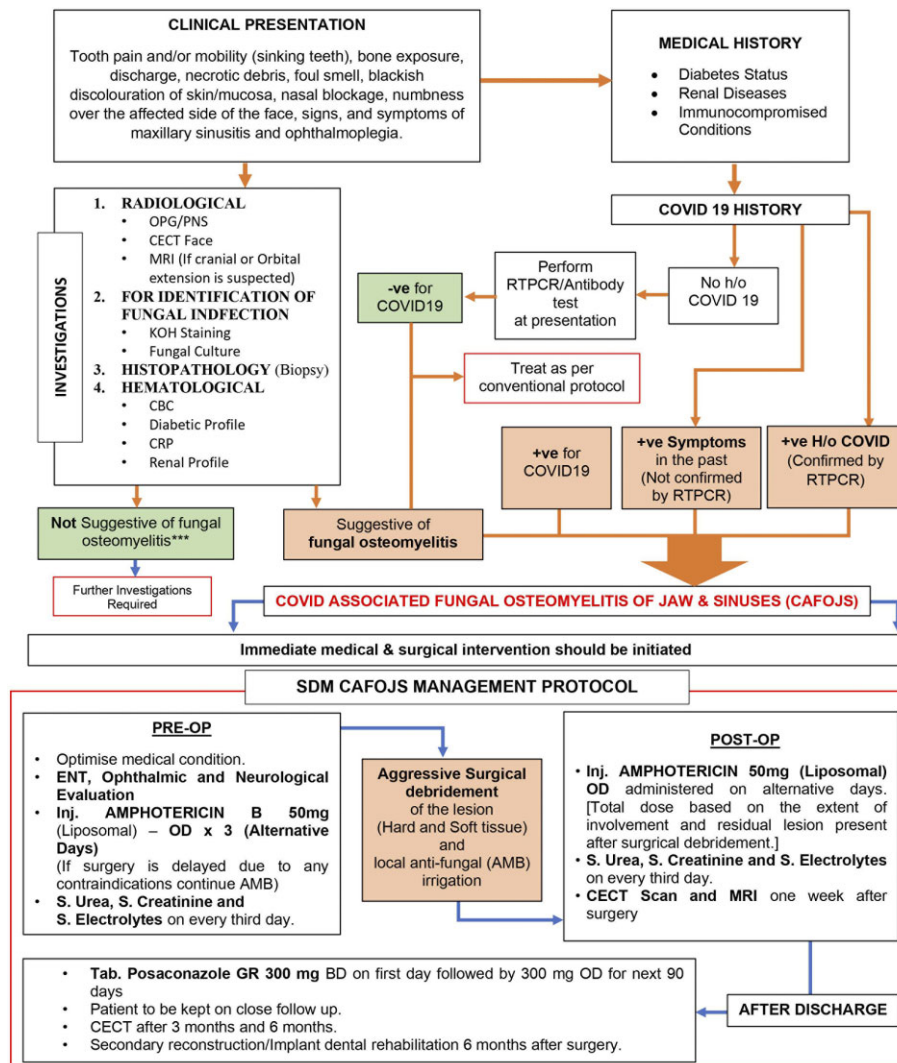


Figure 9. SDM protocol for management of CAFOJS.

and the high cost of the drug were some of the primary deterrents in providing the dosage of liposomal AMB as per guidelines. The drug had to be rationed to accommodate all our patients. It was difficult to adhere to the recommended dose not only because of limited availability but also due to the prevalence of the disease during the pandemic due to the delta variant. In view of all these factors we found it prudent to rely on our previous experience with mucormycosis.² This regime combined with the protocol of aggressive surgical debridement and long-term tab. Posaconazole administration after discharge was a reliable option for managing this unexpected and enormous burden of mucormycosis during the COVID-19 pandemic in our experience.

Surgical debridement of the lesion should be performed, necrotic bone (Figure 2a) to be debrided until fresh bleeding is observed from the margins of residual bone, indicative of healthy bone (Figure 2b). In our study patients, we observed a cleavage between the infected and healthy bone in our study patients which helped us in delineating the necrotic and healthy bone easily. Intraoperative AMB or Gentamycin local irrigation was

performed. Primary closure of the soft tissue defect (Figure 7) was done in all our patients, followed by placement of an obturator prosthesis. Secondary soft tissue or bony reconstruction planned to be performed after 6 months if there is no recurrence. Dental rehabilitation can be done either by conventional dental implants in availability of adequate bone, using zygomatic implants or patient specific implants in cases of hemi or complete maxillectomy.¹⁵ Lesions with cerebral or orbital extension is preferably to be treated by a multidisciplinary team consisting of ENT, ophthalmology, neurosurgeon, and maxillofacial surgeon.

Post-operatively patient must be put on long term anti-fungal therapy, for 90 days preferably Posaconazole oral suspension 4 × 200 mg on day 1 followed by 400 mg/day or delayed release tablets 2 × 300 mg on day 1 followed by 300 mg/day for rest of the days.¹⁴ Patient's diabetic status should be under control post-operatively. Patient should be kept on strict close follow ups and evaluated for any signs of recurrence. All patients reported back with good healing (Figure 8) and none of our patients had any recurrence after a follow up of 3 to 6 months. Itraconazole 100 bd

for 90 days tablets were given initially in 10 CAFOJS patients, which has also shown good outcome in our experience.

CAFOJS is a serious threat in COVID-19 recovered patients and is an aggressive disease as compared to conventional fungal osteomyelitis on our clinical observations. Hyperglycemia at presentation is observed to be the foremost predisposing factor in occurrence of CAFOJS in our experience. Use of steroids during the treatment of COVID-19 infection is highly attributable to the incidence of invasive fungal infections but needs further research to confirm the association. Early diagnosis and treatment is warranted in suspicion of CAFOJS. Our experience driven protocol for management of CAFOJS is summarized in Figure 9.

Acknowledgements

Authors would like to thank the contributions of the following:

- Faculty, residents and the entire team at SDM Craniofacial Surgery and Research Centre towards management of patients with CAFOJS.
- Faculty at department of General Pathology, SDM College of Medical Sciences and Hospital and department & Oral Pathology, SDM college of Dental Sciences and Hospital.
- The Principal Dr Balram Naik and the management for their support.

Author contributions

Amal Suresh: Design, conduct, analysis, and presentation of the research. Abhijit Joshi: Design, analysis, and presentation of the research. Anil Kumar Desai: Design and analysis presentation of the research. Uday Juturu: Conduct of the research. Denis Jacob Kurian: Conduct of the research. Pavithra Jain: Analysis of the research. R. D. Kulkarni: Design and analysis of the research. Niranjana Kumar: Analysis of the research.

Declaration of interest

The authors report no conflicts of interest. The authors alone are responsible for the content and the writing of the paper.

References

1. Farmakiotis D, Kontoyiannis DP. Mucormycoses. *Infect Dis Clinics*. 2016; 30: 143–163.
2. Anehosur V, Agrawal SM, Joshi VK, Anand J, Krishnamuthy K, Kumar N. Incidence and treatment protocol for maxillofacial fungal osteomyelitis: a 12-year study. *J Oral Maxillofacial Surg*. 2019; 77: 2285–2291.
3. Prakash H, Chakrabarti A. Global epidemiology of mucormycosis. *J Fungi*. 2019; 5: 26.
4. Butala A, Shah B, Cho YT, Schmidt MF. Isolated pulmonary mucormycosis in a normal host: a case report. *J Natl Med Assoc*. 1995; 87: 572.
5. Gangneux JP, Bougnoux ME, Dannaoui E, Cornet M, Zahar JR. Invasive fungal diseases during COVID-19: we should be prepared. *J de Mycol Medicale*. 2020; 30: 100971.
6. Verma DK, Bali RK. COVID-19 and Mucormycosis of the Craniofacial skeleton: Causal, Contributory or Coincidental?
7. John TM, Jacob CN, Kontoyiannis DP. When uncontrolled diabetes mellitus and severe COVID-19 converge: the perfect storm for mucormycosis. *J Fungi*. 2021; 7: 298.
8. Rai A, Abraham L, Naikmasur VG, Kulkarni RD, Padmini S. A rare case of maxillary osteomyelitis caused by *Curvularia* species. *J Oral Maxillofac Surg Med Pathol*. 2014; 26: 545–548.
9. Yang JK, Lin SS, Ji XJ, Guo LM. Binding of SARS coronavirus to its receptor damages islets and causes acute diabetes. *Acta Diabetologica*. 2010; 47: 193–199.
10. Ceriello A. Hyperglycemia and COVID-19: what was known and what is really new?. *Diabetes Res Clinical Practice*. 108383, 2020; 167.
11. Garg D, Muthu V, Sehgal IS et al. Coronavirus disease (Covid-19) associated mucormycosis (CAM): case report and systematic review of literature. *Mycopathologia*. 2021 Feb 5: 1–10.
12. Skiada A, Pavleas I, Drogari-Apiranthitou M. Epidemiology and diagnosis of mucormycosis: an update. *J Fungi*. 2020; 6: 265.
13. Ibrahim AS, Spellberg B, Walsh TJ, Kontoyiannis DP. Pathogenesis of mucormycosis. *Clin Infectious Dis*. 2012; 54: S16–S22.
14. Cornely OA, Alastruey-Izquierdo A, Arenz D et al. Global guideline for the diagnosis and management of mucormycosis: an initiative of the European Confederation of Medical Mycology in cooperation with the Mycoses Study Group Education and Research Consortium. *Lancet Infectious Dis*. 2019; 19: e405–e421.
15. Lacroix T, Jaby P, Nokovitch L, Chaux-Bodard AG. Prosthetic rehabilitation with zygomatic implants after maxillectomy: a systematic review. *J Dent Oral Disord*. 2020; 6: 1132.