

Airway management with a rigid external distractor in place

Sir,

External distraction using a rigid external distractor (RED) frame (RED frame II, KLS-Martin, Jacksonville, USA) is frequently used for maxillary distraction and reconstruction.^[1-3] Airway management with the RED frame could be a greater risk of failed intubation/extubation. It could significantly interfere with ventilation with a face mask or intubation by direct laryngoscopy. However, anaesthetic management of patients with the RED frame has not been reported sufficiently.^[2-4] We describe airway management using gum elastic bougie (GEB) for extubation and a small rounded facemask for induction of anaesthesia in two patients.

The first patient was a 19-year-old boy, 164 cm in height and 52 kg in weight and the second, a 15-year-old girl, 155 cm in height and 48 kg in weight. They were diagnosed with a bilateral lip, alveolus and palatal cleft. They underwent bilateral lip closure and palatoplasty. In addition, a bone graft to their cleft palate was performed. They were diagnosed with maxillary hypoplasia as a result of the cleft. A maxillary distraction osteogenesis using the RED frame was scheduled for the reconstruction of severe maxillary hypoplasia under general anaesthesia.

Anaesthesia was induced with intravenous midazolam, atropine and fentanyl. Rocuronium was also given intravenously to facilitate tracheal intubation. We could smoothly intubate using Miller laryngoscope with nasotracheal tube. The Cormack–Lehane grade laryngoscopy grade was II. After the surgery for RED frame placement was completed [Figure 1] and patients emerged from anaesthesia, we tried to use an 11 Fr GEB (Cook Critical Care, Bloomington, USA). After inserting the GEB into the tube, the trachea was extubated. When we observed adequate spontaneous respiration, we removed the GEB. After extubation, their conditions were stable. Then, they had been in hospital with the RED frame device for a month.

One month later, they underwent removal of the RED frame. A small-size rounded facemask that could adequately cover their nose below the horizontal bar of the RED frame was selected for pre-oxygenation [Figure 2]. Anaesthesia was induced

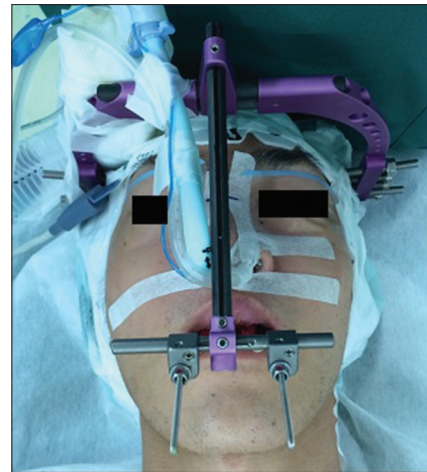

Figure 1: Rigid external distractor frame in situ small round mask for preoxygenation. A RED frame on a patient

with midazolam, atropine and fentanyl in oxygen without neuromuscular blockade. The nasotracheal tube was inserted into the trachea with a fibrescope after topical anaesthesia (lidocaine 30 mg) was sprayed through the working channel at 3 places (pharynx, vocal cord and trachea). After confirming proper awake intubation, propofol and rocuronium were administered. The procedure was completed uneventfully. They were extubated after confirming sufficient spontaneous respiration. After extubation, their respiratory and haemodynamic conditions were stable.

Distraction osteogenesis describes the lengthening of bone and soft tissue by the gradual movement for an osteotomy.^[4] The RED frame is mainly used as an external distractor [Figure 2]. The distraction device is usually removed in the clinical setting without general anaesthesia. However, in these cases, general anaesthesia was scheduled for younger patients to avoid pain and stress. In addition, removing the RED frame without general anaesthesia may increase the risk of malunion of the unsupported segments, as residual contractile force remains in tissues.^[4]

Airway management using GEB for extubation and a small-size rounded facemask for induction of anaesthesia was performed due to restricted access to the oronasal airway.^[3] The GEB is one of the recommended components of extubation.^[5] It is often used as a guide to exchange the tracheal tube. When reintubation is needed, a tracheal tube could be inserted over the GEB.

At the second surgery, to ventilate efficiently using a standard facemask at the induction of anaesthesia, it

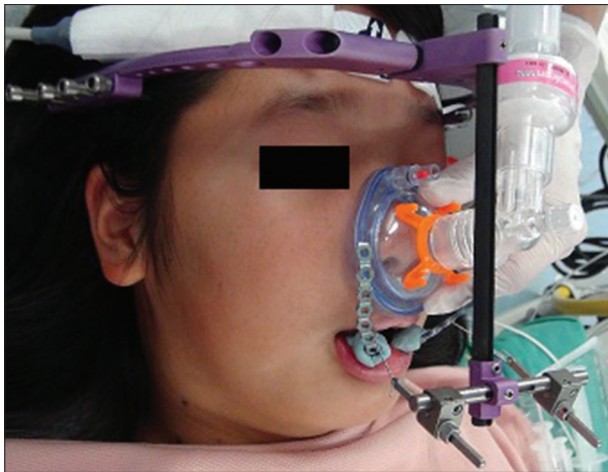


Figure 2: Rigid external distractor frame *in situ* small round mask for preoxygenation

was necessary to create a seal over both the nose and mouth. However, because of restricted access to the oronasal airway, a small-size and rounded facemask that could adequately cover their nose was useful for ventilation. In addition, different sized masks, tracheal tubes, nasal and/or oral airways, stylet, laryngeal masks, fibroscope and tracheostomy set should be kept available.

Fibreoptic intubation maintaining spontaneous breathing is an effective intubation technique for establishing airway access in patients with anticipated difficult airways such as patients with a RED frame.^[2,6] In these cases, the nasal route may precipitate bleeding and have restricted oral space, leading to failed intubation. Although various techniques using fibroscope were reported, topical anaesthesia with lignocaine into pharynx was very simple and effective for fibreoptic intubation with spontaneous breathing. In addition, when the vocal cords were visualized, lignocaine (total 30 mg) was sprayed 3 times over the pharynx, vocal cord and trachea through the working channel with fibroscope.

Declaration of patient consent

The authors certify that they have obtained all appropriate patient consent forms. In the form the patient(s) has/have given his/her/their consent for his/her/their images and other clinical information to be reported in the journal. The patients understand that their names and initials will not be published and due efforts will be made to conceal their identity, but anonymity cannot be guaranteed.

Financial support and sponsorship

Nil.

Conflicts of interest

There are no conflicts of interest.

**Masanori Tsukamoto, Jun Hitokawa¹,
Takeshi Yokoyama¹**

Department of Dental Anesthesiology, Kyushu University Hospital,
¹Department of Dental Anesthesiology, Faculty of Dental Science,
Kyushu University, Fukuoka, Japan

Address for correspondence:

Dr. Masanori Tsukamoto,
Department of Dental Anesthesiology, Kyushu University
Hospital, 3-1-1 Maidashi, Higashi-ku, Fukuoka 812-8582, Japan.
E-mail: tsukamoto@dent.kyushu-u.ac.jp

REFERENCES

1. Frawley G, Espenell A, Howe P, Shand J, Heggie A. Anesthetic implications of infants with mandibular hypoplasia treated with mandibular distraction osteogenesis. *Paediatr Anaesth* 2013;23:342-8.
2. Roche J, Frawley G, Heggie A. Difficult tracheal intubation induced by maxillary distraction devices in craniosynostosis syndromes. *Paediatr Anaesth* 2002;12:227-34.
3. Tong J, Ahmed-Nusrath A, Smith J. External maxillary distraction: An alternative to awake fibreoptic intubation. *Br J Anaesth* 2007;99:301.
4. Xue FS, Liao X, Liu JH, Yuan YJ, Wang Q. Airway management in pediatric patients with a rigid external distractor *in situ*. *Paediatr Anaesth* 2011;21:699-700.
5. Matsunami S, Komasa N, Majima N, Ueno T, Minami T. Evaluation of gum-elastic bougie with direct and indirect laryngoscope for infant difficult airway management: A Pierre Robin simulation model. *J Clin Anesth* 2016;30:59-60.
6. Collins SR, Blank RS. Fiberoptic intubation: An overview and update. *Respir Care* 2014;59:865-78.

This is an open access article distributed under the terms of the Creative Commons Attribution-NonCommercial-ShareAlike 3.0 License, which allows others to remix, tweak, and build upon the work non-commercially, as long as the author is credited and the new creations are licensed under the identical terms.

Access this article online	
Quick response code	Website: www.ijaweb.org
	DOI: 10.4103/ija.IJA_268_17

How to cite this article: Tsukamoto M, Hitokawa J, Yokoyama T. Airway management with a rigid external distractor in place. *Indian J Anaesth* 2017;61:679-80.

© 2017 Indian Journal of Anaesthesia | Published by Wolters Kluwer - Medknow