

BRIEF COMMUNICATION

Pallidal deep brain stimulation and intraoperative neurophysiology for treatment of poststroke hemiballism

Adolfo Ramirez-Zamora¹, Robert S. Eisinger¹, Sameah A. Haider², Youngwon Youn³, Damian Shin⁴, Eric S. Molho⁵ & Julie G. Pilitsis^{3,4}

¹Department of Neurology, Center for Movement Disorders and Neurorestoration, Fixel Center for neurological disorders at the University of Florida, Gainesville, Florida

²Department of Neurosurgery, Henry Ford Hospital, Detroit, Michigan

³Department of Neurosurgery, Albany Medical Center, Albany, New York

⁴Department of Neuroscience and Experimental Therapeutics, Albany Medical College, Albany, New York

⁵Department of Neurology, Albany Medical Center, Albany, New York

Correspondence

Adolfo Ramirez-Zamora, Center for Movement Disorders and Neurorestoration, University of Florida, 3450 Hull Road, 4th Floor, Gainesville, FL 32607. Tel: (352) 294-5400; Fax: (352) 273-5450; E-mail: adolfo.ramirez-zamora@neurology.ufl.edu

Funding Information

No funding information provided.

Received: 7 March 2018; Revised: 10 April 2018; Accepted: 13 April 2018

Annals of Clinical and Translational Neurology 2018; 5(7): 865–869

doi: 10.1002/acn3.573

Abstract

Deep brain stimulation is a recognized and effective treatment for several movement disorders. Nevertheless, the efficacy of this intervention on abnormal movements secondary to structural brain pathologies is less consistent. In this report, we describe a case of hemiballism–hemichorea due to a peripartum ischemic stroke-treated with deep brain stimulation of the globus pallidus internus. Patient observed marked improvement in her symptoms at long-term follow-up. Neurophysiologic data revealed lower globus pallidus internus firing rates compared to other hyperkinetic disorders. Pallidal deep brain stimulation is a plausible option for medically refractory hemiballism–hemichorea and cumulative data from multiple centers may be used to fully evaluate its efficacy.

Introduction

Deep brain stimulation (DBS) is an established therapy for treating a variety of medication-refractory movement disorders including Parkinson disease (PD), dystonia, and essential tremor (Perlmutter & Mink, 2006).¹⁷ However, the therapeutic effect of DBS on abnormal movements secondary to structural brain pathologies have demonstrated less consistent or even disappointing results.^{1–3} New-onset movement disorders occurring after a primary stroke or as a complication of neurosurgery are rare, but dystonia, hemichorea (HC), and hemiballismus (HB) have been reported after vascular events affecting the striatum, putamen, thalamus, or subthalamic nucleus (STN).⁴ Patients with chorea exhibit involuntary, continual, and irregular movements that flow randomly from one body part to another, whereas ballism is a form of high-amplitude flinging resulting from chorea involving proximal limb muscles.

Abnormal movements following a stroke can occur immediately or can be delayed and progressive. HC-HB arising after stroke may improve with medical therapy but in certain circumstances, neurosurgical intervention may be appropriate particularly for refractory symptoms. Despite the well-established benefit of pallidal DBS for primary dystonia, poststroke dystonia has remained particularly difficult to treat with DBS.⁵ On the other hand, a limited number of case reports suggest the potential for DBS as a treatment for poststroke HC-HB. To the best of our knowledge, however, of these four published cases of pallidal DBS for HC-HB secondary to stroke, long-term clinical data is lacking.^{6–9}

In this report, we describe a novel case of HC-HB that developed secondary to a peripartum ischemic stroke. The patient was successfully treated with DBS of the globus pallidus internus (GPi). We provide details of intraoperative neurophysiology and report on clinical outcomes at 28 months' follow-up. Given the novelty of

this specific application of DBS, we present a brief review of established pallidal microelectrode neurophysiology and compare it to the intraoperative GPi firing rates observed in this case.

Patients and Methods

Patient is a 53-year-old woman presenting with insidious onset, progressive, left arm abnormal involuntary movements starting in her 30s after she suffered peripartum

right thalamic cerebral infarction (Fig. 1). New motor symptoms appeared approximately 6 months poststroke after resolution of left hemi-body numbness and weakness. Her symptoms progressed over the following years leading to severe, unremitting, large amplitude, irregular, random movements in her left arm causing marked functional impairments consistent with HB. She had no meaningful use of her left arm. There was no involvement of ipsilateral leg or face and a variety of medications failed to provide benefit including dopamine receptor

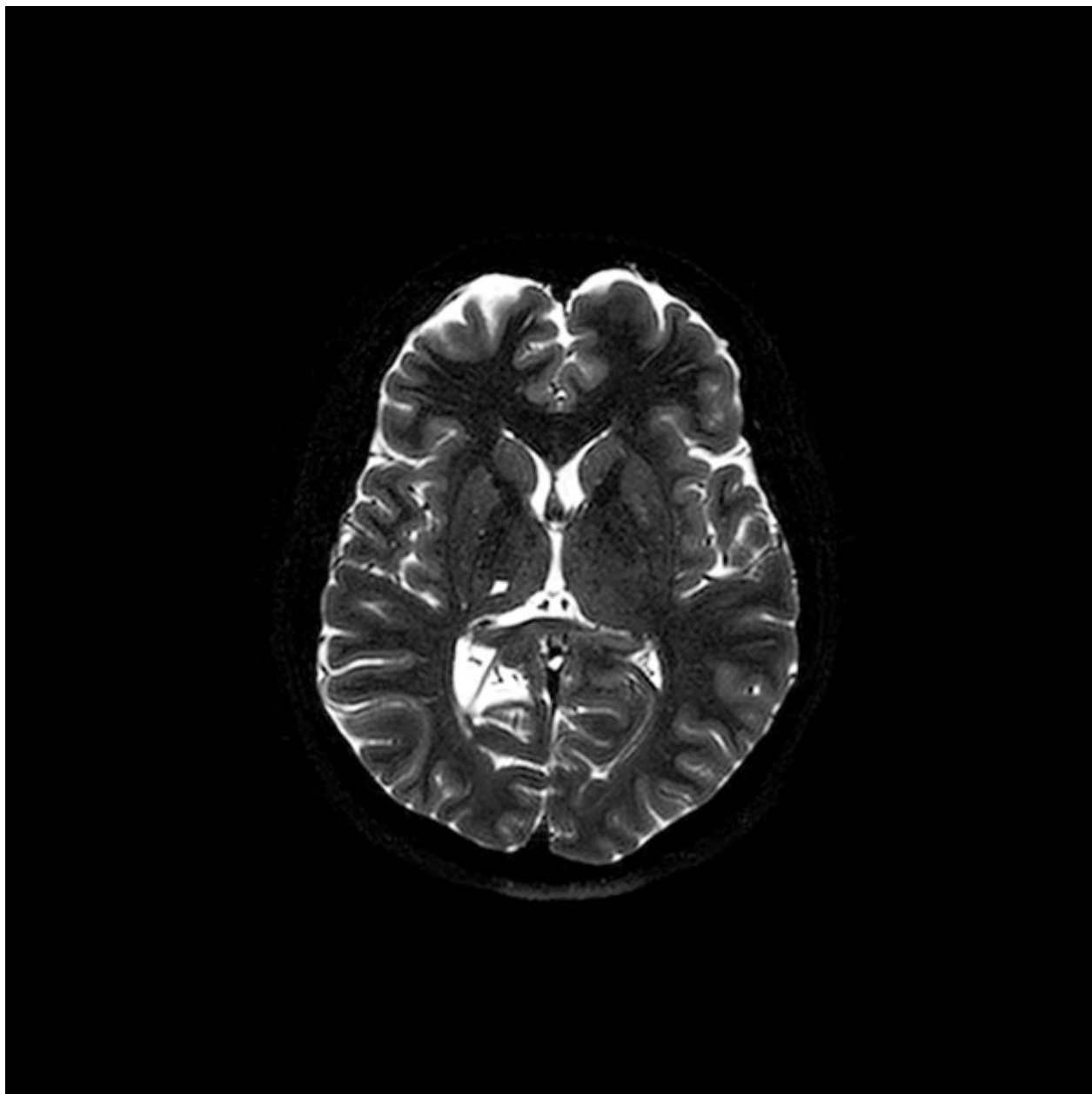


Figure 1. Magnetic resonance image, T2-weighted sequence showing right thalamic lacunar cerebral infarction.

blocking agents, levodopa, bntropine, trihexiphenidyl, valproic acid, benzodiazepines, and tetrabenazine. Because of the severe disability related to her symptoms, she had placement of unilateral right Gpi DBS. The patient was not taking any neurological or psychiatric medications during surgery and an awake procedure was conducted to facilitate microelectrode recordings. Motor improvement was gradual after monthly programming sessions over the first 6 months. At last follow-up at 28 months postoperative, she displayed marked improvement in her symptoms with almost complete resolution of HB (Video S1). Therapeutic stimulation parameters were as follows: Case positive, contact 0 negative, amplitude of 3.0 V, pulse width of 90 μ sec, and frequency of 130 Hz. Reversible side effects were encountered at higher levels of stimulation, namely dysarthria and tonic arm contractions.

Neurophysiology

Single-unit activity recordings were obtained from this patient using microelectrodes during surgery in the Gpi and globus pallidus externus (GPe) based on characteristic firing patterns. A total of 22 and seven cells were recorded from the Gpi and GPe, respectively. The mean Gpi and GPe firing rates for our HC-HB patient (shown as mean \pm SEM) were 16.00 \pm 3.18 and 32.00 \pm 10.60 Hz, respectively. For comparison, Table 1 provides an overview of prior work characterizing firing rates of Gpi and GPe neurons in patients with PD, dystonia, Huntington's disease (HD), and HB.

Discussion

This is the first description of medication-refractory HC-HB secondary to thalamic peripartum stroke treated with Gpi DBS. In addition to this case, a limited number of reports have demonstrated the feasibility of pallidal DBS for poststroke HC-HB. Hasegawa et al.⁹ were the first to report a case of a primary hemorrhagic subthalamic stroke-induced HB treated with Gpi DBS. The patient experienced rapid symptomatic improvement that persisted at 15-months' follow-up. Capelle et al.⁷ described the case of a patient developing HC-HB after resection of a craniopharyngioma that was subsequently treated with combined Gpi and thalamic DBS. They found that stimulation to either target suppressed HC-HB movements, but that therapeutic thalamic stimulation required less voltage. Both Oyama et al.⁶ and Pabaney et al.⁸ have reported patients requiring further treatment for medication-refractory HC-HB developed as a complication of STN DBS for PD. In both cases, high-frequency Gpi stimulation proved clinically efficacious for HC-HB.

Table 1. Review of pallidal neurophysiology.

Diagnosis	Number of patients	Number of units	Firing rate	Reference
			mean \pm SE (Hz)	
Globus pallidus internus (Gpi)				
PD	10	101	95.2 \pm 2.3	Starr et al. ¹⁵
	1	14	46.1 \pm 7.8	Oyama et al. ⁶
	14	188	89.9 \pm 3.0	Tang et al. ¹⁴
	6	200	74 \pm 1.2	Hutchison et al. ¹⁶
	4	13	96 \pm 8	Suarez et al. ¹²
Dys	22	302	55.3 \pm 1.3	Starr et al. ¹⁵
	3	26	50 \pm 4.0	Vitek et al. ¹³
HD	2	39	81.8 \pm 4.3	Tang et al. ¹⁴
	1	17	33.7 \pm 5.1	Vitek et al. ¹³
HB	1	13	30 \pm 5	Suarez et al. ¹²
	1	12	53 \pm N/A	Capelle et al. ⁷
Globus pallidus externus (GPe)				
PD	5	39	55.6 \pm 3.5	Starr et al. ¹⁵
	15	151	54.0 \pm 1.9	Starr et al. ¹⁵
Dys	3	44	37.7 \pm 4.2	Vitek et al. ¹³
	1	15	13.0 \pm 1.8	Vitek et al. ¹³
HC-HB	1	4	41 \pm N/A	Capelle et al. ⁷

Characteristic firing rates reported across multiple studies is shown for both Gpi and GPe neurons. For each row, the following information is provided: diagnosis, number of patients from which cells were recorded, the number of units or cells recorded, the firing rate presented as mean plus or minus the standard error (units of Hertz), as well as the reference. Question marks indicate data that we were unable to find. PD, Parkinson's disease; Dys, dystonia; HD, Huntington's disease; HB, hemiballismus; HC, hemichorea.

Similar to the above reports, in this patient we observed suppression of HC-HB after Gpi DBS therapy. Notably, in this patient, symptomatic improvement remained stable at the last known follow-up of 28 months after DBS. In addition, there were no adverse outcomes associated with DBS therapy in this patient. Given the rarity of these cases and mixed treatment strategies, no two cases in the literature are alike. However, there are now multiple reports suggesting the potential promise of Gpi DBS for HC-HB secondary to certain basal ganglia lesions. Importantly, benefit in our patient was achieved despite a very long latency period from onset of symptoms to surgery of almost three decades.

While both dystonia and HB are recognized complications of cerebrovascular injuries to the basal ganglia, the response to DBS in patients with secondary dystonia is not nearly as consistent, nor robust, as that of patients with primary dystonia.^{2,5} This pattern also persists when examining poststroke dystonia.^{1,5,7} In contrast, the application of Gpi DBS for poststroke HB has been demonstrated successfully across different specific clinical scenarios. The explanation for this observed discrepancy

in response to DBS in poststroke dystonia and HB is not known.

We believe one important feature that distinguishes these two conditions is the extent of damage incurred due to the stroke and therefore the remaining intact striatopallidal network.¹⁰ In a series of 27 patients with HB secondary to a stroke, 77% were found to be due to lacunar strokes.⁴ The average latency period for manifestation of HC-HB is 4 days poststroke.¹¹ While poststroke HB is usually the manifestation of a strategic infarct in the striatum, poststroke dystonia more frequently arises from a larger vascular insult and presents itself months to years after the sentinel event. In fact, poststroke dystonia patients that do respond favorably to GPi DBS tend to have structurally normal MRIs, while those that do not have basal ganglia abnormalities.⁵ Thus, relative preservation of basal ganglia structures may be an important predictor of response to GPi DBS for poststroke HB and dystonia. This is an area that requires further investigation.

Neurophysiology

Additionally, we measured pallidal firing frequencies during intraoperative microelectrode targeting in this patient. A comparison between these values and that of patients with PD, dystonia, HD, and other reports of HC-HB (Table 1) revealed important observations. Specifically, our patient had a GPi mean firing rate of 16.00 ± 3.18 Hz, which is considerably lower than that found in the GPi in other diseases. This is consistent with prior work that has statistically compared groups of GPi cells in patients with HB and PD.¹² One study found similar firing rates in the GPi between patients with HB and dystonia, both of which were lower than GPi firing rates in PD.¹³ In contrast to our results and those of others, Tang et al.¹⁴ found similar GPi firing rates in patients with PD and HD displaying levodopa induced dyskinesia and chorea. We found mean GPe firing rates in our patient to be 32.00 ± 10.60 Hz, which were generally higher and not all that different from previously established GPe firing rates in PD and dystonia.^{13,15} Interestingly, in one case report, the mean firing rate of GPe neurons in a patient with HB was found to be 13.0 ± 1.8 , which is lower than other reports. Our values more closely align with a separate HC-HB case report that found a mean GPe firing rate of 41 Hz.⁷

Although more research is needed, overall it appears that GPi firing rates are generally lower in hyperkinetic disorders, whereas GPe firing rates currently show unclear relationships to different movement disorders. However, the data are limited to single case reports and other factors might contribute to changes in firing rates including sparse sampling or the presence of resting tremor in PD patients modulating sensory feedback and increasing

firing rates compared to other conditions. Nevertheless, these observations can be enlightening in the context of the canonical basal ganglia motor loop. It has been previously postulated that hyperkinetic disorders resulting from basal ganglia lesions can occur due to a reduced influence of the indirect pathway on basal ganglia output nuclei. Specifically, low levels of excitatory output from the STN can lead to an underactivated GPi, thereby lessening inhibition on the motor thalamus. Relative to the firing rate of GPi neurons in hypokinetic disorders, the lower firing rates observed in hyperkinetic disorders is therefore in support of this hypothesis.

Conclusion

Given the low incidence of poststroke HB (0.5%, prevalence 1%), it is unclear whether it is a disease phenomenon that more commonly progresses toward remission, persists unchanged, or exacerbates with time.¹¹ Although definitive evidence is lacking, with this account representing the fifth of its kind, the relative safety and reversibility of GPi DBS makes it a valuable proposition for those suffering from the disease. As GPi DBS gains traction as a feasible option for medically refractory HB, aggregate data amassed from multiple DBS centers may be used to fully evaluate its efficacy. For now, we must make use of case reports depicting both treatment success and treatment failures for poststroke HB. Additionally, the reporting of intraoperative microelectrode recording data may further improve patient selection and understanding of this modality's success.

Author Contribution

A.R.Z., E.M., Y.Y., S.H., and J.G.P. contributed to the design of the study; R.E., D.S., Y.Y., S.H., A.R.Z., and J.G.P. contributed to the acquisition and analysis of data; Y.Y., S.H., A.R.Z., and R.E. contributed to drafting the text and preparing the figures. A.R.Z., E.M., R.E., D.S., and J.G.P. reviewed and revised the manuscript for intellectual content.

Conflict of Interest

Dr. Pilitsis is a consultant for Medtronic, Boston Scientific, Abbott, Jazz and receives grant support from General Electric Global Research Center, Medtronic, Boston Scientific, Abbott, Nevro, Jazz Pharmaceuticals and NIH 1R01CA166379. She is medical advisor for Centauri and has stock equity. Dr. Ramirez-Zamora has received consultant honoraria from Teva pharmaceuticals, Bracket, and Medtronic. The institution and not Dr. Ramirez-Zamora receives grant support from Medtronic and

Boston Scientific. Dr. Ramirez-Zamora has participated as a site PI and/or co-I for several NIH and industry-sponsored trials over the years but has not received honoraria. Dr. Eric Molho receives clinical trial grants from NIH/PSG, CHDI/HSG, Civitas Therapeutics, Kyowa Hakko Kirin, MJF/PSG, and Bristol-Myers Squibb/Biogen. He is on the speaker's bureau for Neurocrine Biosciences, Acadia Pharmaceuticals, and is a consultant for Neurocrine Biosciences. Dr. Eisinger, Haider, Youn, and Shin have nothing to disclose.

References

- Smith KM, Spindler MA. Uncommon applications of deep brain stimulation in hyperkinetic movement disorders. *Tremor Other Hyperkinet Mov (N Y)* 2015;5:278.
- Witt J, Starr PA, Ostrem JL. Use of pallidal deep brain stimulation in postinfarct hemidystonia. *Stereotact Funct Neurosurg* 2013;91:243–247.
- Pretto TE, Dalvi A, Kang UJ, Penn RD. A prospective blinded evaluation of deep brain stimulation for the treatment of secondary dystonia and primary torticollis syndromes. *J Neurosurg* 2008;109:405–409.
- Hawley JS, Weiner WJ. Hemiballismus: current concepts and review. *Parkinsonism Relat Disord* 2012;18:125–129.
- Eltahawy HA, Saint-Cyr J, Giladi N, et al. Primary dystonia is more responsive than secondary dystonia to pallidal interventions: outcome after pallidotomy or pallidal deep brain stimulation. *Neurosurgery* 2004;54:613–619; discussion 9–21.
- Oyama G, Maling N, Avila-Thompson A, et al. Rescue GPi-DBS for a stroke-associated hemiballism in a patient with STN-DBS. *Tremor Other Hyperkinet Mov (N Y)* 2014;4:1–5.
- Capelle HH, Kiefe TM, Krauss JK. Deep brain stimulation for treatment of hemichorea-hemiballism after craniopharyngioma resection: long-term follow-up. *J Neurosurg* 2011;115:966–970.
- Pabaney A, Ali R, Lewitt PA, et al. Successful management of hemorrhage-associated hemiballism after subthalamic nucleus deep brain stimulation with pallidal stimulation: a case report. *World Neurosurg* 2015;84:1176.e1–3.
- Hasegawa H, Mundil N, Samuel M, et al. The treatment of persistent vascular hemidystonia-hemiballismus with unilateral GPi deep brain stimulation. *Mov Disord* 2009;24:1697–1698.
- Fuller J, Prescott IA, Moro E, et al. Pallidal deep brain stimulation for a case of hemidystonia secondary to a striatal stroke. *Stereotact Funct Neurosurg* 2013;91:190–197.
- McCullum D, Silvers S, Dawson SB, Barrett KM. Resolution of acute onset hemichorea-hemiballismus after treatment with intravenous tissue plasminogen activator. *Neurohospitalist* 2013;3:131–134.
- Suarez JI, Metman LV, Reich SG, et al. Pallidotomy for hemiballismus: efficacy and characteristics of neuronal activity. *Ann Neurol* 1997;42:807–811.
- Vitek JL, Chockkan V, Zhang JY, et al. Neuronal activity in the basal ganglia in patients with generalized dystonia and hemiballismus. *Ann Neurol* 1999;46:22–35.
- Tang JK, Moro E, Lozano AM, et al. Firing rates of pallidal neurons are similar in Huntington's and Parkinson's disease patients. *Exp Brain Res* 2005;166:230–236.
- Starr PA, Rau GM, Davis V, et al. Spontaneous pallidal neuronal activity in human dystonia: comparison with Parkinson's disease and normal macaque. *J Neurophysiol* 2005;93:3165–3176.
- Hutchison WD, Lang AE, Dostrovsky JO, et al. Pallidal Neuronal Activity: Implications for Models of Dystonia. *Ann. Neurol* 2003;53:480–488.
- Perlmutter JS, Mink JW. Deep Brain Stimulation. *Annu. Rev. Neurosci.* 2006;29:229–57 [https://doi: 10.1146/annurev.neuro.29.051605.11282](https://doi.org/10.1146/annurev.neuro.29.051605.11282)

Supporting Information

Additional supplemental material may be found online in the Supporting Information section at the end of the article:

Video S1. Patient displays severe hemiballism in left upper extremity with several tasks. Prior to DBS, she had left shoulder fusion surgery due to pain with no benefit in abnormal movements. At 1-year follow-up after DBS, she had marked reduction in abnormal movements with marked functional recovery in her left hand with most daily activities. An example of her ability to color after surgery and at 1-year follow-up is shown.