

# Conductor cable externalization in an atrial hemodynamic sensor lead in a patient presenting with inappropriate shocks



Sing-Chien Yap, MD, PhD,\* Mark G. Hoogendijk, MD, PhD,\* Suzanne D.A. Valk, MD,† Sweder W. Van de Poll, MD, PhD,† Peter van der Kemp,† Tamas Szili-Torok, MD, PhD\*

From the \*Department of Cardiology, Erasmus MC, University Medical Center Rotterdam, Rotterdam, The Netherlands, and †Department of Cardiology, Franciscus Gasthuis and Vlietland, Rotterdam, The Netherlands.

## Introduction

Conductor cable externalization (CCE) is usually the result of inside-out abrasion (IOA) and may be associated with electrical malfunction. This distinct mode of insulation damage has been associated with defibrillator leads with symmetric conductor cable lumen distribution,<sup>1-5</sup> although it has also been observed in defibrillator leads with asymmetric cable lumen distribution.<sup>6</sup> We report the first case of CCE in a multilumen atrial hemodynamic sensor lead: the SonRtip atrial lead (MicroPort, Shanghai, China). The lead was extracted with simple traction and our analysis of the extracted lead suggested IOA as the mechanism of lead failure.

## Case report

A 73-year-old woman had a biventricular implantable cardioverter-defibrillator (ICD) implanted in September 2015 for nonischemic dilated cardiomyopathy with a left ventricular ejection fraction of 30%, NYHA class III, and a left bundle branch block (QRS duration 180 ms). An active screw-in fixation single-coil ICD lead (Protego S 65, Biotronik, Berlin, Germany) was implanted in the right ventricle (RV), a fixed screw-in bipolar pacing lead with contractility sensor (SonRtip PS55D, MicroPort) in the right atrium, and a passive fixation bipolar pacing lead (QuickFlex 1258T, St. Jude Medical, St. Paul, MN) in a posterolateral branch of the coronary sinus (Supplemental Figure 1). The leads were connected to a Platinum SonR CRT-D model 1841 generator (MicroPort). During regular follow-up, there was mild attenuation of the atrial signal and mild augmentation of the far-field ventricular signal causing inappropriate mode switches owing to far-field ventricular sensing since May 2016.

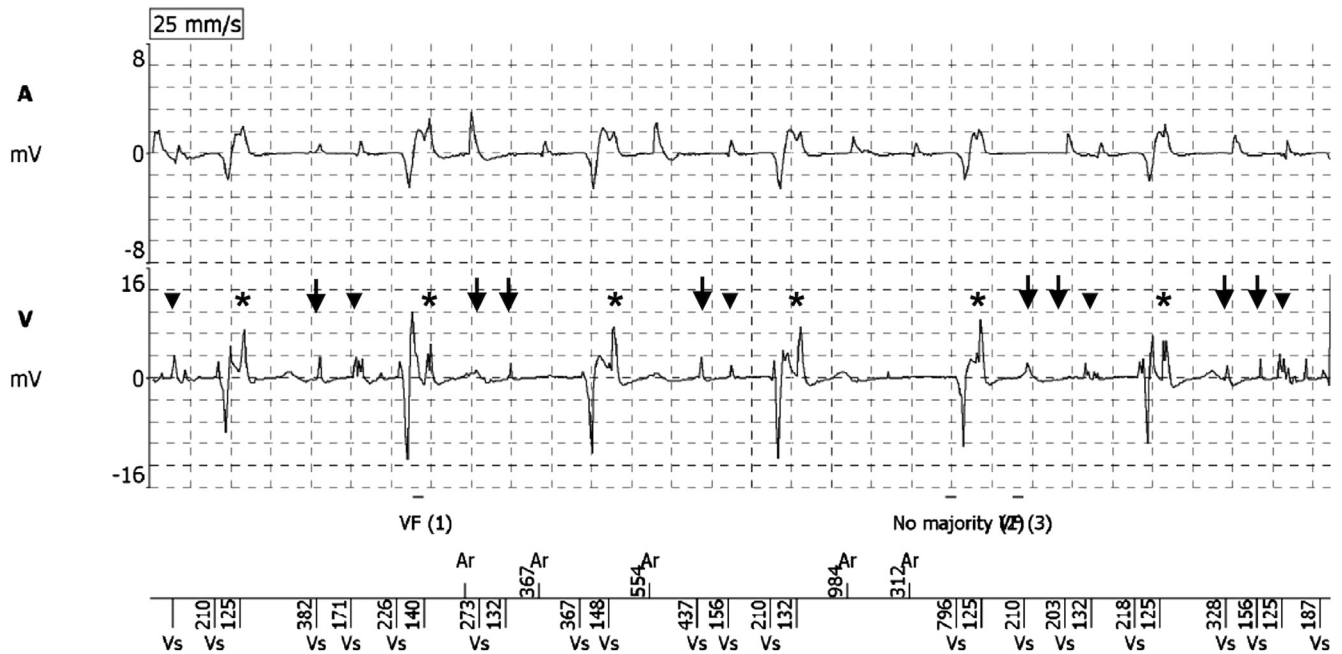
**KEYWORDS** Externalized conductor; Implantable cardioverter-defibrillator; Insulation defect; Lead failure; SonRtip lead (Heart Rhythm Case Reports 2019;5:582-585)

**Address reprint requests and correspondence:** Dr Sing-Chien Yap, Department of Cardiology, Erasmus MC, University Medical Center Rotterdam, Dr. Molewaterplein 40, 3015 GD, Rotterdam, The Netherlands. E-mail address: [s.c.yap@erasmusmc.nl](mailto:s.c.yap@erasmusmc.nl).

## KEY TEACHING POINTS

- Conductor cable externalization (CCE) of the multilumen SonRtip (MicroPort, Shanghai, China) atrial lead can occur despite normal electrical parameters during routine surveillance.
- Inside-out abrasion (IOA) is the most likely explanation for CCE, and in general multilumen leads are more prone to IOA.
- Excessive slack of the SonRtip atrial lead is probably a risk factor for IOA/CCE.

All her electrical parameters were in the normal range until she presented with an ICD storm in May 2019. She experienced 5 inappropriate ICD shocks before arrival at the emergency room. Upon arrival at the emergency room she lost consciousness after an inappropriate ICD shock initiated ventricular fibrillation (VF) and additional ICD shocks failed to terminate VF. Finally, external defibrillation terminated VF. The patient experienced 19 ICD shocks in total. Her post-shock electrocardiogram demonstrated RV pacing only, hence loss of biventricular pacing. When the device was interrogated, both the atrial and ventricular channel showed discrete nonphysiologic noise (Figure 1). Discrete noise on the atrial channel was usually blanked out and not detected. Discrete noise on the ventricular channel was either perisystolic (just after ventricular electric activation or just before atrial electric activation) or at random. After the ICD storm, the measured impedances of the atrial lead, RV pacing lead, left ventricle (LV) pacing lead, and RV coil were 240  $\Omega$ , 2913  $\Omega$ , >3000  $\Omega$ , and >3000  $\Omega$ , respectively. The LV pacing configuration was LV tip to RV coil. The lead trends demonstrated a progressive decrease in RV sensing amplitude and a sudden increase in both the LV lead impedance and high voltage impedance in the period preceding the ICD storm

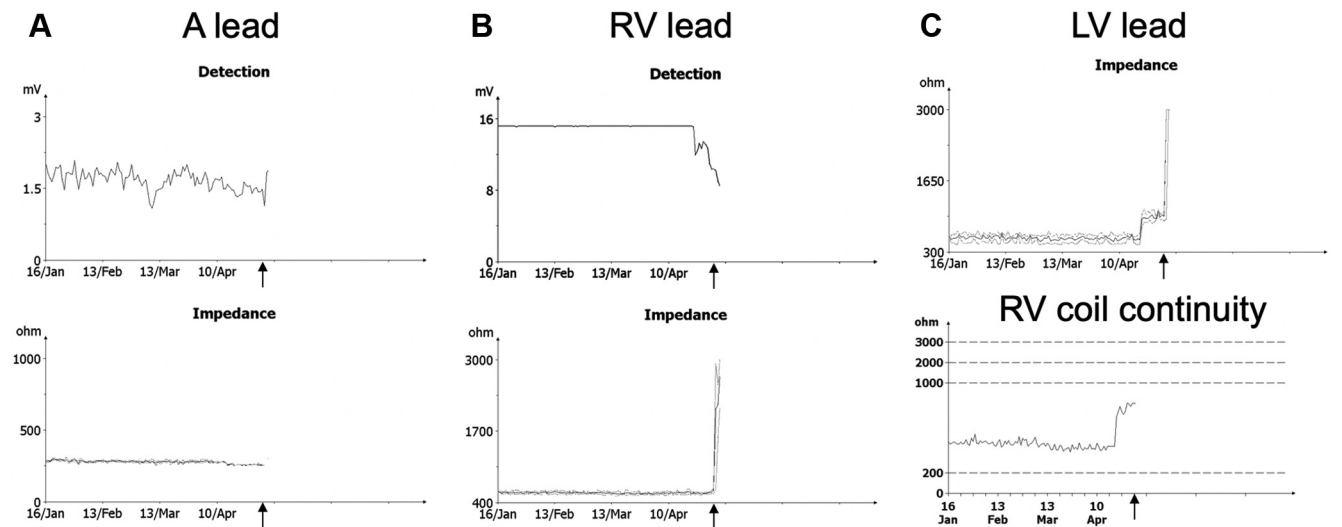


**Figure 1** Electrogram just before the first inappropriate implantable cardioverter-defibrillator shock. Both the atrial (A) and right ventricular (V) channel showed discrete nonphysiologic noise. Discrete noise on the atrial channel was usually blanked out. Discrete noise on the ventricular channel was either perisystolic (just after ventricular electric activation [asterisks]) or just before atrial electric activation [arrowheads] or at random (arrows). Note that the noise is low in amplitude.

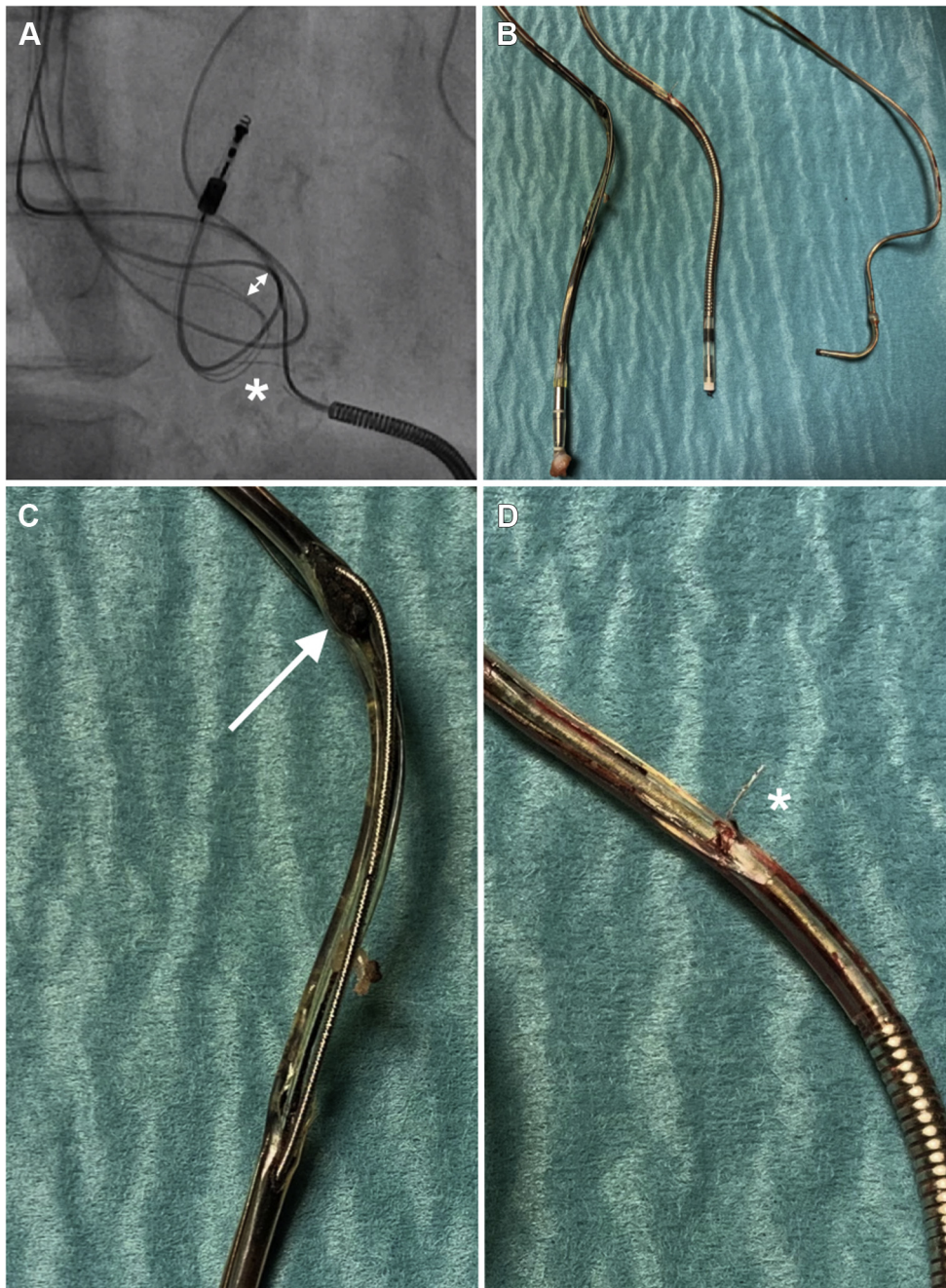
(Figure 2). Furthermore, there was a slight decrease in the atrial lead impedance preceding the abovementioned changes. On fluoroscopy, a fracture and protruding coil conductor cable was seen just proximal to the RV coil. Furthermore, externalization of conductors of the atrial lead was noted (Figure 3A). All leads demonstrated excessive slack.

The patient was transferred for a full system extraction, which was performed 12 days after her ICD storm. All leads were extracted with simple manual traction without specific

extraction tools (Figure 3B). Inspection of the extracted SonRtip atrial lead showed externalization of the pace coil over a distance of approximately 4.5 cm (Figure 3C). There was accumulation of biologic debris at the proximal site of the insulation breach. Inspection of the extracted Protego S lead demonstrated a conductor cable protruding through a breach in the silicone jacket insulation 1.5 cm proximal to the shock coil (Figure 3D). The insulation breach of the Protego S lead had smooth edges. As the patient had developed



**Figure 2** Lead trends. **A:** Upper panel: atrial lead sensing amplitude; lower panel: atrial lead impedance trend. **B:** Upper panel: right ventricle (RV) lead sensing amplitude; lower panel: RV lead impedance trend. **C:** Upper panel: left ventricle (LV) lead impedance; lower panel: RV coil continuity. The period preceding the implantable cardioverter-defibrillator storm (arrow) was characterized by a progressive decrease in RV sense amplitude (suggesting insulation failure), a sudden increase in LV lead impedance (configured as LV tip to RV coil), and high voltage impedance. Note that the impedance of the atrial lead showed a slight decrease since mid-April.



**Figure 3** Failed SonRtip (MicroPort, Shanghai, China) atrial lead and Protego (Biotronik, Berlin, Germany) defibrillator lead before and after extraction. **A:** Pre-extraction fluoroscopy demonstrating conductor cable externalization of the SonRtip lead (*double arrowheads*) and fracture and protrusion of the shock coil conductor (*asterisk*). **B:** Overview of the 3 extracted leads with, from left to right, SonRtip lead, Protego S lead, and QuickFlex (St. Jude Medical, St. Paul, MN) 1258T left ventricular lead. **C:** Detailed view of the SonRtip lead. Old, dark blood was seen in the lead body distant from the insulation breach. Note that the tip conductor coil is protruding out of the silicone body with accumulation of biologic debris and altered blood underneath the coil (*arrow*). There is a large insulation breach over a distance of approximately 4.5 cm. Additional cables remain within their lumens. **D:** Detailed view of the Protego S lead. Discrete breach in the silicone insulation proximal to the shock coil with protrusion of part of the shock coil conductor cable (*asterisk*).

*Staphylococcus aureus* bacteremia prior to extraction, the removed leads were sent for culture and were not returned to the manufacturer for analysis.

## Discussion

We present a case of CCE of the SonRtip lead. Based on our observations, the mechanism of CCE is suspected to be

secondary to IOA. Our hypothesis is that the externalized conductor of the atrial lead may have caused outside-in abrasion of the Protego S lead owing to mutual lead friction. Direct physical contact between the exposed conductor elements resulted in simultaneous contact potentials on the atrial and ventricular channel (Figure 1). The high-voltage circuit failure led to electrical open circuit with failure to defibrillate and loss of LV capture (with an LV pacing configuration set

to LV tip to RV coil). Interestingly, the insulation defect of the SonRtip lead was not associated with a significant change in electrical parameters before the ICD storm. During routine follow-up there was only mild attenuation of the atrial signal and mild augmentation of the ventricular far-field signal causing inappropriate mode switch episodes. The breach in the insulation jacket of the SonRtip atrial lead was large, with ragged edges. The build-up of biological debris underneath the pace coil (arrow, [Figure 3C](#)) clearly suggests a pre-existing insulation breach that was not caused by the extraction procedure. The mechanism of CCE is most likely IOA.

The SonRtip lead embeds a contractility sensor in its tip to assess LV contractility. The RESPOND-CRT trial has shown that automatic atrioventricular and biventricular timing optimization using this contractility sensor was safe and as effective as echo-guided optimization in increasing response to cardiac resynchronization therapy.<sup>7</sup> In the RESPOND-CRT trial, the freedom from acute (0–3 months) and chronic (3–12 months) atrial lead–related complications was 98.5% and 99.8%, respectively.<sup>7</sup> The 7.8F SonRtip lead has a multi-lumen design made of medical grade silicone elastomer with a polyurethane overlayer in the proximal section ([Supplemental Figure 2](#)). There are 4 lumens comprising a microcable for the sensor, a microcable for the proximal electrode, and a pace coil. The insulation defect was located in the outer curve of the “J-shaped” part of the atrial lead. IOA may be explained by differential lead component pulling and conjugate extension with reciprocal compression bending, as described by Lau.<sup>8</sup> In short, when the proximal lead segment is pulled, the noncable components extend in length. The cables cannot extend in length and excess length has to be redistributed from the distal to the proximal lead segment, causing the distal segment to deform by compression and bending. A sawing action of these cables under tension can cause the cables to wear through the outer insulation of the distal segment. This theoretical model also explains why an acute bend in the lead, which impedes cable movement, makes it more vulnerable to IOA.<sup>9</sup> Alternatively, it cannot be ruled out that the initial outer insulation abrasion of the atrial lead was caused by mutual lead friction leading to outside-in abrasion, thereby releasing the conductor cables under tension, followed by IOA extending the insulation breach.

To the best of our knowledge, we report the first case of CCE in a SonRtip atrial lead. The mechanism of CCE is

suspected to be IOA. Excessive slack of the atrial lead may have contributed to this phenomenon, but the multilumen design may also contribute to IOA. Data regarding the long-term longevity of these multilumen atrial leads are limited, because these leads have been in use for <9 years. According to the May 2018 product performance report of MicroPort there were only 5 cases (0.07%) of insulation breach (location not specified) in 6968 worldwide implants.<sup>10</sup> CCE was not reported in the product performance report; however, underreporting of CCE is possible, as this defect is not always accompanied by electrical abnormalities and is only detected with fluoroscopic imaging.

## Appendix Supplementary data

Supplementary data associated with this article can be found in the online version at <https://doi.org/10.1016/j.hrcre.2019.09.002>.

## References

1. Mann IE, Segal OR. A case of Durata ICD lead coil externalization: inside-out lead abrasion? *HeartRhythm Case Rep* 2016;2:283–285.
2. Parkash R, Thibault B, Mangat I, et al. Canadian Registry of Implantable Electronic Device Outcomes: Surveillance of the Riata Lead Under Advisory. *Circ Arrhythm Electrophysiol* 2016;9:e004282.
3. Sato T, Soejima K, Yoshino H, Shoda M. Unusual fracture in a Durata lead with shock coil fragmentation and cable externalization. *HeartRhythm Case Rep* 2017;3:327–331.
4. van Malderen SC, Szili-Torok T, Yap SC, Hoeks SE, Zijlstra F, Theuns DA. Comparative study of the failure rates among 3 implantable defibrillator leads. *Heart Rhythm* 2016;13:2299–2305.
5. Bogossian H, Mijic D, Frommeyer G, Winter J. Insulation failure and externalized conductor of a single-coil Kentrox lead: an ongoing story? *J Cardiovasc Electrophysiol* 2015;26:226–227.
6. Lau EW, Roberts MJD. Inside-out abrasion and contained conductor cable externalization in a defibrillation lead with asymmetric conductor cable lumen distribution. *HeartRhythm Case Rep* 2018;4:121–126.
7. Brugada J, Delnoy PP, Brachmann J, et al. Contractility sensor-guided optimization of cardiac resynchronization therapy: results from the RESPOND-CRT trial. *Eur Heart J* 2017;38:730–738.
8. Lau EW. Differential lead component pulling as a possible mechanism of inside-out abrasion and conductor cable externalization. *Pacing Clin Electrophysiol* 2013;36:1072–1089.
9. Lau EW. Compression-bending of multi-component semi-rigid columns in response to axial loads and conjugate reciprocal extension-prediction of mechanical behaviours and implications for structural design. *J Mech Behav Biomed Mater* 2013;17:112–125.
10. MicroPort CRM. Product Performance Report. Available at: <http://www.crm.microport.com/wp-content/uploads/2018/06/2018-May-PPR-Web-Version-6-1-2018.pdf>. Accessed August 27, 2019.