



Pediatric coccidioidal orbital granuloma

Cassiana E. Bittencourt^{a,*}, Onyinye Okezie^b, Khalid Tawansy^c, Ellena M. Peterson^a,
Don S. Minckler^d

^a Department of Pathology and Laboratory Medicine, University of California Irvine, School of Medicine, Irvine, CA, USA

^b Pediatrician in Private Practice, Bakersfield, CA, USA

^c Retina Specialist Private Practice, Long Beach, CA, USA

^d University of California Irvine, School of Medicine, Gavin Herbert Eye Institute, Irvine, CA, USA

ARTICLE INFO

Presented in part at the Eastern Ophthalmic Pathology Society (EOPS) 13 September, Army-Navy Club, Washington DC, 2018.

Keywords:

Coccidioides spp.
Coccidioidomycosis
Valley fever
Granulomatous disease
Orbit granuloma

ABSTRACT

Purpose: To report a case of orbital coccidiomycosis in an otherwise healthy 11-month-old male.

Observations: An 11-month-old male presented to his pediatrician with parental complaints of swelling, erythema, and pain of the right orbit that increased over ten days in the absence of constitutional symptoms. The child's parents reported an earlier fall onto a carpeted floor. After four weeks of conservative treatment and a course of oral cephalexin, he developed a fever, increased erythema, and palpable enlargement of a mass posterior to the lower eyelid. Ultrasound revealed an encysted mass in the inferior orbit, suggestive of an abscess. Urgent ophthalmic referral led to incision and drainage via orbitotomy. Culture, histopathology, and serological testing were positive for *Coccidioides* spp.. Blood studies revealed mild anemia and thrombocytosis. There was complete resolution of symptoms after surgical drainage and several weeks of oral fluconazole.

Conclusion and importance: We describe a patient with orbital coccidiomycosis without apparent systemic involvement, following what was most likely an unrelated minor trauma. Despite being rare, orbital coccidiomycosis should be considered as a primary manifestation of infection when ocular inflammation is encountered, especially in endemic regions.

1. Introduction

Coccidioidomycosis, also known as valley fever, is a fungal infection usually acquired by inhalation of arthroconidia of *Coccidioides* spp. primarily found in soil. The fungus is endemic in the southwestern United States, parts of Mexico, and Central and South America. The estimated number of infections is approximately 150,000 per year.^{1,2} In 2018, the annual National Notifiable Diseases Surveillance System (NNDSS) reported 15,611 cases to the Centers for Disease Control (CDC), in which California and Arizona represented 96% of the total.³ The highest incidence rates are among adults, typically age 60 and older,³ but infection in children may be increasing.^{4,5,6}

The most common clinical presentation is a respiratory illness, which manifests within one to three weeks after exposure.^{1,7} Hematogenous spread beyond the lungs can occur within weeks to several months after initial exposure. Common sites for dissemination include skin, subcutaneous tissue, joints, bones, internal organs, brain, and rarely the eye. Rates of disseminated disease range from 0.5% to 50%.^{1,3} Ocular and

orbital coccidioidomycosis have been documented in the literature, but the actual incidence has not been established.⁸

2. Case report

A healthy, well nourished, 11-month old male, in no apparent respiratory distress was referred for evaluation of a right orbital mass. According to the parents, the eye symptoms had begun ten days prior to presentation after a fall onto a carpeted floor. Upon initial evaluation by the pediatrician, the patient was afebrile and the right eyelid was swollen and edematous with a palpable mass under the lower eyelid. There were no other skin lesions, lymphadenopathy and the lungs were clear to auscultation. Review of systems was negative for history of HIV, an immunocompromised state, and no other family members were ill. The child resided in the San Joaquin Valley of Southern California. Initially observation and cool compresses were prescribed but then Cephalexin was prescribed after enlargement of the mass with mild fever. After 14 days, there was no response to the oral antibiotics and an

* Corresponding author.

E-mail address: bittenc@uci.edu (C.E. Bittencourt).

<https://doi.org/10.1016/j.ajoc.2022.101302>

Received 24 October 2020; Received in revised form 14 July 2021; Accepted 17 January 2022

Available online 20 January 2022

2451-9936/© 2022 Published by Elsevier Inc. This is an open access article under the CC BY-NC-ND license (<http://creativecommons.org/licenses/by-nc-nd/4.0/>).

orbital ultrasound (US) was performed. The US revealed a 1.5 cm loculated, thick-walled cystic lesion in the anterior right orbit, suggestive of an abscess (Fig. 1). Urgent ophthalmologic consultation was arranged.

Ophthalmologic examination revealed central, steady and maintained vision in both eyes. The right eyelid was swollen, indurated and had a violaceous rash. The inferior orbit had a firm, indurated 2 cm mass with conjunctival and episcleral chemosis and hyperemia. Anterior segment examination revealed no evidence of granulomatous iridocyclitis and there were no iris nodules. Posterior examination showed no vitritis and there were no chorioretinal lesions. The rest of the anterior and posterior examinations were normal. There was no evidence of meningitis on examination. Given the progression of the patient's exam despite antibiotic therapy, urgent orbitotomy with incision and drainage of the abscess was performed. Intraoperatively, a mass of inflammatory debris was encountered. Specimens were sent for culture and histopathology examination. Sections stained with hematoxylin and eosin (H&E) revealed chronic granulomatous inflammation and thick-walled spherules, containing endospores (Fig. 2A–C). The spherules also stained with Grocott methenamine silver (GMS), consistent with *Coccidioides* spp. Cultures grew white fluffy colonies, morphologically suggestive of *Coccidioides* spp., which were subsequently confirmed to be *C. immitis/podasii* by molecular testing. Immunodiffusion and complement fixation (CF) serological tests for *Coccidioides* spp. were positive, with a CF titer of 1:1,024. Blood work showed mild anemia and thrombocytosis. Neither chest X-ray or a pulmonary consult were performed, as the clinical exam had not demonstrated any signs of pulmonary or systemic disease.

Based on culture, serology and histopathology results, a diagnosis of orbital coccidiomycosis was established. Oral fluconazole, 100 mg/day, was prescribed for 4 months, and then was slowly tapered. One month after therapy initiation, the CF titer dropped to 1:64, indicating a

serological response to treatment. Approximately 14 months after diagnosis the patient continued to thrive, without any signs of systemic disease. He was maintained for several weeks on 2.5 mg/day of fluconazole. His CF titer had dropped to 1:16 at the time of this writing.

3. Discussion

Coccidioidomycosis, caused by the dimorphic fungi *C. immitis/podasii*, is usually acquired by the inhalation of arthroconidia dispersed from contaminated soil. Infection is commonly asymptomatic and goes unrecognized in 60% of cases.² The most frequent clinical manifestation is a pulmonary illness, indistinguishable from community-acquired pneumonia.^{1,9} Initial chest radiographs are abnormal in more than 50% of patients. Most infections in immunocompetent patients will resolve, independent of treatment.^{1,10} It is estimated that extrapulmonary complications are as low as 0.5% and as high as 30–50% in immunocompromised hosts.⁷ Patients with disseminated infection often have minimal or absent pulmonary symptoms or chest radiograph abnormalities.^{1,9} Most extrapulmonary dissemination is hematogenous, most commonly to the skin.⁹

Direct inoculation is rare but can result in a localized granuloma that typically self-resolves with a negative or low CF titer.^{10–13} In the case reported here the child fell on a home carpet prior to the onset of ocular symptoms. A carpet, especially in an endemic area, such as the one in this report, could be contaminated with arthroconidia of *Coccidioides* spp. However, in this case the fall was most likely incidental and not associated with the infection, especially in light of the initial high CF titer and lack of skin involvement or conjunctival lesions. Furthermore, while ocular coccidioidomycosis is rare it is usually associated with disseminated disease. Eye manifestations may range from asymptomatic to a fulminant granulomatous endophthalmitis.^{1,14}

As presented in our case, signs of an ocular infection lacking response to oral antibiotic therapy, a high index of suspicion for fungal infection, including coccidiomycosis, should be maintained and additional diagnostic testing performed. In general, a diagnosis of coccidiomycosis can be challenging. A multiple step approach tends to be necessary to establish a diagnosis of coccidiomycosis, which should include a detailed history (including travel history), physical examination, serology, and when possible, culture and histopathology. When done sequentially, this approach will increase the diagnostic yield.¹⁵

In the environment and in culture, *Coccidioides* spp. grow as mold with branching, septate hyphae and barrel-shaped arthroconidia. In tissue, *Coccidioides* spp. exists as large, round, thick-walled spherules (10–80 µm in diameter), containing endospores (2–20 µm in diameter). The organism can be readily detected in tissue by stains including H&E, GMS, Brown and Hopps, and Periodic Acid Schiff.¹⁶

Common serologic assays to aid in the diagnosis of coccidioidomycosis include enzyme immunoassays (EIAs), immunodiffusion (ID), and CF. The sensitivities of these three assays are 83%, 71%, and 56%, respectively.¹⁶ IgM is detectable one to two weeks after the onset of symptoms, and may persist for several months. IgG can be detected months to years after the initial infection, but will return to negative as the infection resolves.¹ As demonstrated with this case, CF titers are useful for diagnosis, evaluation of therapy efficacy, and prognosis. Here the patient had an IgG CF titer of 1:1,024 upon diagnosis which fell to 1:64 one month after treatment and about a year later was 1:16. In general, higher CF titers are correlated with disease severity.^{16–19}

Ocular coccidioidomycosis can present as anterior segment, intraocular and extraorbital lesions.⁷ The clinical manifestations include phlyctenular conjunctivitis, episcleritis, scleritis, keratoconjunctivitis, lid granulomata, iridocyclitis, choroiditis, chorioretinitis, endophthalmitis, nerve paralysis, anisocoria, papilledema, optic nerve granuloma, and optic atrophy.^{7,15,20} Ocular involvement is usually associated with disseminated disease^{7,8,15,20–27}; however, several cases have been reported without clinical evidence of systemic disease.^{15,24} Orbital coccidioidomycosis should be considered in individuals, especially in

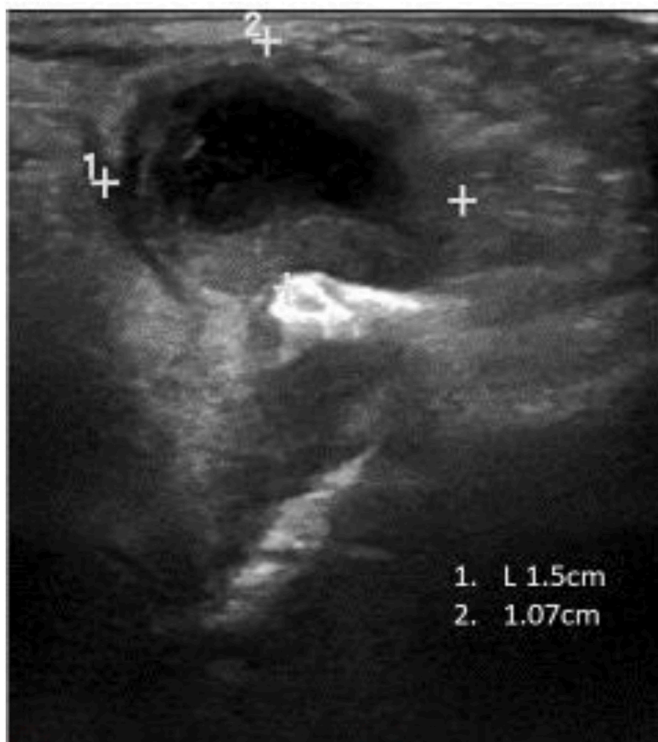

Fig. 1. Real time ultrasound of mass below right eye. The scans and measurements indicate a complex thick-walled cystic lesion in subcutaneous tissues of the orbit, measuring approximately 1.5 cm horizontally X 1.07 cm anterior-posteriorly. The companion Doppler studies indicated prominent surrounding vascularity.

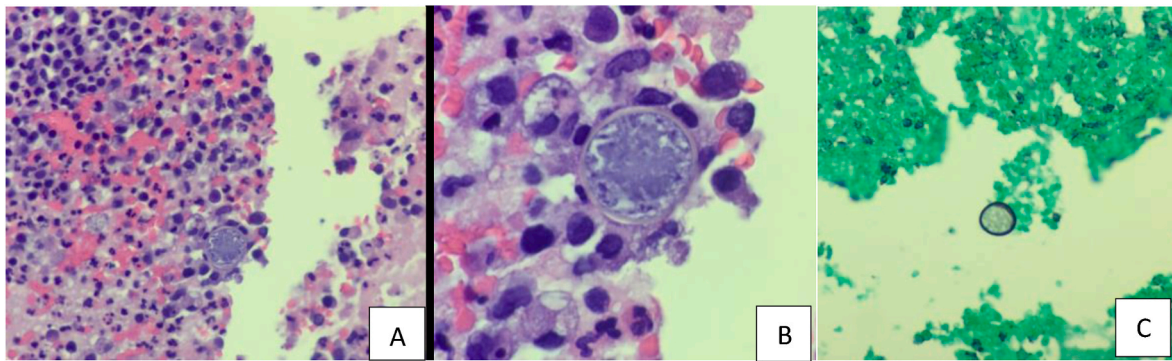


Fig. 2. Photomicrographs of *C. immitis/podasii* from an orbital specimen. (A) A section stained with H&E showing an encapsulated spherule with a distinctive thick-walled capsule containing deteriorating endospores in an acute and chronic inflammatory infiltrate (X400). (B) Higher magnification of the same section (X1,000). (C) Section stained with GMS demonstrating the thick-walled spherule (X400).

endemic regions, presenting with ocular inflammation, particularly if an orbital mass is present.

When extrapulmonary coccidiomycosis is diagnosed, systemic antifungals are usually recommended.¹ The optimal length of antifungal therapy is unclear for intraocular or orbital coccidioidal infection. Azoles, primarily fluconazole and itraconazole, are the antifungal drugs of choice for extrapulmonary coccidiomycosis.¹ Combined oral and intravitreal injections of antifungals have been reported in intraocular disease, with favorable outcomes.^{15,21}

4. Conclusions

To the best of our knowledge, this is the first reported case of orbital coccidiomycosis in an infant. Orbital coccidiomycosis, with no obvious evidence of concomitant systemic involvement is rare. A combination of histopathology, cultures, and serology can aid in the diagnosis.

Coccidiomycosis should be considered in any patient with ocular or orbital granulomatous inflammation, who has recently visited or lived in endemic areas. Increased coccidiomycosis awareness among pediatric and eye care providers is necessary to facilitate early diagnosis and appropriate management.

Patient consent

University of California, Irvine (UCI) does not require a signed permit for a single clinicopathologic case report.

Funding

This research was partially funded by an unrestricted Research to Prevent Blindness grant to the Department of Ophthalmology at UC Irvine, CA, USA.

Authorship

All authors attest that they meet the current ICMJE criteria for authorship.

Declaration of competing interest

None of the authors have any conflict of interest.

Acknowledgements

None.

References

- Galgiani JN, Ampel NM, Blair JE, et al. 2016 Infectious Diseases Society of America (IDSA) clinical practice guideline for the treatment of coccidioidomycosis. *Clin Infect Dis*. 2016 Sep 15;63(6):e112–e146.
- McCotter OZ, Benedict K, Engelthaler DM, et al. Update on the epidemiology of coccidioidomycosis in the United States. *Med Mycol*. 2019 Feb 1;57(Supplement_1): S30–S40.
- Valley Fever (Coccidioidomycosis) Statistics. Available at: <https://www.cdc.gov/fungal/diseases/coccidioidomycosis/statistics.html>. (Accessed: April 4, 2019).
- Lee LA1, Sondermeyer Cooksey GL1, Kim JJ1, Kahal A2, et al. Pediatric coccidioidomycosis: case series from a California pediatric infectious diseases clinic. *Pediatr Infect Dis J*. 2019 Feb;38(2):115–121.
- Sondermeyer Cooksey GL, Jain S, Vugia DJ. Epidemiology of coccidioidomycosis among children in California, 2000–2016. *Med Mycol*. 2019 Feb 1;57(Supplement_1): S64–S66.
- Dimitrova D, Ross L. Coccidioidomycosis: experience from a children's hospital in an area of endemicity. *J Pediatric Infect Dis Soc*. 2016 Mar;5(1):89–92.
- Rodenbiker HT, Ganley JP. Ocular coccidioidomycosis. *Surv Ophthalmol*. 1980 Mar-Apr;24(5):263–290.
- Increase in reported coccidioidomycosis—United States, 1998–2011. *MMWR Morb Mortal Wkly Rep*. 2013 Mar 29;62(12), 217–2.
- Russell DH, Ager E, Wohlman W. Cutaneous coccidioidomycosis masquerading as an epidermoid cyst: case report and review of the literature. *Mil Med*. 2017 Jan;182(1): e1665–e1668.
- Cunningham Jr ET, Seiff SR, Berger TG, Lizotte PE, Howes Jr EL, Horton JC. Intraocular coccidioidomycosis diagnosed by skin biopsy. *Arch Ophthalmol*. 1998 May;116(5):674–677.
- Stevens DA. Coccidioidomycosis. *N Engl J Med*. 1995;3321077–3321082.
- Lee JM, Graciano AL, Dabrowski L, Kuzmik B, Tablizo MA. Coccidioidomycosis in infants: a retrospective case series. *Pediatr Pulmonol*. 2016 Aug;51(8):858–862.
- McHardy IH, Dinh BN, Waldman S, et al. Coccidioidomycosis complement fixation titer trends in the age of antifungals. *Clin Microbiol*. 2018 Nov 27;56(12).
- Saubolle MA. Laboratory aspects in the diagnosis of coccidioidomycosis. *Ann N Y Acad Sci*. 2007 Sep;1111:301–314.
- Vasconcelos-Santos DV, Lim JI, Rao NA. Chronic coccidioidomycosis endophthalmitis without concomitant systemic involvement: a clinicopathological case report. *Ophthalmology*. 2010 Sep;117(9):1839–1842.
- Saubolle MA, et al. Epidemiologic, clinical and diagnostic aspects of coccidioidomycosis. *J Clin Microbiol*. 2007;45:26–30.
- Mandell, Douglas, and Bennett's Principles and Practice of Infectious Diseases. Seventh edition. (Chapter 266).
- Shubitz LF1, Dial SM. Coccidioidomycosis: a diagnostic challenge. *Clin Tech Small Anim Pract*. 2005 Nov;20(4):220–226.
- Garcia Garcia SC, Salas Alanis JC, Flores MG, et al. Coccidioidomycosis and the skin: a comprehensive review. *An Bras Dermatol*. 2015 Sep-Oct;90(5):610–619.
- Hwang JM, Pian D. Iritis presumed as secondary to disseminated coccidioidomycosis. *Optometry*. 2006 Nov;77(11):547–553.
- Ling JJ, Bays DJ, Thompson 3rd GR, Moshiri A, Mannis MJ. Favorable outcome in Coccidioides endophthalmitis—A combined medical and surgical treatment approach. *Cornea*. 2017 Nov;36(11):1423–1425.
- Cheng ML, Leibowitz M, Ha E. Coccidioidal endophthalmitis in immunocompetent person, California, USA. *Emerg Infect Dis*. 2012 Jun;18(6):1015–1016.
- Char DH, Crawford JB, Bertolucci G, Cole T. Intraocular coccidioidomycosis simulating a neoplasm. *Br J Ophthalmol*. 2012 Feb;96(2):218–219.
- Moorthy RS, Rao NA, Sidikaro Y, Foos RY. Coccidioidomycosis iridocyclitis. *Ophthalmology*. 1994 Dec;101(12):1923–1928.
- Pettit TH, Learn RN, Foos RY. Intraocular coccidioidomycosis. *Arch Ophthalmol*. 1967 May;77(5):655–661.
- Blumenkranz MS, Stevens DA. Endogenous coccidioidal endophthalmitis. *Ophthalmology*. 1980;87:974–984.
- Wood TR. Ocular coccidioidomycosis. *Am J Ophthalmol*. 1967;64:587–591.