

Internal Pudendal Artery Perforator Island Flap for Management of Recurrent Benign Rectovaginal Fistula

Haitham H. Khalil, MSc, MRCS, MD, FRCS(Eng)*
 Marco N. Malahias, MSc, MRCS*
 Sharad Karandikar, MS, FRCS(Ed), FRCS(Gen Surgery)†
 Charles Hendrickse, MB, ChB, MD, FRCS(Ed)†

Summary: The management of recurrent rectovaginal fistula after obstetric injury and cryptoglandular sepsis is considered a major surgical challenge. The fistula poses a significant negative psychosocial and sexual morbidity. In addition, the poor quality of local tissues due to previous attempts at surgical repair adds to this challenge. There are few data regarding the management of persistent or recurrent fistula in the literature; however, several studies reported high failure rates after 2 or more procedures. We present 4 cases managed successfully in a multidisciplinary approach involving fistulectomy and immediate reconstruction with an internal pudendal artery perforator island flap. (*Plast Reconstr Surg Glob Open* 2016;4:e841; doi: 10.1097/GOX.0000000000000850; Published online 12 August 2016.)

Recurrent benign rectovaginal fistula (RVF) represents a surgical dilemma and challenge. Fistula formation after obstetric injury and cryptoglandular anal sepsis is rare in developed countries, representing only 0.06% to 0.1% of presenting cases with recurrent cases being even rarer.¹ This problem poses a significant emotional, social, and sexual morbidity especially in healthy young women. In addition, the poor regional tissues' quality, sparse vascularity, dense scar from previous attempts of surgical repair, and the disturbed anatomy contribute to this challenge. Repeated repairs after 1 attempt seem to have a reasonable success rate.² However, several studies reported higher failure rate after 2 or more procedures, so subsequent options should be chosen carefully.² The authors present a case series of 4 patients managed successfully with a multidisciplinary team approach by fistulectomy and immediate reconstruction utilizing the internal pudendal artery perforator (Ipap) island flap.

MATERIAL AND METHODS

Data were prospectively collected on 4 consecutive patients in the period between 2010 and 2015 and were reviewed. Their management entailed a multidisciplinary approach comprising the colorectal and reconstructive surgeons. All patients were subjected to routine clinical assessment, examination under anesthesia, and magnetic resonance imaging.

Data Collection

The demographic information, comorbidities, surgical history, and previous diagnostic workup were collected. The operative details identified the site, extent, length of fistulous tract, size of the resultant defect including the perineal skin deficiency, and size of Ipap flap. The postoperative follow-up period ranged from 8 to 30 months identifying the length of stay, complications, wound healing, and sexual activity.

Operative Consideration

The patients are catheterized and put in the lithotomy position. After identifying the fistula site with a probe, the perforators are marked using 8-MHz hand-held Doppler in the vascular triangle (ischial tuberosity, apex of coccyx, and vaginal orifice), approximately 3 and 6 cm lateral to the midline (Figs. 1–4). (See video, **Supplemental Digital Content 1**, which displays an intraoperative video demonstrating the surgical steps of the repair of a recurrent benign recto-vaginal fistula. This video is available in the "Related Videos" section of PRSGlobalOpen.com or available at <http://links.lww.com/PRSGO/A243>.) Free-style

From the *Department of Oncoplasty and Reconstructive Surgery, Good Hope Hospital, Heart of England NHS Foundation Trust, Birmingham, United Kingdom; and †Department of Colorectal Surgery, Heartlands Hospital, Heart of England NHS Foundation Trust, Birmingham, United Kingdom.

Received for publication February 3, 2016; accepted June 17, 2016. Presented as oral presentation (invited speaker session) at International Society of Pelvic Floor Disorders meeting, November 2015, Hangzhou, China.

Accepted for forthcoming oral/video presentation at Association of Coloproctology of Great Britain and Ireland, 2016, Edinburgh, United Kingdom and Royal College of Obstetricians and Gynecology World Congress, 2016, Birmingham, United Kingdom.

Copyright © 2016 The Authors. Published by Wolters Kluwer Health, Inc. on behalf of The American Society of Plastic Surgeons. All rights reserved. This is an open-access article distributed under the terms of the Creative Commons Attribution-Non Commercial-No Derivatives License 4.0 (CCBY-NC-ND), where it is permissible to download and share the work provided it is properly cited. The work cannot be changed in any way or used commercially.

DOI: 10.1097/GOX.0000000000000850

Disclosure: The authors have no financial interest to declare in relation to the content of this article. The Article Processing Charge was paid for by the authors.

Supplemental digital content is available for this article. Clickable URL citations appear in the text.

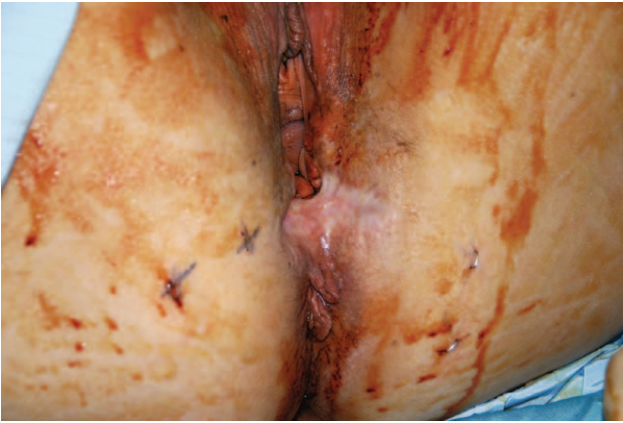


Fig. 1. Preoperative photograph showing scarred contracted deficient perineum previously due to cryptogenic infection and previous surgical attempt for repair of low RVF leading to cloacal deformity of the vaginal introitus.



Fig. 4. Postoperative photograph 24 mo showing complete healing and restoration of the shape and volume of the perineum including the vaginal introitus.

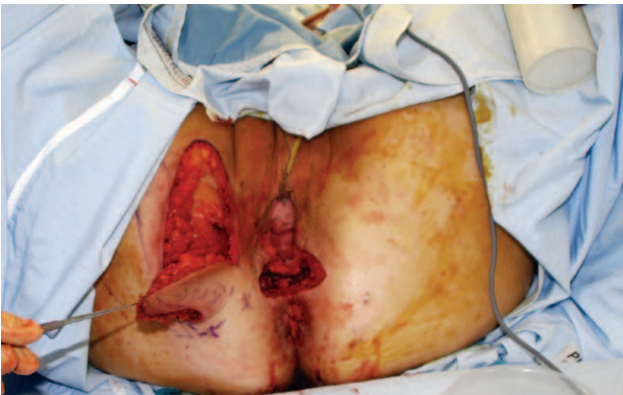
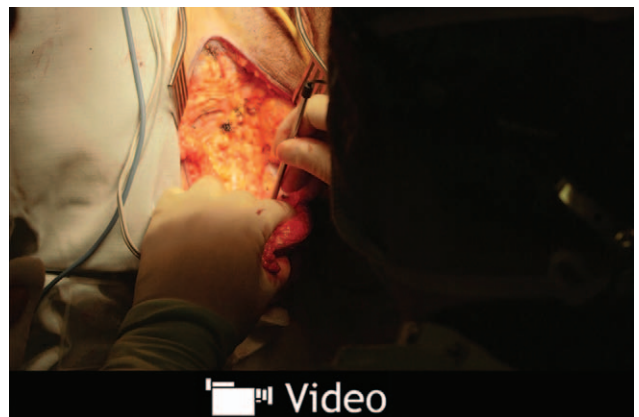
Fig. 2. Intraoperative picture showing the harvesting of the Ipap flap and the perineal defect after en bloc fistulectomy and excision of the perineal scar.



Video 1. See video, Supplemental Digital Content 1, which displays an intraoperative video demonstrating the surgical steps of the repair of a recurrent benign recto-vaginal fistula. This includes the fistulectomy and primary closure of the vaginal and low rectal opening followed by immediate reconstruction of the rectovaginal septum and the concomitant deficient perineal skin simultaneously with internal artery perforator flap (Ipap). This video is available in the "Related Videos" section of PRSGlobalOpen.com or available at <http://links.lww.com/PRSGO/A243>.

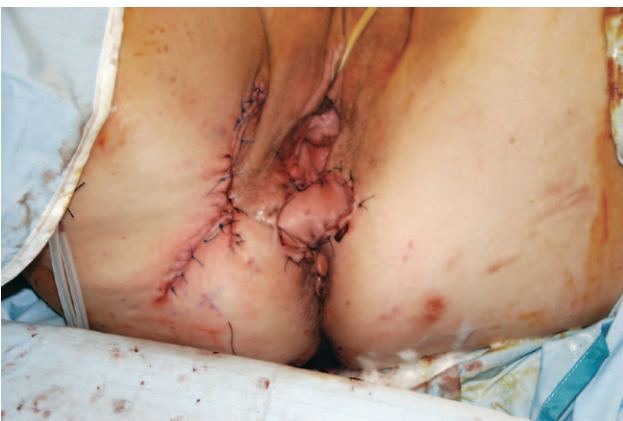

Fig. 3. Intraoperative photograph showing 3-dimensional inset of the flap to reconstruct the rectovaginal septum and restore the perineal deficiency with the cutaneous component with primary closure of the donor site.

design of the skin paddle is performed starting in the medial thigh crease at the adductor longus origin and then caudally to a point medial to the identified perforator representing the flap height (11–15 cm). The skin pinch test technique will determine the width (4–7 cm) that allows primary closure, and subsequently the lateral border is marked joining the medial border cephalically.

Skin incision is performed including any previous perineal scar that is followed by dissection of the plane between the posterior vaginal and anterior anorectal wall to 2 to 3 cm cephalic to the fistulous opening. The low vaginal and midrectal openings of the fistulous tract were debrided to healthy tissue, which in turn increased the size of the defects further. One-layer closure of the defects was achieved using interrupted 3/0 PDS sutures (Ethicon, Cincinnati, Ohio).

Table 1. Patient and Operative Characteristics

	Age (yr)	Body Mass Index	Pathology	Comorbidities	Previous Surgery	Previous Plug Insertion/ Fibrin Injection	Interval between Primary Presentation and Revisual Procedure (mo)	Magnetic Resonance Imaging Pelvis	Defunctioning Colostomy (3 mo before Definitive Procedure)	Perineal Skin Deficiency
Patient 1	38	29	Postdelayed obstetric injury, RVF	None	Twice primary repair + advancement mucosal flap	Once	22	Yes	Yes, no improvement	Yes
Patient 2	41	32	Postcryptoglandular infection, low RVF dyspareunia	Diabetic type II	Seton + twice primary surgical repair with advancement mucosal flap	Twice	18	Yes	Yes, no improvement	Yes including cloacal deformity of vaginal introitus
Patient 3	34	30	Postobstetric injury, low RVF	Smoker	Once primary surgical repair with advancement mucosal flap	Once	14	Yes	Yes, no improvement	Yes
Patient 4	34	31	Postobstetric injury, low RVF	None	Once primary surgical repair with advancement mucosal flap	Once	14	Yes	Yes, no improvement	Yes

	Revisual Definitive Procedure	Depth of Rectovaginal Septum Defect (cm)	Skin Flap Dimensions (cm) and Perineal Skin Island Dimension (cm) (Zone II)	Reversal of Colostomy (wk)	Follow-up (mo)
Patient 1	En bloc fistulectomy + unilateral right island flap	7	11×6 and 2×3	12	20
Patient 2	En bloc fistulectomy + unilateral right island flap	8	15×7 and 2×3	11	30
Patient 3	En bloc fistulectomy + unilateral right island flap thigh flap	7	12×6 and 4×3	9	8
Patient 4	En bloc fistulectomy + unilateral right island flap	7	12×6 and 2×3	12	24

Dissection of the flap is performed from cephalic to caudal in the suprafascial plane harvesting the superficial fascia. An intraoperative Doppler is used to confirm the perforator site within the thick fatty tissue of the ischioanal fossa at the base of the flap. No attempt is made to skeletonize the perforators to avoid vascular injury as the vessels branch off deep in the fossa. Subsequently, the flap is tunneled deep to the labia majora and inset into the rectovaginal septum with concomitant reconstruction of the perineal skin. This allows the determination of 3 zones (proximal, middle, and distal) of the flap. (See Supplemental Digital Content 2, which displays a diagram showing the inset of the flap allow the determination of 3 zones, <http://links.lww.com/PRSGO/A244>.) Routine postoperative care is followed in all patients including careful structured ambulation.

RESULTS

The patient and operative characteristics are summarized in Table 1. All patients had history of classic step-up management of RVF because of recurrence with failed attempts of plug insertion, fibrin glue injection, local surgical treatment, and defunctioning stoma. The repeated surgery had led to extensive scar formation with contracted deficient perineal skin. All flaps survived with good cosmetic outcomes; all patients reported painless sexual intercourse within the follow-up period. Through the follow-up period, no recurrence was encountered after the reversal of their defunctioning stoma.

DISCUSSION

The etiology, site, primary or recurrent, condition of the sphincters, comorbidities, and patient body habitus are recognized to have an impact on the outcome of RVF management.³ Despite the high failure rates reported whatever the surgical option chosen, few studies have reported to date an algorithm for the step-up management of RVF.⁴ This has ranged from simple seton drainage, fibrin glue, plug insertion, advancement mucosal flaps, sphincteroplasty, biomesh interposition to more complex procedures such as gracilis or Martius muscle interposition or abdominal procedures.³⁻⁵ The value of the defunctioning stoma in the surgical management of RVF is still debatable; however, it has been reported to improve outcomes in patients who have had a number of failed repairs.⁶ In this series, all patients have been referred with a defunctioning stoma in an attempt to improve the healing rate. Nevertheless, recurrent fistulas involving the middle third of the vagina almost always require tissue interposition,³ which was encountered in all of the patients after debridement and fistulectomy.

The internal pudendal perforator thigh flap was first described by Wee and Joseph⁷ in 1989 and is also commonly known as the Lotus flap or Singapore flap. Hashimoto et al⁸ reported a large series of 71 Ipap flaps in 45 patients in which 9 of them were for total vaginal repair for malignant disease and included propeller, transposition, and advancement flaps. In our series, we present a

3-dimensional inset of the island flap to reconstruct 2 components including the potential space in the rectovaginal septum after fistulectomy and the perineal skin deficiency simultaneously utilizing the multizone design which to authors' knowledge would be the first to be reported within this context and design.

The armamentarium for reconstruction for perineal and vaginal reconstruction is diverse and includes musculocutaneous flaps as rectus and gracilis flaps, fasciocutaneous flaps including thigh flaps and deep inferior epigastric perforator flaps, bowel interposition, and omental flap.⁸⁻¹⁰ These, however, are longer procedures, bulkier, and more distant options with different dermatomal supply and more donor-site morbidity.⁸⁻¹⁰ Special attention to preservation of the local anatomy for a better cosmetic outcome and the preservation of the integrity of the intact anal sphincters is required for better outcomes. Anatomical considerations are paramount with the main aim directed to the restoration of the shape, volume, and function with the least morbidity. The Ipap flap provides these advantages with minimal local anatomical disruption and same urogenital dermatomal supply, low donor site morbidity with scars being concealed in the natural gluteal and thigh creases. The utilization of Ipap flap would not be suitable in previously damaged perianal skin because of either previous surgery or pathology. There are limitations for this study as this comes from a single-center experience with a small series; however, this is due to the relative rarity of these presentations for this selected group of patients.

CONCLUSIONS

The utilization of Ipap flap for recurrent RVF is a reliable, safe, easy-to-execute option, which has the same urogenital dermatomal supply and low donor-site morbidity. Its versatile nature allows reconstruction of concomitant perineal skin defect with minimal anatomical disturbance and hence should be considered as a valuable tool in the armamentarium of RVF management.

Haitham H. Khalil, MSc, MRCS(Ed), MD, FRCS(Eng)

Department of Oncoplasty and Reconstructive Surgery
Good Hope Hospital
Heart of England NHS Foundation Trust
Rectory Road
Sutton Coldfield
Birmingham, B75 7RR, West Midlands
United Kingdom
E-mail: haitham.khalil@heartofengland.nhs.uk

ACKNOWLEDGMENT

We thank Medial Illustration Team and Department, Heart of England NHS Foundation Trust.

REFERENCES

1. Homs R, Daikoku NH, Littlejohn J, et al. Episiotomy: risks of dehiscence and rectovaginal fistula. *Obstet Gynecol Surv*. 1994;49:803-808.
2. Ozuner G, Hull TL, Cartmill J, et al. Long-term analysis of the use of transanal rectal advancement flaps for complicated anorectal/vaginal fistulas. *Dis Colon Rectum* 1996;39:10-14.

- Halverson AL, Hull TL, Fazio VW, et al. Repair of recurrent rectovaginal fistulas. *Surgery* 2001;130:753–757; discussion 757–758.
- Corte H, Maggiori L, Treton X, et al. Rectovaginal fistula: what is the optimal strategy?: an analysis of 79 patients undergoing 286 procedures. *Ann Surg.* 2015;262:855–860; discussion 860–861.
- Pinto RA, Peterson TV, Shawki S, et al. Are there predictors of outcome following rectovaginal fistula repair? *Dis Colon Rectum* 2010;53:1240–1247.
- Ruffolo C, Penninckx F, Van Assche G, et al. Outcome of surgery for rectovaginal fistula due to Crohn's disease. *Br J Surg.* 2009;96:1190–1195.
- Wee JT, Joseph VT. A new technique of vaginal reconstruction using neurovascular pudendal-thigh flaps: a preliminary report. *Plast Reconstr Surg.* 1989;83:701–709.
- Hashimoto I, Abe Y, Nakanishi H. The internal pudendal artery perforator flap: free-style pedicle perforator flaps for vulva, vagina, and buttock reconstruction. *Plast Reconstr Surg.* 2014;133:924–933.
- Luo S, Raffoul W, Piaget F, et al. Anterolateral thigh fasciocutaneous flap in the difficult perineogenital reconstruction. *Plast Reconstr Surg.* 2000;105:171–173.
- Wang X, Qiao Q, Burd A, et al. A new technique of vaginal reconstruction with the deep inferior epigastric perforator flap: a preliminary report. *Plast Reconstr Surg.* 2007;119:1785–1790; discussion 1791.