

Rare finding of a pericardial lipoma in a pediatric patient presenting with ventricular tachycardia



Majid Husain, MD,^{*†} Anthony McCanta, MD, FHRS,^{*†} Anjan S. Batra, MD, MBA, FHRS^{*†}

From the ^{*}Children's Hospital of Orange County, Orange, California, and [†]UC Irvine Health School of Medicine, Irvine, California.

Introduction

Primary cardiac lipomas in children are rare and often reported as incidental findings during operations or autopsies. Ventricular tachycardia (VT) is an unusual complication of primary cardiac lipomas. We describe the case of a 14-year-old previously healthy male subject who presented with an idiopathic VT arising from the left ventricle, ultimately diagnosed with a rare pericardial lipoma.

Case report

A 14-year-old previously healthy male subject, with no significant personal or familial cardiac history, presented to the emergency room with syncope and several episodes of a “racing heartbeat” associated with weakness, dizziness, and sweating. An electrocardiogram (ECG) revealed a monomorphic wide complex tachycardia with a right bundle branch block (RBBB) at 195 beats/min that was unresponsive to intravenous (IV) amiodarone but terminated with IV verapamil (Figure 1). The QRS duration in VT varied from 180 ms to 200 ms. A baseline 12-lead ECG after termination of the tachycardia showed sinus rhythm with early repolarization and T-wave inversion in the inferior and lateral precordial leads (Figure 2). The initial echocardiogram showed normal function and no intracardiac abnormalities.

A stress test showed no arrhythmias with exercise and a 24-hour Holter monitor showed monomorphic premature ventricular contractions <1%. An electrophysiologic study failed to induce or detect the origin of the arrhythmia. However, the patient had recurrent episodes of VT that terminated acutely with IV verapamil.

A repeat echocardiogram with visualization of the pericardial area beyond the left ventricular (LV) apex revealed an echogenic density in the epicardium suspicious of a tumor impinging on the LV apex and lateral wall. Subsequent cardiac computed tomography characterized the above-stated echogenic density as a 6.3 × 3.7-cm ill-defined fat-density

KEY TEACHING POINTS

- Clinicians must consider primary pericardial tumors in the differential diagnosis when evaluating for unidentifiable sources of arrhythmia or nonspecific cardiac symptoms.
- Echocardiograms focused on intracardiac anatomy can potentially miss tumors in the extracardiac space. Cardiac computed tomography or magnetic resonance imaging is the modality of choice for evaluation of cardiac masses.
- Surgical resection of the identified mass is often curative.

lesion, likely a pericardial lipoma, that was abutting the inferior LV wall, causing irregularity and mass effect upon the cardiac apex. Cardiac magnetic resonance imaging found the lesion to be most consistent with a lipoma, with fat suppression best appreciated on the T2-weighted images (Figure 3).

He underwent resection of a majority of the cardiac tumor with primary reconstruction of the left ventricle via a midline sternotomy. Pathology of this mass revealed homogeneous, yellow adipose tissue throughout, consistent with a lipoma. He had an uneventful postoperative course and there were no additional arrhythmias noted. He was discharged in stable condition after a 13-day hospitalization. He has remained asymptomatic, with no arrhythmias on serial Holter monitors for 2 years.

Discussion

Wide complex monomorphic tachycardias, in the absence of structural heart disease, arise most commonly from the right ventricle (75%–90%) and less commonly (10%–15%) from the left ventricle. The most common type of idiopathic VT arising from the left ventricle is fascicular VT with RBBB.^{1,2} Very rarely, such a tachycardia can be from other causes such as a primary cardiac neoplasm.

Primary cardiac neoplasms, including pericardial lipomas, are an exceedingly rare finding and occur with a frequency of

KEYWORDS Lipoma; Left ventricle; Pediatric; Pericardial; Ventricular tachycardia
(Heart Rhythm Case Reports 2019;5:277–280)

Address reprint requests and correspondence: Dr Anjan S. Batra, Children's Hospital of Orange County, 1140 W La Veta Ave, Suite 750, Orange, CA 92868. E-mail address: abatra@uci.edu.

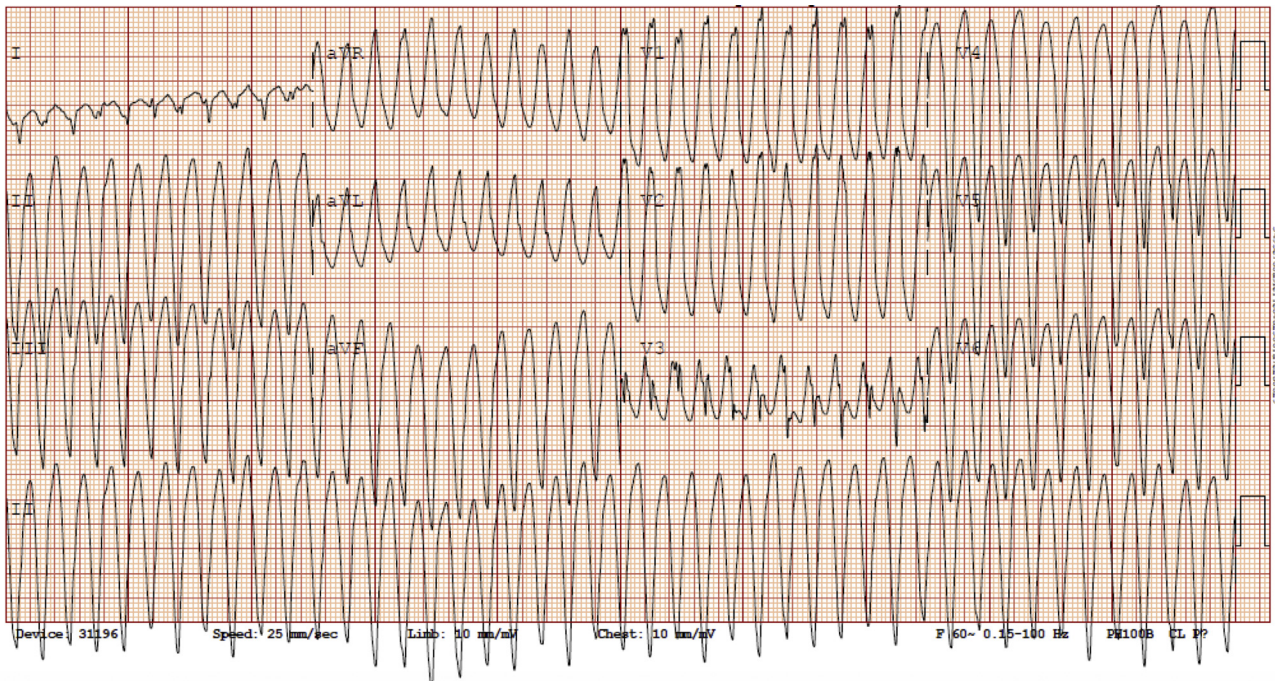


Figure 1 Initial electrocardiogram showing monomorphic wide complex tachycardia with a right bundle branch block and left anterior hemiblock at 195 beats/min. The QRS duration in ventricular tachycardia varied from 180 ms to 200 ms.

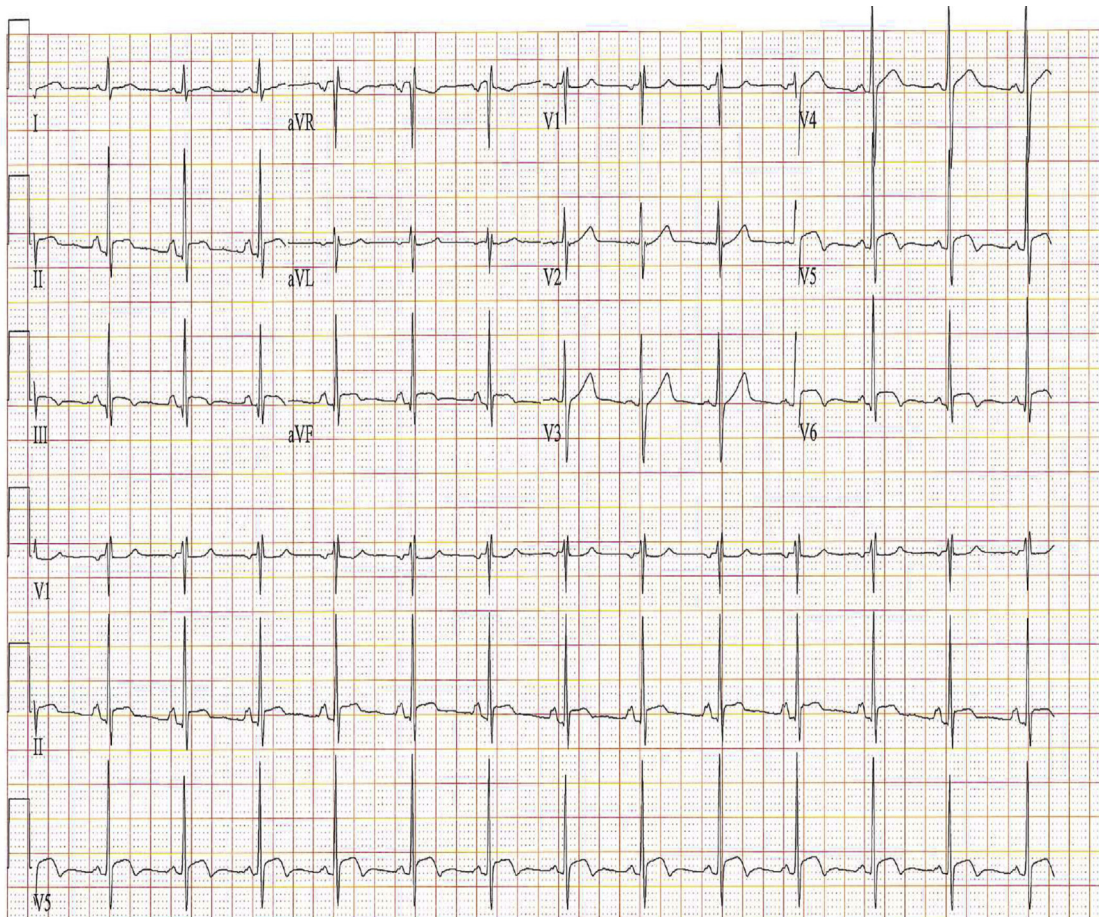


Figure 2 Baseline 12-lead electrocardiogram after termination of the tachycardia showed sinus rhythm with early repolarization and T-wave inversion in the inferior and lateral precordial leads.

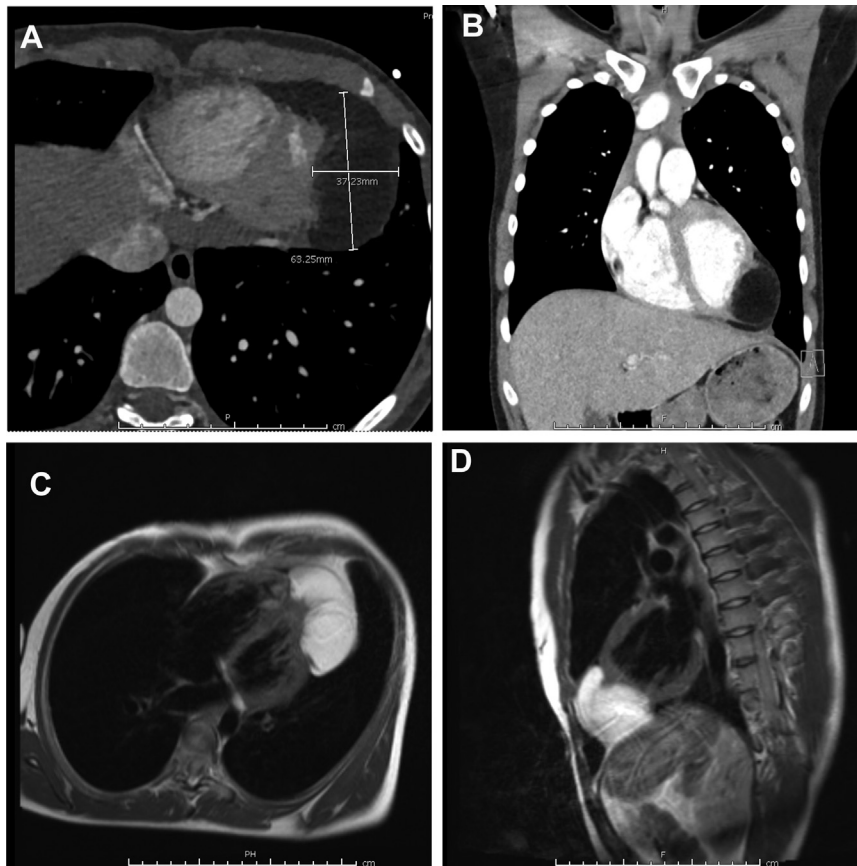


Figure 3 **A, B:** Cardiac computed tomography demonstrating the echogenic density as a 6.3×3.7 -cm ill-defined fat-density lesion, likely a pericardial and less likely intracardial lipoma, owing to internal minimal stranding and septation, noted to be abutting the inferior left ventricular wall and causing irregularity and mass effect upon the cardiac apex. **C, D:** Cardiac magnetic resonance imaging showing the lesion to be most consistent with a lipoma, with fat suppression best appreciated on the T2-weighted images.

0.03%–0.32% in the general pediatric population.^{3–5} While most of these neoplasms are typically benign and asymptomatic, their association with clinically significant arrhythmias has been previously reported. Notably, in one of the largest studies of pediatric primary cardiac tumors ($n = 173$), clinically significant arrhythmias were reported to occur in 42 (24%) of the cases—consisting of rhabdomyomas, fibromas, myxomas, and teratomas. Lipomas made up a minority of the total cases ($n = 3$, 1.7%) and none of these 3 cases had any arrhythmias, hemodynamic compromise, or coronary involvement.⁵ Similarly, a recent study of 166 pediatric patients with cardiac tumors found clinically significant arrhythmias in 11 (6.6%) of the cases. Rhabdomyomas and fibromas made up the majority of these cases. There were a total of 5 cases of lipomas identified; none was associated with an arrhythmia.⁶ Furthermore, Beghetti and colleagues⁷ had previously identified 56 pediatric patients with various cardiac tumors and described arrhythmias in 11 cases. Again, rhabdomyomas and fibromas were the common culprit. The 1 reported case of an epicardial lipoma was not associated with an arrhythmia.⁷ Data regarding the association of a pericardial lipoma with clinically significant arrhythmias have been largely limited to a few case reports.^{8–11} We found only 1 pediatric case report of a previously healthy 13-year-old male patient with VT

who was found to have a lipoma embedded in the myocardium, adjacent to but not involving the circumflex coronary artery.¹¹

From a diagnostic perspective, echocardiograms focused on intracardiac anatomy can potentially miss tumors in the extracardiac space, as was seen on the initial echocardiogram in our case. Cardiac computed tomography or magnetic resonance imaging is the modality of choice for evaluation of cardiac masses. This also provides necessary information on myocardial and pericardial extension, vascularity, and extracardiac extension.

From a treatment perspective, it is important to differentiate a fascicular VT from a VT originating from the myocardium in the left ventricle. While the ECG during both tachycardias can be characterized by RBBB with a left superior axis, suggesting an exit site from the inferoposterior ventricular septum, the QRS duration in fascicular VT varies from 140 ms to 150 ms and the rates are relatively slower. As was seen in our case, calcium channel blockers may be effective in terminating both tachycardias and cannot be used to differentiate the 2 forms of tachycardia.

The mechanism of VT in our patient was likely triggered by automaticity vs reentry. Clinical observation from our case suggests that calcium channel blockers may be effective in suppressing the ventricular arrhythmias and supports

the previously well-established experiences that surgical resection can be an effective, sometimes curative, option for the elimination of life-threatening and difficult-to-control arrhythmias caused by primary cardiac/pericardial tumors.⁵

Conclusion

Pericardial neoplasms should remain on the differential diagnosis when evaluating for unidentifiable sources of arrhythmia or nonspecific cardiac symptoms—especially when refractory to standard treatments.

References

1. Quimby TW, Clark AA, Fix ML. Idiopathic ventricular tachycardia: Belhassen type. *West J Emerg Med* 2010;11:389–390.
2. Chiu C, Sequeira IB. Diagnosis and treatment of idiopathic ventricular tachycardia. *AACN Clin Issues* 2004;15:449–461.
3. Restrepo CS, Vargas D, Ocazonez D, Martínez-Jiménez S, Betancourt Cuellar SL, Gutierrez FR. Primary pericardial tumors. *RadioGraphics* 2013;33:1613–1630.
4. Reynen K. Frequency of primary tumors of the heart. *Am J Cardiol* 1996;77:107.
5. Miyake CY, Del Nido PJ, Alexander ME, et al. Cardiac tumors and associated arrhythmias in pediatric patients, with observations on surgical therapy for ventricular tachycardia. *J Am Coll Cardiol* 2011;58:1903–1909.
6. Shi L, Wu L, Fang H, et al. Identification and clinical course of 166 pediatric cardiac tumors. *Eur J Pediatr* 2017;176:253–260.
7. Beghetti M, Gow RM, Haney I, Mawson J, Williams WG, Freedom RM. Pediatric primary benign cardiac tumors: a 15-year review. *Am Heart J* 1997;134:1107–1114.
8. Shenthar J, Sharma R, Rai MK, Simha P. Infiltrating cardiac lipoma presenting as ventricular tachycardia in a young adult. *Indian Heart J* 2015;67:359–361.
9. Fukushima KK, Mitani T, Hashimoto K, et al. Ventricular tachycardia in a patient with cardiac lipoma. *J Cardiovasc Electrophysiol* 1999;10:1161.
10. Qi L, Yang Y, Huo Y, Sun JP. Cardiac lipoma with ventricular arrhythmias. In: Sun JP, Yang XS, Yan BP, eds. *Comparative Cardiac Imaging: A Case-based Guide*. Hoboken, NJ: Wiley; 2018:197–200.
11. Friedberg MK, Chang IL, Silverman NH, Ramamoorthy C, Chan FP. Images in cardiovascular medicine. Near sudden death from cardiac lipoma in an adolescent. *Circulation* 2006;113:778–779.