

Safety and efficacy of a new cold snare technique with clipping for colorectal angioectasia

**OPEN
ACCESS**



Authors

Jun Arimoto¹, Hideyuki Chiba¹, Keiji Yamada¹, Naoya Okada¹, Mikio Kobayashi¹, Hiroki Kuwabara¹, Michiko Nakaoka¹, Ken Ohata²

Institutions

- 1 Department of Gastroenterology, Omori Red Cross Hospital, Tokyo, Japan
- 2 Department of Gastroenterology, NTT Medical Center Tokyo, Tokyo, Japan

submitted 13.6.2022

accepted after revision 3.11.2022

published online 04.11.2022

Bibliography

Endosc Int Open 2023; 11: E157–E161

DOI 10.1055/a-1972-3510

ISSN 2364-3722

© 2022. The Author(s).

This is an open access article published by Thieme under the terms of the Creative Commons Attribution-NonDerivative-NonCommercial License, permitting copying and reproduction so long as the original work is given appropriate credit. Contents may not be used for commercial purposes, or adapted, remixed, transformed or built upon. (<https://creativecommons.org/licenses/by-nc-nd/4.0/>)

Georg Thieme Verlag KG, Rüdigerstraße 14,
70469 Stuttgart, Germany

Corresponding author

Hideyuki Chiba, 4-30-1, Chuo, Ota-Ku, Tokyo 143-8527, Japan

Fax: +81-45-784-3546

h.chiba04@gmail.com

ABSTRACT

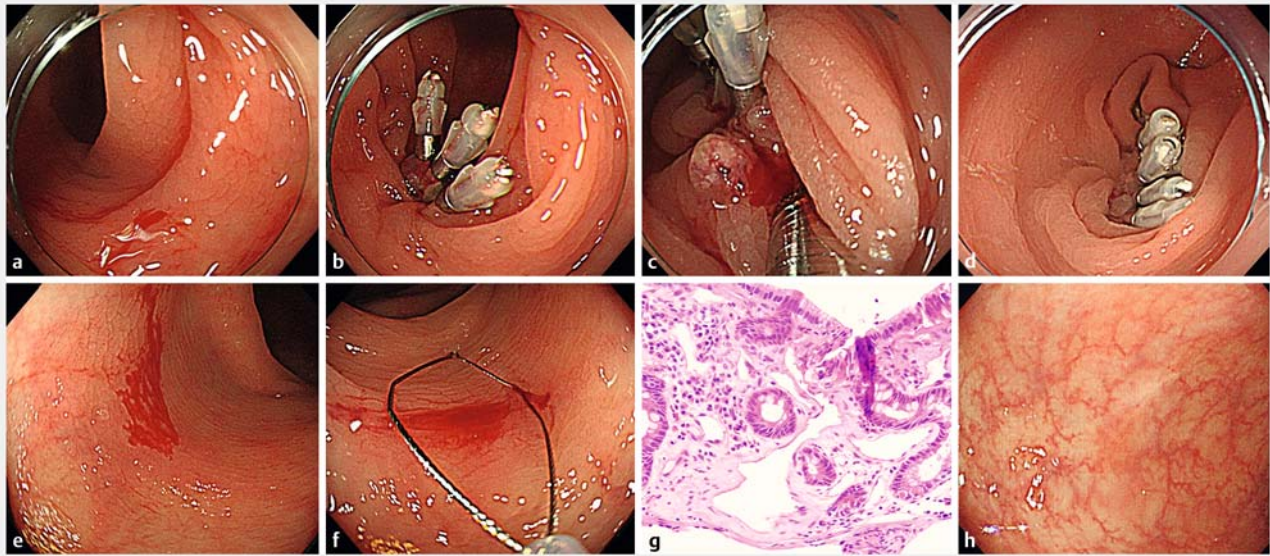
Colorectal angioectasia is a major cause of lower gastrointestinal bleeding. Use of antithrombotic agents is expected to increase with aging of the population, and bleeding from angioectasia is an important issue. Although the effectiveness of endoscopic mucosal resection for colorectal angioectasia has been reported, there are no reports of cold snare technique for angioectasia (CSA). From February 2018 to February 2022, the safety of CSA was evaluated at Omori Red Cross Hospital. We investigated the incidence of bleeding (delayed post-polypectomy bleeding (DPPB) and immediate bleeding) after CSA and the incidence of rebleeding requiring repeated endoscopic treatment. During the study period, 106 angioectasias were identified during colonoscopy. We only targeted patients with bloody stools and/or anemia requiring treatment for bleeding from angioectasia. Finally, we included 11 angioectasias in this study. Rates of DPPB and rebleeding after CSA were 0%. The rate of immediate bleeding during CSA was 27.3% (3/11). Dilated capillaries could be observed pathologically in nine of 11 lesions (81.8%). CSA was safe and can be a new treatment option in the future. To confirm our results and verify the long-term safety and efficacy of CSA, further studies are desirable.

Introduction

Colorectal angioectasia has been increasingly recognized as a major cause of lower gastrointestinal bleeding in the elderly [1]. Argon plasma coagulation (APC) and clipping are often performed for bleeding from angioectasia. However, there are some reports of colonic gas explosion leading to perforation in some cases during APC [2], and endoscopists also often experience patient suffering due to gas explosion. Furthermore, regarding clipping for colorectal angioectasia, the problem of rebleeding commonly occurs.

Four cases of colorectal angioectasia treated with hot snare polypectomy (HSP) or endoscopic mucosal resection (EMR) have been reported [1, 3]. In EMR/HSP, the dilated capillaries

are resected; therefore, the possibility of rebleeding from angioectasia is low. This is a very different technique from APC or traditional clipping. However, patients with clinically severe anemia due to bleeding from angioectasia often take antithrombotic agents, and delayed post-polypectomy bleeding (DPPB) after EMR/HSP is major concern in them. Several studies have shown that DPPB is less common after cold snare polypectomy (CSP) than after conventional EMR/HSP [4, 5]. Use of antithrombotic agents is expected to increase with aging of the population [6]; therefore, the safety of the procedure itself is increasingly important. We have previously reported that use of antithrombotic agents, even multiple antithrombotic agents, does not increase risk of DPPB after CSP [7]. Therefore, we hypothesized that a cold snare technique for angioectasia (CSA) is



► **Fig. 1** **a** Bleeding from angioectasia in the transverse colon. **b** Hemostasis was performed by clipping for bleeding. **c** Two days later, bleeding from the same site was observed. **d** Hemostasis was performed again by clipping for bleeding. **e** Five months later, the patient returned to our hospital with a complaint of bloody stool. Bleeding from angioectasia at another site was observed. **f** We performed CSP for the resection of angioectasia. **g** Some dilated capillaries were found in the mucosa of the resected specimen. **h** We confirmed scarring after 1 year.

safer than EMR/HSP. We examined cases of CSA for bleeding from angioectasia at our hospital.

Patients and methods

Patients

This study was a retrospective case series evaluating the safety and efficacy of a new treatment for colorectal angioectasia using a cold snare technique with clipping. From February 2018 to February 2022, the safety of CSA with clipping was evaluated at Omori Red Cross Hospital. During the study period, 106 angioectasias were identified during colonoscopy. We excluded patients who did not need treatment, such as those with angioectasia that was diagnosed incidentally during colonoscopy, and we only targeted patients with bloody stools and/or anemia requiring treatment for bleeding from angioectasia. Finally, we included 11 angioectasias (5 patients) in this study. We investigated incidence of bleeding (DPPB and immediate bleeding) after CSA with clipping and incidence of rebleeding requiring repeated endoscopic treatment.

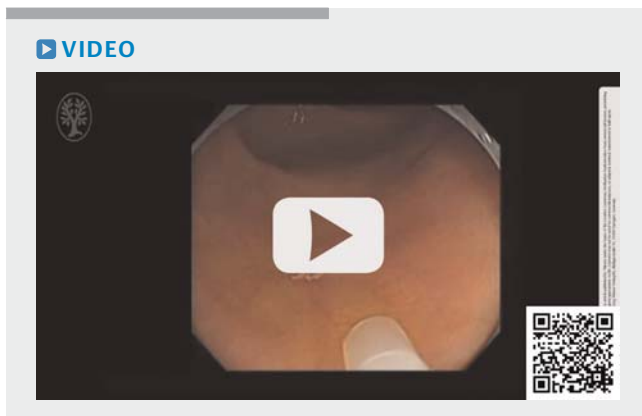
Although CSP for polyps has been shown to be safe, CSA has not been reported, and its safety is unknown. We also examined whether DPPB after CSA is extremely rare similar to that after CSP for polyps.

CSA with clipping

A standard or magnifying colonoscope with carbon dioxide insufflation was used in all cases (CF-HQ290ZI, PCF-Q260AZI, PCF-Q260AI, and PCF-H290ZI; Olympus Co., Tokyo, Japan). After CSA, we performed clipping in all cases. CSA is a challenging treatment that has not been reported so far; therefore, we performed clipping in all cases for patient safety. DPPB was de-

defined as reduction in hemoglobin level by at least 2 g/dL below the most recent preoperative level or need for endoscopic hemostasis and/or blood transfusion and/or massive melena within 2 weeks of the procedure [8, 9]. Immediate bleeding that necessitated hemostatic clipping was defined as spurting or oozing that continued for more than 30 seconds [9]. This definition was used to avoid the potential for a biased assessment of immediate bleeding. ► **Fig. 1** shows a case of CSA with clipping. A 78-year-old man taking edoxaban visited the outpatient department of our hospital with a chief complaint of bloody stools. We performed hemostasis with endoscopic clipping. However, bleeding from the same site was observed after 2 days, and hemostasis was performed again by clipping for bleeding. Five months later, the patient returned to our hospital with a complaint of bloody stool. Bleeding from angioectasia at another site was observed. We performed CSA with clipping. The histopathologic findings of the resected specimen showed some obvious dilated capillaries in the mucosa. At the 1-year follow-up visit, the patient experienced no rebleeding or DPPB after CSA, and we confirmed scarring at the same site after 1 year. ► **Video 1** shows another case of CSA with clipping in the cecum. Although immediate bleeding occurred, the feeding vessel was clearly observed in the defect. The exposed bleeding vessel was clipped, adequately controlling the bleeding through endoscopic hemostasis. At the 1-year follow-up visit, this patient also did not experience complications.

In this study, we counted each angioectasia lesion that was resected, even if two or more angioectasias were resected during the CSA procedure; two or more angioectasias resected during the same CSA procedure were counted as two or more angioectasias. The study protocol complied with the Declaration of Helsinki and the Ethics Guidelines for Clinical Research



► **Video 1** Angioectasias in the cecum. Snaring of the angioectasias. Resection. Feeding vessel in the defect. Clipping of the exposed bleeding vessel. Additional clipping. Confirmation of hemostasis.

published by the Ministry of Health, Labour and Welfare, Japan. Approval for this study was obtained from the Ethics Committee of Omori Red Cross Hospital on October 1, 2021. This was a retrospective study, and patients were enrolled according to an opt-out policy of our hospital.

Results

Patient characteristics

Five patients (11 angioectasias) were included in this study. Their clinical characteristics are presented in ► **Table 1**. Five patients were enrolled in this analysis, with a mean age (\pm SD) of 83.4 ± 3.6 years. All patients were receiving antithrombotic therapy, and antithrombotic therapy was continued even on the day of colonoscopy in all cases. All patients had comorbidities and anemia due to hematochezia.

Angioectasia characteristics

Characteristics of the angioectasias are presented in ► **Table 2**. There were 11 total angioectasias. Six angioectasias (54.5%) were located in the cecum. The rate of immediate bleeding during CSA was 27.3% (3/11), and we performed prophylactic clipping in all cases even without immediate bleeding. Rates of DPPB after CSA and rebleeding from angioectasia were 0%. Re-

garding histopathology, dilated capillaries could be confirmed in nine of 11 lesions (81.8%).

Discussion

Angioectasia is defined as abnormal, dilated, tortuous, and usually small (< 10 mm) blood vessels visualized within the mucosal and submucosal layers of the gut, and the colon is the most frequent site of angioectasia in the gut [2]. Bleeding from colorectal angioectasia can be mild and chronic and can stop spontaneously in up to 90% of patients [2]. However, use of antithrombotic agents is expected to increase with aging of the population [6]; therefore, bleeding from angioectasia is increasingly important. Bleeding from angioectasia can be recurrent and life-threatening.

The effectiveness of EMR/HSP for colorectal angioectasia has been reported in some cases [1, 3]. In EMR/HSP, the dilated capillaries are resected; therefore, the possibility of rebleeding from angioectasia is low. This is a very different technique than APC or traditional clipping. However, patients with clinically severe anemia due to bleeding from angioectasia often take antithrombotic agents, and DPPB after EMR/HSP is a major concern for these patients. On the other hand, DPPB after CSP is very rare [4, 5], and use of antithrombotic agents does not increase risk of DPPB after CSP even if patients are taking multiple antithrombotic agents [7]. Both EMR/HSP and CSA are treatments that involve resection of the dilated capillaries in the same manner. If the therapeutic effects are same, the rate of complications from an endoscopic procedure is important in clinical practice. DPPB after CSP is very rare and the rate is less than that after EMR/HSP. In addition, with this procedure, it is unnecessary to prepare a high-frequency device, apply a counter electrode, and evaluate for absence of metal in the body and clothes. CSP is convenient and safe. Therefore, we think that a cold snare technique with clipping is superior to EMR/HSP as a treatment for colorectal angioectasia.

CSA with clipping also has other advantages. As shown in ► **Video 1**, the feeding vessel was clearly observed in the defect. Therefore, we were able to perform clipping directly on the exposed blood vessel. We think this is likely to be effective for bleeding from angioectasia. On the other hand, CSA with clipping is not without potential disadvantages. Angioectasia is present in the mucosal and submucosal layers of the colon [2]. The incidence of incomplete mucosal layer resection after

► **Table 1** Characteristics of enrolled patients.

Patient	Age	Sex	Antithrombotic agents	Comorbidity	Hematochezia	Hb
1	89	M	Aspirin	CKD	+	7.9
2	79	M	Edoxaban	Af	+	8.7
3	83	M	Prasugrel	History of AMI	+	11.6
4	84	M	Prasugrel	History of AMI	+	9.4
5	82	M	Edoxaban	Af	+	8.2

CKD, chronic kidney failure; Af, atrial fibrillation; AMI, acute myocardial infarction; Hb, hemoglobin.

► **Table 2** Angioectasia characteristics.

Lesion	Location	IB	Clipping	DPPB	Rebleeding	Pathological dilated capillaries
1	C	-	+	-	-	Unclear
2	T	-	+	-	-	Unclear
3	A	-	+	-	-	+
4	A	-	+	-	-	+
5	A	-	+	-	-	+
6	C	+	+	-	-	+
7	C	+	+	-	-	+
8	C	+	+	-	-	+
9	C	-	+	-	-	+
10	C	-	+	-	-	+
11	T	-	+	-	-	+

IB, immediate bleeding; DPPB, delayed post-polypectomy bleeding

CSP was 57% in a previous study [10], and the submucosal layer cannot be removed with CSP. Therefore, the effectiveness of CSA remains unclear. However, feeding vessels can be visually recognized by performing CSA, and clipping of the exposed blood vessel can be performed directly, as shown in ► **Video 1**. In addition, considering the pathophysiologic mechanisms of colorectal angioectasia, we believe that CSA with clipping could be clinically useful for treating bleeding from colorectal angioectasia. Sami et al. reported on pathophysiologic mechanisms contributing to angioectasia and subsequent bleeding [2]. Histologic evaluation of resected colon specimens from patients with angioectasia revealed dilated and tortuous veins in the submucosa, even without obvious mucosal lesions. Therefore, it was suggested that lesions develop with aging because of chronic, low-grade, and intermittent obstruction of submucosal veins, resulting from increased contractility of the muscularis propria, which leads to venous dilation in the submucosal layer. Eventually, an arteriovenous collateral circulation is formed in the mucosal layer. When this circulation spreads superficially, and can be seen endoscopically, it is diagnosed as angioectasia, and bleeding from dilated veins can occur. Considering the pathophysiologic mechanisms of angioectasia, we thought it would be advantageous if blood vessels exposed on the superficial mucosal surface were removed. Numerous blood vessels exist within the walls of the gastrointestinal tract; however, only blood vessels exposed on the surface layer of the gastrointestinal wall cause bleeding. Therefore, we think it is unnecessary to completely resect all blood vessels from the submucosal layer. Resection of superficial blood vessels with CSA means that the tissue returns to a normal state, with veins only present in the submucosa. From this state, contraction of the muscularis propria causes venous congestion, and vasodilation of the submucosal layer is expected to result in a considerable time before blood vessels become re-exposed as angioectasias on the surface layer. This theory is supported, in part, by

the fact that angioectasias are more common in older individuals.

In addition, clipping the wound may prevent future exposure of blood vessels in superficial layers. Therefore, we believe that CSA with clipping, which involves resecting superficial blood vessels and suturing the wound, is an effective treatment for angioectasia.

Although this was a retrospective case series performed at a single center, rates of DPPB and rebleeding after CSA were 0% in this study.

Conclusions

In conclusion, CSA with clipping was safe and can be a new treatment option in the future. To confirm our results and verify the long-term safety and efficacy of CSA, further studies are desirable.

Acknowledgments

The authors thank the staff of the participating institutions for their support in recruiting eligible patients and the patients who participated in this study.

Competing interests

The authors declare that they have no conflict of interest.

References

- [1] Lin It, Chang WH, Shih SC et al. Successful endoscopic polypectomy for colonic vascular ectasia presenting as pedunculated polypoid lesion. *Endoscopy* 2007; 39: E253–E254

- [2] Sami SS, Al-Araji SA, Ragunath K. Review article: gastrointestinal angiodysplasia – pathogenesis, diagnosis and management. *Aliment Pharmacol Ther* 2014; 39: 15–34
- [3] Sriram N, Yishay IB, Kumarasinghe P et al. Definitive therapy of colonic angioectasia by submucosal coagulation. *Endosc Int Open* 2019; 7: E1773–E1777
- [4] Takeuchi Y, Yamashina T, Matsuura N et al. Feasibility of cold snare polypectomy in Japan: A pilot study. *World J Gastrointest Endosc* 2015; 7: 1250–1256
- [5] Yamashina T, Fukuhara M, Maruo T et al. Cold snare polypectomy reduced delayed postpolypectomy bleeding compared with conventional hot polypectomy: a propensity score-matching analysis. *Endosc Int Open* 2017; 5: E587–E594
- [6] Mozaffarian D, Benjamin EJ, Go AS et al. American Heart Statistics Committee and Stroke Statistics Subcommittee. Heart disease and stroke statistics – 2015 update: a report from the American Heart Association. *Circulation* 2015; 131: e29–e322
- [7] Arimoto J, Chiba H, Ashikari K et al. Safety of cold snare polypectomy in patients receiving treatment with antithrombotic agents. *Dig Dis Sci* 2019; 64: 3247–3255
- [8] Arimoto J, Higurashi T, Chiba H et al. Continued use of a single anti-platelet agent does not increase the risk of delayed bleeding after colorectal endoscopic submucosal dissection. *Dig Dis Sci* 2018; 63: 218–227
- [9] Horiuchi A, Nakayama Y, Kajiyama M et al. Removal of small colorectal polyps in anticoagulated patients: a prospective randomized comparison of cold snare and conventional polypectomy. *Gastrointest Endosc* 2014; 79: 417–423
- [10] Shichijo S, Takeuchi Y, Kitamura M et al. Does cold snare polypectomy completely resect the mucosal layer? A prospective single-center observational trial *J Gastroenterol Hepatol* 2020; 35: 241–248