

# Evaluation of technetium-99m metastable nanocolloid as an imaging agent for performing milk scans

Osayande Evbuomwan, Jaleelat Momodu, Khushica Purbhoo and Mboyo D.T. Vangu

**Objective** The aim of this study was to determine whether technetium-99m ( $^{99m}\text{Tc}$ ) nanocolloid was a suitable alternative tracer for carrying out milk scan studies in pediatric patients.

**Participants and methods** Twenty-seven milk scans performed with  $^{99m}\text{Tc}$  nanocolloid were retrospectively assessed for identification of significant esophageal hold-up, gastroesophageal reflux, pulmonary aspiration, and gastric emptying (GE). Scans were also assessed for liver, spleen, and bone marrow uptake. GE results were compared with those of 27 randomly selected normal GE studies carried out using  $^{99m}\text{Tc}$  tin colloid.

**Results** None of the studies had liver, spleen, or bone marrow uptake, and all studies were interpretable. Significant esophageal hold-up and gastroesophageal reflux was observed in 11 and 48% of the patients, respectively. Only one patient had evidence of pulmonary aspiration, and all patients had normal GE at 2 h after radiolabeled milk ingestion. The average rate of GE at 2 h was faster in the  $^{99m}\text{Tc}$  nanocolloid group compared with the  $^{99m}\text{Tc}$  tin colloid group (8.85% retained  $\pm$  8.96% vs. 15.48% retained  $\pm$  10.52%,  $P = 0.016$ ).

## Introduction

The milk scan is a nuclear medicine study that has been performed for more than 30 years for the detection and quantification of gastroesophageal reflux (GER) in infants and children [1–3]. It is also referred to as GER scintigraphy [4,5]. In addition to detecting GER, it can also detect pulmonary aspiration (PA), abnormal esophageal transit (ET), and gastric emptying (GE) disorders in children [4,6]. Its simplicity, noninvasiveness, reproducibility, physiologic nature, and the favorable radiation dose of the test have made it popular and thus accepted by many pediatricians as an additional diagnostic test for the diagnosis and follow-up of GER in infants and children [6]. The ideal radiotracer for this study should mix evenly with ingested food (milk), be nonabsorbable from the gastrointestinal tract or respiratory mucosa, have no effect on GE, and should not bind to gastrointestinal mucosa [4,7]. These qualities have made technetium-99m ( $^{99m}\text{Tc}$ ) sulfur colloid the recommended radiotracer for performing milk scans [4]; however, because of its unavailability in South Africa,  $^{99m}\text{Tc}$  tin colloid is used.

**Conclusion** Our findings show that  $^{99m}\text{Tc}$  nanocolloid is technically a suitable alternative to  $^{99m}\text{Tc}$  sulfur colloid for performing milk scans. However, we could not conclude with certainty on the comparison of the GE rates of  $^{99m}\text{Tc}$  nanocolloid and  $^{99m}\text{Tc}$  tin colloid. This was because of the variability in the two population groups as well as the fact that the milk that was used in each patient was individualized to the patient and was not standardized. *Nucl Med Commun* 40:52–56 Copyright © 2018 Wolters Kluwer Health, Inc. All rights reserved.

Nuclear Medicine Communications 2019, 40:52–56

Keywords: gastroesophageal reflux, milk scan, nanocolloid

Department of Nuclear Medicine and Molecular Imaging, University of the Witwatersrand, Johannesburg, South Africa

Correspondence to Osayande Evbuomwan, MBBS, FCNP (SA), Wits Medical School, Area 559, Blue block, 7 Yorkroad, Parktown, 2193 Johannesburg, South Africa  
Tel: +27 742 869 731; fax: +27 114 883 501; e-mail: moreli14@yahoo.com

Received 26 April 2018 Revised 22 August 2018 Accepted 5 October 2018

Recent production and quality control challenges have resulted in the sporadic availability of  $^{99m}\text{Tc}$  tin colloid in South Africa. Consequently, our facility has been using  $^{99m}\text{Tc}$  nanocolloid as an alternative for milk scans. The effectiveness of this alternative for performing milk scans is not known, but an in-vitro study evaluating radiopharmaceuticals for GE studies showed that it might be an effective alternative [8]. However, we postulated that because of its smaller particle size ( $< 80$  nm) [9–11],  $^{99m}\text{Tc}$  nanocolloid might have a faster GE compared with tin or sulfur colloid, with particle sizes of 100–1000 nm [9].

We decided to investigate whether  $^{99m}\text{Tc}$  nanocolloid is a good substitute for  $^{99m}\text{Tc}$  tin colloid to carry out milk scan studies including assessment of differences in their estimation of GE at 2 h after radiolabeled milk ingestion. The direct consequences of the possible outcome will be cost saving to the department and the hospital, as the same  $^{99m}\text{Tc}$  nanocolloid used routinely for sentinel lymph node mapping and bone marrow scintigraphy can also be used to perform milk scans.

## Participants and methods

Ethics approval was obtained from the University of Witwatersrand's Human Research Ethics Committee, with ethics clearance number M171124. The scans of 27 infants and children referred to the Nuclear Medicine Department at Chris Hani Baragwanath Academic Hospital for milk scans using  $^{99m}\text{Tc}$  nanocolloid between August and September 2017 were retrospectively analyzed. Twenty-seven earlier normal GE studies from our archives using  $^{99m}\text{Tc}$  tin colloid between June and July 2017 were selected randomly using simple randomization and analyzed. Patients who vomited during the study, those who did not complete their study, and who were fed through a nasogastric tube were excluded.

## Equipment and acquisition

All images were acquired using the GE Infinia Hawkeye GP3 (2006; GE medical systems, Tirat Hacarmel, Israel) camera, with a low-energy high-resolution collimator. All the study participants underwent ET, GER, PA, and GE studies as per departmental protocol. One millicurie (mCi) of radiotracer ( $^{99m}\text{Tc}$  tin or nanocolloid) was introduced into 2 mls of

milk in a sterile 2 ml syringe. Each patient was feed orally with the 2-ml syringe and with the camera in the left oblique position, dynamic images (0.5 s a frame for 1 min, matrix size:  $128 \times 128$ ) of the ET phase of the study were acquired. A static image was then acquired for 1 min after the ET phase. This was followed by feeding the child the usual feed volume with unlabeled milk before commencing the GER phase of the study (1 s a frame for 30 min, matrix size:  $128 \times 128$ ). Anterior and posterior static images for 1 min were acquired immediately after the GER phase of the study 1 and 2 h after initial feeding, with matrix sizes of  $256 \times 256$ .

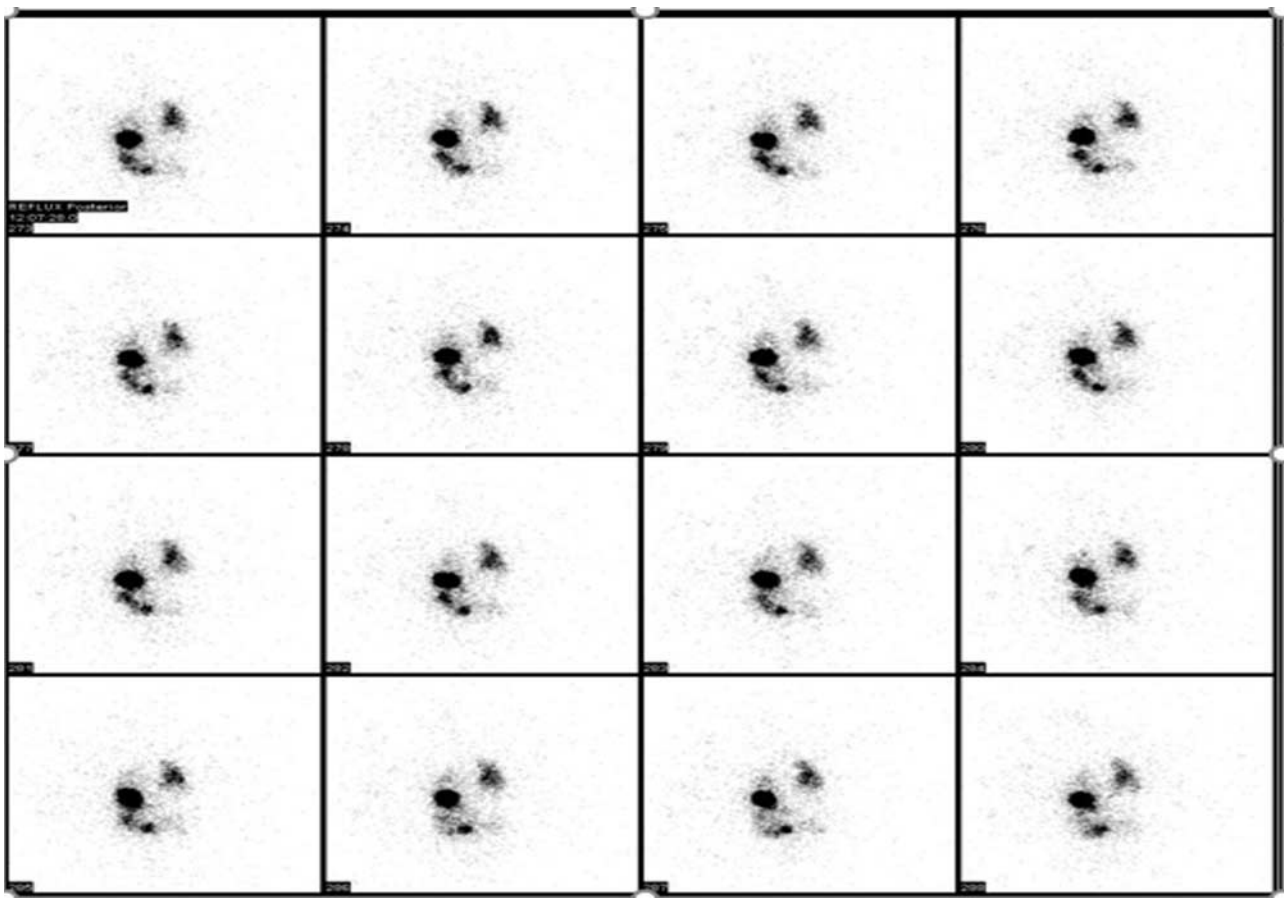
## Image processing and interpretation

Images were processed by an experienced nuclear medicine consultant, who was blinded to which radiotracer was used. The software for gastric and esophageal studies on the GE Xeleris work station was used.

## Esophageal transit study

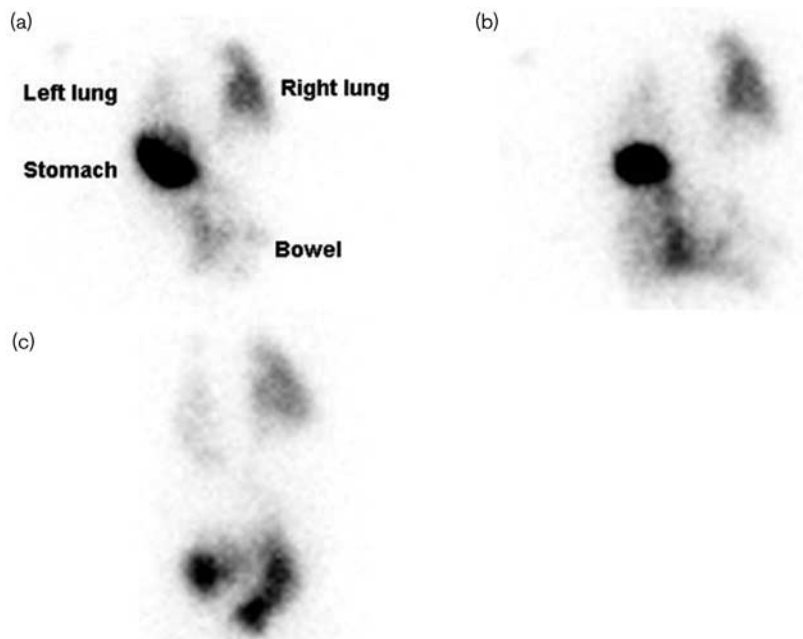
Visual analysis and quantitative analysis (using a condensogram) were used to assess the ET phase.

Fig. 1



Selected posterior frames from the gastroesophageal reflux phase of a milk scan performed with  $^{99m}\text{Tc}$  nanocolloid on a 1-month-old infant with recurrent chest infections and failure to thrive showing diffuse tracer uptake in both lung fields (right > left).

Fig. 2



Posterior static images at 15 min (a), 1 h (b), and 2 h (c) of the patient in Fig. 1 confirming pulmonary aspiration, worse in the right lung field.

Persistent hold-up of tracer in more than eight frames on the dynamic images was considered significant for abnormal esophageal hold-up.

#### Gastroesophageal reflux

Visual analysis and semiquantitative analysis were used to assess for significant GER. The presence of tracer activity in the esophagus, more than 4% of the total gastric activity in any frame, was considered to indicate significant GER. The height of activity and the difference in esophageal counts at the beginning of the reflux phase and during suspected reflux were used to differentiate between previous activity from esophageal hold-up and reflux.

#### Gastric emptying study

A semiquantitative method by drawing a region of interest (ROI) around the stomach and a larger ROI around the stomach and gut on the posterior 2-h static images was used to calculate the GE at 2 h. The number of counts from the ROI around the stomach was divided by the amount of counts from the ROI around the stomach and gut, and the percentage of activity retained in the stomach was calculated.

#### Pulmonary aspiration

Visual analysis was used to assess for PA. The dynamic images during the reflux phase of the study were assessed for ectopic activity in the airways or lungs fields. This was complemented by viewing the static images after ET, after the GER phase, at 1 and 2 h after a radiolabeled meal.

All images of the patients were also assessed qualitatively for spleen, liver, and bone marrow uptake.

#### Data and statistical analysis

Data from each study participant were collected using Microsoft excel 2016, and were analyzed using STATA 13.1 package, MP – parallel edition (StataCorp LP, College Station, Texas, USA).

The results of variables such as sex, esophageal dysmotility, significant GER, PA, spleen, liver, and bone marrow uptake were presented as frequencies and percentages. Age was represented as the mean and SD.

A two-sample *t*-test was used to analyze the difference between the group means of the GE of the two tracers.


#### Results

The mean age of the 27 patients imaged with the  $^{99m}\text{Tc}$  nanocolloid was 11 months ( $\pm 20$ ), with 18 females and nine males. None of the study participants had spleen, liver, or bone marrow uptake, and were all interpretable.

With respect to the ET study, 19 (70%) had no evidence of esophageal hold-up of tracer, three (11%) had significant esophageal hold-up of tracer, whereas five (19%) had nonsignificant hold-up in the distal third of the esophagus.

Eight (30%) patients had no evidence of GER, 13 (48%) had evidence of significant GER (Fig. 1), whereas 22% ( $n=6$ ) had GER that was normal for age. Only one patient

Fig. 3



Selected posterior frames from the gastroesophageal reflux (GER) phase of a milk scan performed with <sup>99m</sup>Tc nanocolloid on a 3-month-old infant with recurrent chest infections showing significant GER.

**Table 1 Gastric emptying rate (defined as percentage retained in the stomach at 2 h after ingestion of radiolabeled milk) of both <sup>99m</sup>Tc nanocolloid and <sup>99m</sup>Tc tin colloid**

	N	Mean	SD	95% CI	Min-max	P value
Nanocolloid	27	8.85	8.96	5.31–12.40	0–32	0.016
Tin colloid	27	15.48	10.52	11.32–19.64	4–34	

Two-sample *t*-test.

CI, confidence interval; max, maximum; min, minimum.

had evidence of PA (Figs 2 and 3). The GE was calculated to be normal in all patients (<35% retained).

The GE studies using <sup>99m</sup>Tc tin colloid of 27 randomly selected patients with normal GE were compared with the GE of the <sup>99m</sup>Tc nanocolloid group. The difference between both groups was significant ( $P=0.016$ ) (Table 1).

## Discussion

GER is the passage of gastric contents into the esophagus with or without regurgitation and vomiting [4,6]. It is

common in healthy and well-thriving infants [4], but its frequency declines with age, and is rarely seen after 18 months of age [12–14]. In contrast, gastroesophageal reflux disease (GERD) is present when the reflux of gastric contents causes symptoms and/or complications [15]. It is of paramount importance to identify patients at risk of developing GERD as most patients achieve symptom relief after successful control of GER [16].

The recommended radiotracer for milk scans is <sup>99m</sup>Tc sulfur colloid because it remains stable in the stomach and is not absorbed by the gastrointestinal tract or respiratory mucosa [4]. These properties reduce background activity, thus improving the detection of reflux and PA [17], and most likely accurate calculation of GE. However, Ertay *et al.* [8], in their series, showed the stability of <sup>99m</sup>Tc nanocolloid-labeled meals in gastric acid. It was for this reason that we decided to use this agent to perform milk scans during the erratic supply of tin colloid in South Africa. This was also shown to be cost effective as we use the <sup>99m</sup>Tc nanocolloid for sentinel lymph node mapping and

bone marrow scintigraphy, making spare doses readily available to perform milk scans.

From our results, none of the study participants showed liver, spleen, or bone marrow uptake, increasing the sensitivity and accuracy of reporting abnormalities. We also showed that  $^{99m}\text{Tc}$  nanocolloid as a milk scan agent can identify patients with GER, esophageal dysmotility, and PA. Unfortunately, we could not compare our findings with any in the literature; despite a detailed literature search, we could not find studies where  $^{99m}\text{Tc}$  nanocolloid was used to perform milk scans.

The gold standard for measuring GE is scintigraphy using radiolabeled test meals [7]. One disadvantage of the technique, however, is that GE may be influenced by many factors such as age, sex, patient position, technique of data acquisition, type, and volume of the administered meal [5]. Our findings showed that the mean GE rate of  $^{99m}\text{Tc}$  nanocolloids was significantly faster than that of  $^{99m}\text{Tc}$  tin colloid. However, these measurements were not performed on the same patient, and even though we could select patients with normal GE values using the same protocol, we could not match the age and sex in these patients. The type of milk used (breast milk or formula feed) and volume were also different for both groups. These confounding factors might have affected our results. In addition to this, the number of patients in the study was not robust enough to obtain statistically significant results. We, therefore, recommend larger prospective studies comparing both tracers in the same patient to conclude whether the GE rates of both tracers are different. If this is the case, then the cutoff values used for  $^{99m}\text{Tc}$  tin or sulfur colloid cannot be used for  $^{99m}\text{Tc}$  nanocolloid. In our facility, the normal GE level for children at 2 h after ingestion of  $^{99m}\text{Tc}$  tin colloid-radiolabeled milk is more than 65%.

## Conclusion

The  $^{99m}\text{Tc}$  nanocolloid is technically a suitable alternative to the  $^{99m}\text{Tc}$  sulfur colloid to perform milk scans. It can be used during erratic supplies of the conventional agent and can be cost effective in facilities that use it routinely for sentinel lymph node mapping, lymphoscintigraphy, and bone marrow studies. Larger prospective studies comparing the GE rates of the two radiotracers in consecutive referred children might be needed. However, the most 'accurate' comparison, which is use of the two radiotracers

in the same individual at two different time points, may not be acceptable for ethical approval.

## Acknowledgements

### Conflicts of interest

There are no conflicts of interest.

## References

- Krausz Y, Maayan C, Faber J, Marciano R, Mogle P, Wynchank S. Scintigraphic evaluation of esophageal transit and gastric emptying in familial dysautonomia. *Eur J Radiol* 1994; **18**:52–56.
- Malmud LS, Fisher RS. The evaluation of gastroesophageal reflux before and after medical therapies. *Semin Nucl Med* 1981; **11**:205–215.
- Heyman S. Esophageal scintigraphy (milk scans) in infants and children with gastroesophageal reflux. *Radiology* 1982; **144**:891–893.
- Bar-Sever Z. Scintigraphic evaluation of gastroesophageal reflux and pulmonary aspiration in children. *Semin Nucl Med* 2017; **47**:275–285.
- Chen W, Codreanu I, Yang J, Li G, Servaes S, Zhuang H. Tube feeding increases the gastric-emptying rate determined by gastroesophageal scintigraphy. *Clin Nucl Med* 2013; **38**:962–965.
- Othman S. Gastroesophageal reflux studies using milk in infants and children: the need for multiple views. *Nucl Med Commun* 2011; **32**:967–971.
- Knight LC. Update on gastrointestinal radiopharmaceuticals and dosimetry estimates. *Semin Nucl Med* 2012; **42**:138–144.
- Ertay T, Dogan AS, Ulker O, Durak H. In vitro evaluation of Tc-99m radiopharmaceuticals for gastric emptying studies. *Mol Imaging Radionucl Ther* 2014; **23**:21–24.
- Agool A, Glaudemans AW, Boersma HH, Dierckx RA, Vellenga E, Slart RH. Radionuclide imaging of bone marrow disorders. *Eur J Nucl Med Mol Imaging* 2011; **38**:166–178.
- De Hullu JA, Doting E, Piers DA, Hollema H, Aalders JG, Koops HS, et al. Sentinel lymph node identification with technetium-99m-labeled nanocolloid in squamous cell cancer of the vulva. *J Nucl Med* 1998; **39**:1381–1385.
- Jimenez IR, Roca M, Vega E, Garcia ML, Benitez A, Bajen M, et al. Particle sizes of colloids to be used in sentinel lymph node radiolocalization. *Nucl Med Commun* 2008; **29**:166–172.
- Campanozzi A, Boccia G, Pensabene L, Panetta F, Marseglia A, Strisciuglio P, et al. Prevalence and natural history of gastroesophageal reflux: pediatric prospective survey. *Pediatrics* 2009; **123**:779–783.
- Nelson SP, Chen EH, Syniar GM, Christoffel KK. Prevalence of symptoms of gastroesophageal reflux during infancy. A pediatric practice-based survey. Pediatric Practice Research Group. *Arch Pediatr Adolesc Med* 1997; **151**:569–572.
- Nelson SP, Chen EH, Syniar GM, Christoffel KK. One-year follow-up of symptoms of gastroesophageal reflux during infancy. Pediatric Practice Research Group. *Pediatrics* 1998; **102**:E67.
- Vandenplas Y, Rudolph CD, Di Lorenzo C, Hassall E, Liptak G, Mazur L, et al. Pediatric gastroesophageal reflux clinical practice guidelines: joint recommendations of the North American Society for Pediatric Gastroenterology, Hepatology, and Nutrition (NASPGHAN) and the European Society for Pediatric Gastroenterology, Hepatology, and Nutrition (ESPGHAN). *J Pediatr Gastroenterol Nutr* 2009; **49**:498–547.
- Thomas EJ, Kumar R, Dasan JB, Bal C, Kabra SK, Malhotra A. Prevalence of silent gastroesophageal reflux in association with recurrent lower respiratory tract infections. *Clin Nucl Med* 2003; **28**:476–479.
- Heyman S, Kirkpatrick JA, Winter HS, Treves S. An improved radionuclide method for the diagnosis of gastroesophageal reflux and aspiration in children (milk scan). *Radiology* 1979; **131**:479–482.