

Double orifice mitral valve: A rare cause of isolated severe congenital mitral regurgitation

Himanshu Pratap¹, Amol Gupta², Pradipta Kumar Acharya³, Viresh Mahajan²

¹Department of Pediatric Cardiac Surgery, Asian Institute of Medical Sciences, Faridabad, Haryana, India, ²Department of Pediatric Cardiology, Asian Institute of Medical Sciences, Faridabad, Haryana, India, ³Department of Pediatric Cardiac Intensive Care, Asian Institute of Medical Sciences, Faridabad, Haryana, India

ABSTRACT

Double orifice mitral valve (DOMV) is a rare congenital anomaly of the mitral valve apparatus consisting of an accessory bridge of fibrous tissue, which partially or completely divides the mitral valve into two orifices. It usually occurs as an associated lesion. Encountering a DOMV as an isolated finding meriting intervention is indeed rare. We, here, report a case of “complete bridging type DOMV” occurring as an isolated entity and presenting as severe congenital MR requiring surgery.

Keywords: Congenital mitral regurgitation, congenital mitral valve disease, double orifice mitral valve

INTRODUCTION

Double orifice mitral valve (DOMV) is a rare congenital anomaly of the mitral valve apparatus consisting of an accessory bridge of fibrous tissue, which partially or completely divides the mitral valve into two orifices. It was first described in 1876.^[1] Functionally, the mitral valve may behave normally or result in mitral regurgitation (MR) or stenosis.

The classification of DOMV, based on echocardiographic imaging, was proposed by Trowitzsch *et al.*,^[2] which divided DOMV into three different types: (1) hole type (accessory orifice surrounded by leaflet tissue that may have a chordal ring), (2) complete bridging (fibrous bridge in the plane of the mitral valve sails, dividing the mitral valve opening into two parts that may be equal or unequal), and (3) incomplete bridging (small strand of fibrous tissue connects only the tips of the anterior and posterior leaflets).

DOMV rarely occurs as an isolated anomaly; rather, it is commonly associated with a variety of cardiac anomalies

such as atrioventricular septal defects, coarctation of the aorta, bicuspid aortic valve, sinus venosus atrial septal defect, ventricular septal defect, patent ductus arteriosus, hypoplastic left heart syndrome, double orifice tricuspid valve, tetralogy of Fallot, Ebstein’s anomaly, and Shone’s complex.^[3,4] In the largest reported series of DOMV, only 3 of the 46 patients were found to have isolated DOMV, and in none of the three, it was clinically significant to warrant surgical intervention.^[5]

Encountering a DOMV as an isolated finding meriting intervention is indeed rare. We, here, report a case of “complete bridging type DOMV” occurring as an isolated entity and presenting as severe congenital MR requiring surgery.

CASE REPORT

Our patient was a 10-year-old female who presented to us with complaints of cough, inadequate weight gain, dyspnea on exertion, and easy fatigability. She had

This is an open access journal, and articles are distributed under the terms of the Creative Commons Attribution-NonCommercial-ShareAlike 4.0 License, which allows others to remix, tweak, and build upon the work non-commercially, as long as appropriate credit is given and the new creations are licensed under the identical terms.

For reprints contact: reprints@medknow.com

How to cite this article: Pratap H, Gupta A, Acharya PK, Mahajan V. Double orifice mitral valve: A rare cause of isolated severe congenital mitral regurgitation. *Ann Pediatr Card* 2020;13:174-6.

Access this article online

Quick Response Code:



Website:

www.annalspc.com

DOI:

10.4103/apc.APC_133_19

Address for correspondence: Dr. Himanshu Pratap, Department of Pediatric Cardiac Surgery, Asian Institute of Medical Sciences, Faridabad, Haryana, India. E-mail: drhpratap@gmail.com

Submitted: 15-Sep-2019

Revised: 15-Oct-2019

Accepted: 06-Dec-2019

Published: 14-Feb-2020

been evaluated before elsewhere and was diagnosed to have severe MR. Echocardiography at our center revealed the following: situs solitus, levocardia, normal systemic and pulmonary venous drainage, intact interatrial and interventricular septum, and concordant atrioventricular and ventriculoarterial connections. There was severe MR, with a suspicion of DOMV; further, the mitral leaflets were mildly thickened and the annulus was dilated to 40 mm. Left atrium (LA) and left ventricles were dilated. There was moderate tricuspid regurgitation (TR) with peak gradient of 48 mm of mercury (mmHg). Left ventricular (LV) systolic function was moderately depressed and was measured to be 33%. Note was made of mild noncompaction of the left ventricle. A chest X-ray was done that revealed moderate cardiomegaly [Figure 1].

After counseling, the patient was taken up for surgery. The mitral valve was approached transseptally. At operation, the diagnosis of DOMV was confirmed [Figure 2] and a note was also made of significantly dilated LA.

One of the orifices of the DOMV corresponded to the expected mitral size, and thus, the accessory opening was closed by two layers of monofilament sutures. The left atrial appendage was closed from within by a circumferential suture, and LA reduction was done by a running plicating suture between the right and left pulmonary veins. Limited annuloplasty was done using a strip of Polytetrafluoroethylene (PTFE) felt. On saline testing, slight leak of fluid was noted; but, the leaflets were felt to have decent excursions. Given the age of the patient, the leak was accepted.

She was extubated on the first postoperative day (POD) to oxygen by face mask. In view of increased work of breathing, a BiPAP mask was continued for the next 3 days, graduating to room air on 5th POD. Inotropic support was in the form of adrenalin (0–3 days) and dobutamine (0–5 days) in view of ventricular dysfunction. Enalapril was added for its afterload-reducing effect.

She was shifted out to ward on 6th POD and discharged from the hospital on 9th POD. Her pre-discharge echo showed good mitral valve opening and an annulus of 28.5 mm, there was mild flow acceleration across it with a mean gradient of 3 mmHg, there was mild to moderate MR, and TR gradient was 37 mmHg with a mild LV dysfunction of 43% [Figure 3].

She remained asymptomatic at 2 weeks after discharge and has been advised to remain in follow-up.

DISCUSSION

The term DOMV was introduced by Rosenberg and Roberts.^[6] In this anomaly, the valve leaflets of the two orifices are supported by chordae tendineae, thus distinguishing it from fenestrations in the valve

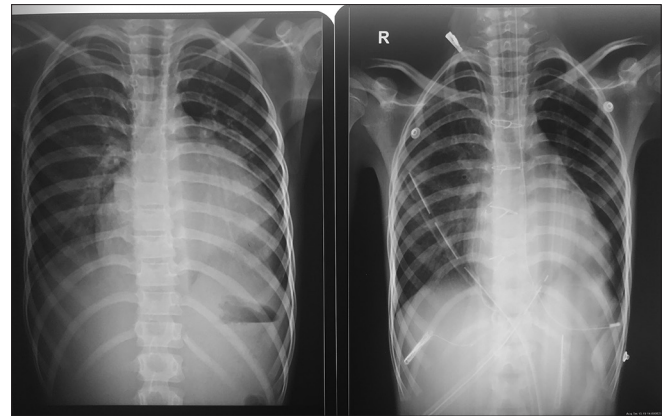


Figure 1: Pre- and post-operative chest X-ray showing the cardiac contour

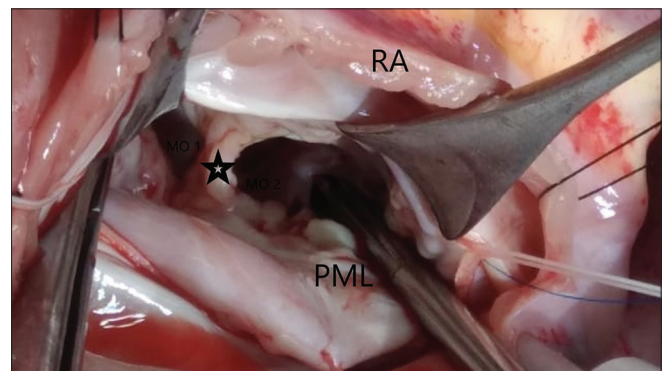


Figure 2: Intraoperative picture showing two orifices (MO 1 AND MO 2) of mitral valve separated by a bridge of tissue (marked by star). The cut edge of the right atrium and the posterior mitral annulus labeled for clarity

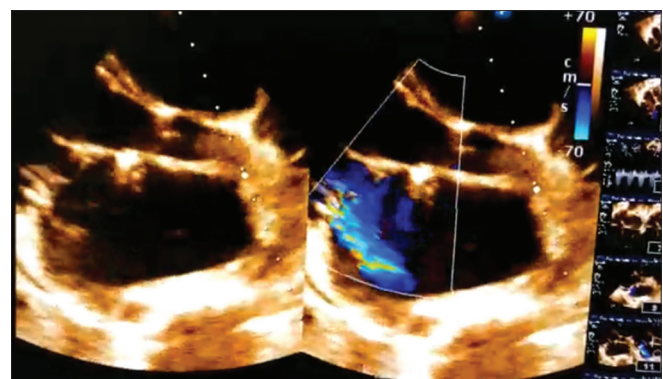


Figure 3: Still image of parasternal long-axis view showing mitral inlet

leaflets, which lack chordal support. Even though more than 200 cases have been reported, a DOMV is usually detected as an associated finding.^[7] Patients with DOMV unassociated with other cardiac anomalies are very rare and usually live a healthy life, although some of them may develop acquired mitral stenosis or MR.^[8]

No intervention is necessary if the mitral valve is competent without mitral stenosis or MR. The type of

operation should depend on the anatomic abnormality in the mitral valve apparatus. In many patients, the valve may be amenable to repair and reconstruction procedures.

Perhaps because it is infrequently encountered, multiple strategies have been adopted in the correction of DOMV ranging from Balloon mitral valvotomy (BMV)^[9,10] to valve repair to even mitral valve replacement (MVR).^[11,12] Whereas BMV and MVR are usually restricted to specific subgroups of patients – pliable stenotic valve and older patients, respectively – variety of repair techniques have been reported in the literature.

The various techniques used to treat a DOMV started with “division of bridging tissue and cleft suture” in perhaps the first reported case of DOMV where it was a part of endocardial cushion defect.^[13] The other techniques include, to name a few, “division of the fibrous bar and valve reconstruction by cleft suture and leaflet expansion,”^[14] use of artificial chordae,^[8] and “edge-to-edge” repair.^[15]

In our case, we discovered that one of the larger orifices was of adequate size for the given weight and age of our patient, and also, we were aware of the opinion by Baño-Rodrigo *et al.* associates that the tissue bridge is responsible for keeping the valve competent^[16] and hence should not be divided; therefore, we proceeded with closure of accessory orifice supplemented by mitral valve annuloplasty.

In short, valvular heart disease remains a complex issue in pediatric population, and given the long remaining life span, a conservative approach to salvage a valve merits consideration. DOMV appears amenable to repair, although if it will last, at least through the most productive years of a life, remains to be seen in follow-up.

Declaration of patient consent

The authors certify that they have obtained all appropriate patient consent forms. In the form the patient(s) has/have given his/her/their consent for his/her/their images and other clinical information to be reported in the journal. The patients understand that their names and initials will not be published and due efforts will be made to conceal their identity, but anonymity cannot be guaranteed.

Financial support and sponsorship

Nil.

Conflicts of interest

There are no conflicts of interest.

REFERENCES

1. Greenfield W. Double mitral valve. *Trans Pathol Soc Lond* 1876;27:128-9.
2. Trowitzsch E, Bano-Rodrigo A, Burger BM, Colan SD, Sanders SP. Two-dimensional echocardiographic findings in double orifice mitral valve. *J Am Coll Cardiol* 1985;6:383-7.
3. Linka AZ, Fatio R, Jost CA. Double orifice mitral valve. *Heart* 2000;84:244.
4. Taksande A, Goutami V, Thomas E. Double orifice mitral valve associated with ventricular septal defect in an infant: Case report. *Images Paediatr Cardiol* 2011;13:6-9.
5. Zalstein E, Hamilton R, Zucker N, Levitas A, Gross GJ. Presentation, natural history, and outcome in children and adolescents with double orifice mitral valve. *Am J Cardiol* 2004;93:1067-9.
6. Rosenberg J, Roberts WC. Double orifice mitral valve. Study of the anomaly in two calves and a summary of the literature in humans. *Arch Pathol* 1968;86:77-80.
7. Anwar AM, McGhie JS, Meijboom FJ, Ten Cate FJ. Double orifice mitral valve by real-time three-dimensional echocardiography. *Eur J Echocardiogr* 2008;9:731-2.
8. Tomita Y, Yasui H, Tominaga R. Mitral valve repair for isolated double-orifice mitral valve with torn chordae. *Ann Thorac Surg* 1997;64:1831-4.
9. Kim MH, Cha KS, Kim JS, Hung JS, Lau KW. Successful inoue balloon mitral commissurotomy in double-orifice mitral stenosis. *Catheter Cardiovasc Interv* 2000;49:200-3.
10. Mercer JL, Tubbs OS. Successful surgical management of double mitral valve with subaortic stenosis. *J Thorac Cardiovasc Surg* 1974;67:440-2.
11. Romano MM, Menardi AC, Almeida-Filho OC, Vicente WV, Evora PR. Double-orifice mitral valve: An educational presentation. *Braz J Cardiovasc Surg* 2019;34:377-9.
12. Kron J, Standerfer RJ, Starr A. Severe mitral regurgitation in a woman with a double orifice mitral valve. *Br Heart J* 1986;55:109-11.
13. Reed GE, Cortes LE, Clauss RH, Reppert EH. The surgical repair of duplication of the mitral orifice. *Ann Thorac Surg* 1970;9:81-5.
14. Amano J, Suzuki A. Surgical treatment of duplication of the mitral valve. *J Cardiovasc Surg (Torino)* 1986;27:323-7.
15. Oda T, Kono T, Akaiwa K, Nakamura K. Edge-to-edge repair for mitral regurgitation associated with isolated double-orifice mitral valve. *Interact Cardiovasc Thorac Surg* 2018;26:529-31.
16. Baño-Rodrigo A, van Praagh S, Trowitzsch E, van Praagh R. Double-orifice mitral valve: A study of 27 postmortem cases with developmental, diagnostic and surgical considerations. *Am J Cardiol* 1988;61:152-60.