

A Korean Patient with Lattice Corneal Dystrophy Type IV with Leu527Arg Mutation in the *TGFBI* Gene

Jinsun Kim¹, Kyung A Lee², Eung Kweon Kim^{1,3}, Hyung Keun Lee^{1,3}

¹*Institute of Vision Research, Department of Ophthalmology, Yonsei University College of Medicine, Seoul, Korea*

²*Department of Clinical Diagnosis, Yonsei University College of Medicine, Seoul, Korea*

³*Corneal Dystrophy Research Institute, Yonsei University, Seoul, Korea*

An 87-year-old woman visited our clinic for a scheduled cataract surgery. At the time of preoperative evaluation, slit lamp examination showed lattice-shaped and granular deposits with asymmetrical patterns in the stroma of both corneas. Genomic DNA samples of the patient, amplified by polymerase chain reaction, showed a single nucleotide substitution, c. 1580T>G (p.L527R), in the transforming growth factor- β -induced *TGFBI* gene. We also found two additional SNP mutations, c.1620T>C (p.F540F) and c.1678+23G>A, along with the well-known L527R mutation. This is the first report of lattice corneal dystrophy type IV with an L527R mutation outside of Japan, and could challenge the idea that L527R is caused by a mutation from a single Japanese ancestor.

Key Words: Hereditary corneal dystrophies, Transforming growth factor beta

Recent advances have allowed us to understand corneal dystrophies on a basic molecular level, and several studies have reported specific mutations in the *TGFBI* gene showing various phenotypes [1]. Among these are lattice corneal dystrophy (LCD), granular corneal dystrophy, Thiel-Behnke corneal dystrophy, Reis-Bucklers corneal dystrophy, and Cogan's dystrophy [2,3].

LCD is one of the most common corneal disorders and is characterized by lineal stromal amyloid depositions that usually present bilaterally and symmetrically. Among the LCD subtypes, type IV is extremely rare, and only a few cases of this subtype have been discovered in the Japanese [4] and Indian populations [3], and one case in the Italian

population [2]. We recently discovered a Korean LCD type IV patient, and therefore we are hereby reporting the first Korean case of LCD type IV, confirmed by DNA sequencing and clinical examination.

Case Report

An 87-year-old woman visited our clinic for a scheduled cataract surgery. At the time of preoperative evaluation, mild localized semitransparent opacity was noted in both corneas. The opacity showed lattice-shaped, granular deposits with asymmetrical patterns in the stroma (Fig. 1). The right eye was more severely affected, showing nodulo-linear amyloid deposits located mainly in the anterior stroma; the left eye showed less linear and macular opacity. The patient demonstrated a good visual outcome after the surgery, with a best-corrected visual acuity of 0.8 in both eyes.

Genomic DNA samples from the patient were extracted from peripheral leukocytes using the Easy-DNA Kit (Invitrogen, Carlsbad, CA, USA). Polymerase chain reaction

Received: December 1, 2012 Accepted: December 13, 2012

Corresponding Author: Hyung Keun Lee, MD. Department of Ophthalmology, Gangnam Severance Hospital, #211 Eonju-ro, Gangnam-gu, Seoul 135-720, Korea. Tel: 82-2-2019-3444, Fax: 82-2-3463-1049, E-mail: shadik@yuhs.ac

This study was previously presented as a poster at the 105th Annual Meeting of The Korean Ophthalmological Society.

© 2014 The Korean Ophthalmological Society

This is an Open Access article distributed under the terms of the Creative Commons Attribution Non-Commercial License (<http://creativecommons.org/licenses/by-nc/3.0/>) which permits unrestricted non-commercial use, distribution, and reproduction in any medium, provided the original work is properly cited.

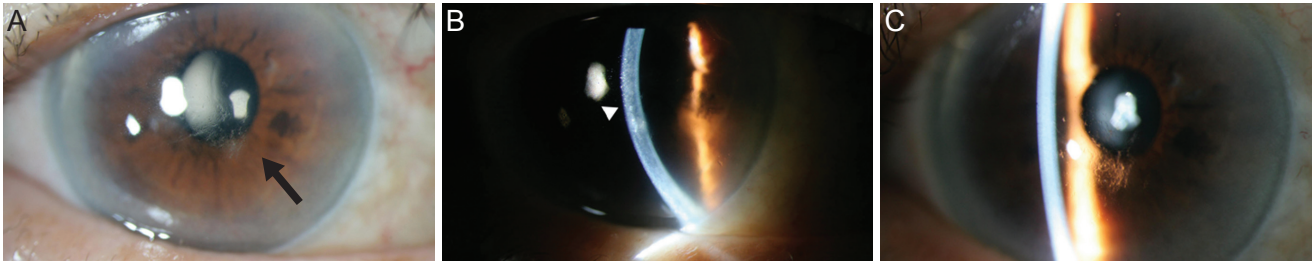


Fig. 1. Corneal photographs of lattice corneal dystrophy type IV patients. (A) The right eye was the more severely affected eye, displaying noduloliner amyloid deposits (arrow). (B) The deposits are mainly located in anterior stroma (arrowhead). (C) The left eye showed less linear and macular opacity than the right.

Table 1. Primers for *TGFBI* gene

Exon	Primer sequence (5'→3')	Product size (bp)
12	<i>TGFBI</i> ex12 F AGCCTGGAATCACTC CCTCT	396
	<i>TGFBI</i> ex12 R GATGTGCCAACTGTTTGCTG	396

was performed on this genomic DNA with specific primers for the *TGFBI* gene (Table 1); the results showed a Leu527Arg mutation in the *TGFBI* gene (Fig. 2A). In addition to the Leu527Arg mutation, two more single-nucleotide polymorphisms (SNPs) were also identified: a T>C variation at cDNA position 1620 resulting in Phe540Phe and a G>A variation at cDNA position 1678+23 (Fig. 2B and 2C).

The patient's only family members, her son and granddaughter, did not show any corneal stromal manifestations. They also did not have any known mutations in the *TGFBI* gene specific for LCD type IV, though both showed the T>C variation at cDNA position 1620 and the G>A variation at cDNA position 1678+23, just as in the present case.

Discussion

LCD type IV was first reported in 1998 [4]. The LCD type IV patients with L527R are characterized by asymmetric corneal opacities, sporadic occurrences, and late onset [5]. In the present case, because visual impairment was not directly related to the cornea, visual acuity was improved after cataract surgery. We could not identify the etiology of the condition because the patient's lesion did not cause her visual symptoms.

Similar to previous LCD type IV cases, the patient in this report also showed only mild clinical manifestation without subjective symptoms. We assert that the novelty of this case is two-fold. Firstly, we found two novel SNP mu-

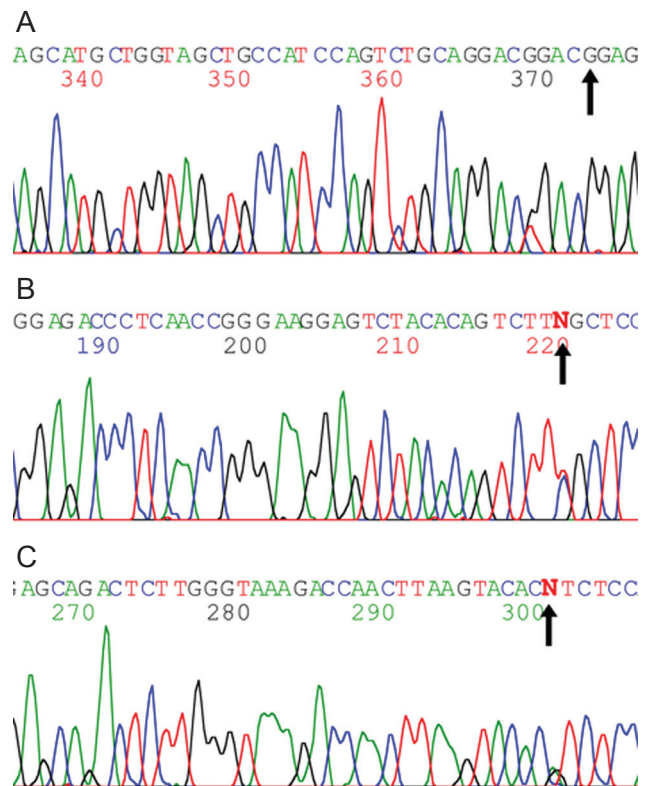


Fig. 2. Open-frame sequencing of the *TGFBI* gene from the patient. Direct sequencing of polymerase chain reaction products corresponding to exon 12 of *TGFBI*. (A) Heterozygous mutation, c.1580T>G (arrow) was detected in the *TGFBI* gene. (B) Heterozygous c.1620T>C p.Phe540Phe (rs4669) was detected (arrow). (C) Heterozygous c.1678+23G>A (rs2072239) was detected (arrow).

tations in addition to the well-known L527R mutation; these were also found in the patient's family members.

Since the effects of these SNP mutations on the development and progression of LCD type IV remain uncertain, the role of these mutations should be investigated in future studies.

Secondly, since the initial report of the L527R mutation in the *BIGH3* gene [4], all LCD type IV patients with an L527R mutation have been found exclusively in the Japanese population. This has led Fukuoka et al. [5] to report that the L527R SNP mutation might have been caused by a founder mutation in a single Japanese ancestor. To our knowledge, present case is the first report of an L527R mutation outside Japan, and it could challenge the idea that L527R is the product of a Japanese founder effect [5].

Lastly, because the clinical manifestations of LCD type IV are sporadic and extremely mild with subtle subjective symptoms, only a few cases have been detected and reported.

In summary, the patient in this report showed typical asymmetric noduloliner stromal opacity in both corneas, and an L527R mutation in the *TGFBI* gene with two novel SNP mutations. This is the first report of the L527R mutation in Korea, as well as outside Japan, challenging the idea that L527R was caused by a founder mutation in a single Japanese ancestor.

Conflict of Interest

No potential conflict of interest relevant to this article was reported.

References

1. Munier FL, Korvatska E, Djemai A, et al. Kerato-epithelin mutations in four 5q31-linked corneal dystrophies. *Nat Genet* 1997;15:247-51.
2. Munier FL, Frueh BE, Othenin-Girard P, et al. BIGH3 mutation spectrum in corneal dystrophies. *Invest Ophthalmol Vis Sci* 2002;43:949-54.
3. Chakravarthi SV, Kannabiran C, Sridhar MS, Vemuganti GK. TGFBI gene mutations causing lattice and granular corneal dystrophies in Indian patients. *Invest Ophthalmol Vis Sci* 2005;46:121-5.
4. Fujiki K, Hotta Y, Nakayasu K, et al. A new L527R mutation of the betaIGH3 gene in patients with lattice corneal dystrophy with deep stromal opacities. *Hum Genet* 1998; 103:286-9.
5. Fukuoka H, Kawasaki S, Yamasaki K, et al. Lattice corneal dystrophy type IV (p.Leu527Arg) is caused by a founder mutation of the TGFBI gene in a single Japanese ancestor. *Invest Ophthalmol Vis Sci* 2010;51:4523-30.