

Large Capsulorhexis Related Uveitis-Glaucoma-Hyphema Syndrome Managed by Intraocular Lens Implant Exchange and Gonioscopy Assisted Transluminal Trabeculotomy

Mohammad Reza Razeghinejad^{1,2}, MD; Shane J. Havens³, MD

¹*Glaucoma Service, Wills Eye Hospital, Philadelphia, PA, USA*

²*Poostchi Eye Research Center, Shiraz University of Medical Sciences, Shiraz, Iran*

³*Truhlsen Eye Institute, University of Nebraska Medical Center, Omaha, NE, USA*

ORCID:

Mohammad Reza Razeghinejad: <https://orcid.org/0000-0001-7961-8425>

Abstract

Purpose: To report a case of uveitis-glaucoma-hyphema syndrome (UGHS) secondary to a large capsulorhexis with an intracapsular intraocular lens (IOL) managed with IOL exchange and gonioscopy assisted transluminal trabeculotomy (GATT).

Case Report: A 73-year-old male patient presented with UGHS of the right eye in the setting of an intracapsular single-piece acrylic IOL with circumferential optic and partial haptics exposure due to a large capsulorhexis. In lieu of the patient's uncomplicated surgical history, subtle symptoms, and clinical findings, the diagnosis and referral was delayed until intraocular pressure reached a peak of 50 mmHg with recurrent anterior chamber cells. The patient underwent combined IOL exchange with placement of a 3-piece sulcus IOL and GATT, which finally resolved the UGHS.

Conclusion: With respect to the increasing prevalence of intracapsular single-piece IOL implantation, it is important to recognize UGHS and thus fashion proper sized capsulorhexis to prevent this vision threatening complication. GATT may be considered to be one of the glaucoma surgeries combined with the IOL surgical procedures in UGHS.

Keywords: IOL-exchange; Iris Chafing; Trabeculotomy; Uveitis-Glaucoma-Hyphema Syndrome

J Ophthalmic Vis Res 2019; 14 (2): 215-218

Correspondence to:

Mohammad Reza Razeghinejad, MD. 840 Walnut Street, Suite 1140, Wills Eye Hospital, Philadelphia, PA 19107, USA.

E-mail: razeghinejad@yahoo.com

Received: 04-06-2017

Accepted: 15-03-2018

Video available on: www.jovr.org

Access this article online

Quick Response Code:



Website:

www.jovr.org

DOI:

10.4103/jovr.jovr_122_17

INTRODUCTION

The Uveitis-Glaucoma-Hyphema Syndrome (UGHS) or "Ellingson" syndrome was first reported as a

This is an open access journal, and articles are distributed under the terms of the Creative Commons Attribution-NonCommercial-ShareAlike 4.0 License, which allows others to remix, tweak, and build upon the work non-commercially, as long as appropriate credit is given and the new creations are licensed under the identical terms.

For reprints contact: reprints@medknow.com

How to cite this article: Razeghinejad MR, Havens SJ. Large capsulorhexis related uveitis-glaucoma-hyphema syndrome managed by intraocular lens implant exchange and gonioscopy assisted transluminal trabeculotomy. *J Ophthalmic Vis Res* 2019;14:215-8.

complication of iris chafing with a first generation anterior chamber intraocular lenses (IOLs),^[1] UGHS is now more commonly seen with posterior chamber IOL implants.^[2-6] UGHS may present as the classic triad of anterior uveitis, glaucoma, and hyphema, but it has a wide range of clinical manifestations including anterior uveitis, pigment dispersion, increased intraocular pressure (IOP), and micro- or macroscopic hyphema.^[7] Generally developing years after cataract surgery, it has also been reported immediately one day after cataract surgery.^[2,3,8] UGHS generally causes an intermittent blurred vision due to intraocular hemorrhage and inflammation, elevated IOP, and transient corneal edema. Repeated elevated IOP attacks can result in glaucomatous optic nerve and corneal endothelial damage. The mechanism of glaucoma includes blockage of outflow by inflammatory cells and fibrin, peripheral anterior synechia formation, hyphema, and ghost cell glaucoma from an associated vitreous hemorrhage.^[9]

Classically, it involves a single-piece acrylic IOL placed partially or completely in the ciliary sulcus. Recent UGHS cases have been reported while setting the intracapsular IOL with additional caveats, including capsular tear at the equator of the lens capsule,^[10] pseudophacodonesis and anterior rotation of ciliary processes,^[4] anterior bowing of the haptic related to IOL deformation during loading,^[5] displaced haptic secondary to iridociliary cyst,^[11] and reverse pupillary block.^[2,3] We report a case involving a myopic UGHS patient during the intracapsular IOL setting with a large capsulorhexis, managed with IOL exchange and gonioscopy assisted transluminal trabeculotomy (GATT). GATT is a minimally invasive, modified trabeculotomy, glaucoma surgery performed ab-internally.^[12]

CASE REPORT

A 73-year-old male patient was referred for uveitic glaucoma evaluation for recurrent anterior uveitis and concurrent IOP elevation (50 mmHg) in the right eye since three days, with history of uncomplicated phacoemulsification surgery of both eyes 14 months back.

The IOP improved with daily use of three topical anti-glaucoma medications and difluprednate. The examination revealed Krukenberg spindles bilaterally without corneal edema or keratic precipitate, iris transillumination defects in the right eye [Figure 1], and rare anterior chamber cells. Posterior chamber IOL was noted bilaterally, but poor pupil dilation hindered visualization of the optic edge and haptics. Gonioscopy before and after dilation was open to ciliary body band with '3+' trabecular meshwork pigment bilaterally. Fundoscopy was unremarkable other than a slight cup/disc asymmetry (0.4 in the right eye and 0.2 in the left). Automated perimetry revealed full visual fields

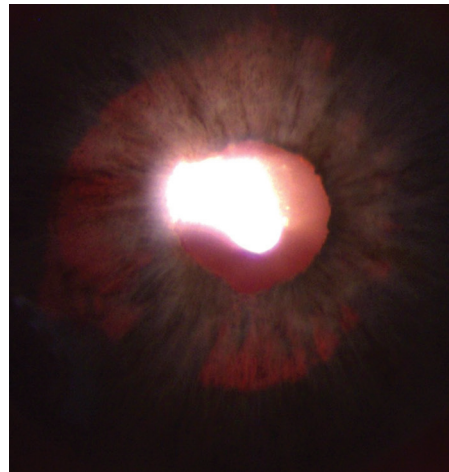


Figure 1. Iris transillumination corresponding to the intraocular lens optic.

bilaterally, and normal optical coherence tomography results of the optic nerve and macula. Ultrasound biomicroscopy demonstrated the temporal haptic to largely be within the ciliary sulcus with posterior iris contact in the right eye and slight posterior bowing of the iris. UGHS related to temporal haptic sulcus displacement and iris-IOL chafing was suspected. Three weeks later, the patient returned with blurred vision, IOP 32 mmHg, and anterior chamber cells and flare in the right eye. In an effort to reduce the potential need for IOP lowering therapy and address possible permanent decreased conventional aqueous outflow, IOL exchange and GATT were performed.

Intraoperatively, iris hooks were used to provide adequate visualization of the IOL and capsular complex. A large capsulorhexis (7.0 mm diameter) was noted with circumferential optic exposure and near complete exposure of the temporal haptic and partial nasal haptic exposure. Old hemorrhages layered in the inferior and temporal capsular recess (surgical video) confirmed UGH syndrome. After explanting the IOL, a three-piece IOL was guided into the sulcus, with uncomplicated GATT completed using a 5-0 Prolene suture.

Six months postoperatively, the patient showed visual acuity of 20/20, controlled IOP with bimatoprost replacing the previous medications, and no recurrent anterior chamber inflammation. Laser iridotomy was completed to address posterior iris bowing and possible iris-IOL optic contact.

DISCUSSION

Temporary vision loss in UGHS can easily be mistaken for other issues such as amaurosis fugax, a common cause of transient monocular vision loss. The key differentiation between UGHS and amaurosis fugax begins with thorough history [Table 1] followed by a complete eye examination, including gonioscopy. The

Table 1. Clinical signs and symptoms of amaurosis fugax and uveitis glaucoma hyphema syndrome

	Amaurosis fugax	UGH syndrome
Onset	Sudden (seconds)	Gradual (minutes)
Character of visual change	Dark curtain passing across visual field	Gradual cloudiness of vision±erythroptasia
Visual recovery	Rapid (seconds to minutes)	Slow (hours to days)
Complete loss of light perception	Present in at least one sector of visual field	Never
Associated pain	Never	± Pain in affected eye

presence of fresh or clotted blood in the inferior anterior chamber angle or in the sulcus detected in gonioscopy after pupil dilation can be diagnostic,^[10] along with anterior segment imaging.^[13] However, these imaging modalities may not be able to show the exact cause of the UGHS in cases with intracapsular IOL placement. Instead, direct observation during a surgical intervention or the endocyclophotocoagulation probe camera could help.^[4]

The cause of the UGHS in our case was a large capsulorhexis. With capsulorhexis >6 mm (the usual optic size of the IOLs), the anterior capsule can fuse to the posterior capsule and continue to contract and migrate behind the optic while the haptics remain in the bag, causing an anterior optic shift, myopic shift, and possible iris-IOL contact. In a study comparing the effect of the capsulorhexis size on the anterior chamber depth, the latter was found to be deeper in eyes with smaller sized capsulorhexis.^[14] Ideally, the entire optic shows circumferential coverage with the anterior capsulorhexis edge (ideal size of rhexis 5.5 mm).

Initially, medical management was appropriate in controlling the inflammation and IOP. Laser iridotomy could also play a role in cases that demonstrated significant posterior iris bowing and reverse pupillary block.^[2,3] However, the definitive treatment involved explantation or repositioning of the malpositioned IOL.^[6,8,15] Miotics can also be used to tighten the iris in reverse papillary block cases; however, since most reported cases of UGHS are usually myopic, it may increase their risk of retinal detachment. As a rule, all single piece IOLs in the sulcus need to be explanted and exchanged for a three-piece IOL designed for the sulcus, if capsular support is sufficient. If the optic of the three-piece sulcus lens has a square edge, prolapsing the optic behind the capsular opening may reduce the risk of recurrent UGHS. Following explantation, the visual rehabilitation options included placement of three-piece IOL in the sulcus, posterior chamber fixation of the lens to the iris or sclera, an anterior chamber lens, iris claw lens, or aphakic contact lens rehabilitation. To prevent any further damage to the compromised trabecular meshwork, it is wise to consider avoiding placing the anterior chamber IOL. Scleral-fixated IOLs are prone to IOL tilt and anterior positioning,^[16] which potentially increases the risk for recurrent iris contact and UGHS.^[3] Iris fixation of the IOL may not be a good

option because the iris stroma is often atrophic from prior inflammation and chaffing.

Although the definite treatment of UGHS is eliminating the IOL-uveal tissue chaffing, ongoing glaucoma medical therapy or even glaucoma surgery may be required in some due to impaired aqueous flow through the trabecular meshwork. If moderate to severe visual field loss is present and the patient is on maximal tolerated medical therapy with inadequate IOP control, a combined incisional glaucoma surgery (trabeculectomy/tube) should be considered.^[5] Since our patient had mild optic nerve damage, we performed a combined GATT procedure instead of trabeculectomy/tube, which are associated with late complications not reported with GATT.^[12] The ability of bypassing the trabecular meshwork without violating the conjunctiva and sclera is a major advantage of GATT that does not interfere with future filtration surgery. The GATT procedure combined with IOL exchange may be considered in management of mild to moderate glaucoma stages in UGHS.

Declaration of Patient Consent

The authors certify that they have obtained all appropriate patient consent forms. In the form the patient(s) has/have given his/her/their consent for his/her/their images and other clinical information to be reported in the journal. The patients understand that their names and initials will not be published and due efforts will be made to conceal their identity, but anonymity cannot be guaranteed.

Financial Support and Sponsorship

Nil.

Conflicts of Interest

There are no conflicts of interest.

REFERENCES

1. Ellingson FT. The uveitis-glaucoma-hyphema syndrome associated with the Mark VIII anterior chamber lens implant. *J Am Intraocul Implant Soc* 1978;4:50-53.
2. Itagaki H, Kunikata T, Hiratsuka K, Saito J, Oshika T. Reverse pupillary block associated with pigment dispersion syndrome after in-the-bag intraocular lens implantation. *J Cataract Refract Surg* 2013;39:1925-1928.
3. Singh H, Modabber M, Safran SG, Ahmed, II. Laser iridotomy to

- treat uveitis-glaucoma-hyphema syndrome secondary to reverse pupillary block in sulcus-placed intraocular lenses: Case series. *J Cataract Refract Surg* 2015;41:2215-2223.
4. Zhang L, Hood CT, Vrabc JP, Cullen AL, Parrish EA, Moroi SE. Mechanisms for in-the-bag uveitis-glaucoma-hyphema syndrome. *J Cataract Refract Surg* 2014;40:490-492.
 5. Boutboul S, Letaief I, Lalloum F, Puech M, Borderie V, Laroche L. Pigmentary glaucoma secondary to in-the-bag intraocular lens implantation. *J Cataract Refract Surg* 2008;34:1595-1597.
 6. Sharma A, Ibarra MS, Piltz-Seymour JR, Syed NA. An unusual case of uveitis-glaucoma-hyphema syndrome. *Am J Ophthalmol* 2003;135:561-563.
 7. Magargal LE, Goldberg RE, Uram M, Gonder JR, Brown GC. Recurrent microhyphema in the pseudophakic eye. *Ophthalmology* 1983;90:1231-1234.
 8. John GR, Stark WJ. Rotation of posterior chamber intraocular lenses for management of lens-associated recurring hyphemas. *Arch Ophthalmol* 1992;110:963-964.
 9. Aonuma H, Matsushita H, Nakajima K, Watase M, Tsushima K, Watanabe I. Uveitis-glaucoma-hyphema syndrome after posterior chamber intraocular lens implantation. *Jpn J Ophthalmol* 1997;41:98-100.
 10. Badakere SV, Senthil S, Turaga K, Garg P. Uveitis-glaucoma-hyphaema syndrome with in-the-bag placement of intraocular lens. *BMJ Case Rep* 2016;2016.
 11. Foroozan R, Tabas JG, Moster ML. Recurrent microhyphema despite intracapsular fixation of a posterior chamber intraocular lens. *J Cataract Refract Surg* 2003;29:1632-1635.
 12. Grover DS, Godfrey DG, Smith O, Feuer WJ, Montes de Oca I, Fellman RL. Gonioscopy-assisted transluminal trabeculotomy, ab interno trabeculotomy: Technique report and preliminary results. *Ophthalmology* 2014;121:855-861.
 13. Lima BR, Pichi F, Hayden BC, Lowder CY. Ultrasound biomicroscopy in chronic pseudophakic ocular inflammation associated with misplaced intraocular lens haptics. *Am J Ophthalmol* 2014;157:813-817.e1.
 14. Cekic O, Batman C. The relationship between capsulorhexis size and anterior chamber depth relation. *Ophthalmic Surg Lasers* 1999;30:185-190.
 15. Kohnen T, Kook D. Solving intraocular lens-related pigment dispersion syndrome with repositioning of primary sulcus implanted single-piece IOL in the capsular bag. *J Cataract Refract Surg* 2009;35:1459-1463.
 16. Pavlin CJ, Rootman D, Arshinoff S, Harasiewicz K, Foster FS. Determination of haptic position of transsclerally fixated posterior chamber intraocular lenses by ultrasound biomicroscopy. *J Cataract Refract Surg* 1993;19:573-577.