

## Skin and ear health in a group of English bulldogs in Finland – a descriptive study with special reference to owner perceptions

Riitta T.K. Seppänen\* , Mirja Kaimio†, Kirsti J.M. Schildt†, Liisa Lilja-Maula‡, Heli K. Hyytiäinen‡, Sari Mölsä‡, Mikael Morelius‡, Minna M. Rajamäki‡, Anu K. Lappalainen‡ and Merja Rantala‡

\*Veterinary Teaching Hospital, Faculty of Veterinary Medicine, University of Helsinki, Viikintie 49, 00790 Helsinki, Finland

†Evidensia Tammisto, Evidensia Eläinlääkäripalvelut Oy, Tammiston Kauppatie 29, 01510 Vantaa, Finland

‡Department of Equine and Small Animal Medicine, Faculty of Veterinary Medicine, University of Helsinki, Viikintie 49, 00790 Helsinki, Finland

Correspondence: Riitta T.K. Seppänen, Veterinary Teaching Hospital, Faculty of Veterinary Medicine, University of Helsinki, Viikintie 49, 00790, Helsinki, Finland. E-mail: riitta.t.seppanen@helsinki.fi

**Background** – Dermatological conditions are common in English bulldogs (EBs).

**Hypothesis/Objectives** – This cross-sectional study describes the dermatological health status of a group of EBs and compares the results with owner perceptions and its possible impact on quality of life (QoL). Computed tomographic (CT) findings of the ear canals were compared between EBs and mesaticephalic dogs.

**Animals** – Twenty-seven EBs participating in a health study in Finland.

**Methods and materials** – A QoL questionnaire was completed for EBs with owner-reported clinical signs referable to the skin or ear. Clinical evaluation included recording the Canine Atopic Dermatitis Extent and Severity Index, the Otitis Index Score, false paw pad grading and the presence of interdigital furunculosis. These were summed to form a total clinical score (TCS). The cross-sectional surface areas of the horizontal ear canals were measured from CT images and compared with respective images of 14 mesaticephalic dogs collected from a patient database.

**Results** – All 27 EBs had abnormal findings on dermatological examination, but 37% of the owners had not recognized skin or ear signs. The median QoL score was 5.0 (range 0–12) and correlated with TCS (correlation coefficient = 0.507,  $P < 0.05$ ). English bulldogs had narrower horizontal ear canals than mesaticephalic dogs ( $P < 0.001$ ).

**Conclusions and clinical importance** – All EBs had abnormal dermatological findings that were unnoticed or considered to be of minor significance to the QoL by most owners. Narrow ear canals were common, possibly related to the brachycephalic conformation of the breed.

### Introduction

A variety of dermatological conditions are common in English bulldogs (EBs).<sup>1–5</sup> A cross-sectional study of show EBs reported that all dogs had abnormal findings on dermatological examination and pedal lesions were especially frequent.<sup>3</sup> Pododermatitis is a multifaceted disease complex with a diversity of underlying causes.<sup>2,6–8</sup> A wide variety of skin disorders<sup>2,7</sup> as well as conformational abnormalities of the paws due to obesity<sup>8</sup> or orthopaedic diseases such as osteoarthritis and joint disease<sup>6</sup> may lead to inflammation of the paws. Chronic inflammation may further lead to altered distribution of weight-bearing to the haired interdigital skin adjacent to digital pads. The skin can then become thicker and fibrotic, forming a

callus-like surface known as false paw pads (FPP).<sup>9</sup> Pads with FPP may further predispose to the formation of interdigital furunculosis (i.e. interdigital inflammatory nodules).<sup>6,9</sup> Dogs with chronic skin conditions are more likely to be exposed to antimicrobial treatments and frequent veterinary visits, both of which, in addition to skin lesions, increase the likelihood of acquiring antimicrobial-resistant bacteria.<sup>10,11</sup>

Brachycephalic dog breeds, such as the EB, have a congenitally flattened facial anatomy. This conformation is associated with several malformations of the head and neck and also has been shown to affect the structure of the ear.<sup>12–14</sup> Brachycephalic dogs have been reported to possess a significantly thicker tympanic bulla wall<sup>12</sup> and a lower tympanic bulla volume<sup>12,13</sup> than nonbrachycephalic dogs.<sup>12,13</sup> Fluid accumulation in the middle ear as an incidental finding appears to be more common in brachycephalic breeds.<sup>12–14</sup> Narrow horizontal ear canals, possibly due to conformational abnormality, are a common anecdotal finding in clinical practice and may be a predisposing factor for otitis.<sup>15</sup>

Skin and ear conditions may affect not only the wellbeing of the dog but also the quality of life (QoL) of the

Accepted 15 March 2019

**Source of funding:** The study was supported by grants from the Finnish Veterinary Foundation and the Finnish Kennel Club.

Part of this study was presented as an abstract at the Finnish Veterinary Conference, December 2017, Helsinki, Finland.

**Conflicts of interest:** No conflicts of interest have been declared.

dog's owner. QoL surveys have been developed to assess the owner-perceived impact of dermatological conditions on the wellbeing of dogs and their owners.<sup>16,17</sup> When these surveys are used in parallel with clinical parameters, a more extensive view of the effect of skin disease on the wellbeing of the dog and the owner may be obtained.

The aim of this study was, first, to describe the clinical dermatological findings from a group of EBs and compare the results with owner perceptions of their dog's dermatological health status and its possible impact on QoL. Secondly, we aimed to evaluate the ear canal structure of EBs by comparing computed tomographic (CT) findings between EBs and dogs with a medium-length skull (mesaticephalic dogs). In addition, dogs were screened for carriage of antimicrobial resistant bacteria. We hypothesized that dermatological conditions are common in EBs and that their ear canals are narrow compared with mesaticephalic dogs.

## Methods and materials

### Study design and population

We utilized the dogs participating in a cross-sectional EB health study, conducted at the Veterinary Teaching Hospital (VTH), University of Helsinki, Finland, from December 2014 to June 2015. The study included three co-projects evaluating the respiratory (including exercise assessment),<sup>18</sup> musculoskeletal and dermatological health of the dogs.

The inclusion criteria consisted of a purebred EB status (registered by the Finnish Kennel Club), an age of two to five years, and no history of airway or orthopaedic surgery nor conditions prohibiting anaesthesia. The owners of the dogs were recruited via the national breed club and social media. In the first stage, the owners completed an online pre-study questionnaire (Table S1) concerning their dog's physical activity and overall health. Altogether, 54 responses were received and dogs were classified according to their activity habits into three groups: (1) "active" which included dogs with daily exercise of  $\approx$ 5 km in 60 min, (2) "average" which included dogs with daily exercise of 1–5 km in a maximum of 45 min and (3) "nonactive" which included dogs with daily exercise of a maximum of 1.5 km in 40 min. Ten dogs from each group were chosen to participate in the order of enrolment. Only one dog per owner was chosen; however, if more dogs were suitable from one owner, the owner was free to decide which dog participated in the study. As two of the 30 chosen dogs could not participate due to acute illness, a total of 28 EB were included in the study. One dog had the first visit before the start of the dermatological study, leaving 27 dogs to participate in this co-project.

All study dogs were privately owned pet animals, whose owners signed an informed consent form. The Committee for Experimental Animals of Southern Finland and the Regional State Administrative Agency of Southern Finland (ESAVI) approved the study and this sub-project (ESAVI/11519/04.10.07/2014, ESAVI/9184/04.10.07/2014 and ESAVI/827/04.10.07/2015).

### Study protocol

At the first visit owners were interviewed to determine the dermatological disease history and a QoL questionnaire<sup>16</sup> was completed. The health of the skin and ears was evaluated by one of two clinicians (see details below).

At the second visit the dogs were anaesthetized. The FPP were graded, dermatological diagnostic samples were taken and computed tomography (CT) of the head was performed. For anaesthesia, the dogs were premedicated with intramuscular butorphanol 0.2 mg/kg (Torbutor, Richter Pharma; Wels, Austria), induced after preoxygenation with intravenous lidocaine 1 mg/kg (Lidocaine, Orion;

Espoo, Finland) and alfaxalone (Alfaxan, Jurox; West Sussex, UK) to effect (approximately 2 mg/kg); anaesthesia was maintained after intubation with sevoflurane (Sevoflurane, AbbVie; Espoo, Finland) and continuous infusion of lidocaine 2 mg/kg/h. CT studies from mesaticephalic dogs in the VTH database were used as a historical control to compare the ear canal surface areas.

### Dermatological disease history

The dermatological history was obtained in an interview with the owners by one of the two clinicians who performed the ear and skin evaluations, and the interviews included questions about pruritic behaviour (head shaking or scratching of the ears, paw licking, rubbing of the muzzle, scratching or rubbing of the flanks) and the history of treatment for dermatological conditions (otitis, pododermatitis or interdigital furunculosis, demodicosis, skin folds) (Table S2). Information on the previous use of systemic antimicrobial treatments was collected.

### Quality of life questionnaire

The pre-question was "Has your dog had skin or ear signs?" If the response was positive, the QoL questionnaire<sup>16</sup> was completed. The first QoL question asked the owners for their perceptions of the general severity of the disease, after which the questions concerned the QoL of the dog (Q2–8) and the owner (Q9–15). Each question had response options scored from 0 to 3 [(0) "not at all", (1) "a little", (2) "quite a bit" and (3) "very much"]. The maximum score was 3 for the first question and 42 for the QoL part of the questionnaire.

### Clinical evaluation

The health of the skin was evaluated using the Canine Atopic Dermatitis Extent and Severity Index (CADESI)-04.<sup>19</sup> Dogs with an index score of < 10 points were considered normal, whereas scores of 10–34 indicated mild, 35–59 indicated moderate and 60–180 points indicated severe dermatitis.

Ear health assessment was based on the Otitis Index Score, OTIS-3.<sup>20</sup> Clinical scores of  $\leq$ 3 per ear were considered normal. An otoscopic examination was performed in an awake animal and the status of the tympanic membrane was recorded if visualization was possible.

The severity of FPP was graded subjectively as follows: (0) no false pads, (1) mild, (2) moderate and (3) severe FPP. Example images of the grading are presented in Figure 1. The presence of interdigital furunculosis also was recorded (yes/no).

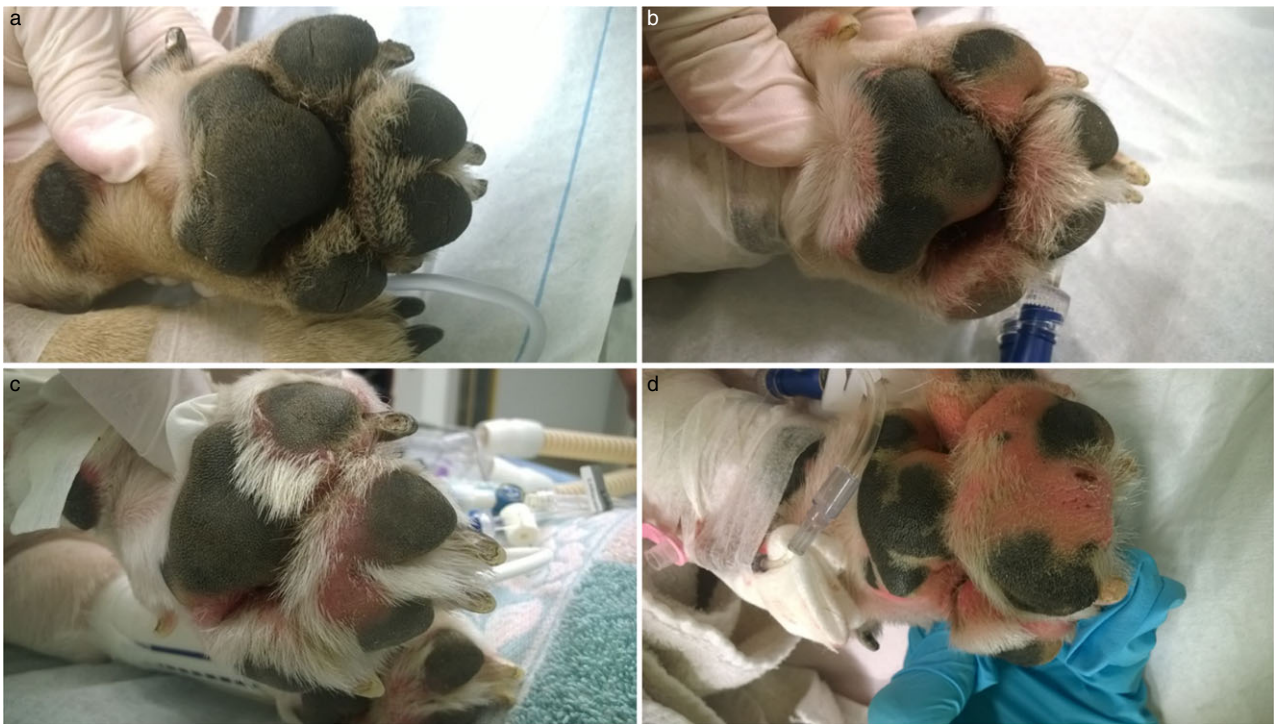The scores from CADESI-04, OTIS-3 (both ears), FPP scores (four paws) and presence of interdigital furunculosis were summed to form a total clinical score (TCS) to obtain an overview of the dermatological findings.

Interdigital deep skin scrapings were taken with a scalpel blade until capillary bleeding, together with trichograms. One scraping and one trichogram were taken from each paw, from the dorsal interdigital space of the left paws and the ventral aspect of the right paws. The samples were placed on glass slides with a drop of paraffin oil and examined at  $\times$ 100 magnification under a microscope to detect *Demodex* mites.

Bacteriological swabs to screen for the presence of meticillin-resistant *Staphylococcus pseudintermedius* (MRSP), *S. aureus* (MRSA) and extended spectrum beta-lactamase (ESBL)-producing *Enterobacteriaceae* were taken using sterile transport swabs (M40 Transystem, Copan Diagnostics; Murrieta, CA, USA). For MRSP/MRSA, two swabs were taken: one from the nares and the mouth/lip commissure, and one from the perianal region.<sup>11</sup> For ESBL, the swab was taken from the rectum.<sup>21</sup> The swabs were processed and bacterial identification, including susceptibility testing and Pulsed Field Gel Electrophoresis (PFGE) analysis, was performed as described previously.<sup>21,22</sup>

### Computed tomography and image processing

The CT examination of the whole head of EBs was performed in sternal recumbency with a helical dual slice scanner (Somatom Emotion Duo, Siemens AG; Forchheim, Germany) using a bone algorithm. The



**Figure 1.** Grading (0-3) of false paw pads in English bulldogs with examples of digital images used for evaluation. a) Grade 0; b) grade 1; c) grade 2; d) grade 3.

slice thickness was 2 mm, feed/rotation 4 mm and reconstruction increment 0.5 mm.

Selected multiplanar reconstruction images were used for measurements of the horizontal ear canal using OsiriX software (v9.0, OsiriX Foundation; Geneva, Switzerland). The window level and width were 300 and 1500, respectively. First, the dorsal image plane was determined from the midsagittal image as the parallel plane to the skull base. Second, the transverse image was straightened at the level of the middle ears using the cochleae as landmarks. The sagittal image for measuring the cross-sectional surface area (CSA; mm<sup>2</sup>) of the air-filled area in the osseous part of the ear canal (CSA1) was the one in which the bony wall was most clearly seen. The image for measuring the CSA of the widest part of the air-filled ear canal (CSA2) was selected as the one in which the cross-section of the canal was considered largest. The images were saved in DICOM format. In addition, the presence or absence of soft tissue attenuating material in the tympanic bullae and presence of significant external ear canal mineralization was recorded from the image series.

In order to compare the results, CT scans of mesaticephalic dogs were collected from the VTH patient database. The inclusion criteria were (i) a mesaticephalic breed, (ii) CT of the head performed for other than ear-related reasons, (iii) weight >13 kg and (iv) slice thickness of the scan ≤2 mm. Dogs with a history of ear and/or skin disease or with abnormal CT findings in the ear canals/bullae were excluded. Nine of 14 dogs had been imaged with the same scanner as the EBs of this study and five with a helical 64-slice scanner (Lightspeed VCT, GE Healthcare; Madison, WI, USA). All CT scans were examined by a single observer by using OsiriX v.9.0 (OsiriX Foundation); the observer did not participate in the clinical evaluations of the EBs.

In subgroup analysis, EBs that had either received veterinarian-prescribed care for otitis or had an OTIS-3 score of >3, or had discharge ≥2 in the OTIS-3 score, were excluded.

### Data analysis

Descriptive statistics were used to summarize the data, which are presented as medians and ranges. For categorical data, counts are provided. The Wilcoxon–Mann–Whitney U-test was used for non-normally distributed data to compare the TCS between dogs with and without owner-recognized skin or ear signs, and the distribution of

basic demographics (except for gender) as well as CSA1 and CSA2 measurements between EBs and mesaticephalic dogs. The distribution of gender between the groups was compared with the chi-square test. Spearman's rank correlation was used to evaluate the correlation of QoL with TCS in dogs with owner-recognized skin or ear signs. Statistical analyses were performed using IBM SPSS v.25 (IBM Corporation; Chicago, IL, USA). The significance level was set at  $P < 0.05$ .

### Results

Twenty-seven EBs (12 females and 15 males) were examined. The median age was three years (range 2–5 years) and the median weight was 25 kg (range 18.5–33.1 kg).

#### Dermatological disease history

In the interview focused on pruritic behaviour and the treatment history, 18 of 27 (67%) owners reported at least one type of pruritic behaviour; 13 of these owners reported paw licking and 10 head shaking or scratching of the ears in their dog. Fourteen (52%) dogs had received prescribed treatment for at least one of the following diseases: otitis (11 of 27), pododermatitis or furunculosis (8 of 27) or other dermatitis (5 of 27). One dog had received treatment for demodicosis. Of 27 dogs, nine (33%) had received systemic antibiotic treatments during the previous year and 10 (37%) more than one year before. In five (19%) dogs, systemic antibiotics had never been used and in three this information was missing. None of the dogs had ongoing medical treatments for skin or ear conditions at the time of the visits.

#### Quality of life

The QoL questionnaire was completed for 17 of 27 dogs (63%), as their owners responded “yes” to the

preliminary question. The median score for owner-assessed disease severity was 1 (Q1, range 0–3 points) and for the QoL part of the questionnaire (Q2–15) the median was 5.0 (range 0–12). Questions concerning therapies, time loss and expenditure had a median score of 1 point (range 0–2). All the other questions had a median of 0 (range 0–2).

### Clinical evaluation

Regarding CADESI-04, all dogs received scores indicating either mild (20 of 27, 74%) or moderate (7 of 27, 26%) dermatitis.

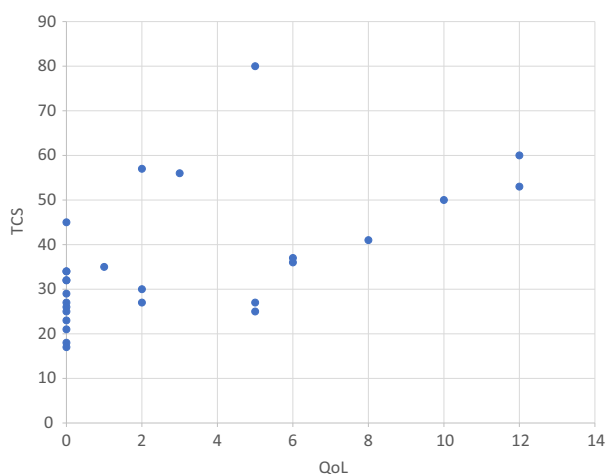
In four of 27 dogs, the OTIS-3 score was >3 (two dogs bilateral, two dogs unilateral) whereas the rest had normal scores. Of these, tympanic membranes could be visualized in only one dog. The presence of a tympanic membrane could not be assessed in an additional 10 dogs (16 ears) due to poor visibility associated with narrow ear canals or discharge in the ear canal.

Twenty-five of 27 dogs (93%) had FPP, of which 14 (52%) were mild, seven (26%) were moderate and four (15%) were severe. In the two most advanced cases, the dogs had severe FPP on all four paws. Nine dogs (33%) had interdigital furunculosis.

Regarding the TCS, the median was 26 (range 17–45) for dogs without and 36 (range 25–80) for dogs with owner-recognized skin and ear signs ( $P = 0.005$ ; Wilcoxon–Mann–Whitney  $U$ ). A correlation between the TCS and QoL scores in dogs with owner-recognized skin and ear signs ( $n = 17$ ) was observed (Spearman rho 0.507;  $P < 0.05$ ) (Figure 2).

All trichograms and skin scrapings were negative for *Demodex* mites.

Five dogs (19%) tested positive for MRSP and one (4%) tested positive for ESBL as part of their microbiota. None of the dogs had MRSA isolated. The MRSP strains were unrelated according to PFGE analysis (Figure S1)



**Figure 2.** Correlation between total clinical scores (TCS) and quality of life (QoL) scores in English bulldogs with owner-recognized skin or ear signs.

Individual TCS (scale 0–217) and QoL scores (scale 0–42) in English bulldogs (EBs) are plotted ( $n = 27$ ). The correlation between TCS and QoL in dogs with owner-recognized skin or ear signs was statistically significant ( $n = 17$ ,  $r = 0.507$ ,  $P < 0.05$ ). The TCS for EBs without owner-perceived skin and ear signs (QoL questionnaire not completed,  $n = 10$ ) are placed at the zero point on the QoL scale.

### Computed tomography image evaluations

Control images were obtained from 14 mesaticephalic dogs representing 13 breeds (breeds and reasons for a CT referral are presented in Table S3). There were no significant differences in gender or age between EBs and control dogs, but EBs were slightly heavier (median 25 kg, range 18.5–33.1 kg) than the controls (median 18 kg, range 13.7–35.9 kg,  $P = 0.04$ ; Wilcoxon–Mann–Whitney  $U$ ).

Horizontal ear canals of EBs were significantly narrower than mesaticephalic dogs in CSA1 and CSA2 ( $P < 0.001$ ; Wilcoxon–Mann–Whitney  $U$ ; Table 1). Subgroup analysis which excluded the 14 EBs that had received veterinarian-prescribed care for otitis and/or had an OTIS-3 score >3 or discharge  $\geq 2$  did not change the results (Table 1). Of the remaining 13 EBs included in the subanalysis, one or both tympanic membranes could not be visualized in six dogs (10 ears) due to narrow horizontal canals.

Two EBs had fluid/soft tissue attenuating material unilaterally in the middle ear. Both dogs had a history of ear treatment and one had an abnormal OTIS-3 score in the affected ear. The tympanum could not be evaluated in the ears with effusion. One of the dogs with middle ear effusion had marked unilateral mineralization of the ear canal. Another dog without effusion had marked mineralization in both ear canals. This dog had a history of ear treatments and an abnormal OTIS-3 score in both ears and lack of visibility of the tympanum.

### Discussion

All EBs in our study had abnormal findings on dermatological examination. Pedal lesions were frequent and all the dogs had abnormal CADESI-04 scores. These results are in accordance with a previous study of show EBs, which all had dermatological signs with frequent pedal lesions.<sup>3</sup> As all dogs had abnormal CADESI-04 scores and many owners reported pruritic behaviour in their dogs, allergic skin diseases may have been among the underlying causes of pododermatitis in some dogs in our study. Demodicosis, another common cause of pododermatitis, was not observed. Obesity was not considered to be a predisposing factor in this study, as the body condition scores were normal in most dogs.<sup>18</sup> Interestingly, 37% of the owners of our study stated that their pet did not have skin or ear-related problems. It is possible that especially mild signs are not noticed by the owner, as these dogs had lower TCS. The majority of those owners who reported skin problems did not consider them to affect the QoL of the dog or the family, or gave relatively low scores (mean 4.6, median 5.0, range 1–12) compared to the mean QoL scores reported previously for similar skin conditions (pododermatitis, 17.3 points, uncomplicated atopic dermatitis, 15.2 points).<sup>23</sup>

The EBs had narrow ear canals compared to mesaticephalic dogs. To determine whether this was conformational or caused by the ear disease, we repeated our analysis after excluding dogs with a history of ear treatment and/or elevated OTIS-3 scores and/or discharge in the ear canal, which could cause artificial narrowing of the canals in CT images. This had no effect on our results, suggesting that EBs have narrow ear canals due to

**Table 1.** Cross-sectional area (CSA) measurements of the ear canals in English bulldogs (EBs) and mesaticephalic dogs.

CSA (mm <sup>2</sup> )	EBs (n = 27)	Subgroup of EBs* (n = 13)	Mesaticephalic dogs (n = 14)	P-value
Median (range)				
CSA1 - osseous air-filled part of the horizontal ear canal	9.1 (0–22.0)	10.3 (0–22.0)	24.0 (11.2–31.4)	0.000**
CSA2 - the widest air-filled part of the horizontal ear canal	30.4 (0–65.2)	31.5 (15.5–65.2)	46.8 (33.5–75.6)	0.000**

\*Subgroup analysis excluding 14 EBs that had either received veterinarian-prescribed care for otitis and/or, had an OTIS-3 score of >3, and/or had discharge  $\geq 2$  in the OTIS-3 score.

\*\*P-values from comparisons between EBs and mesaticephalic dogs, as well as the subgroup of EBs and mesaticephalic dogs.

conformational reasons. We are aware of the methodological restrictions of CT image comparisons between EBs and mesaticephalic dogs. In some EBs, the air-filled area of the ear canal, especially in CSA1, was so small (even < 5 mm<sup>2</sup>) that precise measurement was challenging. It also is possible that we were unable to exclude all the EBs with a history of ear diseases or that these had not been noticed in some of the control dogs, because retrospective data can be incomplete. However, as the difference between the groups was large, it is unlikely that such matters had a major effect on our results. Clinical evaluations of the ears supported our results, as in many EBs the ear canals were so narrow that the presence of a normal tympanum could not be assessed. It is known that narrow conformation of the ear canals may predispose to otitis,<sup>15</sup> but an abnormal OTIS-3 score was a surprisingly rare finding in the dogs in our study. Previous studies have demonstrated a higher prevalence of subclinical middle ear effusion in brachycephalic dogs of various breeds.<sup>12–14</sup> However, only a small number of dogs in these studies were EBs. Two dogs in our study had fluid/soft tissue attenuating material unilaterally in the middle ear. Both dogs had a history of ear treatment and one also had an abnormal OTIS-3 score in the affected ear.

Discrepancies between the owner-reported skin problems and clinical findings raise the question of whether the owners of EBs are unaware of dermatological signs, especially when milder. In three cases, the owners reported either pruritic behaviour or previous treatment for dermatitis, although they responded that their dog did not have skin-related problems. We do not know whether pruritic behaviour was not considered by the owners as a sign of skin problems, or whether this discrepancy was simply a misinterpretation of the questions. In this study, owner-reported paw licking was infrequent (13 of 27, 48%) compared to the presence of pedal lesions. In the previous study of EBs, the frequency of owner-reported paw licking did not differ from a population of healthy dogs, although pedal lesions were very common.<sup>3</sup> It is possible that some EBs may be unable to express certain types of pruritic behaviour, such as paw-licking, due to their body conformation (i.e. inability to bring their paws near to the mouth) as has been suggested.<sup>3</sup> Another explanation might be that not all pedal lesions were pruritic. Of four dogs with an abnormal OTIS-3 score, only two had a history of prescribed treatment for otitis and one of head shaking or scratching of the ears. Thus, it may be that not all the owners recognized skin or ear lesions alone as a problem if no other clinical signs were displayed.

The prevalence of MRSP was higher in this group of EBs (19%) than estimated for the normal canine population in Finland (3%).<sup>10,22</sup> However, the results of this study were not surprising considering that all dogs had abnormal findings on dermatological examination and many had received systemic antibiotics. Pyoderma,<sup>24</sup> skin lesions, antimicrobial treatment and frequent veterinary visits<sup>10,11</sup> are known risk factors for MRSP. In Finland, the prevalence of MRSP in high-risk patients (e.g. dogs that suffer from skin-related diseases and/or have a history of heavy antimicrobial use) is approximately 10%.<sup>10</sup> Considering that all EBs of this study had clinical dermatological findings and that the majority of them had been exposed to antimicrobial products, the prevalence of 19% (95% CI 8–36%) is consistent with the prevalence observed in dogs with risk factors.

Various health problems, such as brachycephalic obstructive airway syndrome,<sup>18,25</sup> osteoarthritis<sup>26</sup> and certain dermatological conditions,<sup>1–5</sup> are common in EBs, although the Official United Kennel Club Breed Standard for the EB states that any conditions or exaggerations that are detrimental to the health, welfare, essence or soundness of the breed must be avoided.<sup>27</sup> Health problems of EBs also have received public attention in the media.<sup>28,29</sup> EB as a breed has low genetic diversity, which may be an obstacle to recreating healthier phenotypes from the existing genetic pool.<sup>30</sup> Moreover, in one study a frameshift mutation in the gene *DISHEVELLED 2 (DVL2)* was found in EBs and other breeds that share many similar morphological and disease-predisposition traits such as a brachycephalic skull morphology and vertebral malformations.<sup>31</sup> Analogous frameshift mutations in the human *DVL1* and *DVL3* genes cause Robinow syndrome, a congenital disorder characterized by similar craniofacial, limb and vertebral malformations to those exhibited in EBs. If the breed-associated characteristics are linked to a gene causing congenital disorders, it should be questioned why a characteristic that should be regarded as “abnormal” has actually become “normal” or even desired in the breed, and whether a better health status could be achievable with cross-breeding. It is not known whether dermatological conditions are related to this gene variant, but the dermatological health status of the breed is nevertheless concerning, because none of the EBs were clinically healthy and neither were the EBs of the previous study, even though show dogs should represent the ideal standard of the breed and are frequently used for breeding.<sup>3</sup>

There were certain limitations in this study. The sample size was small and the dogs were from a selected population. Dermatological health was not among the inclusion

criteria for selection. All of these facts can cause bias in the results. It may be that the results of this small study do not necessarily reflect the situation in the EB population in Finland and other countries. However, the included dogs were young adult EBs, and according to the owners' statements, most were without medical or other conditions affecting the dog's daily life.<sup>18</sup> In addition, although the dermatological health was not among the inclusion criteria, one-third of EBs were without owner-perceived skin and ear signs, but all of these had abnormal findings in the dermatological examination. It would, therefore, be unlikely that the high frequency of abnormal dermatological findings is due to bias or chance alone. However, as the dogs with owner-perceived skin and ear signs had higher TCS than the dogs without, the abnormal dermatological findings would have possibly been milder if the inclusion criteria had been dogs with no history or perceived history of dermatological or otic disease.

Another limitation is related to the questionnaires and clinical assessments. Even though the QoL questionnaire has been validated and is applicable to all dermatological conditions,<sup>16</sup> the pre-question and interview were not validated. The CADESI-04 score has been validated, but only for dogs with atopic dermatitis.<sup>19</sup> Nevertheless, it was considered the best available option for this study. OTIS-3 has not been validated, although in a small pilot study scores of  $\geq 4$  differentiated affected ears from healthy ears with a sensitivity of 91.1% and a specificity of 100%,<sup>20</sup> and was thus considered adequate for this study. A subjective grading system was created and used for FPP. Even though this was not validated, example pictures were used to standardize the assessments between the observers. Ideally, the same investigator would have performed all the evaluations. Otoloscopic examinations were performed in EBs during the first visit while the dogs were awake, as we did not want anaesthesia to affect the OTIS-3 assessments. It would have been optimal for evaluation of the tympanic membranes to repeat the otoscopic examination while the dogs were under anaesthesia during the second visit.

In conclusion, all EBs had abnormal dermatological findings that were unnoticed or considered to be of minor significance to QoL by most owners. The prevalence of MRSP was higher than estimated for the normal canine population in Finland. However, as the sample size was small, these findings may not be generalizable, although they indicate that further studies on the occurrence of dermatological conditions and the presence of MRSP are warranted. The EBs had narrow ear canals when compared to mesaticephalic dogs. Further studies with larger sample sizes are needed to verify the results and investigate whether this could be a breed-specific finding or applicable to brachycephalic dogs in general.

## Acknowledgements

The authors thank Roy Siddall for revising the language of the manuscript, Thomas Grönthal for performing PFGE analysis and Laura Parikka for her invaluable help as research nurse of this study.

## References

1. The Bulldog Information Library: A Guide to inherited and congenital diseases in bulldogs, including genetic predisposition to diseases. Available at: [www.bulldoginformation.com/bulldogs-hereditary-defects.html](http://www.bulldoginformation.com/bulldogs-hereditary-defects.html). Accessed Dec 18, 2018.
2. Miller WH, Griffin CE, Campbell KL. *Muller and Kirk's Small Animal Dermatology*, 7th edition. St Louis, MO: Elsevier Mosby, 2013; 62.
3. Webb Milum AN, Griffin CE, Blessing KS. A cross-sectional study of show English bulldogs in the United States: evaluating paw lesions, cytological findings, pruritic behaviours and gastrointestinal signs. *Vet Dermatol* 2018; 29: 395–401.
4. Mazrier H, Vogelnest LJ, Thomson PC et al. Canine atopic dermatitis: breed risk in Australia and evidence for a susceptible clade. *Vet Dermatol* 2016; 27: 167–174.
5. Miller WH, Griffin CE, Campbell KL. *Muller and Kirk's Small Animal Dermatology*, 7th edition. St Louis, MO: Elsevier Mosby, 2013; 678–680.
6. Paterson S. Elbow dysplasia as a cause of interdigital cysts in 20 dogs. *Vet Dermatol* 2012; 23: 90–91 (abstract).
7. White SD. Pododermatitis. *Vet Dermatol* 1989; 1: 1–18.
8. Kovacs MS, McKiernan S, Potter DM et al. An epidemiological study of interdigital cysts in a research Beagle colony. *Contemp Top Lab Anim Sci* 2005; 44: 17–21.
9. Duclos DD, Hargis AM, Hanley PW. Pathogenesis of canine interdigital palmar and plantar comedones and follicular cysts, and their response to laser surgery. *Vet Dermatol* 2008; 19: 134–141.
10. Grönthal T, Eklund M, Thomson K et al. Antimicrobial resistance in *Staphylococcus pseudintermedius* and the molecular epidemiology of methicillin-resistant *S. pseudintermedius* in small animals in Finland. *J Antimicrob Chemother* 2017; 72: 1,021–1,030.
11. Grönthal T, Moodley A, Nykäsenoja S et al. Large outbreak caused by methicillin resistant *Staphylococcus pseudintermedius* ST71 in a Finnish Veterinary Teaching Hospital - from outbreak control to outbreak prevention. *PLoS ONE* 2014; 9: e110084.
12. Salguero R, Herrtage M, Holmes M et al. Comparison between computed tomographic characteristics of the middle ear in non-brachycephalic and brachycephalic dogs with obstructive airway syndrome. *Vet Radiol Ultrasound* 2016; 57: 137–143.
13. Mielke B, Lam R, Ter Haar G. Computed tomographic morphometry of tympanic bulla shape and position in brachycephalic and mesaticephalic dog breeds. *Vet Radiol Ultrasound* 2017; 58: 552–558.
14. Owen MC, Lamb CR, Lu D et al. Material in the middle ear of dogs having magnetic resonance imaging for investigation of neurologic signs. *Vet Radiol Ultrasound* 2004; 45: 149–155.
15. Miller WH, Griffin CE, Campbell KL. *Muller and Kirk's Small Animal Dermatology*, 7th edition. St Louis, MO: Elsevier Mosby, 2013; 744–745.
16. Noli C, Minafò G, Galzerano M. Quality of life of dogs with skin diseases and their owners. Part 1: development and validation of a questionnaire. *Vet Dermatol* 2011; 22: 335–343.
17. Noli C. Assessing quality of life for pets with dermatologic disease and their owners. *Vet Clin North Am Small Anim Pract* 2019; 49: 83–93.
18. Lilja-Maula L, Lappalainen AK, Hyttiäinen HK et al. Comparison of submaximal exercise test results and severity of brachycephalic obstructive airway syndrome in English bulldogs. *Vet J* 2017; 219: 22–26.
19. Olivry T, Saridomichelakis M, Nuttall T. et al. Validation of the Canine Atopic Dermatitis Extent and Severity Index (CADESI)-4, a simplified severity scale for assessing skin lesions of atopic dermatitis in dogs. *Vet Dermatol* 2014; 25: 77–85.
20. Nuttall T, Bensignor E. A pilot study to develop an objective clinical score for canine otitis externa. *Vet Dermatol* 2014; 25: 530–537.
21. Grönthal T, Österblad M, Eklund M et al. Sharing more than friendship – transmission of NDM-5 ST167 and CTX-M-9 ST69

- Escherichia coli* between dogs and humans in a family, Finland, 2015. *Euro Surveill* 2018; 23. doi. 10.2807/1560-7917.es.2018.23.27.1700497.
22. Grönthal T, Ollilainen M, Eklund M et al. Epidemiology of methicillin resistant *Staphylococcus pseudintermedius* in guide dogs in Finland. *Acta Vet Scand* 2015; 57: 37.
  23. Noli C, Colombo S, Cornegliani L et al. Quality of life of dogs with skin disease and of their owners. Part 2: administration of a questionnaire in various skin diseases and correlation to efficacy of therapy. *Vet Dermatol* 2011; 22: 344–351.
  24. Huerta B, Maldonado A, Ginel PJ et al. Risk factors associated with the antimicrobial resistance of staphylococci in canine pyoderma. *Vet Microbiol* 2011; 150: 302–308.
  25. Packer RMA, Hendricks A, Burn CC. Do dog owners perceive the clinical signs related to conformational inherited disorders as 'normal' for the breed? A potential constraint to improving canine welfare *Anim Welf* 2012; 21: 81–93.
  26. Asher L, Diesel G, Summers JF et al. Inherited defects in pedigree dogs. Part 1: Disorders related to breed standards. *Vet J* 2009; 182: 402–411.
  27. Official UKC Breed Standards. Available at: <https://www.ukcdogs.com/docs/breeds/english-bulldog-breed-standard.pdf>. Accessed Dec 15, 2018.
  28. English bulldogs now so inbred their appalling health problems will not improve. Available at: <https://www.independent.co.uk/news/science/english-bulldog-health-problems-inbreeding-pedigree-dog-breeds-breeders-a7160041.html>. Accessed Dec 15, 2018.
  29. English Bulldog health problems prompt cross-breeding call. Available at: <https://www.bbc.com/news/science-environment-36916431>. Accessed Dec 15, 2018.
  30. Pedersen NC, Pooch AS, Liu H. A genetic assessment of the English bulldog. *Canine Genet Epidemiol* 2016; 3: 6. <https://doi.org/10.1186/s40575-016-0036-y>.
  31. Mansour TA, Lucot K, Konopelski SE et al. Whole genome variant association across 100 dogs identifies a frame shift mutation in DISHEVELLED 2 which contributes to Robinow-like syndrome in Bulldogs and related screw tail dog breeds. *PLoS Genet* 2018; 14: e1007850.

## Supporting Information

Additional Supporting Information may be found in the online version of this article.

**Figure S1.** *smal* restriction enzyme PFGE patterns and antimicrobial susceptibility profiles of five MRSP strains carried by English bulldogs in the study.

**Table S1.** Health survey of English bulldogs; online pre-study questionnaire.

**Table S2.** Dermatological disease history questionnaire.

**Table S3.** Breeds and reasons for referral for the mesaticephalic control dogs in computed tomography evaluations (n = 14).

## Résumé

**Contexte** – Les dermatoses sont fréquentes chez le bouledogue anglais (EB).

**Hypothèses/Objectifs** – Cette étude croisée décrit le statut dermatologique d'un groupe d'EBs et compare les résultats avec les perceptions des propriétaires et de leur impact possible sur la qualité de vie (QoL). Les données tomographiques (CT) des conduits auriculaires ont été comparées entre les EBs et les chiens mésocéphales.

**Sujets** – Vingt sept EBs participant à une étude de santé en Finlande.

**Matériels et méthodes** – Un questionnaire de QoL a été complété pour les EBs avec les signes cliniques rapportés par les propriétaires concernant la peau ou les oreilles. L'évaluation clinique comprenait un CADESI, un OIS (Otits Index Score), un grading des coussinets plantaires et la présence de furunculose interdigitée. Ces données ont été sommées pour former un score clinique total (TCS). La surface de coupe transversale des conduits auriculaires horizontaux a été mesurée des images de CT et comparées avec les images respectives de 14 chiens mésocéphales récupérées d'une base de données de patients.

**Résultats** – Tous les 27 EBs avaient des données anormales à l'examen dermatologique mais 37% des propriétaires n'avaient pas reconnus les signes auriculaires ou cutanés. Le score de QoL médian était 5,0 (écart 0-12) et corrélé avec TCS (coefficient de corrélation = 0.507,  $P < 0.05$ ). Les bouledogues anglais avaient des conduits auriculaires plus étroits que les chiens mésocéphales ( $P < 0.001$ ).

**Conclusions et importance clinique** – Tous les EBs avaient des anomalies dermatologiques qui n'étaient pas remarquées ou considérées comme mineures par rapport à la QoL par la plupart des propriétaires. Les conduits auriculaires plus étroits étaient fréquents, possiblement en relation avec la conformation brachycéphalique de la race.

## Resumen

**Introducción** – las enfermedades dermatológicas son comunes en los perros de raza Bulldog Inglés (EB).

**Hipótesis/Objetivos** – este estudio transversal describe el estado de salud dermatológica de un grupo de EBs y compara los resultados con las percepciones de los propietarios y su posible impacto en la calidad de vida (QoL). Los hallazgos tomográficos computarizados (TC) de los canales auditivos se compararon entre EB y perros mesaticefálicos.

**Animales** – veintisiete EBs que participaban en un estudio de salud en Finlandia.

**Métodos y materiales** – se completó un cuestionario de calidad de vida para EBs con signos clínicos reportados por el propietario y que hacían referencia a la piel o al oído. La evaluación clínica incluyó el registro del índice de extensión y severidad de la dermatitis atópica canina, la puntuación del índice de otitis, la gradación de la almohadilla falsa plantar y la presencia de furunculosis interdigital. Estos valores se sumaron para formar una puntuación clínica total (TCS). Las áreas de la superficie de la sección transversal de los canales horizontales del oído se midieron a partir de imágenes de TC y se compararon con las imágenes respectivas de 14 perros mesaticefálicos recogidos de una base de datos de pacientes.

**Resultados** – los 27 EBs tuvieron hallazgos anormales en el examen dermatológico, pero el 37% de los propietarios no había reconocido signos en la piel o en los oídos. La puntuación media de la calidad de vida fue de 5,0 (rango 0-12) y se correlacionó con TCS (coeficiente de correlación = 0,507,  $P < 0.05$ ). Los perros EB tenían canales auditivos horizontales más estrechos que los perros mesaticefálicos ( $P < 0.001$ ).

**Conclusiones e importancia clínica** – todos los perros EB tuvieron hallazgos dermatológicos anormales que la mayoría de los propietarios no notaron o consideraron de menor importancia para la calidad de vida. Los canales del oído estrechos fueron un hallazgo común, posiblemente relacionados con la conformación braquicefálica de la raza.

## Zusammenfassung

**Hintergrund** – Dermatologische Probleme sind bei englischen Bulldoggen (EBs) häufig.

**Hypothese/Ziele** – Diese Querschnittsstudie beschreibt den dermatologischen Gesundheitsstatus einer Gruppe von EBs und vergleicht die Ergebnisse mit den Erwartungen der BesitzerInnen und den möglichen Einfluss auf die Lebensqualität (QoL). Ergebnisse der Computertomografischen Untersuchung (CT) der Ohrkanäle wurden zwischen EBs und mesaticephalischen Hunden verglichen.

**Tiere** – Siebenundzwanzig EBs nahmen an einer Gesundheitsstudie in Finnland teil.

**Methoden und Materialien** – Es wurde ein QoL Fragebogen für EBs ausgefüllt, worin die BesitzerInnen klinische Anzeichen, die auf eine Ohr oder Hauterkrankung hinweisen könnten, beschrieben. Die klinische Evaluierung beinhaltete den Canine Atopic Dermatitis Extent and Severity Index festzuhalten, sowie den Otitis Index Score, eine falsche Winkelung der Fußballen und das Auftreten von interdigitaler Furunkulose. Aus diesen wurde ein Gesamtwert für die Klinik (TCS) erfasst. Die Querschnittsoberflächen der horizontalen Ohrkanäle wurden in CT Bildern gemessen und mit entsprechenden Bildern von 14 mesaticephalischen Hunden, die aus der Patientendatei genommen wurden, verglichen.

**Ergebnisse** – Alle 27 EBs zeigten abnormale Befunde bei der dermatologischen Untersuchung, aber 37% der BesitzerInnen erkannten diese Haut oder Ohrenanzeichen nicht. Der mediane QoL Wert betrug 5,0 (Bereich von 0-12) und korrelierte mit TCS (Korrelationskoeffizient = 0,507,  $P < 0,05$ ). Die Englischen Bulldoggen hatten schmälere horizontale Ohrkanäle als die mesaticephalischen Hunde ( $P < 0,001$ ).

**Schlussfolgerungen und klinische Bedeutung** – Alle EBs hatten abnormale dermatologische Befunde, die nicht bemerkt oder von den meisten BesitzerInnen als weniger signifikant für die QoL empfunden wurden. Enge Ohrkanäle kamen häufig vor, was möglicherweise mit der brachycephalischen Formation des Kopfes dieser Rasse im Zusammenhang stand.

## 要約

**背景** – 皮膚症状はイングリッシュ・ブルドッグ(EB)にとって一般的な臨床症状である。

**仮説/目的** – 本横断研究の目的は、EBグループの皮膚科学的健康状態を記述し、飼い主の認識結果およびそれがQoLに影響を与えるかどうか比較することである。外耳道のコンピューター断層撮影(CT)所見をEBと中頭犬間で比較した。

**被験動物** – フィンランドの健康調査に参加しているEB27頭。

**材料と方法** – オーナーが報告した臨床徴候が皮膚または耳に関係したEBについて、QoL質問票を完遂した。臨床評価には、犬アトピー性皮膚炎の程度と重症度指数、耳炎指数スコア、偽パッドグレード評価、および指間神経痛の存在を記録した。これらを合計して総臨床スコア(TCS)を作成した。水平耳道の断面積はCT画像から測定し、患者データベースから収集した14頭の中頭犬のそれぞれの画像と比較した。

**結果** – EB27頭すべてが皮膚科検査で異常所見を示したが、オーナーの37%が皮膚または耳の臨床徴候を認識していなかった。中央値スコアは5.0(範囲 0~12)であり、TCSと相関していた(相関係数= 0.507、 $P < 0.05$ )。イングリッシュ・ブルドッグは中頭犬よりも狭い水平耳道を有していた( $P < 0.001$ )。

**結論と臨床的重要性** – すべてのEBはほとんどの飼い主にとって気付かれない、またはQoLにとって重要性が低いと考えられた異常な皮膚科所見を有していた。狭い外耳道は共通であり、おそらく短頭種形態に関連していた。

## 摘要

**背景** – 皮肤病在英国斗牛犬(EBS)中很常见。

**假设/目标** – 该横向研究描述了一组EBSs的皮肤健康状况,并将结果与主人的感受及其对生活质量(QoL)的可能影响进行比较。比较EBSs和中型头犬耳道的计算机断层扫描(CT)结果。

**动物** – 27只参与芬兰健康研究的EBSs。

**方法和材料** – 完成针对EBSs的QoL问卷调查,其中主人报告的临床症状指的是皮肤或耳道。临床评估包括记录犬异位性皮炎严重程度指数、中耳炎指数评分,假爪垫分级和趾间疔病的存在,将它们相加得出总临床评分(TCS)。用CT图像测量水平耳道的横截面面积,并与从病患数据库收集14只中型头犬的相应图像进行比较。

**结果** – 所有27只EBSs的皮肤检查均有异常,但37%的主人未发现皮肤或耳道症状。中位QoL评分为5.0(范围0-12),与TCS相关(相关系数= 0.507,  $P < 0.05$ )。英国斗牛犬的水平耳道比中型头犬更窄( $P < 0.001$ )。

**结论和临床价值** – 所有EBSs的皮肤都有异常,大多数主人都没有注意到或认为对其生活质量影响不大。耳道狭窄十分常见,可能与该品种的短头结构有关。



**Resumo**

**Contexto** – As dermatopatias são comuns nos buldogues ingleses (BIs).

**Hipótese/Objetivos** – Este estudo transversal descreve o status de saúde dermatológica de um grupo de BIs e compara os resultados com as percepções dos proprietários e o seu possível impacto na qualidade de vida (QoL). Os achados de tomografia computadorizada (TC) dos condutos auditivos foram comparados entre BIs e cães mesaticéfalos.

**Animais** – Vinte e sete BIs participantes de um estudo de saúde na Finlândia.

**Métodos e materiais** – O questionário de QoL foi preenchido para BIs com sinais clínicos relacionados à pele e orelhas relatados pelos proprietários. A avaliação clínica incluiu o registro do Índice de severidade e extensão da dermatite atópica canina (*Canine Atopic Dermatitis Extent and Severity Index*), Escore índice de otite (*Otitis Index Score*), classificação dos coxins falsos e a presença da furunculose interdigital. Estes dados foram reunidos para formar um escore clínico total (ECT). As áreas transversais dos condutos auditivos horizontais foram mensuradas das imagens de TC e comparadas com as imagens respectivas de 14 cães mesaticéfalos coletadas do banco de dados de pacientes.

**Resultados** – Todos os 27 BIs apresentaram alterações ao exame dermatológico, mas 37% dos proprietários não reconheceram sinais cutâneos ou otológicos. A mediana do escore QoL foi 5 (intervalo 0–12) e correlacionou com o ECT (coeficiente de correlação = 0.507,  $P < 0.05$ ). Os buldogues ingleses apresentaram condutos auditivos horizontais mais estreitos que os cães mesaticéfalos ( $P < 0.001$ ).

**Conclusões e importância clínica** – Todos os BIs apresentaram achados dermatológicos anormais que não foram notados ou foram considerados de mínimo impacto na QoL pela maioria dos proprietários. Condutos auditivos estreitos foram comuns, possivelmente relacionados à conformação braquicefálica da raça.